LANE MEDICAL LIBRARY STANFORD
D581 .C88 1928 1 OLD
Special cytology : the form and function
24503091453

DEC 3 0 1966



LANE
MEDICAL LIBRARY
SEAL OF THE LELAND STANFORD JUNIOR UNIVERSITY
SEMPER VIRENS
1885

Gift of
Dr. J. Garrott Allen

300 PASTEUR DRIVE
PALO ALTO, CALIF. 94304

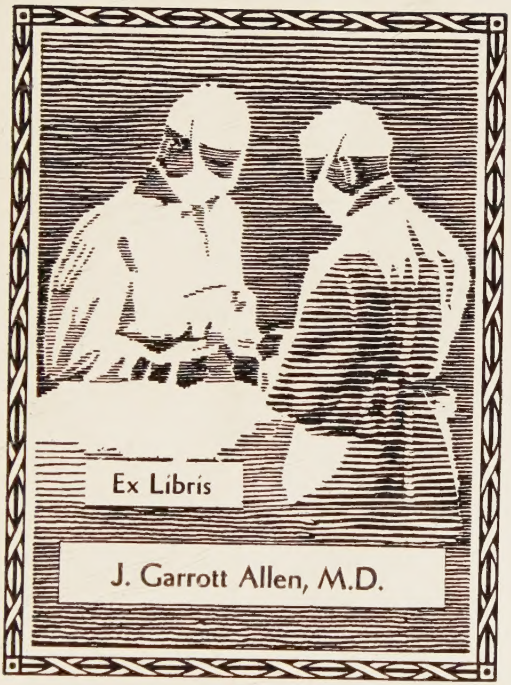

D 581
C 88
1928

SPECIAL CYTOLOGY

VOLUME ONE

Digitized by the Internet Archive
in 2025

https://archive.org/details/specialcytology0001edmu

SPECIAL CYTOLOGY

THE FORM AND FUNCTIONS OF THE CELL IN HEALTH AND DISEASE

A Textbook for Students of Biology and Medicine

Contributors

LESLIE B. AREY
PERCIVAL BAILEY
R. R. BENSLEY
C. H. BUNTING
ALEXIS CARREL
A. E. COHN
G. W. CORNER
E. V. COWDRY
HAL DOWNEY
G. CARL HUBER
J. ALBERT KEY
E. B. KRUMBHAAR
ALBERT KUNTZ
LEO LOEB
C. C. MACKLIN
M. T. MACKLIN
E. F. MALONE
F. C. MANN
DAVID MARINE
A. A. MAXIMOW
E. B. MEIGS
C. W. METZ
W. S. MILLER
EUGENE L. OPIE
WILDER G. PENFIELD
A. T. RASMUSSEN
J. PARSONS SCHAEFFER
G. E. SHAMBAUGH
P. G. SHIPLEY
G. N. STEWART
D. R. STOCKARD
D. L. STORMONT
FREDERICK TILNEY
T. WINGATE TODD
G. B. WISLOCKI

Edited by

EDMUND V. COWDRY

The Rockefeller Institute for Medical Research

693 ILLUSTRATIONS

VOLUME ONE

PAUL B · HOEBER · INC

NEW YORK · MCMXXVIII

LANE LIBRARY. STANFORD UNIVERSITY

Copyright, 1928
By PAUL B. HOEBER, Inc.
All Rights Reserved

Published March, 1928

Printed in the United States of America

288
928
v. 1

INSCRIBED TO
ROBERT RUSSELL BENSLEY

PREFACE

One principle has been held in mind in organizing this book, namely, that each division should be entrusted to an investigator who through his own researches has personal knowledge of the subject on which he writes. Adherence to this method of procedure has brought to light an apparently significant fact. It has been found that our contributors are often engaged in branches of biology and medicine, which, at first sight, seem to be far removed from what is ordinarily regarded as "cytology." This clearly illustrates the central position of modern cytology in the biological and medical sciences.

In order better to understand physiological processes, or more intelligently to treat disease, which amounts to much the same thing, these investigators have, one and all, resorted to a study of the fundamental living units, that is to say, of the cells of the tissues with which they are concerned. They have done this in different ways, directly and sometimes indirectly, and the results make for progress. Some of them are mildly surprised to find that they are classified as cytologists and to realize that they have gone further than the professional cytologists of the old school.

The purpose of this book is, through the friendly cooperation of such specialists, to present a detailed statement of the types of cells which make up the body, and which serve different functions; the nerve cells, gland cells, blood cells, and others. It is under these divisions that information is usually required. We have not hesitated to include physiological and pathological conditions, because otherwise the presentation would be both sterile and uninteresting.

The book is to be regarded as supplementary to an earlier volume called "General Cytology," published by the University of Chicago Press in 1924, and now in its second printing. In "General Cytology" the fundamental principles of architecture and activity which cells of different kinds possess in common were discussed by a group of workers chiefly recruited from the biological sciences. This involved, primarily, a rapprochement between physicochemical and morphological points of view, which is one of the most recent and profitable departures in cytology.

The practise of considering the general and special aspects of a large subject separately, yet in a coordinated way, has already proved its usefulness in certain branches of medicine, for example, in pathology. The

student will also find that it is a sign of the times to secure widespread cooperation in which each contributor, by reason of intimate knowledge of his subject, assumes full responsibility for what he writes. The day has passed when the ground can be adequately covered by a single author, although by writing from a narrower point of view he would achieve greater uniformity in style and arrangement. What is thus unavoidably lost in unity and coherence is, we believe, compensated for by increase in accuracy. It may be more refreshing (at least less monotonous) for the student to be led by different people into their chosen fields, in language which is their own, than to read hundreds of pages of second-hand information.

Certain restrictions are necessary in order that a subject so vast may be confined within the scope of two volumes of convenient size. Thus, attention is focused upon the principal types of cells which make up the human body. Lower forms, below the mammalia, are only mentioned to make the meaning clear, when breadth of view and perspective are necessary. Similarly, conditions in the adult are stressed, but little embryology being given. Historical considerations are usually set aside, because we are concerned with the present and look to the future rather than to the past (see particularly Dr. Carrel's Introduction). This means that the writers, at their discretion, emphasize the known facts and probable explanations and give suggestions as to the most likely avenues of advance. It is something more valuable and less tedious than a mechanical review of the literature that is given; it is, we trust, a mature and well-balanced opinion that is offered, based upon much original research. While attempting to do justice to individual discoveries, it is quite impossible as well as undesirable to attempt to point out the exact part played by the thousands who have contributed to the development of our science.

Methods of technique are treated only superficially, but their great importance is recognized. Indeed, a similar cooperative book on "Cytological Technique" is being prepared under the editorship of Professor C. E. McClung of the University of Pennsylvania, and will soon be published by Paul B. Hoeber, Inc., for it is only by the instrumentality of new methods that we may hope to unravel old and new problems. Because of these restrictions, space permits only a discussion of the really important aspects of the subject. This inability to expand is a blessing in disguise, for it leads to the elimination of what we now look upon as the nonessentials, although those who follow us will be better able to judge. In order that each special type of cell may be followed further than we are permitted to go, by those who are so inclined, many leading references to the literature are cited.

Help has been generously given from so many sources, to the editor and to our contributors, that it would be an impossible task to make due

acknowledgment in the preface. This is left to the individual writers. The editor is particularly indebted to the Publisher, Mr. Paul B. Hoeber. He is also thankful to his secretary Miss Marguerite M. Theiss who had charge of the work during his absence in Africa.

E. V. Cowdry

The Rockefeller Institute for Medical Research
New York City
January, 1928

TABLE OF CONTENTS

		PAGE
PREFACE		vii
SECTION		
I.	INTRODUCTION — *Alexis Carrel*	1
II.	THE SKIN AND ITS DERIVATIVES — *E. V. Cowdry*	11
III.	THE MUCOUS MEMBRANE OF THE NASAL CAVITY AND THE PARANASAL SINUSES — *J. Parsons Schaeffer*	45
IV.	THE EPITHELIUM OF THE LOWER RESPIRATORY TRACT — *William Snow Miller*	69
V.	THE SALIVARY GLANDS — *D. L. Stormont*	89
VI.	THE GASTRIC GLANDS — *R. R. Bensley*	137
VII.	THE INTESTINAL EPITHELIUM — *Charles Clifford Macklin and Madge Thurlow Macklin*	169
VIII.	THE CYTOLOGY OF THE LIVER AND ITS FUNCTIONAL SIGNIFICANCE — *Frank C. Mann*	203
IX.	CYTOLOGY OF THE PANCREAS — *Eugene L. Opie*	239
X.	THE ERTHYROCYTE — *E. B. Krumbhaar*	273
XI.	THE LYMPHOCYTES AND PLASMA CELLS — *Alexander A. Maximow*	319
XII.	THE MYELOBLAST — *Hal Downey*	369
XIII.	THE GRANULAR LEUCOCYTES — *C. H. Bunting*	401
XIV.	THE MACROPHAGES OR HISTIOCYTES — *Alexander A. Maximow*	425
XV.	THE STRUCTURE OF THE HYPOPHYSIS CEREBRI OF MAN AND OF THE COMMON LABORATORY MAMMALS — *Percival Bailey*	485
XVI.	THE PINEAL GLAND — *Frederick Tilney*	501
XVII.	THE THYROID, PARATHYROIDS AND THYMUS — *David Marine*	549
XVIII.	THE SUPRARENAL BODIES — *G. N. Stewart*	621
XIX.	RENAL TUBULES — *G. Carl Huber*	661
XX.	CARTILAGE AND BONE — *P. G. Shipley*	703
XXI.	THE SYNOVIAL MEMBRANE OF JOINTS AND BURSAE — *J. Albert Key*	735
XXII.	STRIATED AND SMOOTH MUSCLE — *Edward B. Meigs*	767
XXIII.	CARDIAC MUSCLE — *A. E. Cohn*	805
XXIV.	THE SPECIALIZED SYSTEMS OF THE HEART — *T. Wingate Todd*	851
XXV.	VISUAL CELLS AND RETINAL PIGMENT — *Leslie Brainerd Arey*	887
XXVI.	CYTOLOGY OF THE INTERNAL EAR — *George E. Shambaugh*	927
XXVII.	THE INTERNAL ARCHITECTURE OF NERVE CELLS — *E. V. Cowdry*	963
XXVIII.	THE GENERAL RELATION OF HISTOLOGICAL CHARACTER TO FUNCTION IN MAMMALIAN NEURONS — *E. F. Malone*	989
XXIX.	THE SYMPATHETIC NERVE CELLS — *Albert Kuntz*	1007

SECTION PAGE

XXX. Neuroglia and Microglia. The Interstitial Tissue of the Central Nervous System . . . . . *Wilder Penfield* 1031

XXXI. The Cytology of the Cerebrospinal Pathway . . *G. B. Wislocki* 1069

XXXII. Cytology of the Ovum, Ovary and Fallopian Tube. *G. W. Corner* 1109

XXXIII. Cellular Changes in the Fluid of the Mammalian Vagina *Charles R. Stockard* 1151

XXXIV. The Cytology of the Mammary Gland. . . . . *Leo Loeb* 1173

XXXV. Interstitial Cells of the Testis. . . . . *A. T. Rasmussen* 1209

XXXVI. The Male Germ Cells. . . . . *Charles W. Metz* 1257

XXXVII. The Seminal Vesicles, Prostate and Bulbo-urethral Glands *Charles Clifford Macklin* 1301

Index 1327

LIST OF CONTRIBUTORS

AREY, LESLIE BRAINERD, PH.D.
Robert Laughlin Rea Professor of Anatomy, Northwestern University Medical School, Chicago.

BAILEY, PERCIVAL, M.D., PH.D.
Instructor in Surgery and Neuropathology, Harvard Medical School; Associate in Surgery, Peter Bent Brigham Hospital; Consulting Neurologist to New England Deaconess Hospital, Boston.

BENSLEY, ROBERT RUSSELL, A.B., M.B., SC.D.
Professor of Anatomy, University of Chicago, Chicago.

BUNTING, CHARLES HENRY, B.S., M.D.
Professor of Pathology, University of Wisconsin, Madison.

CARREL, ALEXIS, L.B., SC.B., M.D., SC.D.
Member, The Rockefeller Institute for Medical Research, New York.

COHN, ALFRED EINSTEIN, A.B., M.D.
Member, The Rockefeller Institute for Medical Research, New York.

CORNER, GEORGE WASHINGTON, A.B., M.D.
Professor of Anatomy, University of Rochester, New York.

COWDRY, EDMUND VINCENT, PH.D.
Associate Member, The Rockefeller Institute for Medical Research, New York.

DOWNEY, HAL, PH.D.
Professor of Histology, Department of Zoology, University of Minnesota, Minneapolis.

HUBER, GOTTHELF CARL, M.D.
Professor of Anatomy and Director of Anatomic Laboratories; Dean of the Graduate School, University of Michigan, Ann Arbor.

KEY, JOHN ALBERT, B.S., M.D.
Associate in Orthopedic Surgery, Washington University; Director of Research, Shriner's Hospital for Crippled Children, St. Louis.

KRUMBHAAR, EDWARD BELL, A.B., M.D., PH.D.
Professor of Pathology, School of Medicine, University of Pennsylvania, Philadelphia.

KUNTZ, ALBERT, M.D., PH.D.
Professor of Anatomy, St. Louis University School of Medicine.

LOEB, LEO, M.D.
Professor of Pathology, Washington University School of Medicine, St. Louis.

MACKLIN, CHARLES CLIFFORD, M.B., M.D., M.A., PH.D., F.R.C.S.
Professor of Histology and Embryology, University of Western Ontario Medical School, London, Ontario.

MACKLIN, MADGE THURLOW, A.B., M.D.
Instructor in Histology and Embryology, University of Western Ontario Medical School, London, Ontario.

MALONE, EDWARD FALL, A.B., M.D.
Brunning Professor of Anatomy, University of Cincinnati, Ohio.

Mann, Frank Charles, m.a., m.d.
Professor of Experimental Surgery and Pathology, Mayo Foundation, University of Minnesota; Director, Division of Experimental Surgery and Pathology, Mayo Clinic and Mayo Foundation, Minneapolis.

Marine, David, a.b., m.a., m.d.
Assistant Professor of Pathology, Columbia University; Director of Laboratories, Montefiore Hospital, New York.

Maximow, Alexander A., m.d., sc.d.
Professor of Anatomy, University of Chicago, Chicago.

Meigs, Edward Browning, a.b., m.d.
Physiologist, Bureau of Dairy Industry, U. S. Department of Agriculture, Washington, D. C.

Metz, Charles William, ph.d.
Staff Member, Department of Genetics, Carnegie Institution of Washington, Washington, D. C.

Miller, William Snow, m.d., sc.d.
Professor of Anatomy, Emeritus, University of Wisconsin, Madison.

Opie, Eugene Lindsay, m.d.
Professor of Pathology, University of Pennsylvania; Director of Laboratories, Henry Phipps Institute, Philadelphia.

Penfield, Wilder, m.a., b.sc., m.d.
Assistant Professor of Surgery, Columbia University; Associate Attending Surgeon, Presbyterian Hospital; Associate Surgeon, Neurological Institute, New York.

Rasmussen, Andrew Theodore, a.b., ph.d.
Professor of Neurology, University of Minnesota, Minneapolis.

Schaeffer, Jacob Parsons, m.d., ph.d., sc.d.
Professor of Anatomy and Director of the Daniel Baugh Institute of Anatomy of the Jefferson Medical College, Philadelphia.

Shambaugh, George Elmer, ph.b., m.d.
Clinical Professor and Chairman, Department of Laryngology and Otology, Rush Medical College, University of Chicago; Otolaryngologist, Presbyterian Hospital, Chicago.

Shipley, Paul Galpin, m.d.
Associate Professor Pediatrics, Johns Hopkins University School of Medicine; Associate Attending Physician, Johns Hopkins Hospital, Baltimore.

Stewart, George Neil, m.a., m.d., sc.d., ll.d., d.p.h.
Professor of Experimental Medicine and Director, H. K. Cushing Laboratory of Experimental Medicine, Western Reserve University, Cleveland.

Stockard, Charles Rupert, ph.d., m.d., sc.d.
Professor of Anatomy, Cornell University Medical College, New York.

Stormont, Daniel Lytle, a.b., ph.d.
Assistant in Surgery, Rush Medical College, University of Chicago, Chicago; Formerly Instructor of Anatomy, Yale University School of Medicine, New Haven.

Tilney, Frederick, a.b., m.d., ph.d.
Professor of Neurology, Columbia University; Neurologist, Roosevelt and Presbyterian Hospitals and Neurological Institute, New York.

Todd, Thomas Wingate, m.b., ch.b., f.r.c.s.
Henry Willson Payne Professor of Anatomy; Director of the Hamann Museum of Comparative Anthropology and Anatomy, Western Reserve University, Cleveland.
Wislocki, George Bernays, m.d.
Department of Anatomy, Johns Hopkins University, Baltimore.

Section I
INTRODUCTION

Section I

INTRODUCTION

ALEXIS CARREL

THE microscopic drop of protoplasm which composes the body of a cell is an organism of great structural complexity—its fragility is so extreme that cytological investigation requires the invention of methods more delicate than those of the other experimental sciences. Although the phenomena which characterize life are of a physico-chemical nature, the secrets of their mechanism will not be discovered by chemists or physicists. Thus, physiological problems are far more complex than those of the sciences which deal with inanimate matter. To an extensive knowledge of physics and chemistry, the cytologist must add the mastery of the difficult procedures developed for the study of living protoplasm. Biology, which occupies in the hierarchy of sciences a higher rank than mathematics, chemistry and physics, must utilize their principles and techniques in the construction of its own methods of investigation.

The purpose of cytology is not only to gain an accurate morphological knowledge of the cell, but also to learn its chemical constitution, the nature of its organs, the functions of its nucleus and cytoplasmic structures, etc. The condition of the cell, however, is closely related to that of its medium. In unicellular organisms living in water as free individuals, these relations are comparatively simple. They are far more complex in Metazoa, where the cells form a community immersed in the interstitial lymph, which was called by Claude Bernard "milieu intérieur," or intraorganic medium. This great physiologist believed that the metabolic condition of a cell depends on the composition of its medium. It is obvious that blood and lymph should contain the substances which regulate cell activity and cause each part of the organism to work in harmony with the whole. We know, for instance, that in rabbits the setting free by the corpus luteum of its hormone into the circulation determines the proliferation of the mammary cells, and that the testicular hormone of the cock brings about the growth of the comb. Some years ago, when the rate of multiplication of fibroblasts in pure culture was discovered to depend on the concentration of certain substances in the pericellular fluid, the demonstration of the close relations between cells and medium was completed. It has also been found that fibroblasts, monocytes and epithelial cells modify their anatomical characteristics as well as their metabolic activity according to the composition of the medium. The morphological appearance of a cell depends on its functional state.

Cytology, therefore, must deal not only with the anatomical and chemical constituents of the tissues but also with the humors which control their metabolism. The study of the properites which determine the specific response of each cell type to the normal and abnormal constituents of the humors leads to the solution of the most important physiological problems. The qualitative and quantitative reactions of the tissues to the physicochemical conditions of the intraorganic medium are responsible for the harmonious growth of the body. If we knew how each cell type is directed by its specific properties to react automatically against the substances set free by other cells into the blood or the interstitial lymph, the obscure problems of morphogenesis would be nearly solved. The discovery of some of the substances which regulate the proliferation of fibroblasts, epithelial cells and macrophages has thrown a little light on the mechanisms which stop the growth of tissues in the adult animals and bring about a resumption of cell activity during the processes of inflammation, wound healing and tumor formation. A complete knowledge of the characteristics essential to each cell type and of its virtual potentialities would render possible the prediction of the behavior within the organism of any tissue if the physicochemical conditions of the pericellular fluid were stated. Thus, the ultimate aim of cytology is the discovery of the principles which cause a cell to be simultaneously an individual and one of the building stones of the organism.

It is evident that cytology cannot reach its goal with the mere help of the classical techniques of microscopic anatomy. These techniques, however, have brought to us a large amount of information and will remain a useful instrument of investigation. It cannot be doubted, on the other hand, that the fixation of the tissues modifies the appearance of the protoplasmic organs and even creates artificial structures. There is a tendency among modern cytologists to revert to the practice of the old anatomists and to study living cells instead of dead specimens. The handling of fresh tissues is more troublesome than that of fixed preparations, but the knowledge which is gained from it is of a more satisfactory nature. The examination of cells within the body of a living animal is far from being a new procedure. Forty years ago excellent techniques had already been developed by which epithelial cells, leucocytes, muscle cells, etc., could be studied for long periods of time on the curarized frog. The more elaborate of these techniques was devised by Thoma and Arnold and perfected by Prudden who introduced it to American workers. But it was soon forgotten. A few years ago, Prudden again taught this procedure to some of us and demonstrated how easily several types of cells can be observed with high power lenses. However, few histologists have utilized this technique, although, combined with the injection of dyes, it could be applied to the investigation of many problems. By using a simple procedure, Clark has studied the growth of the lymph

vessels and the absorption of fat by leucocytes in the tails of living tadpoles. It is well known that Krogh observed directly the functioning of capillaries in living animals. Later, Richards and Schmidt succeeded in observing the glomeruli of the kidney during the process of secretion. It is probable that these techniques could be improved and applied to a number of anatomical structures in warm-blooded animals. But their field will always remain limited, as they do not render possible the analysis of the phenomena and the reduction of a problem to its simpler terms.

The study of the survival and growth of living tissues outside the body was commenced by Harrison and has led to important new developments. The ideal material for the cytological study of living structures is supplied by the strains of cells which are easily obtained by the improved techniques of the method of tissue culture. Pure cultures of fibroblasts, blood monocytes, tissue macrophages, sarcoma cells, cartilage cells, pavement and Malpighian epitheliums and thyroid cells live and grow for long periods of time, like microorganisms. It has become possible to observe the morphological characteristics of cells which are in a known metabolic condition. Their secretions can be detected and sometimes measured. The action of cells of a given type on cells of another type is easily ascertained. Each class of cells responds in its own way to the physicochemical conditions of the medium. The measurement of the rate of growth of fibroblasts and epithelium in media containing some of the constituents of the humors has led to the discovery of substances which regulate cell proliferation. Blood serum, through its lipoids and albumins, inhibits growth, while the proteins of embryonic juice, the leucocytic and thyroid secretions and the first products of the hydrolysis of proteins promote cell multiplication. It has become obvious that cell metabolism and morphology depend on the qualitative and quantitative characteristics of the humors. The study of a cell cannot be separated from that of the medium. The number of the possible applications of the new techniques of the method of tissue culture is practically unlimited. Almost every cytological problem can profitably be investigated with its help. However, it has so far been confined to a few laboratories. Most of the workers still cling to the early procedure. Instead of using pure strains of cells living in media of constant composition and of measuring the rate of growth, the secretions or the respiration of the colonies, they content themselves in observing some fragments of embryonic tissue surviving or degenerating for a few days in a drop of plasma, Ringer or Locke Lewis solutions. However, the experiments of Champy and those of Drew have demonstrated that epithelial cells "cultivated" according to the old procedure do not keep their normal characteristics and de-differentiate. It is therefore necessary to give up the defective practices and to learn the difficult techniques which permit the cells to maintain indefinitely their normal structure.

In the study of fresh or living tissue, it is important to determine whether the cells are normal or injured. Modern cytologists do not seem to have been sufficiently impressed by the necessity of ascertaining the condition of the cells which they keep under observation. This neglect has led to a false interpretation of several facts. The method of tissue culture, applied with a defective technique, is responsible for most of the mistakes. Cells must not merely be assumed to be normal. Precise tests have to be applied in order to ascertain this point. On the cinematographic films of cells in pure culture the first symptoms of injury are clearly seen. They consist chiefly of slight irregularities and minute pulsating hernias of the rigid outline of the fibroblasts and epithelial cells, and of a slower motion of the undulating membrane of the monocytes, macrophages and sarcoma cells. An inflection of the parabolic curve which expresses the normal growth of a colony of epithelial or connective tissue indicates also that the structures have ceased to be in a normal condition. In his well-known experiments on injury and recovery of vegetal cells, Osterhout found that the degree of injury can be measured by the variations of the electrical conductivity. Irwin used this method in her experiments on the penetration of dyes in *Nitella* in order to verify whether the cells were normal.

It is also necessary to determine the metabolic condition of the structures whose morphology is being investigated. The production of CO_2 on the absorption of O by a small mass of tissues can be accurately measured. It is well known that Tashiro succeeded in detecting the production of CO_2 by a nerve during the passage of nervous impulse. Other workers have measured the respiration of very small groups of cells. By using the Warburg method, Rhoda Erdman has ascertained the amount of O absorbed by fragments of skin cultivated in various media. However, the knowledge gained with the help of these techniques is not precise enough to fulfill the requirements of cytology. It is obvious that in the experiments of Warburg, the absorption of O by a fragment of tumor, that is, by an heterogeneous mass of cells of different nature and in various conditions of activity, cannot give any information on the metabolism of a specific group. The techniques should be adapted to the measurement of the respiration of pure strains of cells living in a medium of known composition. So far the metabolism of pure cultures of epithelium or connective tissue has been ascertained merely by their rate of growth. It may be hoped that the technical difficulties which have hitherto prevented the measurement of the respiration of colonies of pure strains of cells will soon be overcome.

The study of living tissues has been helped by the development of excellent procedures for the handling of minute structures. The delicate technique created by Barber and considerably improved by Kite and Chambers has rendered possible the dissection of individual cells. With the apparatus of Chambers it is feasible to isolate a cell, to take it up with a pipette, to

incise part of it and to inoculate into its cytoplasm a small amount of fluid. This microsurgery has been applied to the investigation of many problems. Its future field may be vast and important. If, for instance, a chromosome or part of a chromosome could be extirpated from a cell without irreparable injury, great progress would be accomplished in the study of heredity.

No marked improvement has been brought about by modern cytology in the staining of living cells. Neutral red and Janus green are still the more useful dyes. A large field remains open. We may hope that some chemist will take up the study of vital staining in collaboration with a cytologist, as there is a need of new dyes for the discrimination of cytoplasmic structures. Our knowledge of the physicochemical conditions of protoplasm should also be increased. However, considerable progress has already been accomplished. Vlès has developed some new techniques for the determination of the P_H of the cells. By the judicious injection of a number of dyes into the living animal, Rous has demonstrated that the concentration in H ions varies markedly in different tissues. Through his techniques, new and important data have been obtained regarding the constitution of the interstitial fluid or intraorganic medium of Claude Bernard. It is certain that his method can be applied to the investigation of a number of problems concerning cell physiology.

Our knowledge of the constitution of the living protoplasm of animal cells and of the nuclear and cytoplasmic structures is still very scant. The histochemical methods are in their infancy and their results not entirely reliable. This rich and almost virgin field should attract more workers. Some valuable data on the chemical nature of cell constituents can be obtained from the study of absorption spectra or ultraviolet rays, as Gates has done, of the fluorescence of tissues under the influence of the same rays and possibly of the microincineration practised by Policard. However, it is probable that vegetal cells, instead of animal tissues, should be selected as material for the investigation of problems of this character. The experiments of Osterhout on the permeability of protoplasm of the marine alga, *Valonia*, are of far-reaching importance. As a single cell often contains as much as 10 c.c. of sap, it is possible to find out what goes on inside. As long as it remains in normal condition, *Valonia* excludes entirely magnesium and sulphur, and admits only traces of calcium. Potassium is stored in much greater concentration than in sea water. The sap is not a balanced solution. By investigating the penetration of hydrogen sulphide in living cells, Osterhout found that protoplasm is permeable only to undissociated molecules. Under normal conditions, in this plant, ions enter protoplasm very slowly or not at all. Irwin, experimenting with *Nitella* cells immersed in dilute solutions of dyes, showed that the rate of penetration is directly proportional to the concentration of undissociated molecules. It therefore increases as the concentration of ions decreases. There is little or no pene-

tration of dye ions. Injury and death are accompanied by increased permeability to ions. The difference between the living and the dead states is very marked in respect to the semi-permeable surfaces. After death they lose their selective power and the internal and external solutions begin to mingle. Such semi-permeable surfaces are not confined to the exterior of the cell but exist also at the boundaries of nuclei and other structures within the cell. Although our knowledge of the physical phenomena which take place at the cell boundaries is very scant, it cannot be doubted that the properties of these surfaces are of primary importance for metabolism. The results of the experiments of du Noüy on the static surface tension of proteins, and on the surface viscosity or rigidity of solutions in which a monomolecular layer of protein has been allowed to form, have led this author to interesting hypotheses on cell structure. The ratio of the surface to the volume of a cell is such as to permit the production of a monolayer at its boundaries, provided that the concentration of the proteins is of the same order of magnitude as that of serum. A surface covered with oriented molecules would behave quite differently from a surface on which the molecules were distributed at random. The testing of the ingenious hypotheses of du Noüy will inspire new experiments and lead to a better understanding of the constitution of the cell surface.

The best method for recording the phenomena which take place in living cells is cinematography. The use of the cinema in cytology was introduced long ago by Comandon whose admirable work has not as yet been surpassed. In this country, Alessandro Fabbri and Ebeling succeeded in filming the growth of colonies of fibroblasts during long periods of time. Since these early experiments, the techniques have been very much improved, and microcinematography, instead of remaining a mere procedure for recording the motion of the cells and of their organs, has now become a method of investigation. To this method are due the finding of the undulating membrane of the monocytes, macrophages and sarcoma cells, and of the specific mode of locomotion of the lymphocytes and polymorphonuclear leucocytes, and important data on the architecture of the cytoplasm of fibroblasts and epithelial cells. It is certain that these techniques will be applied to the investigation of many other problems such as, for instance, the secretory process of the gland cells and the mode of progression of the axons growing from nerve cells.

The modern conception of cytology and the development of new techniques have profoundly modified the previous requirements for the training of the workers and the organization of the laboratories. Twenty years ago, preparation for the study of cytology demanded merely a thorough knowledge of microscopic anatomy and some notions of physiology, chemistry and physics. The equipment of the laboratory consisted of the few chemicals, glassware and apparatus necessary to the fixation, section,

staining and examination of the specimens. It was generally completed by a warm stage for observing living tissues stained in neutral red, by a camera, and sometimes by a small operating room for animals. To-day, the enlarged scope of the problems requires of the workers a far more complete scientific training. Besides its own technique, cytology utilizes the techniques of chemistry, physical chemistry and physics. Thus, its object is to investigate the chemical constitution of the cell, the physical phenomena which take place at its boundaries, and the physicochemical properties of the substances which are instrumental in its nutrition, differentiation and pathological transformation. The cytologist must know, besides the methods of microscopic anatomy, the various techniques for the examination of fresh and living tissues, the complex procedures of the method of tissue culture of which the apprenticeship takes, at least, one year of continuous work, the microdissection, the methods for measuring cell metabolism and microcinematography. As he cannot master, during one lifetime, these techniques and those of organic chemistry, physics and physical chemistry, he must have the collaboration or the assistance of workers more especially trained in other sciences. The organization of the laboratory has also become more complex. To the simple rooms and equipment sufficient for microscopic anatomy, several other laboratories and the corresponding apparatus must be added for the cultivation of tissues, the physical and chemical studies, and cinematography.

Modern cytology is endowed with new and powerful methods of investigation and is ready for the attack of fundamental problems. A more profound and scientific knowledge of the cell itself and of its relations with the humors of the organism will be the starting point of great progress in physiology and pathology.

Section II

THE SKIN AND ITS DERIVATIVES

CONTENTS

Section II

PAGE

General Considerations 13
1. Mechanical protection 13
2. Chemical and physical properties of surface layer 14
3. Protection against fluids and gases 15
4. Protection against light 15
5. Protection against extremes of heat and cold 16
6. Selective nervous sensibility 16
7. Effect of substances of epidermal origin on internal tissues 17
8. Influence of internal organs on skin 18
9. Allergic reaction 18
I. Epidermis 19
1. Shape of cells 22
2. Physical consistency of cells and nuclei 23
3. Nuclei 24
4. Mitochondria 24
5. Golgi apparatus 25
6. Intracellular fibrils 25
7. Intercellular bridges 26
8. Melanin 27
9. Keratohyalin 32
10. Keratin 33
11. Fatty substances 34
12. Nerve and vascular supply 34
13. Specific inclusions occurring in diseases due to filterable viruses 35
14. Other substances which have been reported 35
II. Cutaneous Glands 36
III. Hair and Nails 37
IV. Bibliography 37

Section II

THE SKIN AND ITS DERIVATIVES*

E. V. COWDRY

THE skin consists essentially of: (1) a layer of connective tissue containing blood vessels, nerves and lymphatics called the "dermis" (corium or cutis vera) and (2) a continuous layer of avascular squamous epithelium superposed upon the dermis, which is known as the "epidermis" (cuticle or scarf skin). These relations are illustrated in Figure 1.

A discussion of the dermis is not included in this section because its chief components, the blood and connective tissue cells, muscular and nerve cells are described in detail elsewhere. The capillaries of the dermis have, however, been so very actively investigated in recent years from many points of view that it seems essential to at least make reference to the following papers: Hare (1926); Lewis (1926); Petersen and Willis (1926); Mumford (1927); and Petersen (1927).†

The epidermis serves as a mechanism of adaptation between the organism and its environment and exhibits many interesting specializations.

1. *Mechanical protection:*

This is principally afforded by cloaking the body in a complete mantle of dead material. It is a true saying that "while we are in life we are in death." A glance at Figure 1 will show how the dead material is formed.

Throughout life the cells in the deepest layer of the epidermis (*stratum germinativum*), near the blood vessels, multiply actively. It is not known whether their divison is rhythmical—in other words, whether there are periods of rest followed by intensive division—but it may very probably be so, because the epidermis, of all tissues, is the most subject to the influence of oscillations in illumination caused by daylight and darkness. This may, indeed, be a potent factor in the development of some kinds of periodicity in the tissues lying more deeply. The cells as they grow are displaced toward the surface and undergo a progressive series of modifications to which the general term of "keratinization" (or cornification) is applied. These changes occur in a surprisingly short distance from the dermis; because, in conse-

* Owing to the fact that the contributor, who was qualified to write on this subject, found himself unable to do so the Editor has been obliged at the last moment to care for it himself.

† Here and in other parts of this section, preference is given to the most recent papers as being more useful since they generally give in addition to the newest advances data concerning the older literature. The space available does not permit complete citations with special attention to priority.

quence of the avascularity of the epidermis, the cells soon die through reduction in blood supply.

The alterations are chemical in nature and find expression in definite structural changes. As one passes from the actively multiplying cells in the *stratum germinativum* to the specialized cells in the *stratum granulosum* and the dying and dead cells of the *stratum lucidum* and *stratum corneum*, there is a gradual diminution in the water content. Associated with this one finds many modifications, several of which will be mentioned again. The chief among them may here simply be enumerated:

1. A decrease in metabolic activity.
2. A decrease in mitochondria and Golgi apparatus both of which are completely lost in the most superficial dead cells.
3. A diminution in intensity and similar progressive loss of the sulphydryl reaction, which Walker (1925) believes to indicate the presence of a substance similar to or identical with the thermostabile sulphydryl constituent of muscle.
4. A decrease in melanin content (p. 27).
5. An increase in certain substances like keratohyalin (p. 32), and keratin (p. 33).
6. Architectural modifications, such as changes in shape: the development of fibrillae and of intercellular bridges, all of which enable the cells to adhere firmly together and to withstand pressure.

The oldest cells in the superficial layer are gradually lost through desquamation. In this way the general body surface is covered by a layer of resistant material which is continually replenished from within. The thickness of this composite coating depends upon local conditions (0.02 to about 1 mm.). It is very thick on the soles of the feet as compared, for example, with the lips. The attacks of pathogenic bacteria and protozoa are thus warded off unless there exists an aperture produced by traumatism. The filterable viruses of small-pox, chicken-pox and other diseases of the same category, which are perhaps the most minute of living things, have the property of attacking chiefly young cells (Rivers, 1927) and these are found in the layers remote from the surface.

The epidermis provides additional mechanical protection through the development of hair (p. 37) and nails (p. 37). The dentine of the teeth is one of its derivatives. The horns of ruminants, the heavy dermal plates of reptiles and the scales of fishes are built up through a differentiation of both epidermis and dermis.

2. *Chemical and physical properties of the surface layer:*

These have been exhaustively investigated. The hydrogen ion concentration has been studied in particular by Sharlit and Scheer (1923), Sharlit and Highman (1923) and Memmesheimer (1924). According to the first named authors it is about 5.5; that is to say a little on the acid side of neutral. The reacton of the constituent cells of the epidermis will be mentioned

later (p. 23). Rous (1926) gives an account of the changes in the reaction of skin-grafts and electrical phenomena are considered by David (1922), Rein (1924), Regelsberger (1924) and Aveling and McDowell (1925). The consistancy of the surface is also cared for. It is not allowed to grow dry and brittle. In health it is continually coated by small quantities of a fatty substance (sebum) produced by the sebaceous glands which renders it smooth, flexible and relatively impermeable, while the sweat glands discharge on the surface variable amounts of a very dilute saline fluid.

Other secretions of wide variety are elaborated by the skin glands of lower animals. In fishes the surface is often supplied with protective mucoid materials. The dermal poison glands of some toads function as organs of defense. Their secretion is even capable of causing blindness in an adversary. The discouraging effect of the secretions produced by skunks is well known.

3. *Protection against fluids and gases:*

The penetration of fluids and gases is probably retarded by keratinization and by the spreading of the fatty film over the surface of the epidermis, but this is not all. It is perhaps by the living cells in the deeper layers that most protection is given. We find that many chemical substances in solution are prevented from passing through the skin while these deeper layers are still alive which pass freely when the entire epidermis is dead. Boric acid is one of the few solutions which pass through the living intact skin with considerable freedom (Kahlenberg, 1924).

As an organ of respiration and excretion the skin of the frog is effective, and in the absence of its normal function, life is impossible. In man, some oxygen is taken up and carbon dioxide given off but this kind of activity is much reduced. A considerable amount of nitrogenous material is excreted in the sweat (Talbert, Silvers and Johnson, 1927).

Comparatively little is known of the penetration of gases foreign to the organism, although this is very important from the points of view of industry and of war. Walton and Witherspoon (1925) have, however, shown that hydrocyanic acid gas and hydrogen sulphide gas are absorbed by the skin of dogs and guinea pigs, while carbon monoxide is apparently excluded.

4. *Protection against light:*

Another protective mechanism, due apparently to the living components alone, is that of the formation of melanin pigment (p. 27) by which the rays of light when unduly strong are absorbed; for it is known that the epithelial cells are extraordinarily sensitive to light stimuli. This is shown by Holmes' (1914) work with tissue cultures. Melanin deposition is seen in sunburned people and in the colored races. The pigment is found both in the epidermis and in the underlying dermis (Strong, 1927). We shall return to this mode of protection later (p. 30).

5. Protection against extremes of heat and cold:

The barrier afforded by this comparatively thin layer composed of both living and dead cells is by itself but poor protection against extremes in temperature. Hairs, in addition to being protective in a mechanical sense, when sufficiently abundant, aid materially in the retention of body temperature. These structures, owing to their rich nerve supply, may also be regarded as sense organs (see below) and thus afford a striking example of epidermal derivatives which may serve three functions. Perspiration results in a cooling of the body. Temperature regulation is also brought about by changes in the blood vessels, but this is not a property of the epidermis. Much work on the temperature of the skin has been done by Benedict (1925) and his coworkers.

6. Selective nervous sensibility:

These adaptive features—and attention might be called to many more tending to keep the organism apart and to some extent insulated from its environment—are but one side of the picture. If carried too far this isolation would obviously be inhibitive of physiological activity. We find, indeed, a whole train of differentiations which tend to bring the organism in very close relation to its environment.

The skin is highly selective. Provision is made for the reception of certain kinds of impressions from the outside world so that adequate responses may be made. The "exteroceptors," as they are termed by Sherrington, receive impressions of temperature, pressure and pain and are thus much more discriminative than the interoceptors and proprioceptors (p. 992) by which internal integration is effected. Thus we find that, when the surface of the brain itself is exposed, it is insensitive to touch, although it acts as an "adjustor" for impressions of this kind received from the periphery. The receptors consist "essentially of specialized protoplasm which is highly sensitive to some particular form of energy manifestation, but relatively insensible to other forms of stimulation" (Herrick, 1924). They are sometimes arbitrarily divided into "contact receptors" and "distance receptors." The former occur as delicate nerve terminals or end-bulbs in contact with the epithelial cells; or as the elaborate corpuscles of Ruffini, Krause, Pacini, and others, situated in the underlying dermis. The "distance receptors" serve to orient the organism in reference to remote objects although stimulation is brought about by the contact of substances (olfactory) or the receipt of vibrations (auditory and optic).

Definite sense organs chiefly or wholly of ectodermal origin are constructed. "Each sense organ possesses, in addition, certain accessory parts, adapted to concentrate the stimuli upon the essential sensitive protoplasm to intensify the force of the stimulus, or to transform the energy of the

stimulus so as to enable it to act more effectively upon the essential end-organ" (Herrick). The cornea and lens of the eye are ectodermal derivations designed for the reception of light rays in a fluid medium and for their concentration upon the sensitive cells of the retina (Section XXV).[1] The fluid is supplied by two skin glands, the lachrymal and Harderian. It serves also to reduce to a minimum the friction of moving surfaces and to wash away foreign particles which so frequently lodge on this exposed part of the integument.

7. Effect of substances of epidermal origin on the internal tissues:

Not only does the skin influence the body as a whole by bringing it into close touch with the outside world through the medium of the nervous system but also by the local manufacture of chemical substances which enter the circulation. Here again it is the living element which is active. Just what the epithelial cells do when the skin is exposed to bright sunlight we do not know. After a definite time interval the area as a whole becomes hyperemic, its temperature rises, there is some splitting of its proteins, absorption is increased, melanin may be deposited and many other things may happen. It is clear, however, that changes occur which if sufficiently intense effect the whole organism by the transport of materials from the epidermis.

Several enzymes have been found in the skin among which carboxylase (Nakamura, 1926), diastase and phenolase (Melczer, 1926), phosphatase and sulfatase (Nakamura, 1926) may be mentioned. Under certain conditions these similarly gain the circulation.

Immune bodies are probably produced in these living epithelial cells in skin diseases caused by filterable viruses and very likely in other conditions also. These materials are likewise poured into the blood stream. Our knowledge of immune body formation by the optic lens is rapidly advancing (Hektoen, 1923 and others).

It is by no means certain that the cells of the epidermis do not under normal conditions manufacture so-called internal secretions. Without doubt

[1] Since the cornea and lens are not considered with the retina some leading references may be submitted here:

A. *Cornea:* Development (Seefelder, 1925), diffusion through (Goldschmidt, 1920), edema (Aubineau, 1922), fatty changes (Rohrschneider, 1924), fibrils (Laguesse, 1923), Golgi apparatus (Deineka, 1912), herpetic changes (Cowdry and Nicholson, 1923), hyaline change (Gifford, 1924), mitochondrial changes in vaccinia (Cowdry, 1922), regeneration (Hoffman, 1919), siderosis (Kranz, 1926), vitamine deficiency (Yudkin and Lambert, 1923).

B. *Lens:* Critical review (Werber, 1918), embryonic rests (Lent and Lyon, 1922), immune body production (Hektoen, 1923), lipoids (Goldschmidt, 1922), opacities (Weil, 1922), physiological rests (Vogt, 1919), regeneration (Alberti, 1922; Uhlenhuth, 1919), ultraviolet light (Jess and Koschella, 1923).

the mammary gland, which is derived from the epidermis and is in fact a modified sebaceous gland still pouring its principal product onto the surface, manufactures a substance giving a galactogogue effect, while its own activity is controlled to some extent by hormones from the uterus and corpus luteum (Schafer, 1926). Several other examples of the physiological action of epidermal products might be cited.

8. *Influence of the internal organs on the skin:*

We have mentioned, briefly, the means whereby, the surface is brought into accord with the internal parts. The reverse also holds: the epidermis is influenced by the condition of the interior in two principal ways. First, through efferent impulses from the nervous system to the peripheral blood vessels and cutaneous glands, and especially in certain lower animals, to the hairs and epidermal pigment cells. In man even the emotions exercise a marked effect on the skin (Hazen and Whitmore, 1925). Second, by the passage *via* the blood stream of endocrine products for the most part from the pituitary, thyroid and suprarenal glands (see Pottenger, 1926; Levy-Franckel and Juster, 1926).

9. *The allergic reaction:*

According to Kolmer (1925) "It is highly probable that the skin plays a more important rôle in the mechanism of recovery from disease of the internal organs than is commonly supposed." The skin "has become sensitized during the course of many diseases, some of which are not cutaneous diseases or characterized by any special cutaneous manifestations."A good illustration is that given by the tuberculin reaction. In other words the skin becomes allergic: it exhibits an exaggerated response to small amounts of substances which are harmless to the majority of individuals. That such reactivity is adaptive is shown by the fact that it often appears only after the first few years of life. This is one of the best examples of how the condition of the skin is influenced by the organism as a whole. Knowledge of the protein sensitivity of the skin permits the avoidance of substances toxic for the internal organs.

Some surfaces within the body are, in like manner, opposed to harmful influences of environmental origin and exhibit equally remarkable functional adaptations. The superficial ectoderm extends into the nasal fossae (Section III) and comes in contact with the endoderm of the respiratory system (Section IV). In the latter situation protection against extremes of temperature and the more radical forms of mechanical injury is no longer required. The epidermal layer is also projected into the mouth and anus. In the alimentary system the contact with the environment is a fluid one and the adaptive modifications in structure are wholly different and must be of a kind to allow ready absorption (Sections V, VI). Keratinization does, however, take place in the esophagus where the danger of traumatism from foreign substances is greatest, and where through the march of "civilization," the epithelium is subject to an alternation of ice cold and

scalding hot fluids. Here, and in other situations, a lubricant and protective mucus is produced, and in the intestine cilia are differentiated. The superficial layer of ectoderm is also invaginated for a short distance into the lumen of the urinogenital tract. The apertures through which these internal surfaces open on the exterior are usually guarded by special sphincters, by the flow of fluid toward the outside or by ciliary action in the same direction.

Obviously the skin, as one of the most interesting and important tissues of the body, is now gradually attaining its rightful place. It has been the custom in the past, especially in textbooks of biology, to ignore it altogether, or at best to set it aside with a few words only. In textbooks of histology and cytology a brief discussion of the skin is found somewhere in the middle or at the end of the book, seldom, if ever, in the logical position at the beginning. In the dissecting room, until recently, the first duty of the student was to get rid of it. The skin has been left almost entirely to specialists in dermatology among whom the Germans alone have shouldered their responsibility. Consequently, most of the literature is German and inaccessible to the majority of our students and medical men. Several factors seem to have promoted this change in outlook. Among them we must reckon advances in physiology and immunology; and particularly, in medicine, the experimental study of certain filterable viruses and of the allergic reaction.

We now pass to a description of the cytology of the epidermis, cutaneous glands, hair and nails. For a more exhaustive account of the skin, including the dermis, than it is possible here to give, reference should be made to Pinkus (1927) and for technique to Krause (1926). Those interested in the comparative physiology of the epidermis should consult Biedermann (1926).

I. THE EPIDERMIS

Four layers of cells are usually present in man (Fig. 1) and the following designations have been assigned to them by the Basle Nomenclature Association (B.N.A.) which must be considered as official:

The innermost layer is called *stratum germinativum* presumably because the cells in it are "germinal" in the sense that through multiplication they give rise to the others. This stratum is, of necessity, always present. When, after deep injury, it is destroyed, regeneration of the epidermis is no longer possible and the process of skin-grafting must be resorted to. The cells are often pigmented (p. 27) and possess well developed mitochondria, Golgi apparatus and protoplasmic bridges (p. 26). Synonyms: Malpighian layer, Rete Malpighi, Basement layer, Rete mucosum, sometimes divided into "basal layer of columnar cells" and "layer of prickle cells" (layer of polyhedral cells or "stachelschicht").

Then follows a thinner layer, the *stratum granulosum*. The cells in it may be recognized by their highly granular appearance owing to the presence of a substance termed by Waldeyer "keratohyalin" which has a high refractive index and is colored intensely by both basic and acid dyes (p. 32). When the epidermis is very thin this stratum is often unrecognizable. Synonym: Keratohyalin layer.

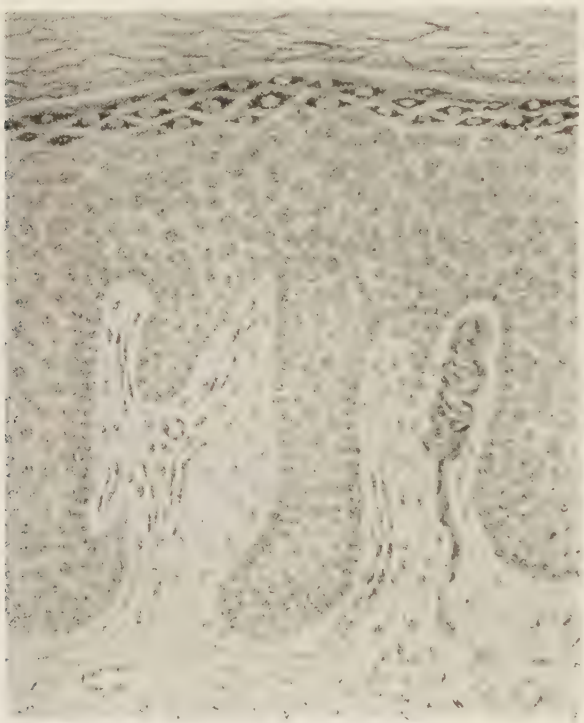

FIG. 1.—Skin on the palmar surface of the finger. In the lower part is seen the dermis (d.) with its papillae projecting upward into the epidermis. One of these contains a tactile corpuscle. In the epidermis four strata are recognizable: *germinativum* (s.g.), *granulsoum* (s.gr.), *lucidum* (s.l.), and *corneum* (s.c.). (After Schafer, 1912.)

The *stratum lucidum*, which is still nearer the surface, exhibits a clear transparent appearance. The cells contain large fluid masses of a substance for which Ranvier proposed the name "eleidin" (p. 32). Like the granules of keratohyalin this is intensely colored by carmine (see Fig. 2). The cell walls contain some keratin. Frequently the *stratum lucidum* is not sharply demarked from the *stratum corneum*. Synonyms: Ochl's layer, Unna's basal corneous layer, Ranvier's *stratum intermedium*, Schmidt's optically neutral zone.

In the fourth and outermost layer, which is known as the *stratum corneum*, keratinization is pushed to an extreme and the cells are dead and horny. The cells contain, in addition to keratin, a fatty substance which reduces osmic acid (paraeleidin, p. 34). To the most superficial cells, which are said to stain diffusely with osmic acid, the term *stratum disjunctum* has been applied by Ranvier. Synonym: horny layer.

The innermost two layers, comprising the living and vital portion, are often grouped together and called the *stratum malpighi*. This *stratum malpighi* may be readily separated from the tissue covering it by maceration.

The outermost two strata are sometimes considered together under the single term of *stratum corneum*. They constitute the dead or dying components of the epidermis already referred to. There exists, however, a sharp distinction between them because the *stratum corneum* is doubly refractile, when viewed with crossed Nicols, whereas the *stratum lucidum* is not (Schmidt, 1921, and earlier workers). According to Pinkus (1910) "the corneus layer" comprises also the *stratum granulosum*.

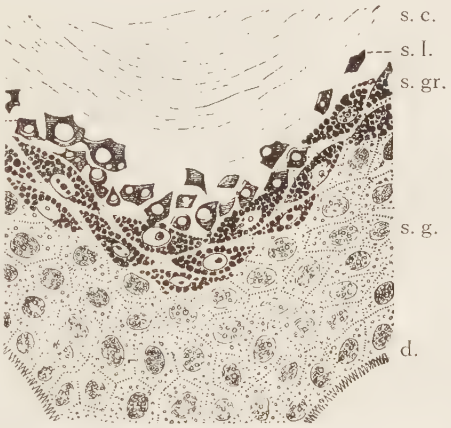

FIG. 2.—Epidermis of the finger stained with picrocarmine. Below, the denticulations (d.) of the basal cells of the *stratum germinativum* (s.g.) are represented. The cells of the *stratum granulosum* (s.gr.) contain many eleidin droplets which have become confluent in the *stratum lucidum* (s.l.). The *stratum corneum* (s.c.) is keratinized. (After Schafer, 1912.)

The exact relation of the epidermis, composed of the above mentioned layers, to the dermis is a matter of considerable importance. Whether or not the deepest layer, or *stratum germinativum*, is separated from the underlying dermis by a basement membrane has been much discussed (Frieboes, 1920, 1922; Born, 1921; Busacca, 1922; and Hoepke, 1924). The proximal ends of the epidermal cells are firmly wedged together and are, frequently provided with a peculiar series of "denticulations" through which they come into very intimate contact with the vascularized connective tissue beneath. These teeth-like processes are illustrated in Figure 3. The epidermis is thrown into a series of ridges through the projection upward into it of the dermis. These ridges are visible on the surface and are, once they have been developed, like the apertures of the ducts of the cutaneous glands, of very constant position throughout life as revealed by experts in finger printing. An account of their formation is supplied by Cummins (1926).

1. *Shape of the cells:*

In shape the cells vary considerably. The innermost ones of the *stratum germinativum* tend to be columnar and to be arranged in a single layer with their long axes perpendicular to the surface of the dermis. As one passes toward the *stratum granulosum* the cells become first somewhat more rounded, or polyhedral, and then flattened in a direction parallel to the surface. Coincidently there is a development of intercellular bridges (p. 26)

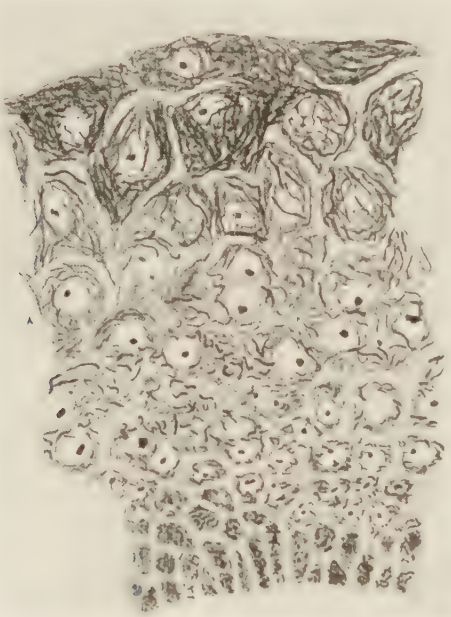

Fig. 3.—Section of the beak of a chick embryo of 13 days. The mitochondria are visible in the deeper cells, and the epidermal fibrils in the more superficial ones. (After Firket, 1911.)

which on fixation result in a jagged border. For this reason all the cells in the *stratum germinativum* with the exception of the basal columnar cells are known as "prickle" or "spinous" cells. The distinction between the two types is quite marked. Each may undergo neoplastic change giving rise, as the case may be, to a "basal celled" epithelioma or to a "prickle celled" or "spinocellular" epithelioma.

In the *stratum granulosum* the cells are further flattened, and, in the *stratum lucidum*, their boundaries are ill-defined. They then become much enlarged in the deeper layers of the *stratum corneum*, and finally, near the surface of this layer, they are transformed into hard, dry, flattened scales which desquamate.

2. *Physical consistency of the cells and nuclei:*

The cells in the deeper layers are rich in water and gradually undergo a dehydration with the formation of keratohyalin, keratin and other substances as the surface is approached. This is to some extent paralleled by a change in hydrogen-ion concentration. As the cells die they become more acid—a phenomenon met with also in other tissues. According to Pinkus (1927), Schmidtmann (1925) found the basal cells to be more acid (6.8–6.9) than those covering them (7.3–7.5) and the corneal layer to be strongly acid (6.2). It is, however, to the microdissection studies of Chambers and Renyi (1925) that we owe our chief information from direct observation as to the physical state of the cells.

The cytoplasm of the cells of the deeper layers "is a translucent nonadhesive, rather tough jelly and is optically structureless except for a few conspicuous granules which occur in clumps irregularly scattered throughout the cell. By dark ground illumination the cytoplasm is optically structureless except for these brilliantly illuminated granules. Tearing the cytoplasm with needles offers no evidence of the existence of intracellular fibrils so frequently observed in fixed material. On the contrary, the entire cell substance reacts to the needles as a tough jelly with no variations in consistency except in the immediate neighborhood of the nucleus, where it is less solid than elsewhere."

"The cell nucleus is a translucent, oval body, rather firmly embedded in the highly gelatinous cytoplasm. With a needle it was found possible to displace the nucleus slightly. When released, it moves back to its original position. When the cell is stretched, the nucleus tends to become elongated in the direction of the pull. When released from the pull, the nucleus returns to its original shape. The fluid state of the nucleus is indicated by the fact that the pressure of the needle produces an indentation which quickly disappears when the needle is removed." The nucleus is irrepairably injured by puncture and rapidly sets into a jelly with a coarse reticular structure. The nucleus, in this condition, can be torn out of the cell and will persist as a discrete body for a long time. This readiness of the nucleus to set into a jelly is probably the explanation for the frequent occurrence of naked nuclei in teased fresh preparations of almost any histological tissue."

The cells are held firmly together by the intercellular bridges. When the cells are torn apart the bridges lengthen and finally break in the middle. If a cell is injured, resulting in nuclear coagulation, after an interval of 20 seconds the contiguous cells exhibit the same lesion which agrees with "the view that the bridges are organic continuations of the cytoplasm between neighboring cells."

In the *stratum lucidum* the cells "are much firmer in consistency than those of the deeper layers of the epidermis. They are quite rigid and, when

torn apart, do not pull out, but break apart as complete cells with sharp, angular edges which persist after the cells have been separated. The cells are translucent with no evidence of granules in the cytoplasm. The nuclei are almost imperceptible except when they have been coagulated by injury. There is no evidence of any intercellular cement, and the cells, when once separated by the breaking of their protoplasmic bridges, float freely apart." Unfortunately Chambers and Renyi do not make specific reference to conditions in the *stratum corneum*.

3. *The nuclei:*

The nuclei present no very special structural peculiarities. In the basal cells normal multiplication takes place through karyokinetic division—a process which is generally suppressed in the prickle cells. In neoplasms nuclear multiplication is irregular often giving rise to giant nuclei and with figures suggestive of amitosis. Amitotic division is described under normal conditions by Ludford (1924*b*) and reference should be made to the same investigator for the little that we know regarding changes in the nucleo-cytoplasmic ratio during the cytomorphosis of epidermal cells. It is said that the nuclei are intimately concerned in pigment formation (p. 32). In certain diseases due to filterable viruses they develop remarkable inclusion bodies to be described in a later paragraph (p. 35).

4. *The Mitochondria (Chondriosomes, Chondriomites, Chondrioconts, Plastosomes, Plastochondria, and in part, Altmann's granules, Fuchsinophile granules, etc.):*

The word "mitochondria" is derived from the Greek μίτος, a thread, and χόγδρος, a grain, and is intended to indicate that the shape of the bodies thus designated is thread-like or granular. They are of about the same size as small bacteria which they resemble superficially. They are very widely distributed in protoplasm and hence are often referred to in other parts of this book. They are delicate indicators of certain types of injury and very unresponsive to others ("General Cytology," p. 327).

Whether the granules mentioned by Chambers and Renyi, as the only optically visible structures in the epidermal cells, are mitochondria is doubtful, most probably not; because the mitochondria in this situation are often rodlike, even filamentous and are definitely arranged. Granules of keratohyalin and of melanin, when present are beyond question optically visible, likewise the fat and glycogen and the "neutral red" granules, which latter may have been the granules seen by these authors. It is important to bear in mind that methods of dark-field examination only reveal marked surfaces of separation between fluids of different optical properties as well as pronounced colors, and that but few indications are thereby obtained of

microchemical differences of, for example, materials rich and poor in chromidial substance. Ultraviolet photography might be helpful.

The mitochondria may be easily detected in living cells of the *stratum germinativum* both unstained and with the aid of the supravital dye, Janus green. Ludford (1924*b*) has emphasized the fact that the cells of the innermost layer are polarized in respect to their mitochondria which are heaped up in the proximal cytoplasm next the dermis. The mitochondria become scattered, diminished in number and finally lost as one approaches the dead cells of the superficial layers. They are said to give rise to the epidermal fibrils (p. 25), to the nodes of Bizzozero (p. 26), and to contribute to the formation of keratohyalin (p. 32) and melanin (p. 27).

Mitochondria have been investigated in the epidermis in many types of pathological change. In carcinomata the above mentioned polar distribution is lost (Ludford, 1924*b*). The additional literature may be summarized:

Edema (Regaud and Favre, 1912), epidermal tumors (Favre and Regaud, 1910, 1913; Wakelin Barrat, 1912), fowl-pox (Findlay and Ludford, 1926), syphilitic chancre (Regaud and Favre, 1912), vaccinia lesions (Cowdry, 1922).

5. Golgi apparatus (Binnennetz, Reticular material, Säftkanalchen?, Trophospongium?, Canalicular apparatus, Intracellular network, etc.):

This term is applied to a peculiar network, about the size of the nucleus, which cannot be seen in the living cell, but which is revealed (or produced) by impregnation with silver or by prolonged treatment with osmic acid. It was discovered by the neurologist, Golgi. Unhappily very little is known of its chemical constitution, but it is supposed by some to be lipoidal. For the literature see "General Cytology," p. 377.

From the researches of Deineka (1912), Tello (1923) and Ludford (1924*b*), it is clear that this cytoplasmic component presents rather parallel changes in the epidermis to those exhibited by the mitochondria. In the deeper cells it occupies a position in the distal cytoplasm. As the cells grow older and are displaced toward the surface it loses this position, fragments and finally disappears. Like the mitochondria also, in tumors, its polar distribution is suppressed (Ludford, 1924*b*).

The Golgi apparatus has been described in the epidermis in a variety of pathological conditions:

Fowl-pox (Findlay and Ludford, 1926), tumors (Da Fano, 1921; Tello, 1923*a*; Ludford, 1924*b*).

6. Intracellular fibrils (Epidermal fibrils, Fibrils of Herxheimer, Basal filaments, Tonofibrils):

For years our ideas relative to the intracellular fibrils of epidermal cells have been much confused. This is due largely to failure in recognizing how

very different the cells of this layer may be in different forms. In the human skin they are very easily stained. There is nothing elusive about them as with the neurofibrils (p. 971). Their general appearance is illustrated in Figure 4 and in tumors they are definitely increased in number (Fig. 5). It has been suggested that they develop from mitochondria (Favre and Regaud, 1910, and Regaud and Favre, 1912). A similar origin is claimed for the epidermal fibrils in chicks (Firket, 1911), and tadpoles (Duesberg, 1912); see however "General Cytology," p. 323. It is known that the tonofibrils in reptilia are doubly refractile (Schmidt, 1921). Saguchi (1913) has investi-

FIG. 4.—Cells of the *stratum germinativum* showing intraprotoplasmic plexus of fibrils (A), and the appearance of spines (B) when the cell is viewed from the surface. (After Rio Hortega, 1917.)

gated in detail the filamentous bodies of Eberth in amphibia, but their degree of resemblance to the human fibrils remains problematical. Kollman and Papin (1914) have expressed the opinion that the fibrils on disintegration give rise to keratohyalin (p. 32).

-. *Intercellular bridges ("Rippel" of Schultze, Filaments d'union of Ranvier, Ereidesms of Shapiro, Exoplasmic fibers, etc.):*

Perhaps the best description of their morphology is given by Rio Hortega (1917). Figure 6 has been copied from Saguchi (1913). Small swellings, the nodes of Bizzozero, are to be seen in the bridges midway between adjacent cells. These, Favre (1924) claims to be of mitochondrial origin. Their

function in holding the cells together has been intimated and the possibility that they also serve to transmit stimuli from one cell to another. Pinkus (1927) is inclined to believe that these bridges differ from the epithelial fibers which course throughout the epidermis following the lines of mechani-

FIG. 5.—Alterations in the epidermal fibrils in an epithelioma. (After Rio Hortega, 1917.)

cal stress. The arrangement of these fibers has been worked out by Schridde (1905), Shapiro (1923) and others.

8. *Melanin:*

The individual granules of this pigment possess a yellowish-brown color. When they are grouped in dense masses this becomes almost black. The

resultant color is also influenced by other factors, such as the pigmentation and vascularity of the dermis, so that grays and even grayish-blue tints may appear, as Strong (1927) has described. Even in blond persons granules of melanin are often found in small amounts in the most basal cells of the *stratum germinativum*. This is represented in Figure 7. In mulattoes and negroes the amount of melanin is greatly increased (see Jordan, 1911).

A second kind of pigment, a lipochrome, may occur in addition to melanin in the hair, where it is responsible for the characteristic red coloration often met with. Somewhat similar pigments have been reported in the skin from time to time and the possibility of their presence should always be kept in mind. Very little is, however, known of their formation and constitution in this location. Most workers believe that yellow coloration of the epidermis is due simply to a spreading of the melanin pigment which

FIG. 6.—Basal cells of a 4.5 cm. long Rhacophorus larva showing well-formed fibrils. (After Saguchi, 1913.)

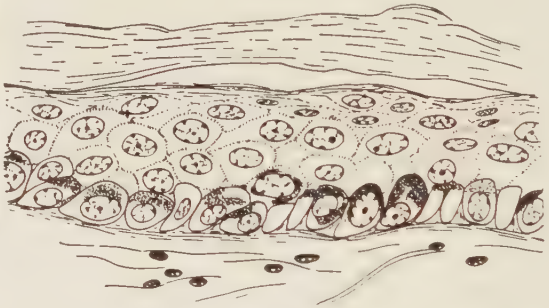

FIG. 7.—Epidermis of a blond person in which the melanin is restricted to the basal cells where it is heaped up between the nucleus and the surface. (After Jordan, 1911.)

when packed tightly together appears black—a phenomenon beautifully seen in Cephalopods. This second pigment is called by Davenport (1913) the "xanthin element." It is totally different from the yellow carotinoid pigmentation resulting from certain kinds of vegetarian diet. This is limited to the *stratum corneum* owing to the presence in this layer of fatty substances in which the pigments are soluble (Hashimoto, 1922).

A good summary of the chemistry of melanin and of its occurrence in pathological conditions is given by Wells (1925). The extensive work of Bloch (1927) and the papers of Lorberbaum and Unna (1925) and of Menschel (1925) should also be consulted for details.

There are many melanic pigments in the epidermis of different races which differ slightly in composition. According to Gortner (1911) there are two principal types of melanin: first a "melanoprotein" existing in the keratins and soluble in dilute acids and second, granules of pigment insoluble in these solvents. To what these differences in composition are due is uncertain. The cells are highly specific in their constitution and physiologic

activities, and the solar rays themselves are, to some extent, modified by altitude, humidity, and other factors (they are altered for marine forms by passing through water), so that there is some variation both in the cells and the kind of protection required. Nevertheless the melanins occurring in man and throughout the phylogenetic series form a rather closely homogeneous group. Like the keratins (described on page 33), they are highly insoluble proteins rich in sulphur.

It seems clear, through the labor of many investigators, that melanin is formed within the epidermal cells and is not taken in by them after its elaboration in the deeper tissues. In support of this contention reference is often made to the fact that these epidermal cells will not take up either melanin or vital dyes injected subcutaneously. A discussion of the vital staining of the human skin is supplied by Poehlmann (1924). Fürth "urges strongly the view that both normal and pathological melanin formation depend upon the action of the tyrosinase or allied enzymes in conjunction with autolytic enzymes . . . ." The autolytic enzymes split the chromogen groups from the protein molecule "which are then oxidized by the tyrosinase, undergo condensations and take up sulfur—and iron-holding groups and also other organic compounds, the entire complex forming the malanin" (Wells). The most likely chromogens—or to be more specific melanogens—are tyrosin, brenzcatechin derivatives, tryptophan and pyrrol derivatives. The relation between skin pigmentation and blood tyrosin is considered by Steiger-Hazal (1926). Against ferment action we have the observations of Lemmel and Lignac (quoted from Wells) that pigment formation may be initiated in boiled skin. A critique of their conclusions is given by Bloch (1927).

From the standpoint of genetics the attribute of melanin deposition seems to be a dominant character. But all "whites" are apparently not recessive. According to Gortner (1910) "dominant whites are due to the presence of an antioxydase which prevents pigment formation: recessive whites, on the other hand have neither power to form pigment or to inhibit the formation." Much further work is needed in this connection.

A white skin may conceivably be caused by: (1) such an antioxydase. (2) The absence of sufficient chromogen due perhaps to lessened activity of the autolytic enzymes, or of other agents producing localized protein decomposition. (3) Absence of sufficient enzyme (tyrosinase, dopaoxydase, etc.). (4) A change of conditions, which, instead of facilitating the reaction, tends to retard or inhibit it, such as absence of ultraviolet light. (5) The reaction, becoming so intense that further oxidation gives a colorless compound. This is merely hypothetical. It is curious how little attention has been paid to the process of removal of melanin. For a protein which is so insoluble it disappears remarkably quickly. It is true that this may be accomplished through the steady migration of pigmented cells to the

periphery and their removal by desquamation. We have very little idea as to how long this would take, because the duration of life of the epidermal cells is not known even so imperfectly as that of the erythrocytes. It is hastened after sunburn, which results in a pealing of the skin and often lays bare layers of cells which are red but less colored by melanin. In this feature, it is adaptive preparing the epidermis for the absorption of more ultraviolet light. But normal removal of melanin does not take place in this way for the reason that only rarely are the superficial cells pigmented. Some intracellular mechanism must also be operative, which sometimes acts very rapidly, as in the whitening of hairs.

Conversely, increased melanin production will presumably be brought about when: (1) An antioxydase of this description is removed. (2) There is an unusual abundance of chromogen. This may result from heightened activity of the autolytic enzymes initiated by various kinds of injury including ultraviolet rays, leading to increased local production of chromogen; or from a superabundance of chromogen arriving *via* the blood stream. The latter occurs when the amount of tyrosin and tryptophan in the diet is increased, because Hartwell (1923) has shown that this treatment causes a darkening in the coats of rats; probably also in Addision's disease. (3) The oxidizing enzyme is unusually widespread. (4) There is a release of some inhibiting process which normally causes the oxidation to be arrested when a certain stage is reached. Some mechanism of this description may operate in the case of melanotic tumors, during the growth of which the amount of melanogen in the blood is not known to be excessive and pigmentation is not increased elsewhere.

The melanin is formed in the epidermis in two chief places. First, in the most basal cells as illustrated in Figure 8. These are nearest the blood vessels, and are, as compared with the more superficial ones, rich in water, mitochondria, Golgi apparatus, the thermostabile sulfhydryl constituent (see p. 14), as well as in other materials. Rather convincing evidence is advanced that there exists a melanin antecedent or leucomelanin, also in the form of granules, just as the leucoplastids precede colored plastids in plants. These antecedents are said to be capable of oxidizing dioxyphenylalanin (Bloch and Ryhiner, 1917)—a test known as the "Dopareaction" (Bloch, 1927). Many investigators are of the opinion that such antecedents, not as yet colored, may be revealed in the human epidermis by methods of impregnation with silver and gold salts and by certain staining reactions.

In this situation the melanin granules tend to be clumped in the distal cytoplasm, between the nuclei and the outside world. Ludford has discovered a somewhat similar orientation of melanin in the epidermis of the horse and remarks upon the protection thus afforded to the nuclei against the harmful effects of strong sunlight—a view which is supported by Young's (1914) observation that melanin extracted from the epidermis absorbs

ultraviolet rays. Either the melanin granules have been formed in this portion of the cytoplasm, or have assumed this position after their development. A physiological migration of pigment granules occurs in the human retina (p. 909) and in the skin of fishes, but it has not been reported as yet in the human epidermis. Neither is there any nervous control of the cells containing pigment, at all similar to that which exists in lower forms like the octopus and the squid, notwithstanding the fact that the cells in man

FIG. 8.

FIG. 9.

FIG. 8.—Epidermis of the mouse illustrating breaking up and budding of the nucleolus (n.) and the subsequent extrusion of nucleolar material (n.m.) into the cytoplasm. The granules of keratohyalin (k.) and the intercellular bridges (i.b.) are also represented. (After Ludford, 1924.)

FIG. 9.—The same process much accentuated in the hypertrophied epidermis adjacent to a rat tumor. The extruded nucleolar material is swollen as a result of imbibition. Masses of keratin (k.) are visible. (After Ludford, 1924.)

may have a rich nerve supply. Cellular polarity may exercise a determining influence in the orientation of the granules of pigment. The basal cells represented in Figure 7 are definitely polarized. Mention has been made of the concentration of mitochondria in the proximal cytoplasm and of the Golgi apparatus in the distal cytoplasm. The centrosomes are probably placed with the Golgi apparatus. But in the case of the horse the same orientation is evidenced in older cells nearer the surface, which have to some extent lost this polarity. If the formation of melanin is at all comparable to the elaboration of zymogen granules in gland cells they appear in

just that part of the cytoplasm which one would expect, and like the zymogen, may spread throughout the cytoplasm when the cell is fully charged.

When the chromogen is developed within the epidermal cells, the material presumably forming it has been most recently studied cytologically by Ludford (1924*a*). He believes that both the mitochondria and the nucleus function in this way. The rôle of the former has been discussed in some detail by Turchini (1922), and there is no doubt but that the mitochondria themselves often assume the most brilliant and varied colors in a few invertebrates and many plants. Ludford has found, in some cases, granules of melanin within the nuclei.

The second and more elusive site of melanin formation in the epidermis is in the structures called variously "Langerhans cells," "dendrite cells," "melanoblasts," "stellate cells" and "chromatophores." These occur within the *stratum germinativum* and extend finely branched processes between the epithelial cells. They differ widely from the chromatophores of fishes. It is not even certain that they are actually of cellular nature. They may consist simply of the intercellular spaces which have been rendered visible by engorgement with pigment. It has been suggested that, if they are cells, they are to be regarded as functional adaptations of the ordinary basal cells. The whole subject of these formations is fully considered by Bloch (1927).

9. *Keratohyalin (eleidin, parakeratose, keratoeleidin):*

The "keratohyalin" of Waldeyer and the "eleidin" of Ranvier are usually regarded as synonymous. Schafer (1912) applies them in this sense. Ludford (1924*b*) says "that the term 'eleidin' has been applied to a substance said to result from the dissociation of keratohyalin and considered to be a glycoproteid."

The granules of keratohyalin, unlike those of melanin, are most abundant in the older cells of the epidermis as the free surface is approached. Their formation is certainly coextensive with alterations in almost all of the visible components of the epidermal cells. Ludford (1924*b*) has shown that parallel with the development of keratohyalin: (1) the mitochondria and Golgi apparatus disintegrate and become greatly reduced in amount, (2) there is a fragmentation and apparent extrusion of nucleolar material and (3) a relative increase occurs in the volume of the cytoplasm as compared with the nucleus. According to him this act of nucleolar extrusion may be seen to take place under normal conditions even in the lowest layer of cells of the *stratum germinativum* (Fig. 8). In the hypertrophied epidermis adjacent to tar tumors the nucleolar changes are much more marked (Fig. 9). He concludes that keratinization is mainly a function of the ground cytoplasm and that the nucleoli, and to a lesser extent the mitochondria contribute to the formation of the granules.

The granules of keratohyalin alter in the successive layers of cells. In the *stratum germinativum* they are scattered irregularly in the cytoplasm. They are very abundant in the *stratum granulosum*, and fuse together to form hyalin masses (eleidin) in the *stratum lucidum*. Finally in the *stratum corneum* with greater dessication the characteristic affinity of the material for such dyes as carmine is lost and the keratohyalin (or eleidin) is no longer recognizable. These phases in the elaboration and alteration of keratohyalin are to be regarded as antecedent to keratinization.

10. *Keratin:*

Pinkus (1910) accepts the conclusion of Unna and Golodetz (1908) that there are two kinds of keratin. Keratin "A" is insoluble in fuming nitric acid and in sulphuric acid plus hydrogen peroxide, while keratin "B" is soluble in these reagents. Both remain undigested when treated with hydrochloric acid and pepsin and are colored red by Millon's reagent indicating the presence of tyrosin.

It is difficult to critically check the results of such tinctorial and solubility tests applied to sections with the data derived from chemical analyses of relatively large amounts of hair, horn, etc. On the chemical side we know that "keratin" is an albuminoid (scleroprotein) and thus belongs in the same category with "collagen" and "elastin." There are several keratins which differ slightly in composition in the different races. "The keratins as a group are insoluble in the usual protein solvents and are not acted upon by the gastric or pancreatic juices. They all respond to the xanthoproteic and Millon reactions and are characterized by containing large amounts of sulphur" (Hawk and Bergeim, 1927).

In the *stratum lucidum* the cell membranes are noticeably keratinized and as one passes toward the surface the process is pushed to an extreme resulting in a hardening of the cells which become dehydrated and desquamate.

No satisfactory explanation of the mechanism of keratinization has ever been given. In the normal epidermis the process becomes more and more marked as the cells migrate further away from the underlying dermis with its rich blood supply. During this change in position they become progressively more dependent upon slow diffusion of substances through the intercellular spaces. Whether they lack certain essentials or whether differentiation is caused by inability to eliminate waste products is not entirely clear. Probably both factors are operative. Drew (1922) has found that keratinization will occur in skin growing in tissue cultures, when subcultures are not made sufficiently frequently, and that the presence of connective tissue aids keratinization. Certainly as the cells grow older they become topographically further removed from any stimulating influences of connective tissue origin. The gradual decrease in oxygen supply

must likewise be considered, also the fact that Wolbach and Howe (1925) have brought about keratinization in epithelia not normally keratinized by reduction in the available amount of fat-soluble A vitamin. The influence of serum lipoids and proteins on growth is discussed by Baker and Carrel (1927) and reference is made to a series of earlier investigations which has an important general bearing on the problem.

11. *Fatty substances (paraeleidin?):*

There is some difference of opinion regarding the normal distribution of fat stainable with Scharlach R in the epidermis, occasioned probably by the examination of skin from different regions under variable physiological states. It occurs in the basal columnar cells of the *stratum germinativum*, in the *stratum granulosum* and *stratum lucidum* (Pinkus, 1910). Nicolau (1911) reports it in the *stratum germinativum* but not in the *stratum corneum*.

The presence of a substance in the *stratum corneum* which is blackened with osmic acid has been noted above. This is the "paraeleidin" of Weidenreich (1901). Unna and Golodetz (1908) have found fatty acid (oleic) and esters of fatty acids in this layer. The coloration with Scharlach R and Sudan may be diffuse, or the fat may exist as granules in the cells, or between the cells (Kollmann and Papin, 1914). The distribution of cholesterol is described by Eckstein and Wile (1926).

The mode of formation of these "fatty" substances is but little understood. Paraeleidin may be formed in some way from eleidin as Rabl (1902) believes and, as the name implies. The mitochondria may even be concerned, for it is known that they play a part in fatty degeneration (Scott, 1916). It is safe to say that we have to do with a complex of influences: one type endogenous, and dependent upon chemical changes in the cells during their life cycle; and another kind exogenous, consisting of processes of adsorption by the cells of the *stratum corneum* of materials poured onto the surface of the skin by the sebaceous glands (p. 36). Since the secretion of these glands varies in different regions one would look for a variation in the fatty substances. They should be different in the keratinized epithelium of the esophagus where the sebaceous glands are replaced by mucus secreting ones.

12. *Nerve and vascular supply:*

Nerve fibers end in contact with the cells of the deeper layers usually in the form of slight expansions or end-bulbs. Sometimes a kind of pericellular network is produced (Cajal, 1925). In the dermis more complicated terminals occur (p. 16). The problem of innervation is considered in detail by Pinkus (1927).

Frequent mention has been made of the fact that the epidermis is an avascular sheet of stratified epithelium. It has no blood vessels of its own,

but one may occasionally observe, especially in the *stratum germinativum* spaces between the cells through which nutritive materials permeate and into which waste products are discharged. These channels are of very inconstant diameter and branch frequently. Sometimes they are visible in sections and sometimes not. They are described and figured by Kolossov (1925). In them are found, under normal conditions, the Langerhans cells above referred to (see also Mawas, 1926), an occasional polymorphonuclear leucocyte, even mast cells, which have entered from the blood vessels of the dermis. For a systematic description of these blood vessels see Spalteholz (1927).

In its avascular character the epidermis resembles cartilage (Section XX). In cartilage, however, the amount of intercellular substance is more considerable and the thickness of the avascular layer much greater, particularly in the costal cartilages notwithstanding the occasional penetration of the so-called "vascular canals." A remarkable feature of the epidermis is the close association of living and dead cells, so often stressed in this account, within an extremely thin layer (.02 mm.). This would obviously be impossible were it not for the special factors promoting keratinization.

13. *Specific inclusions occurring in diseases due to filterable viruses:*

Diseases of this kind are very prone to attack epidermal cells in which the inclusions produced are highly specific and constitute one of the most characteristic features of the reaction. An instructive review has been written by Findlay and Ludford (1926). These authors present the classification suggested by Lipschütz (1921):

"(1) Cyto-oikon group in which the enclosures lie in the cytoplasm—molluscum contagiosum, trachoma, fowl-pox, sheep-pox.

"(2) Karyo-oikon group in which the enclosures lie in the nucleus—herpes, warts.

"(3) Cyto-karyo-oikon group in which the enclosures lie in the cyto- and nucleoplasm—variola and para-vaccinia."

To these the virus III of Rivers and Tillett (1924) should be added because it gives rise to destructive intranuclear inclusions when acting on epidermal cells. Some other intranuclear inclusions, which have been described, are open to question since the investigators concerned have not apparently considered critically certain nucleolar modifications which the cells of the epidermis are inclined to exhibit in the absence of infections (Fig. 8). Some additional details concerning specific inclusions in epidermal cells, both nuclear and cytoplasmic are given by Cowdry (1928).

14. *Other substances which have been reported:*

Calcium (Bornstein, 1926; Dähn, 1926; Weidman and Shaffer, 1926), colloid (Jager, 1925), ferments (Klopstock, 1924; Yamasaka, 1924; Sugihara, 1925), glycogen (Gage, 1906; Lombardo, 1907; Sasakawa, 1921), hemosiderin (Masson, 1921; Pautrier and Lévy, 1924), mucin (Krieblich, 1926), potassium (Bornstein, 1926).

II. THE CUTANEOUS GLANDS

It has already been mentioned that in man the general body surface is supplied with fluid principally by two kinds of glands which secrete sebum and sweat respectively.

In the sebaceous glands the secretory products are elaborated by the fatty metamorphosis, destruction and discharge of the cells themselves. These are the "holocrine" glands of Ranvier. The genetic relationship of the secreting cells to the epidermis is shown by the fact that, in addition to the sebum, they may elaborate in their interior small quantities of keratohyalin. Part of the cell substance may even become keratinized. The products are discharged through a duct into the hair follicles and for this reason they are often called, simply, "hair glands." Glands of this nature undergo specialization in certain regions. The Meibomian glands of the eyelids (glandulae tarsales) belong to this category although they do not drain into the hair follicles. The mammary glands are fundamentally of the same type. The character of the secretion is changed somewhat and they have undergone great development along different lines owing to their appropriation by the reproductive system. A special section is devoted to them (Section XXXIV).

The sweat, or sudoriferous glands, are of distinctly different nature. They reach their highest development in man and are wholly absent in some of the lower forms. They give rise to one of the most watery fluids produced by secretory action, and the cells are not broken down in the act of producing it. Ranvier speaks of these glands as "merocrine." In contrast also, to the sebaceous glands the secretion is usually discharged directly upon the surface of the skin although it may sometimes pass *via* the hair follicles. The glands themselves are situated, not in the dermis, but in the subcutaneous fatty tissues. A relationship to the epidermis is evidenced by the frequent deposition of melanin within the secretory cells. The ceruminous glands of the external auditory meatus are regarded as a modification of this sudoriferous type notwithstanding the fatty character of their secretion (Schafer, 1912). In this subdivision also belong the glands of Moll (ciliary glands) found in the eyelids and certain glands distributed about the anus (circumanal glands).

A third group of glands may be mentioned in this connection because their secretion is likewise poured out upon the surface of the body, namely, those associated with the production of tears—the lachrymal and Harderian glands which are developed from the conjunctival epithelium.

All of these cutaneous glands are "exocrine" in the sense that they are external secretory and do not pass their products into the blood stream, as is the case with the "endocrine" glands. The cytology of the "exocrine" glands is so fully described elsewhere that no detailed exposition need be

attempted here. Reference will merely be made to a few of the leading contributions on the subject:

Anthropoids (Brinkmann, 1926), centrosomes (Melczer, 1923), fetuses (Becker, 1921), general cytology (Sundwall, 1916), Golgi apparatus (Bowen, 1926), iron distribution (Homma, 1924), lipoidal secretion (Walter, 1924), mitochondria (Altmann, 1894; Nicolas, Regaud and Favre, 1912*a*, *b*), regeneration (Pfanner, 1923), relation of duct to hair (Giovannini and Fontana, 1922), vitamine A deficiency (Lambert and Yudkin, 1923; Wolbach and Howe, 1925).

III. HAIR AND NAILS

Both of these structures are differentiations of the epidermis and are built on fundamentally the same plan. As in the epidermis, multiplication of the cells is confined to the deeper layers, next to the blood vessels, pigment is elaborated and the superficial cells are dead and protective in nature. The hair and nails are, relatively speaking, subject to comparatively few pathological changes. The following references are given for detailed information concerning them:

A. *Hair*—Cuticula (Friebos, 1924), development of pigment (Bloch, 1927), hypertrichosis, homology and phylogeny (Danforth, 1925*a*, *b*), mammalian (Hausman, 1924), mechanical properties (Basler, 1925), mitochondria (Branca, 1911), morphology (Ludwig, 1921), nerve endings (Szymonowicz, 1909; Tello, 1923*b*), nitroprusside reaction (Kaye, 1924), polarized light (Schmidt, 1925), regeneration of pigment (Barfurth, 1925).

B. *Nails*—Melanoma (Jones, 1924), pathology, endocrinology (Heller, 1926), pigmented stripe (Templeton, 1926).

IV. BIBLIOGRAPHY

Alberti, W. 1922. Zur Frage der Linsenregeneration bei Anuren. *Arch. f. Entw. d. Org.*, **1**, 355.

Altmann, R. 1894. *Die Elementarorganismen und ihre Beziehungen zu den Zellen.* 2 Aufl. Leipz.: Veit & Co. 160 pp.

Aubineau, E. 1922. Oedème cornéen et hypercholésterinémie. *Ann. d'ocul.*, **159**, 580.

Aveling, F. and McDowell, R. J. S. 1925–26. The effect of the circulation on the electrical resistance of the skin. *J. Physiol.*, **40**, 316.

Baker, Lillian E. and Carrel, Alexis. 1927. Effect of age on serum lipoids and proteins. *J. Exper. Med.*, **45**, 305.

Barfurth, W. 1925. Ueber Regeneration des Haarpigments. *München. Med. Wchnschr.*, **72**, 811.

Basler, A. 1925. Die mechanischen Eigenschaften der menschlichen Kopfhaare. *Arch. f. d. ges. Physiol.*, **208**, 761.

Becker, 5. 1921. Ueber Haut und Schweissdrüsen bei Foeten und Neugeborenen. *Ztschr. f. Kinderh.*, **30**, 3.

Benedict, F. G. 1925. Die Temperatur der menschlichen Haut. *Ergebn. d. Physiol.*, **24**, 594.

Biedermann, W. 1926. Vergleichende Physiologie des Integuments der Wirbeltiere. *Ergeb. d. Biol.*, Julius Springer, Berl., **1**, 342.

Bloch, B. 1927. *Das Pigment.* in: Handbuch der Haut- und Geschlechtskrankheiten. Berl.: Julius Springer, Vol. 1, Part 1.

— — **and Ryhiner.** 1917. Histochemische Studien in überlebendem gewebe über fermentative Oxydation und Pigmentbildung. *Ztschr. f. exper. Med.*, **5**, 179.

Born, Sofie. 1921. Zur Frage der epidermidalen Basalmembran. *Dermat. Ztschr.*, **34**, 324.

Bornstein, K. 1926. Calcium-und Kalium bestimmungen in der Haut von Mäuser. *Biochem. Ztschr.*, **172**, 133.

Bowen, R. 1926. Studies on the Golgi apparatus in Gland Cells. *Quart. J. Micr. Sci.*, **70**, 193, 395.

Branca, A. 1911. Sur la structure du poil. *J. de l'Anat. et Physiol. etc.*, **47**, 545.

Brinkmann, A. 1926. Skin glands of anthropoid apes. *Anat. Anz.*, **62**, 236.

Busacca, A. 1922. Ueber das Verhalten der sogenannten Basalmembran als Bindemittel zwischen Epidermis und cutis. *Arch. f. Dermat. u. Syph.*, **141**, 88.

Cajal, S. R. 1925. Note sur le réseau péricellulaire de l'epithelium pavimenteux stratifié de la langue. *Trab. d. lab. de invest. biol., Univ. de Madrid*, **23**, 241.

Chambers, R. and Renyi, G. 1925. The structure of the cells in tissues as revealed by microdissection. I. The physical relationships of the cells of epithelia. *Am. J. Anat.*, **35**, 385.

Cowdry, E. V. 1922. The supravital staining of vaccine bodies. *J. Exper. Med.*, **36**, 667.

——— 1928. *Cellular changes in response to the action of filterable viruses.* In Rivers book on "*Filterable Viruses.*" Baltimore: Williams & Wilkins.

——— **and Nicholson, F. M.** 1923. Inclusion bodies in experimental herpetic infection of rabbits. *J. Exper. Med.*, **38**, 605.

Cummins, H. 1926. Epidermal-ridge configuration in developmental defects, with particular reference to the ontogenetic factors which condition ridge direction. *Am. J. Anat.*, **38**, 89.

Da Fano, C. 1921. On Golgi's apparatus of transplantable tumour cells. *7th Rep. Imp. Cancer Res. Fund*, 67.

Dähn, W. 1926. Ueber die Kalzium- und Kalium vertilung in normalen Haut. *Dermat. Wchnschr.*, **82**, 425.

Danforth, C. H. 1925*a*. Studies on hair with special reference to hypertrichosis. *Arch. f. Dermat. u. Syph.*, **11**, 637.

— — — 1925*b*. Hair in its relation to questions of homology and phylogeny. *Am. J. Anat.*, **36**, 47.

Davenport, C. B. 1913. Heredity of skin color in Negro-white crosses. *Carnegie Institution publication*, No. 188, 106 pp.

David, E. 1922. Ueber die Sekundärelektromotorischen Eigenschaften der menschlichen Haut. *Arch. f. d. ges. Physiol.*, **195**, 101.

Deineka, D. 1912. Der Netzapparat von Golgi in einigen Epithel-und Bindegewebszellen während der Ruhe und während der Teilung derselben. *Anat. Anz.*, **41**, 289.

Drew, A. H. 1922. A comparative study of normal and malignant tissues grown in artificial cultures. *Brit. J. Path.*, **3**, 20.

Duesberg, J. 1912. Plastosomen, "Apparato reticulare interno" und Chromidialapparat. *Ergeb. d. Anat. u. Entw., Anat. Hefte*, 2 Abt., **20**, 567.

Eckstein, H. C. and Wile, U. J. 1926. The cholesterol and phospholipid content of the cutaneous epithelium of man. *J. Biol. Chem.*, **69**, 181.

Favre, M. 1924. Faits histologiques concernant la signification des nodules de Bizzozero. *Compt. rend. Soc. de biol.*, **91**, 1220.

— — **and Regaud, C.** 1910. Sur la nature des fibres d'Herxheimer ou filamenst basaux de l'epiderme. *Lyon mêd.*, **22**, 1132.

Favre, M. and Regaud, C. 1913. Sur les formations mitochondriales dans les cellules néoplastiques des épithéliomes de la peau et des muqueuses dermo-papillaires. *Compt. rend. Soc. de biol.*, **74**, 688.

Findlay, G. M. and Ludford, R. J. 1926. The ultra-microscopic viruses. *Brit. J. Exper. Path.*, **7**, 223.

Firket, J. 1911. Recherches sur la genèse des fibrilles épidermiques chez le poulet. *Anat. Anz.*, **38**, 537.

Frieboes, W. 1920. Basalmembran; Bau des Deckepithels (1. Physiologische und pathologische Ausblicke). *Dermat. Ztschr.*, **31**, 57.

——— 1922. Nochmals epidermale Basalmembran. *Arch. f. Dermat. u. Syph.*, **140**, 201.

——— 1924. Haarcuticula und Haarfaserung. *Ibid.*, **147**, 473.

Gage, S. H. 1906. Glycogen in a 56 days human embryo and in pig embryos of 7–10 mm. *Am. J. Anat.*, 5, *Proc. Am. Ass. Anat.*, XIII.

Gaus, O. 1924. Calciumbilder in der Haut. *Arch. f. Dermat. u. Syph.*, **145**, 135.

Gifford, S. R. 1924. Zur Klinik und Histologie der "hyalinen Degeneration" der Kornea, etc. *Klin. Monatsbl. f. Augenh.*, **73**, 346.

Giovannini, S. and Fontana, A. 1922. Peli semplici e composti canalicolati in parte con papilla a corpo incavato e glandole sebace intrabulbari. *Gior. d. r. Accad. di Med. di Torino*, **28**, 172.

Goldschmidt, M. 1920. Experimentelle Studien über Diffusion durch die Hornhaut. *Arch. f. Ophth.*, **103**, 280.

——— 1922. Die Pipoide der Linse. *Biochem. Ztschr.*, **127**, 210.

Gortner, R. A. 1910. Spiegler's "white melanin" as related to dominant or recessive white. *Am. Naturalist*, **44**, 497.

——— 1911. On Melanin. *Biochem. Bull.*, **1**, 207.

Hare, R. 1926. An experimental investigation into the vascular reactions of the susceptible skin to protein. *Heart*, **13**, 227.

Hartwell, G. A. 1923. Note on the colour changes in rats' fur produced by alterations in diet. *Biochem. J.*, **17**, 547.

Hashimoto, H. 1922. Carotinoid pigmentation of the skin resulting from a vegetarian diet. *J. Am. Med. Assoc.*, **68**, 1111.

Hausmann, L. A. 1924. Further studies of the relationships of the structural characters of mammalian hair. *Am. Naturalist*, **58**, 544.

Hawk, P. B. and Bergeim, Olaf. 1927. *Practical Physiological Chemistry*. Phila.: P. Blakiston's Son & Co., 931 pp.

Hazen, H. H. and Whitmore, E. R. 1925. Skin diseases due to emotional disturbances. *Arch. f. Dermat. u. Syph.*, **12**, 261.

Hektoen, L. 1923. Immune reactions of the lens. *Am. J. Ophth.*, **6**, 276.

Heller, J. 1926. Onchopathologie und Endokrinologie. *Deutsche med. Wchnschr.*, **52**, 786.

Herrick, C. Judson. 1924. *An Introduction to Neurology*, Ed. 3, Phila: W. B. Saunders Co., 395 pp.

Hoepke, H. 1924. Epithelfasern und Basalmembran. *Verhandl. d. Anat. Gesellsch.*, **33**, 147.

Hoffman, V. 1919. Studien uber die histologischen Veränderungen und über die Regeneration der Hornhaut bei berätzung derselben durch Bleisalzlosungen. *Arch. f. Augenh.*, **85**, 231.

Holmes, S. J. 1914. The behavior of the epidermis of amphibians when cultivated outside the body. *J. Exper. Zool.*, **17**, 281.

Homma, H. 1924. Über positive Eisenbefunde in den Epithelien der apokrinen Schweissdrusen menschlicher Axillarhaut. *Arch. f. Dermat. u. Syph.*, **148**, 463.

Jager, T. 1925. So-called colloid degeneration of the skin with report and discussion of a case. *Arch. f. Dermat. u. Syph.*, **12**, 629.

Jess, A. and Koschella, Julia. 1923. Ueber den Einfluss des Ultravioletten Lichtes auf die Cysteinreaktion der Linse. *Arch. f. Ophth.*, **111**, 730.

Jones, T. B. 1924. Melanoma of the nail bed. *Ann. Surg.*, **80**, 839.

Jordan, H. E. 1911. A comparative microscopic study of the melanin content of pigmented skins with special reference to the question of color inheritance among Mulattos. *Am. Naturalist*, **45**, 449.

Kahlenberg, L. 1924. On the passage of boric acid through the skin by osmosis. *J. Biol. Chem.*, **62**, 149.

Kaye, Madge. 1924. Observations on the behavior of a substance giving the nitroprusside reaction in skin and in hair. *Biochem. J.*, **18**, 1289.

Klopstock, E. 1924. Die Fermente der Haut. *Biochem. Ztschr.*, **153**, 487.

Kollmann, M. and Papin, L. 1914. Étude sur la kératinisation, l'epithélium corné de l'oesophage de quelques mammifères. *Arch. d'anat. micr.*, **16**, 193.

Kolmer, J. A. 1925. *Infection, Immunity and biologic therapy.* Ed. 3., Phila.: W. B. Saunders Co., 1210 pp.

Kolossov, H. 1925. Ueber die Beziehungen der Zellen zu einanderer und über die Saftkanälchen in Deck- und Drusenepithelien und in Glatten Muskelgewebe. *Arch. Russ. d'Anat. d'Hist. et d'Embry.*, **4**, 143.

Kranz, H. W. 1926. Beiträge zur Siderosis corneae. *Klin. Monatsbl. f. Augenh.*, **76**, 469.

Krause, R. 1926. Enzyklopädie der Mikroskopischen Tecknik. Ed. 3., Berl.: Urban und Schwarzenberg.

Kreiblich, C. 1926. Mucin bei Hauterkrankung. *Arch. f. Dermat. u. Syph.*, **150**, 243.

Laguesse, E. 1923. Chondriome et développement des fibrilles dans la cornée. *Compt. rend. Soc. de biol.*, **89**, 871.

Lambert, R. A. and Yudkin, A. M. 1923. Changes in the paraocular glands accompanying the ocular lesions which result from deficiency of vitamine A. *J. Exper. Med.*, **38**, 25.

Lent, E. J. and Lyon, Martha B. 1922. Persistence of embryonic fibrovascular sheath of the crystalline lens. *Am. J. Ophth.*, **5**, 706.

Levy-Franckel, A. and Juster, E. 1926. The rôle played by disturbances of the sympathetic nervous system and of the endocrine glands in the pathogenesis of cutaneous affections. *Urol. & Cutan. Rev.*, **30**, 327.

Lewis, T. 1926. Observations upon the regulation of blood flow through the capillaries of the human skin. *Heart*, **13**, 1.

Lipschütz, B. 1921. Untersuchungen über die Atiologie der Krankheiten der Herpesgruppe. *Arch. f. Dermat. u. Syph.*, **136**, 428.

Lombardo, C. 1907. Il glicogeno della cute. *Gior. ital. d. mal. ven.*, **42**, 448.

Lorberbaum, L. and Unna, P. G. 1925. Das Eleidin. Eine chromolytische Studie. *Dermat. Wchnschr.*, **81**, 1520.

Ludford, R. J. 1924*a*. Nuclear activity during melanosis with special reference to melanin formation in a melanotic sarcoma. *J. Roy. Micr. Sci.*, **44**, 13.

——— 1924*b*. Cell organs during keratinization in normal and malignant growth. *Quart. J. Micr. Sci.*, **69**, 27.

Ludwig, E. 1921. Morphologie und morphogenese des Haarstrichs. *Ztschr. f. d. ges. Anat.*, I Abt., **62**, 59.

Masson, P. 1921. Les cellules de Langerhans; leur rôle dans les échanges dermo-épidermiques. *Bull. Soc. franc. de dermat. et Syph.*, Paris, S 28, *Bull. rêun. dermat. de Strasburg*, 7.

Mawas, J. 1926. Sur les cellules dites Langerhans et leur rôle dans la constitution des tumeurs épidermique des paupières. *Ann. Anat. Path.* (Paris), **3**, 285.

Melczer, N. 1923. Über die Zentralkörper der menschlichen Talgdrüsenzellen. *Arch. f. Dermat. u. Syph.*, **146**, 131.

——— 1926. Zur Biochemie der Hauttuberkulose. III Über den Phenolase und Diastasegehalt der tuberkulosen Haut. *Ibid.*, **152**, 381.

Memmesheimer, A. 1924. Die H- Ionenkonzentration der Hautoberfläche. *Berl. Klin. Wchnschr.*, **3**, 2102.

Menschel, H. 1925. Zur Kolloidchemie und Pharmakologie der Keratinsubstanzen der menschlichen Haut. *Arch. f. exper. Path. u. Pharmakol.*, **110**, 1.

Mumford, P. B. 1927. Habit formation in the blood vessels of the skin. *Brit. Med. J.*, **1**, 324.

Nakamura, Y. 1926. Ueber das Verhalten der Lipase und über das Vorkommen von Phosphatase, Sulfatase und Carboxylase in der Haut. *Biochem. Ztschr.*, **175**, 216.

Nicolas, J., Regaud, C. and Favre, M. 1912*a*. Sur les mitochondries des glandes sébacées de l'homme et sur la signification générale de ces organites du protoplasma. *Compt. rend. de l'Assoc. anat.*, **201**.

——— 1912*b*. Sur la fine structure des glandes sudoripares de l'homme particulièrement en ce qui concerne les mitochondries et les phénomènes de sécrétion. *Ibid*, 191.

Nicolau, S. 1911. Recherches histologiques sur la graisse cutanée. *Ann. de dermat. et syph.*, **2**, 641.

Pautrier, S. M. and Lévy, G. 1924. Les échanges dermo-épidermiques et le réseau tropho-melanique. *Ann. de dermat. et Syph.*, **5**.

Petersen, W. F. 1927. The permeability of the skin capillaries in various clinical conditions. *Arch. Int. Med.*, **39**, 19.

——— **and Willis, D. A.** 1926. Capillary permeability and the inflammatory index of the skin in the normal person as determined by the blister. *Arch. Int. Med.*, **38**, 663.

Pfanner, H. 1923. Beitrag zur Frage der Neubildungsmöglichkeit der Hautdrüsen. *Arch. f. Dermat. u. Syph.*, **146**, 28.

Pinkus, Felix. 1910. *The Development of the Integument.* Keibel & Mall's *Embryology*, **1**, 243, Phila: J. B. Lippincott Co.

——— 1927. Die normale Anatomie der Haut. In: Handbuch der Haut- und Geschlectskrankheiten. Vol. 1, part 1. Berl.: Julius Springer.

Poehlmann, A. 1924. Zur Frage der Vitalfärbung der Haut am Menschen. *Dermat. Wchnschr.*, **79**, 849.

Pottenger, F. M. 1926. The neurological and endocrinological aspects of icthyosis, chronic indurative eczema and some of the minor forms of so-called trophic changes in dermal tissues. *Endocrinology*, **10**, 105.

Rabl, H. 1902. Histologie der normalen Haut des Menschen. *Mracek's Handb. der Hautkrankheiten.* Vol. 1, part 1, p. 1, (cited from Pinkus).

Regaud, C. and Favre, M. 1912. Nouvelles recherches sur les formations mitochondriales de l'épiderme humain a l'état normal et pathologique. *Compt. rend. Soc. de biol.*, **22**, 328.

Regelsberger, H. 1924. Ueber den Galvanismus der menschlichen Haut. *Ztschr. f. d. ges. exper. Med.*, **42**, 159.

Rein, H. 1924. Experimentelle Studien über Electroendosmose an überlebender menschlicher Haut. *Ztschr. f. Biol.*, **81**, 125.

Rio Hortega, P. del. 1917. Contribucion al conocimiento de las epiteliofibrillas. *Trab. lab. de invest. biol., Univ. Madrid*, **15**, 201.

Rivers, T. M. 1928. *Virus Diseases.* Baltimore: Williams & Williams Co.

——— **and Tillett, W. S.** 1924. The lesions in rabbits experimentally infected by a virus encountered in the attempted transmission of varicella. *J. Exper. Med.*, **40**, 281.

Rohrschneider, W. 1924–25. Experimentelle Untersuchungen über die infiltrative verfettung der cornea beim Kaninchen. *Arch. f. Ophth.*, **115**, 535.

Rous, Peyton. 1926. The Relative reaction within living mammalian tissues. VI. Factors determining the reaction of skin grafts. *J. Exper. Med.*, **44**, 815.

Saguchi, S. 1913. Über Mitochondrien (Chondriokonten) und mitochondriale Stränge (= sog. Eberthsche intrazelluläre Gebilde) in den Epidermiszellen der Anuren larven nebst Bemerkungen über die Frage der Epidermis-Cutisgrenze. *Arch. f. mikr. Anat.* Abt. II, **83**, 177.

Sasakawa, M. 1921. Beiträge zur Glykogenoerteilung in der Haut unter normalen und pathologischen Zuständen. *Arch. f. Dermat. u. Syph.*, **134**, 418.

Schafer, Sir E. A. 1912. *Textbook of microscopic anatomy*. Lond.: Longmans, Green and Co., 752 pp.

——— 1926. The Endocrine Organs. Part II. Lond.: Longmans, Green & Co. 417 pp.

Schmidt, W. J. 1921. Ueber den Nachweis der Epidermis-Tonofibrillen (bei Emyda granosa) im polarisierten Licht. *Arch. f. Zellforsch.*, **16**, 1.

——— 1925. Menschliche Haare in polarisiertern Licht. *Mikrokosmos* (Stuttg.), **19**, 65, 89.

Schmidtmann, M. 1925. Über die intracelluläre wasserstoffionenkonzentration. *Klin. Wchnschr.*, **4**, 759.

Schridde, H. 1906. Die protoplasmafasern der menschlichen Oberhaut. *Arch. f. mikr. Anat.*, **67**, 291.

Scott, W. J. M. 1916. Experimental mitochondrial changes in the pancreas in phosphorus poisoning. *Am. J. Anat.*, **20**, 237.

Seefelder, R. 1925–26. Zur Entwicklung der Hornhaut des Menschen. *Arch. f. Augenh.*, **97**, 156.

Shapiro, B. 1923–24. On the epithelial fibres in the skin of mammals. *Quart. J. Micr. Sci.*, N. S., **68**, 101.

Sharlit, H. and Highman, W. J. 1923. The use of chromogenic indicators in dermatology. *Arch. f. Dermat. u. Syph.*, **8**, 515.

——— **and Scheer, M.** 1923. Hydrogen ion concentration of the surface of the healthy intact skin. *Arch. f. Dermat. u. Syph.*, **7**, 592.

Spalteholz, W. 1927. Blutgefässe der Haut. In: Handbuch der Haut- und Geschlechtskrankheiten. Vol. I, part I. Berl.: Julius Springer.

Steiger-Hazal, D. 1926. Über die Beziehungen zwischen Hautpigment und Blutty-rosin. *Arch. f. Dermat. u. Syph.*, **152**, 420.

Strong, R. M. 1927. Color of the skin and corium pigmentation. *Arch. of Path.*, **3**, 938.

Sugihara, N. 1925. Vergleichende Untersuchungen über den Fermentgehalt frischer Haut von Mensch und Tier und über den Einfluss verschiedener Lichtarten auf die Haut. *Biochem. Ztschr.*, **163**, 260.

Sundwall, J. 1916. The Lachrymal Gland. *Am. J. Anat.*, **20**, 147.

Szymonowicz, L. 1900. Über die Nervenendigungen in den Haaren des Menschen. *Arch. f. mikr. Anat.*, **74**, 622.

Talbert, G. A., Silvers, S. and Johnson, W. 1927. Simultaneous study of the constituents of the sweat, urine and blood, also gastric acidity and other manifestations resulting from sweating. *Am. J. Physiol.*, **81**, 81.

Tello, F. 1923*a*. El reticulo de Golgi en las células de algunos tumores y en las del granuloma experimental producido por el kieselgur. *Trab. lab. invest. biol., Univ. de Madrid.*

——— 1923*b*. Genèse des terminaisons motrices et sensitives. II. *Ibid.*, **21**, 255–384.

Templeton, H. J. 1926. Pigmented stripe in the nail. *Arch. f. Dermat. u. Syph.*, **14**, 533.

Turchini, J. 1922. Etude histologique de la Poche du Noir des cephalopodes Dibranchiaux. *Arch. d'anat. Micr.*, **18**, 328.

Uhlenhuth, E. 1919. Studien zur Linsenregeneration bei den Amphibien. *Arch. f. Entw. d. Org.*, **45**, 498.

Unna, P. G. and Golodetz, L. 1908. Neue Studien über die Hornsubstanz. *Monatschr. f. prakt. Dermat.*, **47**, 62.

Vogt, A. 1919. Der physiologische Rest der Arteria hyaloidea der Linsenhinterkapsel. *Arch. f. Opbth.*, **99**, 328.

Wakelin Barrat, J. O. 1912–13. Changes in chondriosomes occurring in pathological conditions. *Quart. J. Micr. Sci.*, **58**, 553.

Walker, E. 1925. The sulphydryl reaction of skin. *Biochem. J.*, **19**, 1085.

Walton, D. C. and Witherspoon, M. G. 1925–26. Skin absorption of certain gases. *J. Pharmacol. and Exper. Therap.*, **26**, 315.

Walter, A. 1924. Ueber die Hautdrüsen mit Lipoidsekretion bei Nagern. *Beitr. z. path. Anat. u. z. allg. Path.*, **73**, 142.

Weidenreich, F. 1901. Weitere Mitteilungen über den Bau der Hornschicht der menschlichen epidermis und ihren sog. Fettgehalte. *Arch. f. mikr. Anat.*, **57**, 583.

Weidman, F. D. and Shaffer, L. W. 1926. Calcification of the skin including the epiderm. *Arch. f. Dermat. u. Syph.*, **14**, 503.

Weil, Mabel. 1922. A physico-chemical discussion of the mechanism of formation of lenticular opacities. *Am. J. Physiol. Optics*, **3**, 58.

Wells, H. Gideon. 1925. Chemical Pathology, Ed. 5, Phila.: W. B. Saunders Co., 790 pp.

Werber, E. I. 1918. Critical notes on the present status of the lens problem. *Biol. Bull.*, **34**, 219.

Wolbach, S. B. and Howe, P. R. 1925. Tissue changes following deprivation of fat-soluble A vitamine. *J. Exper. Med.*, **42**, 753.

Yamasaki, Y. 1924. Ueber die Fermente der Haut. *Biochem. Ztschr.*, **147**, 203.

Young, W. J. 1914. A note on the black pigment in the skin of the Australian black. *Biochem. J.*, **8**, 460.

Yudkin, A. M. and Lambert, R. A. 1923. Pathogenesis of the ocular lesions produced by a deficiency of vitamine A. *J. Exper. Med.*, **38**, 17, 25.

Section III

THE MUCOUS MEMBRANE OF THE NASAL CAVITY AND THE PARANASAL SINUSES

CONTENTS

Section III

PAGE

I. Nasal Vestibule 47
II. Nasal Fossa 48
1. Olfactory portion 48
Olfactory cells—Sustenacular cells—Basal cells—Trigeminal nerve—Tunica propria of olfactory region—Olfactory glands of Bowman
2. Respiratory portion 53
Respiratory epithelium—Basement membrane—Tunica propria—corpora cavernosa—Glands of respiratory mucous membrane
III. Vomeronasal Organ 60
IV. Paranasal Sinuses 60
1. Epithelium 61
2. Basal membrane 62
3. Tunica propria 62
4. Glands 63
V. Protective Mechanism 64
VI. Chemical Composition 65
VII. Bibliography 66

Section III

THE MUCOUS MEMBRANE OF THE NASAL CAVITY AND THE PARANASAL SINUSES

J. PARSONS SCHAEFFER

THE erroneous Galenic idea that mucous discharges from the nasal fossae in health and disease are from the brain by way of the cribriform portion of the ethmoid bone is set aside by Victor Conradin Schneider in a contribution, "De Catarrhis," published about 1660. So well does the Wittenberg professor and physician to the Elector of Saxony present his argument on the lining membrane of the nasal fossae and the source of the discharges, that at an early time his name becomes inseparably associated with the membrane. The designation, *Schneiderian membrane*, meaning the nasal mucous membrane, is of common usage even at the present time.

In conformity with the grosser plan of the nasal cavity and its appendages, the lining mucous membrane on each side is divided into three more or less distinct regions: (1) the vestibule, (2) the nasal fossa, and (3) the paranasal sinuses. The several regions have histological features which characterize them, despite the fact that the lines of demarcation are not rigidly fixed. The want of sharp definition also is true where the nasal mucous membrane becomes continuous with that of the nasopharynx, the auditory tube, the vomeronasal organ and the nasolacrimal duct. In agreement with the physiology of the nasal fossa proper, the mucous membrane is divided, both histologically and physiologically, into two unlike portions, a discovery made by Todd and Bowman (1857).

1. THE NASAL VESTIBULE

The paired nasal vestibules correspond closely in extent and contour to the cartilaginous portion of the nasal wall. Each serves as an antechamber to the related nasal fossa, the lining membrane being known as the *regio vestibularis* of the nasal mucosa.

At the naris or nostril, the skin of the upper lip and the wing of the nose turns into and lines the vestibule. For a goodly but variable distance, the lining membrane retains its surface characteristics of a stratified squamous epithelium with superficial horny cells resting upon a connective tissue corium continuous with that of the skin. The skin characters are lost about the middle of the vestibule, changing to a stratified squamous epithelium with an absent horny layer, resting upon a connective tissue propria. The gradual change to the moist respiratory epithelium is thus anticipated.

The tunica propria is very intimately attached to the perichondrium of the related nasal cartilages and is composed of fibrous tissue richly interspersed with elastic fibrils. In the outer part, the vestibule contains numerous coarse and stiff hairs (vibrissae), which do not appear to have any associated arrectores pilorum muscles. Many sebaceous glands are connected with the hairs, while others open directly upon the surface of the epithelium. The hairs and the secreting portions of the sebaceous glands protrude into the deeper strata of the fibrous tunica propria. Sudoriferous glands, likewise, are encountered. In the inner part of the vestibule, the connective tissue propria contains mixed seromucous glands, but no sweat glands.

Not infrequently areas of stratified squamous or pavement epithelium are carried beyond the limits of the vestibule at the limen vestibuli on to the nasal septum and the inferior nasal meatus and its related concha.

II. THE NASAL FOSSA

Whatever secondary functions may be ascribed to the nasal fossae, they clearly serve as the peripheral olfactory organ and as an adjunct to the respiratory system. In spite of the fact that Schneider's epochal discoveries justify the naming of the nasal mucous membrane, the *Schneiderian* or *pituitary membrane*, Todd and Bowman must be credited for distinguishing, almost two centuries later, the two fundamental histological portions of the membrane—the olfactory and the respiratory—and for first using the caption, the "olfactory region."

1. *The olfactory portion (pars olfactoria):*

The olfactory portion of the nasal mucous membrane occupies a relatively small portion of each nasal fossa, being confined to the upper third of the nasal septum, nearly the whole of the superior concha, a small portion of the middle concha and, in some instances, to the ventral extremity of the supernumerary conchae that may be differentiated above the superior concha. This is in fair agreement with the field as plotted by Read, but is larger than the long-accepted field of v. Brunn (250 sq. mm.). In the healthy and fresh state, the limits of the olfactory region are marked by a yellowish or sienna-brown tint of the epithelium and not infrequently by an increase in thickness over the related respiratory portion. However, the chief characterizing features are to be found in the cytological picture.

The epithelium of the olfactory region is in part a surface neuroepithelium, resting upon a tunica propria. There is no basement membrane in man, save for short stretches; however, these are atypical. In cat, a structureless membrane next the epithelium suggests a basal membrane. The epithelium of the olfactory region consists of three types of cells: (1)

the *olfactory*, (2) the *sustentacular* (stay or supporting), and (3) the smaller *stellate basal* cells. Occasionally wandering cells are lodged amongst the foregoing elements (Fig. 10). No structure in the nasal epithelium of dog, cat or man which resembles the "Geruchnospen" of Blaue or the "Epithelknospen" described by Disse are demonstrable (Read). Recent studies of the epithelium in man confirm this.

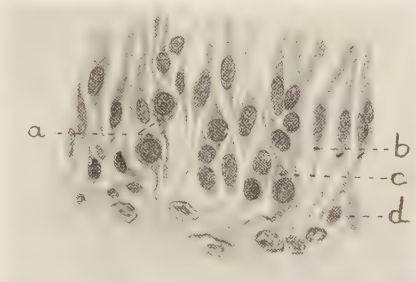

FIG. 10.—The epithelium of the olfactory region of the mucous membrane of the nasal fossa. Drawing made from a very thin section. (Obj. 2 mm., oc. 10x, child aged 10 years.) a, c, olfactory cells; b, sustenlacular cells; d, basal cells.

(*a*) THE OLFACTORY CELLS

The olfactory cells (cell body and processes) are the perceptive elements in the olfactory region, functioning in the sense of smell. They are neurons of the first order in the olfactory pathway and represent morphologically the ganglionic cells on the sensory roots of the spinal nerves. However, the cell bodies retain their primitive location in the surface epithelium, a unique feature for neuro-epithelial elements.

The olfactory cell bodies are fusiform and bipolar and contain fairly large spherical nuclei which lie variously in the middle and deep layers of the epithelium, forming a zone of round nuclei (Figs. 10 and 11). However, taking into account the entire formation —cell body and processes —the olfactory cell or neuron extends through and beyond the entire thickness of the epithelium. In the epithelium the olfactory cells are supported by the sustentacular or stay cells, the peripheral and central processes passing between them. The nucleus of the olfactory cell is enclosed by a narrow fringe of protoplasm from which flow the processes.

The *peripheral process* or dendrite is short, the length being dependent upon the level of the cell body, often irregular and is the more robust of the processes. It courses or curves through the non-nuclear epithelial zone and terminates slightly beyond the free surface of the epithelium in a small hemispherical vesicle or bulbous enlargement which, in turn, is surmounted by from six to eight short cilia or olfactory hairs. Occasionally, the peripheral process projects spine-like without enlargement. At the epithelial

surface, a faintly striated or homogeneous border, the *cuticular* or *olfactory limiting membrane*, the *semi-fluid cuticle*, covers the entire surface of the epithelium. Into this push the bulbous ends of the peripheral olfactory processes and through it penetrate to the very surface the olfactory hairs or cilia to receive the smell stimuli. It is believed that the cuticular membrane is formed by the stay or supporting cells subjacent to it (see elsewhere).

The *central process* of the olfactory cell is much less robust than the peripheral. Typically, it is slender and follows an undulating course between and among the deeper epithelial cells into the tunica propria. It is the axis

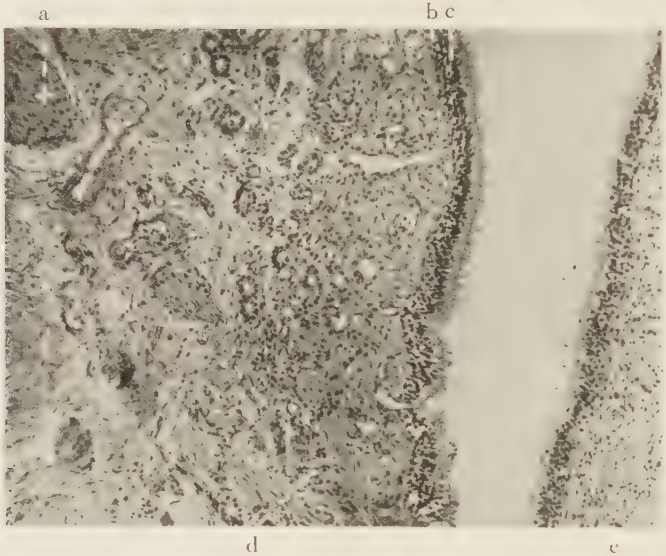

FIG. 11.—Section of the mucous membrane in the olfactory region of the nasal fossa. The superior nasal concha and the adjacent portion of the nasal septum are shown. Note the olfactory glands and the olfactory nerve bundles. The non-nuclear clear zone, the zone of ovoid nuclei and the zone of round nuclei are well illustrated. (Photograph obj. 16 mm., oc. 7.5 x, female child aged 9 years.) a, olfactory nerve; b, zone of round nuclei; c, zone at oval nuclei; d, olfactory region, superior nasal concha; e, olfactory region, nasal septum.

cylinder or axon of the olfactory cell or neuron. In thick sections, properly stained, one can trace each process variously into one of the non-medullated olfactory nerve bundles of the tunica propria. However, in thin sections the central processes can be traced only for short distances from the olfactory cell body, owing to cutting of the fibers.

While Max Schultze did not directly observe the continuity of the olfactory fibers and the bipolar cells, he firmly held to the belief that they were parts of the same cell. In 1862 he concluded: "The future will prove this view through observation." Eckhard, Ecker, v. Brunn and others were less certain. Ehrlich, in 1866, by the methylene blue method, proved

beyond peradventure the direct connection of the olfactory fibers of the tunica propria with the bipolar cells of the epithelium. Subsequently, other workers by the use of the Golgi method credited Ehrlich's conclusions. Since the time of Scarpa, 1785, the olfactory nerve bundles beneath the epithelium are described and illustrated as forming a plexus in the olfactory region. To Effie A. Read (1908) goes the credit for discovering that in dog, cat and man the olfactory nerve bundles do not anastomose to form a plexus. It is now known that the axon or the olfactory fiber "keeps its unity and independence from the olfactory cell to the olfactory bulb," branching only where it reaches the glomerulus. Whenever there is an appearance of a plexus Read finds it to be merely a crossing of nerve bundles.

(*b*) THE SUSTENTACULAR CELLS

The sustentacular or stay cells were first distinguished from the olfactory cells by Eckhard in 1855, but doubt exists in his contributions as to their nature and purpose. They are tall, columnar and non-ciliated elements. Especially the outer halves of the cells are wide and cylindrical, the deeper halves are more slender and forked, forming a protoplasmic network (Fig. 10).

A thin, homogeneous or perhaps indistinctly striated cuticular border overlays the sustentacular cells. The structure not infrequently appears such that small rods or vertical markings are suggested in the border zone. These are, however, not true cilia. Different stages in the physiology of the cells may be a factor in the varied picture of the cuticular border. Doubtless, the border is the product of the sustentacular cells. Being extruded mucus, it leads to great irregularity of the surface, some cells projecting far beyond others. Here and there patches of true ciliated epithelium of the respiratory type are found in the olfactory region. However, these cilia must not be confounded with the surface striations of the cuticular border of the non-ciliated sustentacular cells.

The sustentacular cells have an oval nucleus, smaller than that of the olfactory cells and located more superficially. The nucleus is in the outer and broader ends of the cells, the many nuclei forming a conspicuous nuclear stratum—the zone of oval nuclei. However, there is a considerable distance between the free end of the cells and the location of the nucleus, which leads to a peripheral clear zone devoid of nuclei, one of the characteristic features of the olfactory portion of the nasal mucous membrane (Fig. 11).

The body of the sustentacular cells is much broader than the peripheral processes (dendrites) of the olfactory cells which come to the surface between them. The deep or basal end of the sustentacular cells may be clubbed, but more frequently is forked into two or more processes. The latter reach the deepest limits of the epithelium and, in the absence of a

true basement membrane, rest upon the tunica propria. In the intervals of the basal forks are found the stellate basal cells. The cytoplasm of the sustentacular cells is granular. The mucoid granules are often arranged more or less into longitudinal or vertical rows. Yellow pigment is frequently present in large amounts; again, little is to be found. Goblet cells are also found, indicating a provision for mucous secretion in the absence of mucous glands in the region.

(*c*) THE BASAL CELLS

The stellate basal cells lie in the network formed by the basal forking of the supporting or stay cells. They form the deepest nuclear zone of the olfactory mucous membrane. The basal cells are variously low pyramidal, cuboid or round. They have an ovoid nucleus and a finely granular protoplasm and sometimes contain pigment particles. It is believed that the stellate basal cells represent additional and younger forms of supporting or stay cells.

(*d*) THE TRIGEMINAL NERVE

The trigeminal nerve yields free terminations in the olfactory epithelium.

(*e*) THE TUNICA PROPRIA OF THE OLFACTORY REGION

Strictly speaking, no basement membrane is found in the olfactory region, hence the epithelium rests directly upon the tunica propria. Here, the tunica propria is differentiated into a superficial and a deep stratum. The superficial stratum is from 15μ to 25μ thick, and consists of a delicate reticulated tissue in which are found many irregularly round cells. In places the cells are so closely packed as to suggest small lymph follicles. The deeper stratum contains fewer cells, but heavier bundles of connective tissue. Large olfactory nerve bundles are found in the tunica propria, especially as the bone is neared. Elastic fibrils are found throughout (Fig. 11).

(*f*) THE OLFACTORY GLANDS OF BOWMAN

The tunica propria of the olfactory region contains glands of a different nature from those in the respiratory portion of the nose, e.g., the olfactory glands, also named Bowman's glands by Kölliker. The olfactory glands are of the branched tubular or tubulo-acinar variety and open on the free surface of the epithelium by a narrow excretory duct which leads from a collecting reservoir or ampulla. Throughout its intra-epithelial course, the excretory duct is lined with a single layer of low cuboidal cells. The secreting tubules are lined with higher cuboidal or conical cells. Several tubules come together to form a secondary excretory duct which soon dilates into a saccular fusiform ampulla lined with a single layer of low cuboidal epi-

thelium, which serves as a temporary reservoir for the secretion. The ampulla again narrows and at the deep border of the epithelium becomes the ultimate intra-epithelial excretory duct.

The yellowish cuboidal cells of the tubules of the olfactory glands contain large numbers of albuminoid secretory granules not unlike the parotid. This suggests that the olfactory glands are serous and elaborate a specific secretion, despite the fact that a few mucus-secreting cells are found amongst them. However, the determination of their real function remains for future investigation. Since smell is a chemically excited sense, requiring a solution of the gaseous odoriferous substances in the secretions of the nose before the olfactory receptors or cells can be stimulated, it is clear that the olfactory glands and probably others are adjuncts to the sense of smell.

In the border zone the olfactory glands variously overflow into the respiratory region of the nasal mucous membrane. As stated elsewhere, islands of ciliated columnar epithelium of the respiratory type are occasionally cut off and entirely surrounded by olfactory epithelium. The glands which open upon these islands are mucous in type but they, as well as the ciliated epithelium, are atypical for the olfactory region.

2. *The respiratory portion (pars respiratoria):*

The nasal respiratory mucous membrane typically presents a stratiform or pseudo-stratified ciliated columnar or cylindrical epithelium. On the nasal septum in the region of the vestibule and on the related portion of the inferior nasal concha, patches of stratified squamous epithelium are occasionally encountered. The transition at the limen vestibuli is not always absolute or sharply demarcated. From the surrounding respiratory epithelium, ciliated columnar cells are carried on to the squamous patches, leading to an intermixing of cells.

There is a transitional zone between the respiratory, stratiform, ciliated columnar epithelium of the nasal fossae and the stratified squamous epithelium of the pharynx. The zone encircles the nasal pharynx in a variable wavy ring. Bryant investigated the transitional zone in man, monkey, cat, rabbit, etc., and while he reports considerable variation in the outline in some of the forms, there is a fair constancy in the same animal. The cat, cebus and macacus monkey and man are in close agreement, the anterior border of the zone crossing the Eustachian orifice, while the posterior border is a short distance behind the orifice. Bryant finds that the transitional zone is composed of cuboid cells with imperfect cilia or no cilia at all.

The respiratory mucous membrane varies much in thickness in the several localities of the nasal fossae. Over the inferior concha, the anterior projecting part of the middle concha and the adjacent portions of the nasal septum, the membrane may reach a thickness of 2 to 3 mm. Elsewhere it is

less than a millimeter, at places extremely thin. The thickness in normal states is largely due to the degree of development of the tunica propria and its component structures, especially the contained cavernous spaces. The respiratory mucous membrane readily thickens in physiological and pathological conditions, often attaining a thickness from four to six times normal, thus greatly hindering the intake of air.

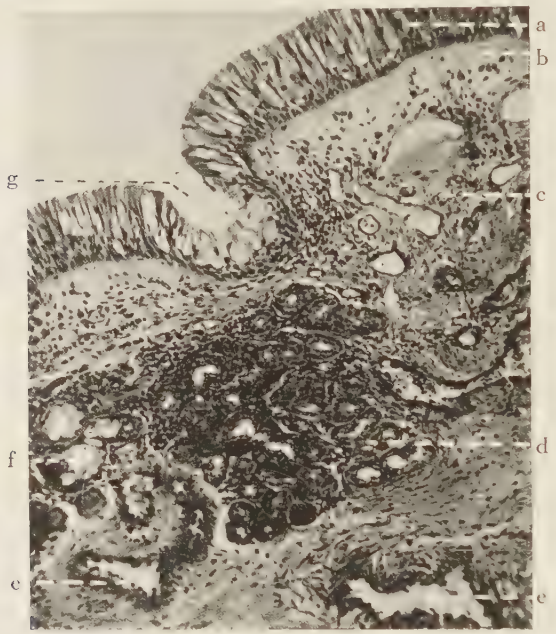

FIG. 12.—The mucous membrane of the inferior nasal concha. Particularly note the large number of blood capillaries in the more superficial portion of the tunica propria. Only a few of the spaces composing the corpus cavernosum conchae or erectile tissue are shown. The larger of the spaces are located in the deeper planes of the tunica propria. (Photograph obj. 16 mm., oc. 10 x, female aged 40 years., a, epithelium; b, basement membrane; c, blood capillaries; d, serous glands; e, erective tissue space; f, sero-mucous gland; g, epithelial crypt.

The deeper fibro-elastic bundles of the tunica propria mingle freely with the periosteum and the perichondrium of the related bones and cartilages, forming a muco-periosteum and a muco-perichondrium. There is, however, considerable variation in the degree of closeness in the several localities of the nasal fossa.

(*a*) THE RESPIRATORY EPITHELIUM

The stratiform or pseudo-stratified ciliated columnar or cylindrical epithelium of the respiratory portion of the nasal mucous membrane typi-

cally rests upon a basement membrane and is from 50μ to 75μ thick (Figs. 12 and 14). The tall ciliated surface cells extend the entire thickness of the epithelium. The deeper slender ends of the cells rest upon the basal membrane, while the more bulky cilia-containing ends come to the surface of the epithelium. Cement edges are demonstrable between the superficial extremities of the ciliated cells and the related chalice or goblet cells. The cilia vary in length from 5μ to 10μ, being least developed over the respiratory portions of the upper nasal conchae. They appear to have a mass action, the wave current moving in the direction of the choanae or posterior nares.

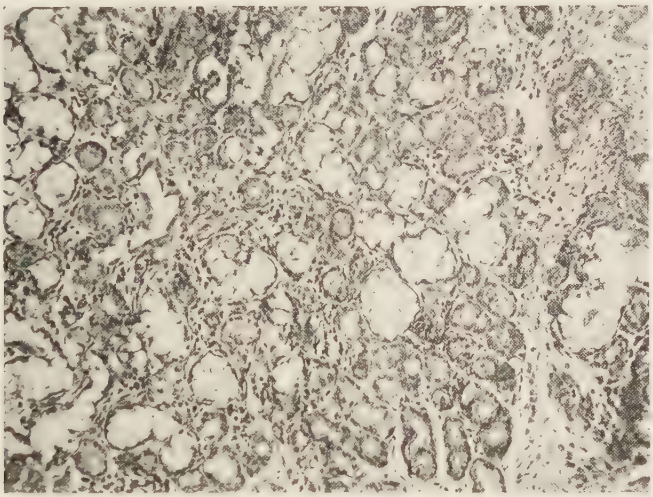

FIG. 13.—Portion of the tunica propria of the inferior nasal concha. Note the large number of mucous and serous glands. Demilunes of Heidenhain are present in some of the mucous tubules. (Photograph obj., 16 mm., oc. 10 x, female aged 40 years.)

The cilia are to be looked upon as an important defense mechanism and no portion of the cilia-bearing epithelium should be destroyed unless absolutely necessary.

The spaces between the deep, forked and pointed extremities of the tall ciliated cells are filled with irregularly cylindrical or conical cells, also called basal cells. These rest upon the basement membrane, but their pointed apices do not reach the free surface.

It is believed by some that these basal cells grow to the surface, acquire cilia and replace cast-off ciliated cells. They are thus thought to be replacement cells. There is, however, considerable evidence that they are concerned with the secretion of mucus. Schafer says that they contain mucigen in all stages of their growth and become distended by it into goblet cells. Opportunity was recently afforded to examine areas where the ciliated cylindrical epithelium suffered destruction through accident. From this it would appear

that such areas fill in from the edges and not from the bottom. A flattened epithelium first covers over the denuded area; this subsequently becomes cylindrical and ciliated. This would indicate, therefore, that the irregularly cylindrical basal cells are not replacement cells. Further observation is essential before conclusions can be drawn.

The respiratory portion of the nasal mucous membrane usually harbors a large number of mucus-containing chalice or goblet cells. They are located between the tall ciliated cylindrical cells and rest upon the basement membrane. At times they largely replace the ciliated elements. Many cells are encountered that are in various stages of conversion into goblet cells. Not infrequently one finds granules or droplets of mucus exuded from the free and, what appears, an open end of the goblet cells. At times, and in certain locations, few if any goblet cells are found.

Intra-epithelial migratory lymphocytes are common and numerous. Nerves with free terminations are reported by Read in histological specimens of the nasal septum and the conchae or turbinates in dog, cat and man. These are endings of the trigeminal nerve.

(*b*) THE BASEMENT MEMBRANE (MEMBRANA PROPRIA)

Generally speaking, the respiratory portion of the nasal mucous membrane may be said to have a basal membrane. However, at places it is very atypical, or feebly developed, or wanting altogether. There appears to be no constancy in the location of basement membrane-free areas. The membrane varies in thickness from 2μ to 15μ, and under pathological conditions may increase many times.

Where typical the basement membrane is usually homogeneous or delicately striated (Figs. 12 and 14). It is fenestrated or pierced by small vertical canals (basal canals), admitting many connective tissue cells and leucocytes into its substance, frequently giving it a very cellular appearance (Fig. 12). Areas are encountered in which the tunica propria directly abuts the basal ends of the epithelial cells; a faint line caused by the apposition of the bases of the epithelial cells alone intervening. It appears in the patches where there is no basement membrane, that the basal cells occasionally give off processes which blend with the connective tissue of the subjacent tunica propria.

(*c*) THE TUNICA PROPRIA (CORIUM)

The tunica propria of the respiratory mucous membrane of the nasal fossae has a framework of interlacing bundles of fibro-elastic tissue, interspersed with many cellular elements, glands, vessels and nerves. While there is no constancy in the histological plan in the various localities of the nasal fossae, one may, in a general way, divide the tunica propria into a superficial stratum and a deep stratum.

The superficial stratum consists of a very loose and sparse fibro-elastic tissue, well shown over the lower part of the nasal septum. The stratum is rich in cells and blood capillaries. Aggregations of lymphocytes, not unlike masses of adenoid tissue, are encountered. Especially in the tunica propria of the nasal conchae as they near the choanae or posterior nares are the lymphocytes massed into small nodules. Clearly, these masses foreshadow the adenoids or pharyngeal tonsils of the adjacent nasopharynx. While most of the cells in the subepithelial or superficial stratum of the tunica propria are of the round cell type, spindle-shaped connective tissue cells, pigment

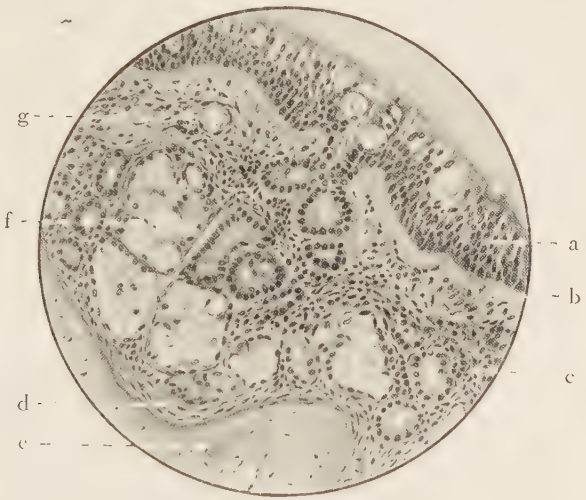

FIG. 14.—The mucous membrane of the superficial surface of the non-olfactory portion of the superior nasal concha. Note the cellular character of the basement membrane and the intimacy between the deep stratum of the tunica propria and the periosteum. (Obj., 4 mm., oc., 10 x, male aged 45 years.) a, epithelium; b, basement membrane; c, tunica propria; d, periosteum; e, bone; f, mucous and serous glands; g, blood vessel.

cells, plasma cells and polymorphonuclear leucocytes are variously encountered. In the deeper stratum, the fibro-elastic tissue becomes more compact and gradually goes over into the periosteum and perichondrium. Many cellular elements, likewise, are present.

An important characteristic of the nasal respiratory mucosa is the extremely rich blood supply of the tunica propria. The arteries of the deeper stratum send their branches into the superficial stratum, forming conspicuous and characteristic capillary loops and a network beneath the epithelium and around the related glands. From the arterial network the blood flows into a superficial venous plexus, thence into a deeper one.

The lymphatics form a wide-meshed capillary plexus, from which emerge small collecting trunks.

(*d*) THE CORPORA CAVERNOSA (THE PLEXUS CAVERNOSI CONCHARUM)

In certain localities of the nasal fossae the stroma or tunica propria of the mucous membrane contains many vascular areas composed of intercommunicating blood spaces that are not unlike cavernous or erectile tissues (Fig. 12). The cavernous tissue would appear to be at its maximum amount and activity during the sexual life of the individual. Paucity of cavernous spaces, normally, appears to go with senility. Of course, certain pathological conditions may result in early changes and it may be difficult to determine the underlying cause.

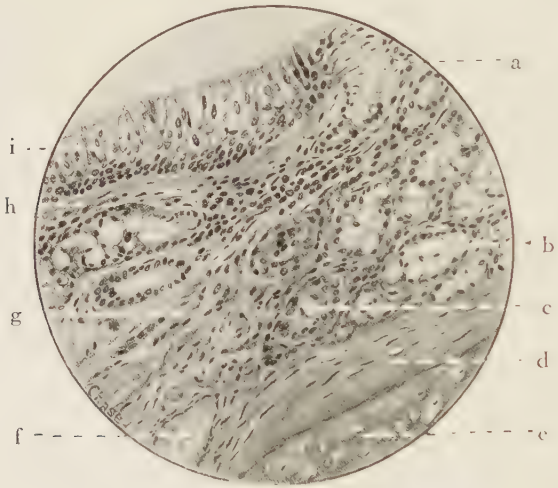

FIG. 15.—The mucous membrane of the nasal septum in the region of the septal cartilage. (Obj., oc., 4 mm., 10 x, male aged 40 years.) a, intra-epithelial gland; b, mucous glands; c, serous glands; d, perichondrium; c, cartilage; f, blood vessel; g, tunica propria; h, basement membrane; i, epithelium.

It would appear certain that intimate physiological and pathological relationships exist between the sexual apparatus and the nose, especially the intranasal erectile tissue. Many clinical observations are extant on the relationship. Mackenzie states that his observations encourage the belief, if they do not establish the fact, that the natural stimulation of the reproductive apparatus, as in coitus, menstruation, etc., when carried beyond its normal physiological limits, or pathological states of the sexual apparatus, as in certain diseased conditions, or as the result of their over-stimulation from venereal excesses, masturbation, etc., are often the predisposing, and occasionally the exciting causes of nasal congestion and inflammation and perversion of the sense of olfaction. Space forbids further discussion of this interesting problem.

The corpora cavernosa are especially well developed over the inferior nasal concha, the overhanging border of the middle concha and the adjacent parts of the nasal septum. Elsewhere the development of the spaces is much less. Where typical, the cavernous tissue occupies the entire thickness of the tunica propria, the larger blood sinuses appearing in the deeper strata and the smaller ones in the superficial reticular stratum.

The interlacunar fibro-elastic trabeculae contain circular and longitudinal bundles of unstriped muscle, glands and blood vessels, the latter on their way into the subepithelial stroma. The nasal blood spaces are not as broken up or crossed as frequently by muscle-containing fibro-elastic septa as the blood spaces of the genitals proper.

There is some evidence that there is an alternate erectility of the mucous membrane of the two nasal fossae. Hemchandra Sen relates an interesting personal observation regarding this phenomenon and states that it was known to the ancient Hindus as early as the Vedic Period. That one nasal fossa may be markedly congested, admitting of little air and the other fairly free, and in a short space of time the condition be reversed, is well known. Whether this should be interpreted as a normal alternate erectility of the nasal mucous membrane is a matter that requires further investigation.

(*e*) THE GLANDS OF THE RESPIRATORY MUCOUS MEMBRANE

The glands of the respiratory nasal mucous membrane are extremely numerous and varied. They differ from the olfactory glands of Bowman in essential details. The simplest of the glands in the respiratory field are short diverticula of the surface epithelium, dipping into the underlying tunica propria (Figs. 12 and 15). These are usually lined with goblet cells resting on a frail basal membrane. The chief glands of the region are of the many-branched, tubo-alveolar type, resembling the glands of the lips (Figs. 12, 13 and 14). Their excretory ducts open on the free surface of the epithelium by small orifices which often can be detected by the naked eye because of the pitting in these places. Not infrequently, deep crypts in the epithelium indicate the site of large gland ducts or actual intra-epithelial glands. The deeper ends of the excretory ducts of the chief tubulo-alveolar glands branch and rebranch irregularly into tubes which bear the terminal ovoid alveoli. The latter are lined with mucus-secreting cells between which frequently are found nests of serous cells. However, purely serous and purely mucous glands are encountered, both in considerable numbers (Figs. 12 and 13).

Small lymph follicles are found in the excretory ducts of the mucous glands, particularly in the glands of the inferior nasal concha. Leucocytic infiltration of the epithelium of the ducts also is seen. Some of the mucous tubules have well-marked crescents of Gianuzzi or demilunes of Heidenhain (Fig. 13).

Widely distributed among the mammals is a more or less fixed and conspicuous gland known as the lateral nasal gland (Glandula lateralis nasi) or the nasal gland of Steno (Stenson). It appears also to have its homologue in reptiles and amphibia. The lateral nasal gland is a single serous gland, of the compound tubulo-alveolar type. Its duct varies in length in accord with the animal, more or less parallels the nasolacrimal duct and opens at the posterior lateral border of the nasal vestibule. In its location it is intimately related to the medial or nasal wall of the maxillary sinus and the nasoturbinal. The gland pours its secretion into the nasal vestibule and appears not to be associated with any function of the maxillary sinus. Bast, in a recent contribution, gives a description of the gland in the dog. He finds it to differ in important details from certain glands on the medial wall of the maxillary sinus and which, contrary to the lateral nasal gland, open into the sinus. While the lateral nasal gland appears not to be present in the adult man, Grosser directs attention to it in the human embryo. The function of the gland is not known.

III. THE VOMERONASAL ORGAN

The vomeronasal organ of Jacobson is found in all amniotic vertebrates. In man it is a rudimentary organ, reaching its height of development during the twentieth week of embryonal development. However, it is found in the newborn child and not infrequently in the adult. It is a flattened tubular structure, from 1 to 6 mm. in length, located just inside the vestibule on each side of the nasal septum. It passes backward into the mucous membrane and ends blindly.

The median wall contains tall columnar cells not unlike the sustentacular cells of the olfactory region of the nose. The lateral wall is composed of cells in consonance with the respiratory mucous membrane. Read finds, in the cat and dog, that the vomeronasal organ is intimately connected with the sense of smell and that its epithelium contains sensory cells identical with the olfactory cells of the nasal fossa. This is also true for other animals, e.g., the rabbit. Read traced a branch of the olfactory nerve to the vomeronasal organ in a child at birth. However, in the adult man the characteristic olfactory cells appear to be absent and the organ associated only with general sensation. The trigeminal and the terminal nerves can be traced to it. Glands may open into its lumen. Space does not permit of further detail in this connection.

IV. THE PARANASAL SINUSES

The paranasal (accessory nasal) sinuses in man are lined with mucous membrane directly continuous with that of the nasal fossa, including the maxillary, the frontal and the sphenoidal sinuses and the cells composing

the ethmoidal labyrinth. In a general way the mucous membrane of the sinuses resembles that of the respiratory region of the nasal fossa, save that it is thinner, contains fewer glands and does not have the erectile tissue in the tunica propria.

1. *The epithelium:*

The mucous membrane of the paranasal sinuses is covered with a stratiform, e.g., a pseudo-stratified ciliated columnar epithelium, invaded by numerous lymphoid elements. The entire thickness of the epithelium is,

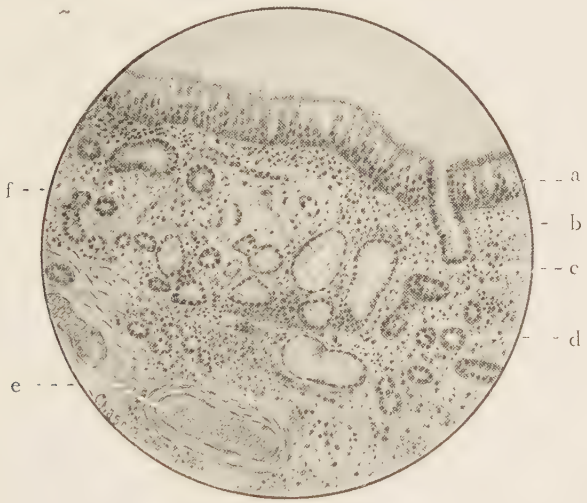

FIG. 16.—The mucous membrane of the maxillary sinus from the medial or nasal wall. (Obj., 4 mm., oc., 10 x, male aged 26 years.) a, epithelium; b, gland duct; c, mucous glands; d, serous glands; e, blood vessels; f, tunica propria.

in most instances, passed through by the tall ciliated cells (Figs. 16, 17, 18 and 19). Only in short stretches and this infrequently, does the epithelium appear to be truly stratified.

The basal end of the ciliated cells is narrow and lies between the conical basal cells. The superficial extremity is much wider and presents definite walls. The cilia are usually prominent, varying in height in the several sinuses from 6μ to 10μ, and project from the free cuticular border. The wave movement of the cilia is strong and is in the direction of the outlet apertures of the several paranasal sinuses. The nuclei of the cells are round, are nearly so, and the cytoplasm granular. Between the ciliated columnar cells are the variously sized conical and low cuboidal basal cells. Most of these reach the epithelial floor as do the ciliated cells but, unlike them, the basal cells never reach the surface. Some appear to be crowded away from the epithelial floor.

Goblet cells, while not nearly as numerous as in the ciliated epithelium of the nasal fossae, are found in all of the sinuses. Much variation, however, exists. They occur in patches, as isolated cells, or are entirely absent over long stretches.

In the epithelium of the maxillary sinus of the dog, Bast reports two additional types of cells. He refers to them as "specially modified cells." *First*, he describes a tall fusiform cell, which he regards as an olfactory cell because of its structure, nerve connection and position at the opening of the sinus into the nasal fossa. The *second* is a broad cell with branched basal

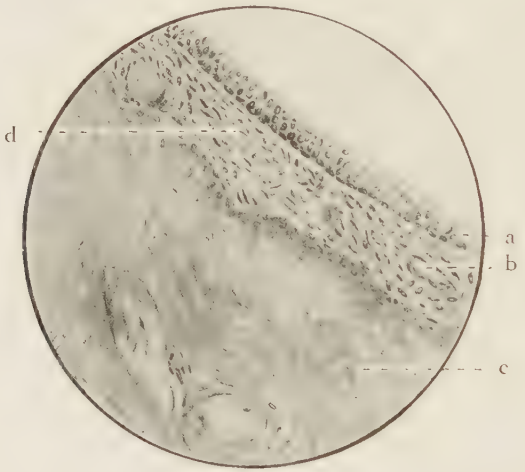

FIG. 17.—The mucous membrane of the frontal sinus. Note the absence of glands. (Obj., 4 mm., oc., 10 x, male, colored, aged 26 years.) a, epithelium; b, blood vessel; c, bone; d, tunica propria, merging with periosteum.

processes which, in many cases, are closely connected with nerve terminations. This cell he believes to be a sensory end organ for special sensation, giving the maxillary sinus in the dog also a dynamic function.

2. *The basal membrane:*

In the paranasal sinuses of man, there is, as a rule, no basement membrane. The epithelium rests directly upon the tunica propria. Only at times, and then in short stretches, is demonstrable a delicate line suggestive of a membrana propria (Figs. 16, 17, 18 and 19).

3. *The tunica propria:*

The tunica propria varies greatly in thickness and structure in the several sinuses and in different localities of the same sinus. It is especially thick and vascular where there are depressions and irregularities in the contour of the bony walls.

It is composed of a loose and delicate connective tissue stroma, interspersed with few elastic fibrils. The connective tissue becomes more compact and robust, the elastic fibrils greater in numbers, as the periosteum is neared. With the latter the tunica propria is inseparably blended. The tunica propria is extremely loose and delicate at times, especially in the sphenoidal sinus (Fig. 19). Large tissue spaces, often distended with body fluids, increase the thickness of the stroma and block the drainage apertures or ostia. While not as vascular as the mucous membrane of the nasal fossae, a goodly number of blood vessels are found in the tunica propria of all the

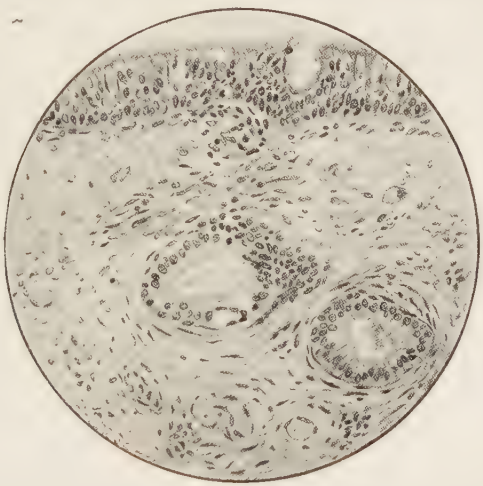

FIG. 18.—The mucous membrane of a posterior ethmoidal cell. Note the presence of a few glands and the total absence of a basement membrane. (Obj., 4 mm., oc. 10 x, male aged 40 years.)

paranasal sinuses. Connective tissue cells, pigment cells, laden with hemosiderin and other matter, polymorphonuclear leucocytes, lymphocytes and not infrequently a goodly number of plasma cells are variously present in the tunica propria. Goodly sized patches of pigment are often found diffused into the connective tissue stroma.

4. *The glands:*

The glands in the mucous membrane of the paranasal sinuses are few in number as compared with the nasal fossae. Not infrequently one examines long stretches which are gland-free (Figs. 17 and 19). Indeed, in a recent study of the sphenoidal sinuses of a child aged nine years, no glands were found save a few near the sphenoidal ostium. The maxillary sinus is an exception in man (Fig. 16). On the medial or nasal wall are found many glands. Most of these are serous in type. However, mucous glands also are found (Fig. 16).

It would appear that the goblet cells assume the rôle of unicellular glands in the paranasal sinuses.

Bast directs attention to peculiar glands on the median wall of the maxillary sinus in the dog. These he finds to be small, compound, alveolar serous glands whose ducts open into the sinus. The secretory granules are different from those of the lateral nasal glands both in size and location. He believes the glands to be related to the function of the maxillary sinus,

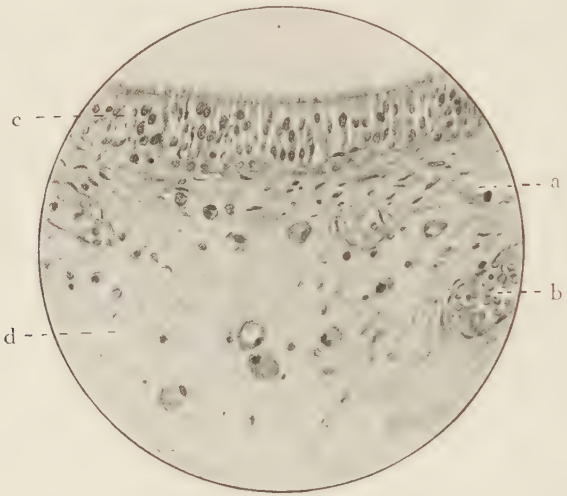

FIG. 19.—The mucous membrane of the sphenoidal sinus. Note the loose character of the tunica propria, the want of a basement membrane and the goodly number of plasma cells. While some of the plasma cells may be present in response to an infectious process, they are normally present in the mucous membrane of the nasal fossae and the paranasal sinuses. The specimen is from a girl aged nine years who died from mastoid disease with secondary involvement of the left cavernous sinus. The specimen was secured two hours after death. (Obj., 4 mm., oc. 10 x.) a, plasma cell; b, blood vessel; c, tunica propria; d, epithelium.

and that their function must be looked for in the lining epithelium of the maxillary sinus on which the secretion is poured: e.g., the tall fusiform cells and the broader cells with branched processes which he discovered in the epithelium of the maxillary sinus (see elsewhere).

V. A PROTECTIVE MECHANISM

It has been estimated that in twenty-four hours over a liter of fluids is supplied by the mucous membrane of the nose. When the function of the glands is impaired, there is a dryness and a tendency to catarrhal states. The great vascularity of the nasal mucous membrane and the secretions of

the nasal glands are the important factors in supplying heat and moisture to the inspired air.

The erectile tissue of the nose, which permits of accumulation of great masses of blood in the mucous membrane, is especially active and engorged when the air is dry and less so when the air is humid.

The mucous membrane of the nose and the sinuses, when in its normal condition, has cleansing and bactericidal properties, whereby the nasal fossae and sinuses become defensive organs against the invasion of bacteria by way of the inspired air. Two prominent physiological factors come into play. First, the action of the ciliated epithelium and second, the bactericidal or surely inhibitory properties of the secretions of the nasal fossae and the paranasal sinuses. The large amount of lymphoid tissue also is a factor. Should these defensive agents be overcome by invading bacteria, infection of the nose and the sinuses is inevitable.

Sir St. Clair Thomson, a noted British clinician, in commenting on the bactericidal functions of the secretions of the nasal glands, emphasizes the importance of respecting the erectile tissue portions of the nasal mucous membrane; arguing that "it is better to be a partial mouth-breather than to have free nasal passages with their protective mechanisms seriously damaged."

VI. THE CHEMICAL COMPOSITION

The chemical composition of the nasal mucous membrane of the ox is reported by Russell and Gies. Transverse sections of the mucous membrane from many oxen, selected at random, yield 77.74 water, 22.26 solid, 21.46 organic matter and 0.80 inorganic matter. The quantity of ether-soluble material is equal to about 8 per cent of the solid matter. Reducing substance is absent from aqueous extracts. Neither proteolytic nor amylolytic enzymes have thus far been detected. The following is quoted from a brief summary of their work:

"Much of the proteid in the tissue dissolves in water and salt solutions. Successive extractions of the fresh tissue in water, 5 per cent sodium chloride and 0.5 per cent sodium carbonate yielded solution from which the following quantities of pure proteid (in terms of percentage of fresh tissue) were precipitated: water 4 per cent; sodium chloride 2 per cent; sodium carbonate 0.5 per cent. A collagenous residue, amounting to 10.5 per cent, remained.

"Conspicuous among the soluble proteids present in the extracts is an acid precipitable material, equal to about 2 per cent of the fresh tissue. Its properties have not yet been distinguished in detail. It appears to be nucleoproteid or a mixture containing nucleoproteid in large proportion. It does not appear to be coagulable. Preliminary tests have failed to show the presence of mucoid in the extracts.

"Nearly 10 per cent of the fresh tissue is indigestible in artificial pancreatic juice and gelatine is readily obtained from this residue. Only about 1 per cent of the fresh tissue remains undissolved in artificial gastric juice. This residue contains nuclein."

VII. BIBLIOGRAPHY

Alagna, G. 1925. Contributo allo studio delle proprieta biologiche del muco nasale. *Valsalva, Milano,* **1,** 381.

Bast, T. H. 1924. The maxillary sinus of the dog with special reference to certain new structures, probably sensory in nature. *Am. J. Anat.,* **33,** 449.

Bauer, T., and Beck, O. 1924. *Atlas der Histopathologie der Nase und ihrer Nebenhohlen.* Leipzig.

Baume, H., and Trautmann, A. 1925–26. Die Lymphgefasse in der Nasenschleimhaut des Pferdes, Rindes, Schweines und Hundes und ihre Kommunikation mit der Nasenhohle. *Anat. Anz.,* **9,** 161.

Beecker, A. 1903. Vergleichende Stilistik der Nasenregion bei den Sauriern, Vögeln und Säugethieren. *Morphol. Jahrb.,* **31,** 565.

Born, G. 1882. Die Nasenhölen und der Tränennasengang der amnioten Wirbeltiere. *Morphol. Jahrb.,* **8,** 188.

Blaue, J. 1884. Untersuchungen über den Bau der Nasenschleimhaut bei Fischen und Amphibien, namentlich über Endknospen als Endapparate des Nervus olfactorius. Inaugural Dissertation, *Arch. f. Anat. u. Phys.,* Anat. Abth., 231.

Braune, W., and Clasen, F. E. 1887. Die Nebenhölen der menschlichen Nase, ihrer Bedeutung für den Mechanismus des Riechens. *Zeits. f. Anat.,* **2,** 1.

Brisotto, P., and Pitzurri, F. 1925. L'influenza del simpatico sui fenomeni vasomotori e secretori della mucosa nasale. *Arch. di farmacol. sper.,* **39,** 251.

v. Brunn, A. 1875. Untersuchungen über das Reichepithel. *Arch. f. mikr. Anat.,* **2,** 468.

——— 1880. Weitere Untersuchungen über das Reichepithel. und sein Verhalten zum Nervus Olfactorius. *Ibid.,* **17,** 141.

——— 1892. Beiträge zur mikroskopischen Anatomie des menschlichen Nasenhöhle. *Ibid.,* **39,** 632.

Bryant, W. S. 1915–16. The transition of the ciliated epithelium of the nose into the squamous epithelium of the pharynx. *J. Anat. and Phys.,* **50,** 172.

Chariton, F. 1905. Beitrag zur Kenntnis der epithelialen Auskleidung des Vestibulum nasi des Menschen und Säugetiere. *Zeits. f. Ohrenheilk.,* **49,** 143.

D'Alise, C. 1925. Funzione masticatoria e sviluppo delle fosse nasali. *Arch. ital. di otol.,* **36,** 501.

Della Vedova, T. 1907. *Monographia e ricerche sulto sviluppo delle cavita nasali nell'-uomo.* Milano. Hoepli.

Disse, J. 1896. Ueber Epithelknospen in der Regio olfactoria der Sauger. *Anat. Hefte,* Abth. 1, 6.

— 1899. Die Ausbildung der Nasenhohle nach der Geburt. *Arch. f. Anat.,* suppl.

Ecker, A. 1855. Ueber das Epithelium der Reichschleimhaut und die wahrscheinliche Endigung des Geruchsnerven beim Menschen und der Säugetieren. *Bericht über die Verhandl. zur Beförd. der Naturwiss. zu Freiburg,* i B 12.

Eckhard, C. 1855. Ueber endigungsweise des Geruchsnerven. *Beitr. z. Anat. u. Phys.,* 1, 77.

Ehrlich, P. 1886. Ueber die Methylenblaureaktion der lebenden Nervensubstanz. *Deutsche Medic. Wochenschr.,* **12,** 49.

Findlay, J. W. 1893–94. A research into the histological structure of the olfactory organ. *J. Anat. and Phys.,* **28,** 387.

Fliess, W. 1897. *Die Beziehungen zwischen Nase u. wertlichen Geschlechtsorganen.* Berlin.

Glas, E. 1904. Ueber intraepitheliale Drüsen, Cysten und Leukocytenhäufchen der menschlichen Nasenschleimhaut. *Arch. f. Laryngol. u. Rhinol.,* **16,** 236.

Goodale, J. L. 1896. An experimental study of the respiratory functions of the nose. *Boston M. and S. J.*, **185**, 457.

Grosser, Otto. 1902. Zur Anatomie des Nasenhohle und des Rachens der einheimischen Chiropteren. *Morphol. Jahrb.*, **29**, 1.

——— 1913. Die Glandula Nasalis lateralis und des Nasoturbinale beim Menschen. *Anat. Anz.*, **43**, 172.

Ha¸ek, M. 1905. Ein Beitrag zur Kenntnis der sogenannten intraepithelialen Drüsen der Nasenschleimhaut. *Arch. f. Laryngol. u. Rhinol.*, **17**, 95.

Hopkins, A. E. 1926. The olfactory receptors in vertebrates. *Jour. Comp. Neurol.*, **41**, 253.

Jacobson, L. 1813. Sur une glande conglomerée appartenante à la cavité nasale. *Nouv. Bull. Sci., Soc. Philom.*, Paris.

Kallius, E. 1905. *Sinnesorgane erste Abteilung. Geruchsorgan (Organon olfactus). Geschmacksorgan (von Bardeleben).* Jena.

——— 1905. Geruchsorgan. *Handb. d. Anat. d. Menschen*, **1**, 2.

Kangro, C. 1884. *Über Entwicklung und Bau der Stenoschen Nasendrüse der Saugetiere.* Dorpat.

Klein, E. 1881. The organ of Jacobson in the rabbit. *Quar. J. Micr. Sci.*, **21**, 549.

——— 1881. Contributions to the minute anatomy of the nasal mucous membrane. *Ibid.*, **21**, 98.

——— 1881. A further contribution to the minute anatomy of the organ of Jacobson in the guinea-pig. *Ibid.*, **21**, 219.

Kölliker, A. 1902. *Handbuch der Gewebelehre des Menschen. Sechste Umgearbeitete Auflage.* Leipzig.

Mackenzie, J. N. 1898. The physiological and pathological relations between the nose and the sexual apparatus of man. *Johns Hopkins Hosp. Bull.*, **9**, 10.

Meyer, Werner. 1904. Beiträge zur Kenntnis der Anatomie und Histologie der lateralen Nasendrüse. *Anat. Anz.*, **24**, 369.

Mihalkowics, V. 1899. Nasenhöhle und Jacobsonsches Organ. Eine morphologische Studie. *Anat. Hefte*, **11**, 34, 35.

Peter, Karl. 1902. Die Entwicklung des Geruchsorgans und Jacobsonschen Organs in der Reihe der Wirbeltiere. Bildung des äusseren Nase und des Gaumens. *Hertwigs Handbuch der Vergleich. und exper. Entw.*, **11**, 2.

——— 1912. Die Entwicklung der Nasenmuscheln bei Mensch und Saugetieren. *Arch. f. mikr., Anat.*, **80**, Abt. 1, 478.

Pietrantoni, L. 1925. Il tessuto connectivo e la lamina basale della mucosa nasale. *Arch. ital. di. anat. e di embriol.*, **22**, 556.

Popper, J. 1925. Zur Histologie der Lymphdrusen bei Sinuserkrankungen. *Zeits. f. Hals-, Nasen u. Ohrenb.*, **12**, 556.

Prenant, L., Bouin, P., and Maillard, Et. L. 1904. *Traité d'histologie, 1. Cytologie.* Paris.

Read, Effie A. 1908. A contribution to the knowledge of the olfactory apparatus in dog, cat and man. *Am. J. Anat.*, **8**, 17.

Russell, B., and Gies, W. J. 1906. On the chemical composition of the nasal mucous membrane. *Sci.*, **23**, 336.

Schaeffer, J. Parsons. 1910. The lateral wall of the cavum nasi in man, with especial reference to the various developmental stages. *J. Morphol.*, **21**, 613.

——— 1920. *The nose, paranasal sinuses, nasolacrimal passageways and olfactory organ in man. A genetic, developmental, and anatomico-physiological consideration.* Philadelphia.

Schafer, E. A. 1912. *Textbook of microscopic anatomy.* (Quain's Anatomy, Ed. 11, **2**, Pt. 1.) London.

Schiefferdecker, P. 1896. Histologie der Schleimhaut der Nase und ihrer Nebenhöhlen. *Handbuch d. Laryngol. u. Rhinol.*, **3**, 87.

Schmidt, V. 1904. Zur Frage über die laterale Nasendrüse bei Saugetieren. *Anat. Anz.*, **25**, 355.

Schneider, Victor C. 1660. *De catarrhis.* Lib. II.

Schultze, Max. 1856. Ueber die Endigurgsweise der Geruchsnerven und die Epithelialgebilde der Nasenschleimhaut. *Monatsber. der königl. Akad. d. Wiss. zu Berlin*, 504.

——— 1862. Ueber den Bau der Nasenschleimhaut. *Abhandl. d. Naturf. Gesellsch. z. Halle*, **7**, 1.

Schwink, F. 1888. *Uber den Zwischenkiefer und seine Nachbarorgane.* München.

Sen, Hemchandra. 1901. Alternate erectility of the nasal mucous membrane. *Lancet*, **2**, 564.

Steno, N. 1664. *De musculis et glandulis.* Amstelodami.

Thomson, Sir St. Clair. 1926. *Diseases of the nose and throat, comprising affections of the trachea and oesophagus.* London.

Todd, R. B., and Bowman, W. 1857. *The physiological anatomy and physiology of man.* Philadelphia.

Trautmann, A. 1911. Zur Frage der Herkunft des Nasenspiegelsekretes des Hundes. *Arch. f. d. ges. Phys.*, **142**, 89.

Van Gehuchten, A. 1890. Contributions à l'étude de la muqueuse olfactive chez les mammiféres. *La Cellule*, **6**, 393.

Wilder, Inez W. 1903. The lateral nasal glands of Amphiuma. *J. Exp. Morph.*, **20**, 144.

Wright, J. 1899. Comparison of the erectile tissue in the nasal mucous membranes of a bull and a bullock. *Tr. Am. Laryngol. Ass.*, **20**, 138.

Zarniko, C. 1903. Ueber intraepitheliale Drüsen der Nasenschleimhaut. *Zeits. f. Ohrenh.*, **45**, 211.

Zuckerkandl, E. 1893. *Normale und pathologische Anatomie der Nasenhohle und ihrer pneumatischen Anhänge.* Bd. 1 and 2, Wien und Leipzig.

——— 1910. Das Jacobsonsche Organ. *Erg. d. Anat. u. Entw.*, **18**, 801.

Zwaardemaker, H. 1897–98. Influence des parfums sur le sens genital. *Intermed. d biol.*, 1, 322.

Section IV

THE EPITHELIUM OF THE LOWER RESPIRATORY TRACT

CONTENTS

Section IV

	PAGE
I. Tracheal and Bronchial Epithelium	71
1. Basal cells	72
2. Intermediate cells	72
3. Ciliated cells	72
4. Goblet cells	72
II. Regeneration	73
III. Stratified Squamous Epithelium	73
IV. Epithelium Bronchioli	74
V. Basement Membrane	77
VI. Alveolar Epithelium	78
VII. Alveolar Reticulum	85
VIII. Alveolar Pores	85
IX. Bibliography	86

Section IV

THE EPITHELIUM OF THE LOWER RESPIRATORY TRACT

WILLIAM SNOW MILLER

IN the following account of the epithelium of the lower respiratory tract my individual investigations are based on a study of the human trachea, bronchi and lungs. For a description of the epithelium in the lower vertebrates, in addition to the authors quoted, the account given by Oppel and the various works on comparative histology should be consulted.

I. TRACHEAL AND BRONCHIAL EPITHELIUM*

By some authors, for example, F. E. Schulze (1871), the epithelium is described as consisting of a single layer of ciliated columnar cells interspersed with goblet cells. Where more than one row of nuclei appears in a

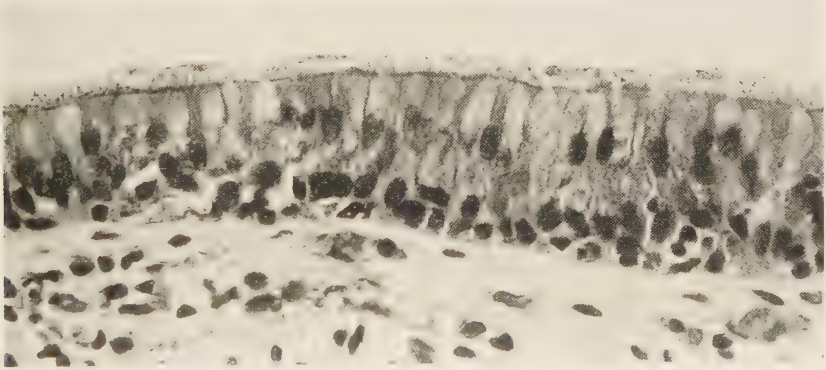

Fig. 20.—Section of the epithelium lining a bronchus 3 mm. in diameter. × 500.

section, those who contend for a single layer say it is due to an oblique section of the epithelium, and call it "pseudo-stratified epithelium." It is true that in the smaller bronchi the epithelium often appears to consist of a single layer, but a close study will enable one to differentiate more than a single type of cells, goblet cells excluded.

There is but little distinction between the epithelium lining the trachea and that lining the bronchi; in each instance the epithelium consists of several rows of cells in which four types can be recognized: (1) basal cells; (2) "Ersatzzellen" or intermediate cells; (3) ciliated cells, and (4) goblet cells. Of these four types the ciliated and goblet cells exceed the others in number (Fig. 20.).

* My study of the epithelium of the trachea and bronchi coincides, in the main, with the results obtained by Kölliker, and I shall make free use of his description.

1. *Basal cells:*

The basal cells form the deepest row of cells and they are situated just above the basement membrane. Their nuclei are sometimes round, sometimes elongated and parallel to the basement membrane on which the cells rest. Dividing nuclei are not often seen. Drasch (1881) has described basal cells as dividing in such a manner that the resulting cells lie one above the other; on the other hand, cells are sometimes seen dividing in the opposite direction.

2. *Intermediate cells:*

The intermediate cells form the second layer and have various forms due to the pressure exerted by the adjoining cells. They are, in general, spindle-shaped and often extend from the basement membrane to the surface of the epithelium. When this is the case, the outer end usually tapers to a point; or it may end in a rounded extremity.

3. *Ciliated cells:*

The ciliated cells of the trachea and the larger bronchi belong to the columnar type of cells; in the bronchioles they belong to the cuboidal type. The outer free ends of the ciliated cells possess a thickened, cuticular border which bears the cilia. Chambers and Rényi (1925) have shown that it is only at this cuticular border that ciliated cells have a continuity. "The apparent continuity between contiguous cells of this type does not seem to be an organic one in the same sense as that which exists in squamous stratified epithelium." Injury of one cell, they find, is not transmitted to adjoining cells. The lower or attached end of the ciliated cells is much smaller than the free end; it may be rounded, or it may be divided into a number of fine prolongations. The ciliated cells extend through the entire thickness of the epithelial layer and their lower ends always reach the basement membrane. At the place where the ducts coming from the mucous glands enter the trachea or bronchi, the ciliated cells line the trumpet-shaped opening and extend some distance into the duct.

As stated by Kölliker (1881), ciliated epithelium extends beyond the point where goblet cells disappear; it does not, however, form a complete layer; for, interspersed with the ciliated cells, there are numerous non-ciliated cells. Moreover, the type of the cilia-bearing cells changes from a columnar to a cuboidal epithelium, which is the predominating type of epithelium in bronchioli between 0.3 mm. and 0.4 mm. in diameter.

4. *Goblet cells:*

The goblet or chalice cells, like the ciliated cells, extend through the entire thickness of the epithelial layer. As their name implies, they often

have an outline which may be compared to that of a goblet; but the pressure exerted by the adjoining cells frequently modifies their outline. Their lower, or attached end, is applied to the basement membrane. This may be expanded into a "foot;" it may end in a pointed prolongation or, like the ciliated cells, in a number of fine prolongations. Their free end varies in outline: sometimes it is widely open; then again it may be contracted into what may be compared to the neck of a bottle. Their nuclei are usually situated on the same plane as those of the adjoining ciliated cells. As a rule goblet cells are more abundant in the larger bronchi than in the trachea. In sections cut parallel to the surface of the epithelium, or in surface views of the epithelium, the position of the goblet cells can be recognized by their clear, more or less round openings, in the midst of the finely granular ends of the ciliated cells. While goblet cells are found abundantly in the larger bronchi, they diminish in number as the bronchi diminish in diameter, and finally disappear in bronchioli of 0.4 mm. in diameter.

Throughout the tracheal and bronchial epithelium scattered lymphocytes are found; but I have not found, in the normal lung, those collections described by some authors.

II. REGENERATION

The basal cells give origin to the restitution or intermediate cells ("Ersatzzellen" of Kölliker; "Keilzellen" of Drasch); and the intermediate cells give origin on the one hand to the ciliated cells, and on the other hand to a lesser number of goblet cells. Drasch (1880) describes the goblet cells as a transitional stage in the development of the ciliated cell from his "Keilzellen." Goblet cells are not infrequently seen with a row of cilia around the circumference of their opening. This seems to indicate that they represent a mucous degeneration of the ciliated cells; a view that is taken by Waller and Björkman (1882), F. Merkel (1902), Knauff (1867) and Kölliker (1881).

The occurrence of mitotic figures in the tracheobronchial epithelium is rarely noted. Bockendahl (1885) has found them scattered through the tracheal epithelium; but he considers regeneration of the epithelium, under normal conditions, to be very inactive, a conclusion previously reached by Henle (1873).

As previously stated, I have occasionally seen basal cells with two nuclei and, in one instance only, I have seen a ciliated cell with two nuclei.

III. STRATIFIED SQUAMOUS EPITHELIUM

The earliest accounts of stratified squamous epithelium in the human trachea, with which I am acquainted, are found in papers by Griffini (1875), and by Baraban (1890). Baraban found areas of squamous epithelium in the

trachea of an executed criminal. It has not been my fortune to find this type of epithelium in the human trachea, but I have found it in the human bronchi. Baraban thinks that the transition of ciliated epithelium into stratified squamous epithelium is due to a low grade of irritation which leads to the loss of the cilia and to the appearance of mucus in the cells.

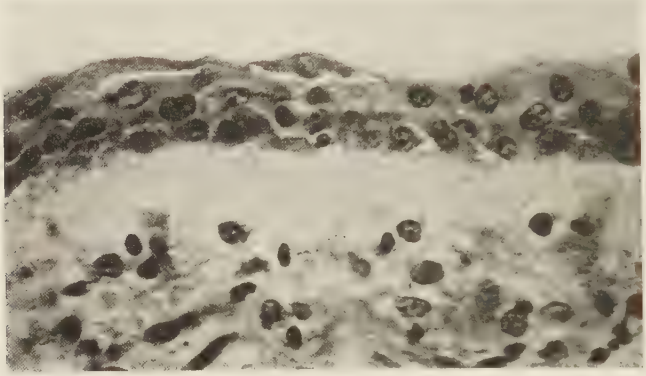

FIG. 21.—Longitudinal section of a bronchus lined with stratified squamous epithelium. From a case of tuberculosis. × 500.

As was the case with Griffini, all the instances in which I have found stratified squamous epithelium in the human bronchi have been from tuberculous lungs (Fig. 21). As suggested by Baraban, it was probably the constant coughing that played the chief rôle in the change from ciliated to stratified squamous epithelium.

IV. EPITHELIUM OF THE BRONCHIOLI

The transition which the epithelium undergoes as the subdivisions of the bronchial tree approach their termination and alveoli appear along their walls forms an interesting study. In bronchioli of 1 mm. in diameter the epithelial layer diminishes in thickness (Fig. 22). Although there can still be recognized the various types of cells described in the trachea and bronchi, the ciliated cells far outnumber the other forms. Only here and there can a goblet cell be distinguished; in many of the basal cells the nucleus is oval, with its long diameter parallel to the basement membrane (Fig. 23). As was the case in the larger bronchi, an occasional lymphocyte can be seen between the epithelial cells.

Previous to the appearance of alveoli along the walls of the bronchioli the character of the epithelium changes. The ciliated cells are now of the cuboidal instead of the columnar type (Fig. 24). The goblet cells have disappeared, but an occasional basal cell is seen. The basement membrane,

when cut transversely, is reduced to a thin line. In a longitudinal section of a bronchiolus which is dividing into bronchioli respiratorii a still further transformation of the epithelium can be followed. The cilia-bearing cells gradually disappear and are replaced by non-ciliated cuboidal epithelium



FIG. 22.—Transverse section of a bronchiolus 1 mm. in diameter. Hematoxylin and eosin staining. × 500.



FIG. 23. -From the opposite side of the same bronchiolus as the one shown in Figure 22, stained by Bielschowsky's method to show that it is reticulum that forms the basement membrane. × 500.

(Fig. 25) which can be best seen in transverse sections of bronchioli respiratorii which have but few alveoli along their walls (Fig. 26).

The non-ciliated cuboidal epithelium persists throughout the bronchioli respiratorii. In longitudinal sections of the bronchiolus it is seen on those small lengths of its wall which are found between the openings of the alveoli into its lumen (Fig. 27).

FIG. 24.—From a section that includes a portion of a bronchiolus 0.4 mm. in diameter. The type of the ciliated epithelium has changed from columnar to cuboidal. The basement membrane is not as thick as in Figure 23. In the lower half of the figure the reticulum in the alveolar walls is shown. A few epithelial cells can be distinguished *in situ*. × 500.



FIG. 25.—Longitudinal section of a bronchiolus 0.35 mm. in diameter. A few ciliated cells of the cuboidal type can be seen on the right of the figure; followed to the left they give place to a non-ciliated cuboidal epithelium. × 500.

In a longitudinal section through the wall of a bronchiolus respiratorius, at the place where it divides into two ductuli alveolares, a still further modification of the epithelium takes place. The cuboidal cells which line the bronchiolus respiratorius gradually become flattened (Fig. 28) and eventually are transformed into the simple squamous epithelium (respiratory epithelium) which lines the walls of the pulmonary alveoli.



FIG. 26. FIG. 27.

FIG. 26.—Transverse section of a bronchiolus respiratorius 0.35 mm. in diameter. Only a few alveoli were present along its walls. × 500.

FIG. 27.—From a longitudinal section of a bronchiolus respiratorius which shows a small portion of the wall of the bronchiolus between the openings leading into two alveoli. The nuclei of three cuboidal cells can be seen, and behind the epithelium, the elongated nucleus of a smooth muscle cell. From a bronchiolus respiratorius 0.25 mm in diameter. × 500.

V. BASEMENT MEMBRANE

The basement membrane of the trachea and bronchi, when any attempt has been made to describe it, has been described as a clear, homogeneous, structureless membrane; as derived from the subepithelial elastic layer; or as made up of elongated cells, placed end to end.

The work of Mall (1891) on the reticulum gave a new conception of basement membranes and their composition. He showed that in the case of the kidney and of the testis, the cells rested on a delicate network of reticulum. Flint (1902), in his study of the submaxillary and other glands, found that the basement membrane in each instance was made up of reticulum; thus confirming the work of Mall.

The introduction of Bielschowsky's method of staining the fibrils of reticulum has simplified the digestion method of Mall for demonstrating these fibrils, and throughout the entire framework of the lung it has been found that it is *reticulum* that forms the basement membranes on which the various types of cells rest.

In the case of the trachea, where the basement membrane is especially thick, a few collagenous fibers can, in some sections, be demonstrated; but

within the lung the basement membrane of all the subdivisions of the bronchial tree is made up wholly of reticulum (Figs. 23 and 24).

VI. ALVEOLAR EPITHELIUM

The presence or absence of an epithelium lining the walls of the pulmonary alveoli has been a much discussed subject. While at first the presence of an epithelium was strenuously denied, later investigations, although they did not agree as to the character of the epithelium, did agree that an epithelium was present. The subject has recently been reopened by the

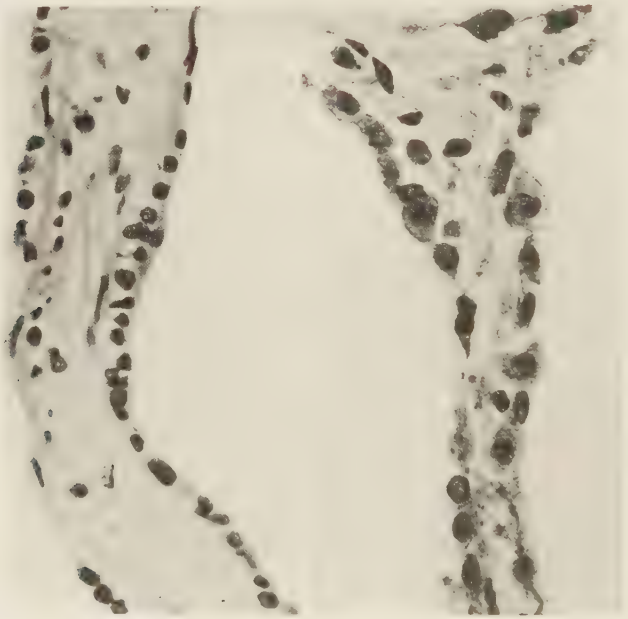

FIG. 28. FIG. 29.

FIG. 28.—On the right side of the section, the transition of the cuboidal epithelium of a bronchiolus respiratorius into the flattened epithelium lining a ductulus alveolaris can be followed; while on the left side of the section a ductulus alveolaris is given off at a slightly higher level than on the right side; consequently the few epithelial cells present are of the cuboidal type. × 500.

FIG. 29.—The swollen epithelium along an alveolar wall (see text). × 500.

denial of any epithelial lining of the alveolar walls other than the non-nucleated plates of Kölliker.

It is now over eighty years since the subject was brought to the attention of both normal and pathological histologists by the papers of Thomas Addison. I do not find any direct statement in regard to alveolar epithelium in his first paper (1837), but in a later publication (1843) he disagrees with

Reisseisen (1822) and others who say "that the air cells are merely the blind extremities of as many bronchial tubes, and that, like the latter, they are lined by an ordinary mucous membrane"; thus implying the absence of any epithelium.

In his study of the membranous walls of the air cells, William Addison (often confused with Thomas Addison) (1842) found that "they possess an epithelium in the form of large, round, nucleated scales, and from one to fifteen or more nuclei may be counted in a single scale. . . . I have never satisfied myself that they possess the ciliated cylinder epithelium so abundant in the trachea and the bronchi."

Williams (1855) confirmed the observation of William Addison; but Rainey (1855) denied the presence of any epithelial lining to the alveolar walls and the long contest regarding the presence or absence, and, eventually, the kind of epithelium present, was under way. Oppel (1905) gives a long, but not always accurate, analysis of the various opinions.

Eventually the contest narrowed down to the question of a continuous layer of squamous epithelium, or one made up of large non-nucleated plates interspersed with islands of small nucleated cells. Chrzonszczewsky (1863) championed the former; Kölliker, in his 1881 paper, the latter arrangement. Of the two opinions, that of Kölliker has, up to the present time, received the support of the majority of investigators.

It will be necessary to review briefly the investigations of Eberth, (1862, 1863, 1864), Chrzonszczewsky (1863, 1866), and Elenz (1864), on the alveolar epithelium of the higher vertebrates, and of Colberg (1863) on the human fetal lung, before considering the work of Kölliker (1881); for their results paved the way for Kölliker.

Eberth described islands of epithelium that occupied the mesh of the capillary network, but did not extend over the capillaries; the capillaries being covered by a structureless membrane. His studies formed the groundwork for the continuance of his investigations by Elenz (1864), one of his students.

Chrzonszczewsky, criticizing the technique of those investigators who denied the presence of an epithelium lining the alveoli, says: "in all these instances the fault evidently lies, not in the lung, but in the method."

As the result of his studies Chrzonszczewsky found, not only in sections taken just beneath the pleura but also in sections taken from the deeper portions of the lung, that the alveoli were lined with a complete, uninterrupted layer of delicate cells, which had a polygonal outline. Oppel says that in Chrzonszczewsky's illustration the cells are too uniform in size and that the nuclei are always in the center of the cell; a criticism that seems trivial, since the drawing is apparently an attempt to represent diagramatically what he saw, and he saw correctly.

Elenz went a step further than Eberth, and, after describing the same islands of epithelium in the capillary network as Eberth, found that the structureless membrane described by Eberth as extending over the capillaries was made up of large, irregular, membranous, non-nucleated plates. By this statement Elenz became the predecessor of Kölliker in ascribing to the alveolar walls two types of cells: groups of small nucleated cells, and large non-nucleated plates.

Elenz, criticizing the work of Chrzonszczewsky, said that his illustration demonstrated that it was the pleural mesothelium, and not alveolar epithelium, that he had stained. In reply Chrzonszczwesky (1866) said, and correctly, that the two in no way resembled each other, and pointed out that Elenz had correctly described and illustrated the distinction between the two types of cells.

Colberg studied the alveolar epithelium in human fetal lungs, and found that, with the growth of the fetus, the epithelium increased only in width and that the cells eventually fused to form an uninterrupted, complete "membrana epithelica," in which only the nuclei of the previously existing cells could be recognized. That Colberg failed to demonstrate the cell boundaries is not surprising; for it is a difficult problem, even with modern technique.

In his paper published in 1866, he sums up his studies as follows: "pathological and comparative anatomical facts show, that, in spite of nearly constant negative results, a complete epithelium must also exist in the adult human lung."

Kölliker, like Elenz, describes the alveolar epithelium as consisting of two distinct types of cells; small, nucleated, flat, rounded polygonal cells which occupy the mesh of the capillary network; and large, variously formed, apparently non-nucleated, very thin plates which rest upon the capillaries but can also extend over their mesh.

His study was made on a lung which was removed from a criminal half an hour after his execution. The lung was injected, through the bronchi, with a weak solution of silver nitrate, and then placed in a 0.5 per cent solution of the same salt. This stained only the pleural mesothelium and some of the superficial alveoli. The lung was next placed in alcohol, and some months (sic) later sections were cut and exposed to the light.

Any one who has had much experience trying to obtain satisfactory stains of the alveolar epithelium with nitrate of silver can readily understand how uncertain its action can be; and Kölliker's illustrations are good examples of its irregular action.

With the general acceptance of Kölliker's description of the alveolar epithelium, all investigation of the alveolar epithelium practically ended, and his illustrations are frequently reproduced.

In a recent publication Lang (1925) goes a step beyond Kölliker, and denies the presence of any epithelium, except the non-nucleated plates, on the alveolar walls. He describes a special cell which he calls a "septum cell." I am yet to be convinced that this is anything but an alveolar epithelial cell which has changed its form through imbibition of fluid, or, possibly, it may be a mononuclear leucocyte which has undergone the same process.

The great obstacle to a correct understanding of the alveolar epithelium is the inability to dissect off the epithelial layer, or to remove it by any artificial means. Colberg tried in vain to isolate his "membrana epithelia," and other investigators have had the same experience.

As the pathological histologist is obliged at times to turn to normal tissues, so the normal histologist is obliged to turn to pathological tissues to

FIG. 30.—Three sections from a series which show, on their right side, the epithelium slightly raised from the surface of the alveolar wall by the exudate behind it. These sections are described in detail in the text. × 500.

obtain a better insight into the material under observation. What Colberg and other workers could not accomplish is often accomplished by pathological processes. Through the pouring out of a serous exudate *behind* the alveolar epithelium in a pneumonia, or in the mechanical edema of mitral stenosis with insufficiency of the valves, the *vis à tergo* pushes off the epithelium.

In a section through an alveolar wall in which a small amount of edema is present (Fig. 29), the epithelium lining its walls is but slightly raised from

FIG. 31.—The wall of an alveolus from which the epithelium has been pushed off along its upper side by the accumulation of serum behind it, while along the lower side it is still, although somewhat swollen, attached to the alveolar wall. × 500.

its surface; the individual cells are swollen, due to the imbibition of the serous exudate. In various places, on each side of the alveolar wall, epithelial cells are overlaid by other epithelial cells; this gives them the appearance of having two nuclei. The sections of the capillaries and their relation to the epithelium are interesting. The capillary near the center of the section has, on its right, the nucleus of an epithelial cell, while on its left there is the thin, expanded part of an epithelial cell.

Eberth, Elenz, Schulze, and Kölliker state that only the non-nucleated plates cover the capillaries; a statement which this, and numerous other sections, show to be incorrect. In the upper portion of the section two other capillaries appear; the lower of the two contains a mononuclear leucocyte turned up edgewise, while the upper one shows an endothelial nucleus cut transversely.

In order to show the relation of the nucleus to the thin, expanded portion of the cell, and the changes in the appearance of the same epithelial cell at different levels, three sections from a series are shown in Figure 30. The sections are 7μ in thickness, and between "a" and "b," and between

"b" and "c," a section has been omitted on account of its being stained for the reticulum. These three sections represent, therefore, 35μ of the alveolar wall. More sections could have been used, but they would only repeat what is shown in these three sections.

The amount of the serous exudate is greater in Figure 30 than in Figure 29, and, as a consequence, the cells are pushed further away from the alveolar wall. Some of the cells, especially on the left of Figure 30a, have absorbed a considerable quantity of fluid and are assuming a spherical

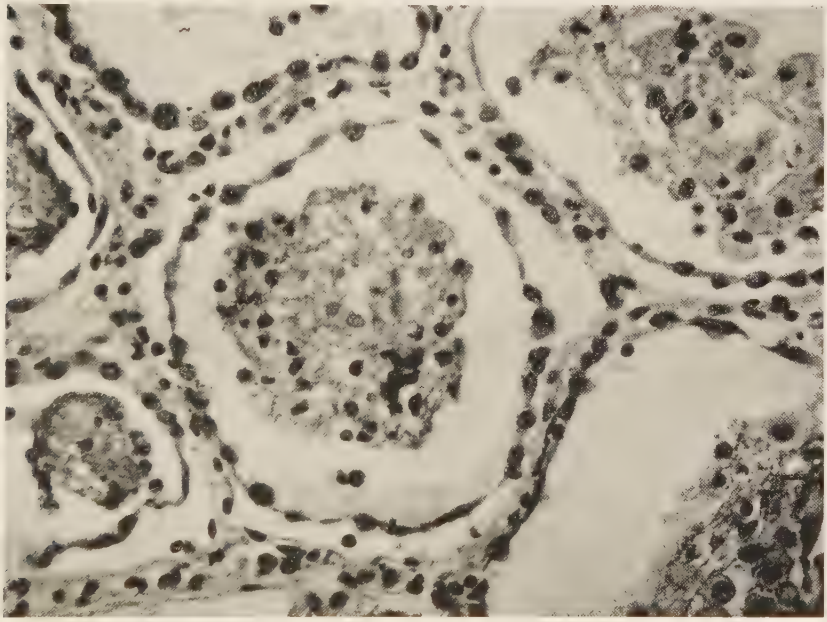

FIG. 32.—The epithelium lining the alveolus in the center of the figure has been pushed off as a continuous sheet. Certain of the cells are more swollen than others. The alveolus in the upper right of the figure shows clearly the epithelium before and after an exudate has raised it from the surface of the alveolar wall. For a further description of the figure see the text. × 375.

form. As soon as a chain of these cells breaks apart, the individual cells float into the lumen of the alveolus and become the large round cells so frequently seen.

In Figure 30b, some of the cells show either the lower, or the upper, edge of nuclei which are cut nearer the center in "a," or in "c." In Figure 30c, in which individual cells are well shown, the spindle shape of the cells before any considerable amount of fluid is absorbed is clearly shown.

When these three sections are considered as a whole, they point to the fact that, in the normal lung, the epithelium lining the alveolar walls is

made up of thin, flattened, nucleated squames, which are closely applied to the alveolar wall, and that *it is a continuous epithelium.*

Figure 31 is from the same series as Figure 30, but is from an alveolus some distance from the one shown in Figure 30. Along the upper border of the section the cells have been pushed off some distance from the alveolar wall, while on the under side most of the cells are still *in situ*, though somewhat swollen. Here again evidence is shown that it is a continuous, nucleated epithelium that lines the alveolar walls.

One of the most interesting examples I have found, illustrating this pushing off of the epithelium from the alveolar walls by the accumulation of an exudate behind it, is from a case of pneumonia (Fig. 32). The epithelium lining the alveolus in the center of the figure has been pushed off as a complete and continuous sheet. Certain of the cells have absorbed a larger quantity of fluid than others; consequently they have assumed a more spherical outline.

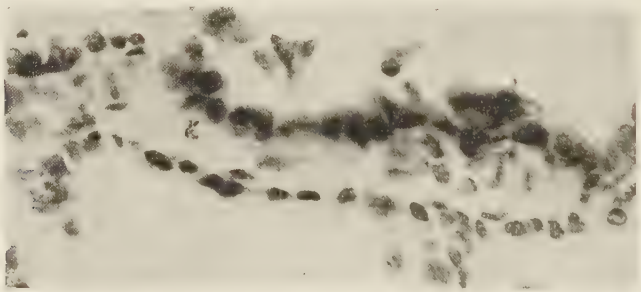

FIG. 33.—From a torn section of a normal, partly collapsed lung. The alveolar epithelium has been pulled off as a continuous sheet. × 500.

The alveolus in the upper right quadrant of Figure 32 is of even more interest. Along the lower border of the alveolus the epithelium has been pushed off from the alveolar wall, and the cells show a moderate degree of swelling. As these cells are followed around the left side of the alveolus, it can be seen that the epithelium is closely applied to the alveolar wall and that the nuclei show but faintly. In other words, on the left side of the alveolus the epithelium is in its normal position, a thin, continuous sheet with its nuclei, like the cells themselves, stretched out and staining faintly; while along the lower border the epithelium has been pushed off the alveolar wall by the exudate. The epithelium in the other alveoli also shows interesting stages in the position and form of the cells.

In Colberg's 1866 paper there is an illustration similar to Figure 32. I had not seen this at the time I published my paper in *The Journal of Experimental Medicine* (1925), and I take this opportunity of calling attention to it.

Not infrequently imperfect sections show a given point to better advantage than perfect sections. In a section through a bronchiolus, of an imper-

fectly distended lung, the somewhat "demoralized" section (Fig. 33) shows the epithelium torn off as a continuous sheet along the upper wall of the larger alveolus, while the few cells in the alveolus at its right show, by their cuboidal shape, that the lung is partly collapsed; for in sections taken through an atelectatic area of a lung, the alveoli are found to be lined with a continuous cuboidal epithelium and only the absence of smooth muscle prevents their being mistaken, in many instances, for sections of bronchioli. Here again, the evidence points to a *continuous* epithelium lining the pulmonary alveoli.

VII. ALVEOLAR RETICULUM

The epithelium of the alveoli, like that of the bronchi and bronchioli, rests upon a network of reticulum (Fig. 24). The alveolar epithelium stains more faintly with Bielschowsky's stain than the epithelium of the bronchioli; but here and there along the alveolar walls, as marked out by the reticulum, an epithelial cell with its nucleus can be seen. In other places the faint outlines of epithelial cells appear. The upper wall of the smaller of the alveoli has been cut obliquely, and the network of reticulum in its wall is indistinctly shown. In the lower wall of the same alveolus a transverse section of a capillary, with an epithelial cell just outside its wall, can be seen.

VIII. ALVEOLAR PORES

Kohn (1893) aroused renewed interest in these minute openings through the alveolar walls, which had been previously described by Henle (1873), by calling attention to the fact that in pneumonia threads of fibrin could be traced, from one alveolus into an adjoining alveolus, through these openings.

That these openings were normal, pre-formed openings was maintained by Hansemann (1895, 1900), Schulze (1871), Marchand (1912), and other investigators; while a larger group of investigators, among whom were Ribbert (1894), Aigner (1899), v. Ebner (1902), and Miller (1923, 1925), maintained that they were not normal structures. Flint (1907), in his study of the development of the lung, states emphatically that pores are not normal structures.

In the preceding subdivision it has been shown that there, is in the normal lung, a complete lining of epithelium on each side of an alveolar wall. So long as this remains intact no pore can exist. The shedding of the epithelium on one side of an alveolar wall will not give rise to a pore. It is only when the epithelium is shed on diametrically opposite sides of an alveolar wall that a pore can be formed.

I have discussed this question in two previous publications, and have there shown that it is not only in pneumonia, where they have been so fre-

quently described, but also in the mechanical edema of mitral stenosis with insufficiency of the valves, that pores exist. In each instance the epithelium has been pushed off, by the *vis à tergo*, from diametrically opposite sides of the alveolar wall. In edema pores are more difficult of demonstration than in pneumonia, because there are no fibrin threads to direct attention to them.

IX. BIBLIOGRAPHY

Addison, T. 1837. Observations on the diagnosis of pneumonia. *Guy's Hosp. Rep.*, **2**, 56.

——— 1843. Observations on pneumonia and its consequences. *Ibid.*, S. 2, **1**, 365.

Addison, W. 1842. On the ultimate distribution of the air passages, and the formation of the air cells of the lungs. *Phil. Trans.*, **2**, 157.

Aigner, A. 1899. Ueber Trugbilder von Poren in den Wänden normaler Lungenalveolen. *Sitzungsber. d. Akad. d. Wiss. Wien, math.-nat. Kl.*, Bd. **108**, Abt. 3.

Baraban, L. 1890. L'épithelium de la trachée et des bronches chez un supplicié. *Rev. méd. de l'est*, **22**, 545.

Bockendahl, A. 1885. Ueber die Regeneration des Trachealepithels. *Arch. f. mikr. Anat.*, **24**, 361.

Chambers, R., and Rényi, G. S. 1925. The structure of the cells in tissues as revealed by microdissection. I. The physical relationships of the cells in epithelia. *Amer. Jour. Anat.*, **35**, 385.

Chrzonszczewsky, N. 1863. Ueber das Epithel der Lungenbläschen der Säugetiere. *Würzburger med. Zeitschr.*, **4**, 206.

—— 1866. Zur Lehre von dem Lungenepithel. *Arch.* f. *pathol. Anat. u. Physiol.*, **35**, 165.

Colberg, A. 1863. *Observationes de penitore pulmonum structura et physiologica et pathologica.* Halis.

——— 1866. Beiträge zur normalen und pathologischen Anatomie der Lungen. *Deutsch. Arch. f. klin. Med.*, **2**, 453.

Drasch, O. 1880. Die physiologische Regeneration des Flimmerepithels der Trachea. *Sitzungsber. d. Wiener Akad. math.-nat. Kl.*, **3**, 1 (Oct. Heft, 1879).

— — 1881. Zur Frage der Regeneration des Tracheaepithels, mit Rücksicht auf die Karyokinese und die Bedeutung der Becherzellen. *Ibid.*, **3**, 341.

Eberth, C. J. 1862. Der Streit über das Epithel der Lungenbläschen. *Arch. f. pathol. Anat. u. Physiol.*, **24**, 503.

— — — 1863. Ueber den feineren Bau der Lunge. *Zeitsch. f. wissensch. Zool.*, **12**, 427.

——— 1864. Zu den Kontroversen über das Lungenepithel. *Würzburger naturwiss. Zeitschr.*, **5**, 84.

Ebner, V. v. 1902. In Kölliker, *Handbuch der Gewebelehre des Menschen.*, Aufl. 6, Leipzig, p. 280.

Elenz, E. 1864. Ueber das Lungenepithel. *Würzburger naturwiss. Zeitschr.*, **5**, 66.

Flint, J. M. 1902. The development of the reticulated basement membranes in the submaxillary gland. *Amer. Jour. Anat.*, **2**, 1.

—— 1907. The development of the lungs. *Ibid.*, **6**, 1.

Griffini, L. 1875. Contribuzione alla patologia generale dell tessuto epitelico cilindrico. *Osservatore della cliniche di Torino*, **11**.

——— 1884. Contribution à la pathologie du tissu épithélial cylindrique. *Arch. ital. de biol.*, **5**, 247.

Hansemann, D. 1895. Ueber die Poren der normalen Lungenalveolen. *Sitzungsber. d. Preuss. Akad. d. Wiss.*, **9**, 451.

Hanseman, D. 1900. Ueber Victor von Ebners Zweifel an der existenz normaler Poren zwichen den Lungenalveolen. *Arch. f. mikr. Anat.*, **55**, 337.

Henle, J. 1873. *Handbuch der Anatomie des Menschen.* Bd. 2, Braunschweig.

Knauff, F. 1867. Das Pigment der Respirationsorgane. *Arch. f. pathol. Anat. u. Physiol.*, **39**, 442.

Kölliker, A. 1881. Zur Kenntnis des Baues der Lunge des Menschen. *Verh. d. physik.-med. Ges. zu Würzburg*, N. F., **16**, 1.

Kohn, H. N. 1893. Zur Histologie des indurirenden fibrinösen Pneumonia. *Münch. med. Woch.*, **40**, 42.

Lang, F. J. 1925. The reaction of lung tissue to tuberculous infection in vitro. *Jour. Infec. Diseases*, **37**, 430.

Mall, F. P. 1891. Das reticulirte Gewebe und seine Beziehung zu den Bindegewebsfibrillen. *Abhand. d. math.-phys. Kl. d. Kgl. Sächs. Gesellsch. d. Wissensch.*, **17**, 299.

Marchand, R. 1912. Les pores des alvéoles pulmonaires. *Bibliog. Anat.*, **22**, 57.

Merkel, Fr. 1902. Atmungsorgane. In Bardeleben, *Handbuch der Anatomie des Menschen.* Jena.

Miller, W. S. 1892. The lobule of the lung and its blood vessels. *Anatom. Anz.*, **7**, 181.

——— 1923. A study of the factors underlying the formation of alveolar pores in pneumonia. *Jour. Exper. Med.*, **38**, 707.

——— 1925. The alveolar pores of pneumonia. *Jour. Exper. Med.*, **42**, 779.

Oppel, A. 1905. *Lehrbuch der vergleichenden mikroskopischen Anatomie.* Sechter Teil, Atmungsapparat, Jena.

Rainey, G. 1855. Critical examination of the evidence for and against the presence of epithelium in the air cells of the human lung. *Brit. and Foreign Med. Chirurg. Rev.*, **16**, 491.

Reisseisen, F. D. 1822. *Ueber den Bau der Lungen.* Berlin.

Ribbert, H. 1894. Zur Anatomie der Lungenentzüngen. *Fortschr. d. Med.*, **12**, 371.

Schulze, F. E. 1871. Die Lungen. In Stricker, *Lehre von den Geweben des Menschen und der Tiere.* Leipzig.

Waller, C., and Björkman, G. 1882. Studien über der Bau der Trachealschleimhaut mit besonderer Berücksichtigung des Epithels. *Biol. Unters. von Retzius*, **2**, 71.

Williams, T. 1855. Epithelium of the air cells of the human lungs. *Med. Times and Gaz.*, N. S., **11**, 361.

——— 1859. Organs of respiration. In Todd, *Cyclopaedia of Anatomy and Physiology*, **54**, 258. (Suppl. Vol.) London.

Section V

THE SALIVARY GLANDS

CONTENTS

Section V

	PAGE
I. Classification of Salivary Glands	92
II. Mucous Cell	94
III. Serozymogenic Cells	98
IV. Special Serous Cells	102
1. Demilune cells of submaxillary glands of cat and dog	104
2. Submaxillary gland of rodents	107
3. Special serous cells of retrolingual gland of dog	111
4. Submaxillary gland of insectivora	111
V. Duct Elements	113
1. Intercalated ducts	113
2. Intralobular duct cells	113
3. Ducts as sources of water and reaction spaces	114
VI. Development of Salivary Glands	115
VII. Innervation	115
VIII. Blood Supply and Lymphatics	123
IX. Salivary Glands of Man	123
1. Parotid gland	125
2. Submaxillary gland	127
3. Sublingual glands	128
X. Bibliography	129

Section V

THE SALIVARY GLANDS

D. L. STORMONT

IN using the term "salivary glands" reference is made to that group of serous, or seromucous glands that occupy positions in proximity to the buccal cavity. These cell groups arise as solid outgrowths from the oral epithelium. Secondarily, these cords acquire a lumen, or cavity, around which these cells may assume a more or less definite arrangement.

FIG. 34.—Dissection of adult human salivary glands of the right side, with resection of portion of mandible. Columbia University Morphological Museum, #1949. (After Carmalt.) 1, Submaxillary gland; 2, Lesser subligual and isthmian gland; 3, Parotid gland; 4, Parotid duct carrying dorsal accessory parotid labules; 5, Facial vein; 6, Lymphatic nodes.

Although the salivary glands also include the smaller glands of the buccal cavity, it will be our purpose to limit this account chiefly to the parotid, submaxillary and sublingual glands.

The topographical relationships of the major salivary glands can be seen in Carmalt's dissection of the superficial structures of the face (Fig. 34).

In general, the morphological plan of a salivary gland is similar to other glands. It consists of (1) one or more large excretory ducts with smaller contributing ducts, or interlobular ducts, which branch into the ultimate lobule, forming the intralobular duct; this in turn connects with the small intercalary duct leading away from the gland alveolus; (2) the secretory alveoli grouped as lobules or masses of cells around the terminations of the ducts; (3) a generous gland stroma of connective tissue, which serves as a conduit for nerves, blood and lymph vessels, and also as a covering of the individual and collective lobules of the gland, and (4) a membrana propria, or basement membrane, upon which rests the glandular epithelium.

The membrana propria in direct contact with the glandular cells consists of two elements; viz., the incomplete layer of stellate cells ("Korbzellen" of Boll, 1869), and the connective tissue layer upon which these and the glandular cells rest. The stellate cells were first observed by Krause (1895) but have been studied by Kölliker, Boll, Pflüger, v. Ebner, Ranvier and many others. They consist of a syncytium of branched cells lying in close contact with the bases of the glandular cells and embracing the acinus in the form of a basket-work of processes. Between these processes the glandular cells are in contact with the connective tissue membrane. The nature and function of the Korbzellen is unknown. Whether they are derived from mesenchyme, or, as suggested by Kolossow, are modified epithelial elements, has not yet been determined. Unna compared them with the muscular cells which are found in the sweat glands, a view which is shared by Renaut and also by Kolossow who frankly called them "musculoepithelial cells" and accepted their epithelial origin. In considering the effect of stimulation of the nerves of the gland, these cells are of much importance, but further research is necessary to demonstrate their presumed contractile nature. Lacroix, who studied similar cells in the mammary gland, states that their protoplasm has a fibrillar structure, a fact also confirmed by Renaut.

The connective tissue portion of the basement membrane, according to the researches of Flint (1903), is composed of a thin layer of closely woven reticular fibers in the sense of Mall.

I. CLASSIFICATION OF THE SALIVARY GLANDS

The classifications which have been proposed for the salivary glands have been of little help in the biological analysis of these structures. Since the differences between the ultimate components of the glands, namely, the secreting cells, cytologically considered, are those imposed upon them by the nature and history of the substances which they elaborate, rather than fundamental differences in the structure of the cytoplasm or the external relations of the cells, the attempt made by Heidenhain (1868) to classify them on a functional basis according to the qualities of the secretion they deliver has, perhaps, been of the greatest service; although it must be recognized that this classification has in some measure also obstructed investigation by reason of the erroneous implications attached to it by those who followed Heidenhain. Heidenhain recognized that the salivary

glands could be divided into two groups depending upon whether they secreted a solution containing mucus, or a solution of albuminous materials not containing mucus. The former he termed "mucous glands," the latter "albuminous glands." The same groups were termed by A. Heidenhain (1870) respectively "mucous glands" and "serous glands," and one of the chief efforts of histophysiologists since that time has been to determine whether a given gland belonged to one or the other of these categories or contained elements belonging to both. Thus we have the mucous glands, serous glands and mixed glands. The discovery of an active enzyme in the secretion of some of the serous glands added a new significance to the group, and new responsibility to the investigator, because the presumption that a serous gland was also a zymogenic gland became so strong that it was often taken for granted, although the evidence available was not convincing. The prozymogen of Bensley, the basal filaments of Solger and the chromidial substance of Hertwig are presumably all one and the same. The chromidial substance may present a radial appearance, and in all probability has its origin partly in the nucleus. Both zymogen granules and the chromidial substance give positive tests for iron and phosphorus (Macallum).

The zymogenic cell shows characteristic chemical differences from the mucous cell, which permit differentiation between the two (Bensley). It had become increasingly apparent, as the results of research have accumulated, that both of the major classes proposed by Heidenhain contained several kinds of secretory cells, that these classes were really heterogeneous and that the only information really conveyed was whether a cell secreted mucus or not. In particular the submaxillary gland of the hedgehog may be mentioned in this connection. Krause (1895) described in this gland two types of cells, one of which resembles cytologically the mucous cell, the other the serous cell, but the gland contained no mucin, and the serous cell differed in some important characteristics from the conventional serous cells of the parotid gland of the rabbit. Similarly the submaxillary gland of the rabbit contains two types of cells which are non-mucous according to Heidenhain (1868), but differ markedly from the serous cells of the parotid.

Attempts to expand the classification have been more or less unsuccessful, chiefly because they have not covered a wide enough field of comparative study.

Bensley (1908) proposed the subdivision of the serous cells into "homeochrome" and "tropochrome" on the basis of the metachromatic staining of the latter after fixation in formalin solutions, and M. Heidenhain (1919–1920) used the word "amphitrope" to indicate a similar property in the salivary demilunes of man. Bensley, however (personal communication), does not advise the general adoption of this subdivision, because it has not been tested on a sufficient variety of glandular cells to determine whether

there may be intermediate types forming a gradient between the homeochrome and tropochrome divisions. Until more precise biochemical information is available, little progress can be made. In the meantime it is obvious that the best that can be done is to describe as accurately as possible those cell types which constitute well-defined categories, and to leave many of the types for the present "incertae sedis." The mucous cell on the one hand, and the serozymogenic cell—the prototype of which is the acinous cell of the pancreas—seem to be such types, and will therefore be considered among the topics to be discussed first.

II. THE MUCOUS CELL

By "mucus" we mean a solution of mucin, which is a glycoproteid. There may be different kinds; e.g., mucins which have a different nitrogen content, such as that of the submaxillary, as compared with the content of the mucous cells of the gastric mucosa. Mucous cells do possess secretion granules, but do not contain any noticeable chromidial substance, or at best only a trace, as determined by the organic iron tests. They give negative results to the phosphorus test. Mucous or mucin-like cells may be stained by Mayer's mucicarmine method, and show a marked contrast to serous cells. The mucin reaction is non-specific and non-microchemical.

The only method by which a mucous gland may be recognized with certainty is by collecting its secretion and examining it chemically for mucin, or, where this is impossible, by the chemical examination of extracts of the gland made by the methods employed by Hammarsten (1885) in studying the submaxillary mucin of the ox. If either of these tests gives a positive result, then it may be assumed that the gland in question contains mucus-secreting cells, due allowance having been made for the presence of mucoid substances of connective tissue origin. If the gland consists of only one type of cell, the problem is a simple one; but if, on the contrary, several obviously different types of secreting cells are present, then other devices must be adopted to differentiate the mucous cells from others which are non-mucous. It should be emphatically stated at this point that morphological differences, like those often referred to in textbooks, may be wholly misleading, and may result in incorrect conclusions. Furthermore, no character, either of the fresh material or of the fixed material other than a true microchemical reaction, which we do not possess at present, can be trusted by itself as a criterion for the recognition of mucous cells. Several properties, however, taken in conjunction with one another, may afford a mass of evidence which has considerable presumptive value, and which, when added to the actual demonstration of a mucin in the gland or in its secretion, justifies the conclusion that certain cells of the glands are the mucus-producing cells. These properties are as follows:

1. In the fresh condition as noted first by Langley* the mucous cells contain the antecedent of the mucin in the form of minute droplets (granules of Langley) of so low a refractive index that they are difficult to see except with the best optical equipment. These droplets are frequently so labile that they change rapidly under the eye, the whole cell changing its appearance, and the droplets are lost to view. If the fresh material be examined in serum from the same species or in aqueous humor, the change is delayed, and the droplets may be kept under observation for some time. The lability of these antecedent droplets, which is often retained after fixation, makes their subsequent study more difficult; but the introduction of formaldehyde fixatives has been helpful. Bensley (1903) found, in the case of the glands of Brunner of the opossum, that merely floating the paraffin sections on water to extend them would change the whole aspect of the intracellular contents in material fixed in a sublimate-bichromate-alcohol mixture.

2. The secretion antecedent in many mucous cells stains metachromatically in thionin (Hoyer, 1890), and many other hydrochlorides of color bases, as, for example, toluidine blue, safranine, cresylechtviolet and several others. That is to say, the mucin antecedents stain reddish in the blue dyes, yellowish in the red dyes, etc. The nature of this metachromatism is unknown. The reaction is discharged by alcohol, or glycerin; but, as Krause (1923) has pointed out, may be fixed rather unsatisfactorily by potassium ferrocyanide. This reaction is not given by all mucous cells. Cells known on chemical grounds to be mucous cells may in one animal give the metachromatic reaction, while the homologous elements from another species may prove negative. The metachromatic reaction is also given by non-mucous elements, as, for example, the granules of mast cells, and the secretion in Bensley's tropochrome cells of the salivary glands after special fixation.

3. The secretion antecedents in the mucous cell stain blue with Mayer's muchematein and red with Mayer's mucicarmine. It had long been known that well-ripened hematoxylin solutions in alum water stain goblet cells blue; but it remained for Paul Mayer (1897) to investigate this property of hematoxylin, and to devise solutions which would color with certainty many mucins and would not stain other substances. These solutions are the ones mentioned above. In this connection it must be remembered that there are many mucins, and, further, that the staining of them is an absorption phenomenon depending on gel concentration and on degree of dispersion of the coloring substances as well as other factors. This being the case, it is not surprising that some mucins are difficult to stain, or that certain intracellular secretion products which are known not be to mucin give a positive result. As an illustration of these limitations it may be mentioned that in order to stain with certainty the mucous neck cells of the gastric gland,

* For an extensive study of the behavior of mucin granules, see Langley (1889) and Metzner (1907).

Bensley (1898) had to increase the concentration of Mayer's solution fivefold. On the other hand, Sundwall found that certain cells of the lacrimal gland of the ox stained perfectly in both of Mayer's solutions, although extracts of the glands showed the presence of only a trace of mucin sufficiently accounted for by the presence of goblet cells along the ducts.

4. Using muchematein as an indicator, the solubility of the secretion antecedents in alkali may be tested in material fixed for only a brief period in alcohol. The sections may be tested with muchematein, then treated with weak alkali and tested again from time to time to see whether the stainable material is being dissolved out.

5. The mucous cells have in their cytoplasm only a minute amount of the basophile material so abundant in the chief cells of the gastric glands and in the pancreatic acinous cells. By the ordinary staining methods it is impossible to satisfy oneself that any of this material exists, but Macallum's microchemical reaction for masked iron usually reveals a trace. This material will be more fully discussed in connection with the serozymogenic types of cells.

6. In general, the mucous acini, or those portions of mixed acini which contain mucous cells, do not display intercellular secretion canaliculi.

Observations on the cytoplasm of the mucous cell present great difficulties in the fresh cell on account of the fact that the cell is so highly charged with mucin granules that the other elements are obscured. According to Noll (1902), however, small darker granules may be seen among the mucin granules. These, by reference to fixed preparations, are in all probability the fuchsinophile granules of Maximow (1901) or the mitochondria (chondriosomes or plastosomes of later authors). No data are available as to the consistence of the intergranular protoplasm, and with the exception of the small granules mentioned, and in some cells of fat droplets, no structural differentiation is seen. According to Langley, the nuclei are usually not visible in the fresh cell. In the fixed material the aspect of the cell is contingent on the methods employed and on whether or not the granules of secretion or their products are preserved. In the usual preparation, fixed in sublimate solutions and stained with hematoxylin and eosin, the cell presents the classical appearance of a wide meshed network, with a shrunken nucleus at its base and about it a small accumulation of cytoplasm. The cytoplasm, in this case, is represented by the trabeculae of the network, and the lateral and basal condensations of it. The trabeculae, in such inadequately fixed preparations, are not wholly cytoplasmic in nature as they are doubled by the precipitated material which in the fresh cell constituted the secretion granules. Maximow (1901), by means of Podwyssotzky's fluid (Flemming's chrom-osmium acetic solution saturated with sublimate), was able, in the mucous cells both of the submaxillaris and retrolingualis of the dog, to preserve the mucous granules in their original

form. Accordingly his figures correspond well with those of the living cell. Metzner (1907) and Arima (1918), also, by other fixing fluids containing osmic acid, accomplished the same result. In such preparations the mucous cells are found studded closely with large stainable granules which are separated from one another by thin protoplasmic partitions. In these preparations of Noll (1902), Takagi (1925) and others show minute mitochondrial threads. In the retrolingual gland of the dog, Maximow found that these cytoplasmic partitions in the portion of secretion nearest the nucleus were much denser, and that as the cell discharged itself (paralytic secretion) the secretion was divided clearly into two disimilar zones, both of which were finally discharged. This observation accords with that made by Bensley in the cells of the glands of Brunner, regarding which he advanced the hypothesis that the new secretion was formed in the interior of the cell near the nucleus and in the territory occupied by the canals of Holmgren (1903). Similar observations have been recently made in a vast number of different glandular cells by Nassonov (1924b) and Bowen (1926), using the methods of Kolatchev (1916) for the demonstration of the Golgi apparatus. They find in general a close relation between the Golgi apparatus and the newly formed granules, from which they deduce a direct participation of the Golgi apparatus in the formation of secretion. Their observations seem to show, also, that the Golgi apparatus in some glandular cells at least loses a portion of its substance to the newly formed secretion granule. The observation of these authors is of the utmost importance as indicating a definite participation of the Golgi reticular apparatus in the chemical activities of the secreting cell. The elucidation of the nature of this participation remains a fascinating task for future research.

In Metzner's and Arima's preparations some of the granules of the mucous cell stained more intensely in toluidine blue than the general mass. These might be interpreted as granules in an earlier stage of preparation. In the retrolingual gland of the hedgehog, a pure mucous gland, Krause (1895) discovered that cells which did not contain mucin contained in sublimate preparations a protein substance in the form of minute granules which were colored red when stained by the Biondi-Heidenhain method. These he interpreted as precipitates derived from protein substances present in the cell at this stage, which he considered to be in part the antecedents of the mucin. These observations require further confirmation by more modern cytological methods.

The nucleus of the mucous cell is usually not visible in fresh preparations of fully charged cells. In fixed preparations of such cells it is usually deformed, often cup-like, shrunken and deeply staining. As the cell pours out its secretion, the nucleus resumes its oral or spherical shape, the structure of the chromatin becomes visible, and one or more oxyphil nucleoli appear. In short, it becomes a typical epithelial cell nucleus. To what extent

the deformed shape of the nucleus in such cells is due to hydrostatic pressure, to osmotic disturbances or to fixation artefacts is not clear; but, in view of the lability of the granules as demonstrated by the observations of Langley (1889), it may be presumed that the changes in the volume or in the state of the secretion antecedent during the process of fixation and staining are the causes of this shrunken appearance.

The Golgi apparatus of mucous cells has been studied by v. Bergen (1904), but the descriptive details offered by him are not clear.

III. THE SEROZYMOGENIC CELLS

The justification for the use of this term for a large category of cells of the salivary glands rests in the fact that they resemble closely in structure and in functional changes the cells of the pancreatic acini and the chief cells of the fundus gland of the stomach, which are well known to produce enzymes. In the salivary glands cells of this type are found, which are known to produce a saliva containing diastase, and also in a large number of glands where the search for this particular enzyme has yielded negative results. But the use of this term must not be taken to imply a prediction that further research will reveal enzymes in the secretions of the glands in question.

To this class belong the parotid glands of most mammals thus far investigated, the demilunes and serous cells of the human submaxillary gland, the demilune cells of the submaxillary gland of the horse, the cells of the acini of the submaxillary gland of the guinea pig and the serous glands of v. Ebner in relation to the gustatory neuroepithelium.

The serozymogenic cells present the following characters, which may be used for the present to distinguish them from mucous cells on the one hand, and from other sorts of serous cells on the other:

1. In the fresh condition the serozymogenic cells, examined in native serum or in aqueous humor (sometimes even in isotonic sodium chloride solutions or in Ringer's or Locke's balanced solutions), contained a variable amount, according to their functional state, of easily visible, highly refractile droplets (granules of Claude Bernard). These droplets are less labile than the droplets of the mucous cells and for this reason remain longer under observation, which probably accounts for the fact that the droplets in these cells were readily accepted by investigators, while those in the mucous cells were long the subject of dispute. The consistence of these droplets may vary from sols, liquid enough to round up immediately when released in the indifferent medium, to gels, sufficiently stiff to retain for a time the facets impressed on them by their neighbors in the cell. Droplets of different consistence may be present at the same time side by side in the cell. Evidently their water content is variable, or the granules under

some conditions undergo a chemical change which reduces their gel quality. The granules thus visible in the surviving cell may be very difficult to preserve, and, as in the case of the mucous granules, droplets from homologous cells may behave differently in this respect. Only by experimentation in each individual case can satisfactory fixation be attained.

2. The serozymogenic cell reacts negatively to muchematein mucicarmine, Hoyer's thionin and to other metachromatic stains.

3. The granules of the serozymogenic cell, when successfully fixed, may be positively stained by a number of methods which usually are negative for mucin; for example, iron hematoxylin, Bensley's copper chrome hematoxylin, Bensley's neutral gentian, the Altmann, Champy, and Begaud and Bensley methods for mitochrondria.

4. The serozymogenic cells have a relatively high content of a substance to which attention was first called by Rudolph Heidenhain, who noted that the chief cells of the stomach and the acinus cells of the pancreas contained a substance which was precipitated by dilute acetic acid. As is well known, these cells have a large content of material, which is often referred to as basophilic or chromophilic material. This substance, long known in the pancreatic acinus cell, was discovered in the chief cells of the stomach and in the glands of v. Ebner of the tongue by Bensley (1898); was described in the serous cells of the human submaxillary by Solger (1898); was studied in a wide range of serous glands under the general term "ergastoplasma" by Garnier, and was included in his general conception of "superior protoplasm" by Prenant. Much confusion has arisen in the consideration of this substance by applying to it imperfect morphological criteria. For example, Laguesse confused it in the pancreas with the structures made visible by vital staining with Janus green B (mitochondria), adopted the Prenant-Garnier conception of a noble protoplasm and called the structures revealed after acid fixation "ergastidia." Hoven (1912), and more recently Nassonov (1924), and Bowen (1926) have adopted the theory that the ergastoplasm of Garnier was merely badly fixed mitochondria. All of these observers have overlooked an important cell constituent as defined by the following characters:

a. Heidenhain showed that these cells in which the chromophile (basophile) material is abundant contain a substance precipitable by acetic acid.

b. Bensley demonstrated that the chromophile material contains iron in organic combination as revealed by the microchemical method of Macallum, and that the iron reaction is co-extensive with the staining with hematoxylin, etc.

c. Bensley (1911), Regaud and Mawas (1909a) and others showed by appropriate fixation and staining the chromophile material could be demonstrated and differentiated from the mitochondria in the same cell. It may be remarked at this point that the Nissl bodies present similar properties,

and it has been clearly shown by Cowdry (1912) that these substances occupy a different territory from and are not to be confused with mitochondria.

This chromophile material confers the staining properties on the basal artefacts produced by acid fixation in serozymogenic cells. In such fixations the basal cytoplasm resolves itself into rods or threads sometimes exhibiting highly complex arrangements, but staining intensely with basic stains. The simple rods seen by Solger in the demilunes and serous cells of the human submaxillary gland, the complicated plexuses described by Eberth and Müller (1892) Mouret (1895), Mathews (1898) and others and the thread-like materials described by Garnier (1900) all belong in this category. They include the coincidently precipitated ground substance and chromophile substance of the cell. This tendency to precipitate as threads and rods is responsible for the unfortunate misconception of those authors who regard them as badly fixed mitochondria, a conception which the application of Millon's reagent, or of Macallum's reaction should at once refute, since the mitochondria are negative to Macallum's reaction, and only feebly positive to the Millon's reagent, while the structures in question are strongly positive to both (Bensley, personal communication, 1926).

The nature of the chromophile material is still unknown. Its precipitability with acids, and its iron content, suggest that it belongs either to the phosphoproteins or to the nucleoproteins. Mathews, who studied it by staining methods, was inclined to the opinion that it was phosphoprotein in nature, and that it was formed under the influence of the nucleus but outside of the latter. Macallum, in his study of the pancreatic cell, describes the nucleus as losing substance to the cytoplasm which combines with a constituent of the latter to constitute the prozymogen or antecedent of the zymogen. All of these conceptions are of value as working hypotheses, but do not settle the question, either of nuclear origin, or of chemical nature. Reasoning from the analogy of the nerve cell in which the Nissl substance apparently presents similar chemical characters, it seems probable that the material is derived from the nuclear chromatin, but it remains for the future to elicit the convincing proof of this idea. The theme has been much confused by the expansion of the chromidial hypothesis of R. Hertwig by Goldschmidt and his pupils to include many diverse things stainable by basic dyes including under various conditions of fixation, mitochondria and Golgi reticular apparatus. There is no need for this confusion, if the chemical as well as the morphological facts be considered, and if it be remembered that the fixation is as important a factor in determining staining properties as the cytoplasmic substrate.

The amount of the chromophile material in the cell depends on (1) the stage of functional activity, and (2) the specific secretory equilibrium of the cell. Many observers agree that the chromophile material increases in

amount while the cell is actively exporting its secretion, and again diminishes in amount when export ceases and the cell enters on a period of rest. Bensley furnishes illustrations of these differences in the chief cells of the gastric glands, and Mouret and others in the acinus cells of the pancreas. It must be recognized at the present time, however, that these inferences rest upon a somewhat insecure foundation, since under the conditions of observation in which only two dimensions of the cell are considered the changes in volume of the cell may easily lead to misconceptions. It is obvious that the mere loss of the secretion droplets without any actual change in the amount of chromophile material would make the latter show an apparent increase. More accurate quantitative observations are necessary to elucidate this point. By "specific" secretory equilibrium is meant the fact that different glandular cells tend to attain an equilibrium of their secretogenic processes at different levels which are specific for the type. For example, the cells of the parotid gland fill up with granules, and show a relatively small chromophilic zone after a period of rest, while those of the pancreas remain clearly divided into two zones, one glandular, and the other chromophilic. Even homologous cells from the same organ but from different sites may show this difference. For example, the chief cells in the glands of the fundus ventriculi of the rabbits' stomach resemble those of the parotid gland, while those of the curvatura major resemble the pancreas in specific secretory equilibrium.

It may be well to mention the fact that the chromophile material, so defined, is not the exclusive possession of the serozymogenic type of gland cell, but is present also in moderate amounts in the tropochrome cells of Bensley, and in even still smaller amounts in the mucous cells. It seems probable that it is present in some quantity in all cells but in some in too small an amount for detection.

The secretory changes in the serozymogenic cell follow the same general lines as in other secretory cells; namely, they consist in a diminution by export of the elaborated secretion antecedents (secretion granules) and an apparent increase in the amount of the cytoplasmic constituents. Heidenhain noted the increase of the clear basal protoplasm in certain cells as the secretion antecedents diminished, and Langley noted a similar phenomenon in the parotid gland cells. Regaud and Mawas (1909*a*) studied the mitochondrial content of certain serozymogenic cells, and observed that in the fully charged cell the mitochondrial filaments were few in number and occurred in the form of short rods. In the discharged cell, on the contrary, the mitochondria were very abundant. In the parotid gland of the ass they found the mitochondria in the form of granules, rods and long filaments. In the fully charged cell these were represented only by very few filaments situated exclusively at the base of the cell. In the discharged cell, on the other hand, the mitochondria were abundant and occupied the whole extent of the cyto-

plasm. In a later communication (1909*b*), these authors expand these observations with certain speculations concerning the mode of participation of the mitochondria in the secretory activity of cells. Their conception is that a portion of the material of the filament separates to form a plast which is discharged into the cytoplasm and ultimately forms the secretion granule. In terms of this theory the mitochondria are regarded as organs of the cell, the function of which is to select and segregate the necessary substances for the synthesis of the granules, but which are not of themselves destroyed in the process. Hoven, in a series of articles, also adheres to this hypothesis, but expresses the opinion that in some cases the mitochondrium actually breaks up into granules which become by further change the secretion granules. There has been a vast amount of research in this field, and the problem is not yet solved. Obviously the morphological facts are not sufficiently clear-cut to justify a conclusion. Meanwhile other structures and substances which show changes in relation to the process of granule storage and export must be considered; for example, the chromophile material, particularly in the serozymogenic cell where it is abundant, and the Golgi apparatus, which has already been referred to.

The nucleus of the serozymogenic cell is oval or spherical, and is situated at different points in the cell depending upon variable functional conditions. The evidence for the participation of the nucleus in the secretory process is not clear (see Maximow, 1901, on the serous cells of the retrolingual of the dog, and Dolley, on the cells of the pancreas).

Cells of the serozymogenic type are to be found in the following locations: acinous cells of the parotid gland of most mammals; acinous cells of the submaxillary gland of the guinea pig; serous acini and demilunes of the human submaxillary gland; demilunes of the submaxillary gland of the horse, ox and other ungulates; the serous glands of v. Ebner in the base of the tongue.

The parotid gland of most mammals presents the serous or serozymogenic types of cell. By "serozymogenic" we mean a gland cell characterized by the presence of zymogene granules plus chromophile material.

IV. SPECIAL SEROUS CELLS

By the expression "special serous cells" it is intended to designate those non-mucous cells which differ in important respects from the serozymogenic type but which, notwithstanding a vast amount of research, remain, as yet, functionally and cytologically ill defined. In examining the literature dealing with these elements one is impressed with the fact, that, while there is a great deal of descriptive detail (concerned particularly with the staining reactions of the secretory contents), the information from the standpoints

of the appearances of the fresh gland, the analysis of mitochondrial and other relationships are deficient and microchemical or biochemical data are practically lacking. Under these circumstances it would be unwise to attempt a classification of them into homologous, or functionally similar groups, and it would seem to be better so to emphasize the differences that it will be apparent to all that the salivary glands of mammals afford an unequalled opportunity for further research. In doing so I have been faced with the fact that the accumulated records have been made from very different points of view, and with various preconceptions of the degree of ordinal specification of the salivary glands in mammals. The wordy discussions in which the literature abounds concerning the question whether the demilunes are cells sui generis or transitory phases in the life cycle of mucous cells would have been spared us if the early investigators had recognized what we now know to be true, that the demilune concept is only concerned with a form of cell grouping and not with a type of cell, and that the determination of whether a cell is mucous or serous is only a first and relatively unimportant step in gland analysis.

With these facts in mind I shall endeavor in what follows to present a picture of the present state of knowledge as regards these little understood special serous cells, devoting particular attention to those which have been especially the subject of research. Among the types to be so considered are the following: demilune cells of cat and dog (the demilunes of primates and ungulates belong to the serozymogenic division); the serous cells of the retrolingual gland of the dog; all cells in the submaxillary gland of rabbit, rat, mouse, muskrat and gopher (the cells of the submaxillary gland of the guinea pig are serozymogenic); all cells of the submaxillary glands of the hedgehog, and of shrews.

In making this survey it has become apparent that, especially as regards the submaxillary gland, there is a high degree of specialization in different mammalian orders, but considerable similarity of structure, and presumably of function, within the limits of the ordinal divisions. Thus, for example, the submaxillary gland of the rabbit possesses a cellular type which is also present in the rat, mouse and gopher, and the structure of the submaxillary glands in the ox and horse is essentially the same, while vastly different from that either of rodents or of carnivora. On the contrary, the submaxillary gland of the guinea pig is wholly different from that of the other rodents, and according to the observations of Krause the submaxillary of two species of *Herpestes* is different from that in other carnivora.

The types which have received most attention from investigators have been the demilune cells of the cat and dog; the cells of the submaxillary gland of the rabbit; the retrolingual gland of the dog and the submaxillary gland of the hedgehog (*Erinaceus europaeus*). These types will accordingly be the topics of special discussion.

1. *Demilune cells of the submaxillary glands of the cat and dog:**

As early as 1889 Langley recognized the inadequacy of the current theories as to the nature of the demilune cells, and devoted a considerable amount of attention to them. He studied the structure of the cells of the submaxillary gland of the dog when examined fresh in sodium chloride solutions of 0.5 per cent strength, and not only observed the granular antecedents of the secretion of the mucous cells and of the demilune cells for the first time but studied the reactions of these granules with various reagents, and with different concentrations of salt. These researches are of the greatest importance not merely because they furnish information concerning the actual structures visible in the living cell, but also because they illustrate so well the difficulty of applying the facts learned by the chemical study of extracts of the gland directly to microchemical search for the antecedents of the substances in the gland known to be produced by it. In the demilune cells Langley found the cytoplasm studded with minute granules similar in refractive index to those in the mucous cells but only about one-third the size.

Mislawsky and Smirnow (1896) studied the demilunes in the submaxillary gland of the dog after twenty-four hours fasting and after prolonged stimulation of the chorda tympani nerve. Their material in some instances was fixed in a mixture of equal parts of saturated solution of sublimate and of a one per cent solution of osmic acid, and the sections were stained with dahlia. In others the material was treated throughout by the Altmann technique. Both techniques showed the presence in the cells of minute granules filling the entire cell in the fasting animal to be somewhat fewer and scattered in the stimulated gland. The authors thus found that the demilune cells responded to the chorda stimulation, but at a slower rate than the mucous cells.

Maximow (1901), in connection with his study of the changes induced in the submaxillary and retrolingual glands of the dog by paralytic secretion, devotes considerable attention to a consideration of the normal gland. He accepts the statement of Langley that the demilune cells contain specific granules, together with a hyaline substance surrounding them as described by Langley. In a preparation fixed in Podwyssotsky's fluid and stained with safranine and lichtgrün he found the demilune cells containing minute green-stained granules which sometimes filled the whole cell, but which in other cases left the outer portions of the cell free. In some of the preparations he noted a special grouping of the green granules near the nucleus. In addition to these granules he also found granules of another sort, usually in the immediate vicinity of the nucleus, much less numerous, but some-

* For a discussion of the discarded theories of Hebold, Stohr, and Heidenhain the reader is referred to the original publications. In this article the theory of v. Ebner that the demilunes are composed of cells sui generis is accepted as a basis for discussion.

what larger than the green granules and stained a dark brown color. In the Altmann preparations he observed fuchsinophile granules (chondriosomes) obviously different from the secretion granulations, and with no special relation to the nucleus. He did not find the basal filaments of Solger, the ergastoplasmic formations of Garnier or the secretion vacuoles in these cells. In the pilocarpinized gland, on the other hand, vacuolation developed to a considerable extent.

There is little doubt that Maximow has seen and clearly discriminated between the actual secretion granules and the mitochondria in the demilune cells. There remain, however, in his sublimate preparations, granules which stain with iron hematoxylin, the relation of which to the other cell constituents is doubtful. His figures of the secretion-filled cell accord very well with those of Mislawsky and Smirnow, and with the descriptions by Langley of the appearance of the fresh cell. The descriptions of the cells of the demilunes of the pig by Krause (1897) are not apposite to the present survey, since they are concerned with cells of a different functional category.

Noll (1902) also confirms Langley's description of the granules in the fresh cell, and contrasts the appearance of these granules in the demilune cell with that of the granules in the parotid gland, which he considered different in nature. In his fixed material he was not so fortunate, since the place in his modified Altmann preparations where the secretion was present in the fresh cell appears as an alveolar network. He found, however, in the demilunes large numbers of fuchsinophile granules, a part of which were unquestionably mitochondrial. A part of them he considered to be the original granules of secretion, but an examination of his figures is not convincing in this regard.

In the active gland, on the other hand, Noll discovered, as he thought, transition types between the demilune cells and the mucous cell, and finally reached the conclusion that there was in reality but one type of cell in the dog's submaxillary, of which the demilune cells and the mucous cells respectively were different phases.

Metzner (1907), in his general review of the processes of secretion in glandular cells, describes the results obtained by new methods of fixation and staining. He saw the granules in the demilune cells of the fresh gland, and was able to stain them in properly fixed material. In this work much stress is laid upon the different colors obtained by toluidine blue staining as an indication of the stage of elaboration of the secretion granules in mucous cells, and apparently because the granules in the demilune cells stain similarly to those in the mucous cells in certain phases of their elaboration, he adopts the phase theory of Hebold and considers that the demilune cells are but a phase of the mucous cells. A similar conclusion is reached by Arima (1918) who applied to a similar study the techniques recommended by

Metzner. Takagi (1925), on the contrary, regards the demilune cells in the submaxillary of the cat, which he studied in various stages of development and in different functional stages, as cells sui generis. He distinguishes in them chondrioconts, mitochondria, large stainable granules and vacuoles. The latter he regards as peculiar to the demilune cells. In the active gland after mild faradic stimulation he found the number of chondrioconts increased, the stainable granules and vacuoles diminished. After strong stimulation by means of the faradic current he found the number of chondrioconts again diminished, the stainable granules increased and the vacuoles completely absent. The contents of the vacuoles remained negative to the Altmann method and to iron hematoxylin but stained faintly in mucicarmine or basic fuchsin. Even after long-continued stimulation, Takagi, contrary to Metzner, Noll, and Arima, was able to distinguish clearly between demilune cells and mucous cell, which, according to his observations, remained independent throughout.

Bensley (1908) describes the secretion antecedents in the demilune cells of the cat and dog, examined in homologous serum, in much the same terms as Langley. He finds, however, that when formalin bichromate mixtures are used for fixation the substance of these granules is well preserved though in a modified form, and may be stained selectively metachromatically by toluidine blue, safranine or thionin. In the material fixed in sublimate, on the other hand, no metachromatically staining material is visible. He finds, in agreement with Cohoe (1907), that the same properties are displayed by certain cells of the submaxillary glands of rodents, and classes cells from these various sources together as "tropochrome cells."

If we sum up now the combined results of the several authors who have investigated the demilunes in the cat and dog by cytological and experimental methods, the following facts emerge clearly:

1. The demilune cells contain a secretion antecedent in the form of granules visible in the fresh cell occupying a variable extent of the cell. Müller, Maximow, Metzner, Bensley, and Arima were able to stain these granules in fixed materials. In Takagi's material they constituted the contents of his vacuoles. Metzner and Arima were too much impressed by the capacity of these granules to stain with toluidine blue after certain osmic fixations, and confused them with mucin antecedents for that reason. For a similar reason they were unable to distinguish between the mucin residues in the acinous cells and the secretion residues in the demilune cells by the technique they employed, hence their conclusion that the two were merely different phases in the secretory history of the mucous cell.

2. The secretory content of the demilune cells diminishes during stimulation by the faradic current or by pilocarpine.

3. The demilune cells contain mitochondria varying in form from the fine granular type to the short rods and filaments.

4. The demilune cells contain granules of larger size than the secretion occupying chiefly the intermediate zone of the cell, which stain both by the mitochondrial methods applied by Noll and Takagi, and by the methods for the recognition of the secretion employed by Maximow. These granules are at present of doubtful reference. They may be modified mitochondria, or quite different stuctures.

5. According to Bensley the secretion in non-mucigenous stains like mucin after formalin fixations.

6. The cytoplasm of these cells has an optically structureless ground substance in which the formed elements (mitochondria, secretion granules, fat droplets and special granules of Maximow) are suspended.

7. According to v. Bergen, a Golgi reticular apparatus is present in the demilune cells but the details are not clear.

Probably the demilunes are as essential to mucus secretion as is the mucous cell itself. The cavity of the gland and its ducts are not merely conduction paths but a reaction space for chemical changes.

2. *The submaxillary gland of rodents:*

Rudolph Heidenhain (1868) examined the secretion collected from the submaxillary gland of the rabbit and found that it differed in composition from that delivered by the same gland in the dog inasmuch as it contained no mucin, although it contained an albuminous substance which could be precipitated by the addition of acid. Nussbaum employed this gland to establish his thesis that enzyme antecedents reduced osmium tetroxide, a conception which was refuted in a series of investigations by Langley. Nussbaum, however, thought the gland contained groups of cells which darkened with the osmic reagent and so foreshadowed the discovery of the complex character of the gland which we owe chiefly to Erik Müller (1895). Müller found that sections of the gland fixed in Kopsch's formalin-bichromate mixture and stained with iron hematoxylin presented two classes of cells; namely, (1) cells in groups which were closely studded with deeply stained granules, and (2) other groups of cells forming the major part of the secretory tubules of the gland which remained clear, palely stained, and showed a coarse reticular structure somewhat resembling mucous cells. Müller thought that the two types of cells were phases of the secretory history of a single type, but this interpretation was shown to be erroneous by Cohoe (1907), who demonstrated that each type of cell examined in the fresh state had its own type of secretory content, and succeeded in staining the two sorts of secretion differentially in sections. He discovered also that the coarsely granulated cell occupies a constant position in the gland tubule, inasmuch as it is interposed between the intralobular ducts and the second type. He observed that in sections made from material fixed in formalin-bichromate mixtures, the granular contents of the clear cells consisted of

rather large spherical granules which stained positively with mucicarmine and muchematein and gave a pronounced metachromatic reaction in thionin. He found also the lumen of the tubules and of the intralobular ducts filled with a gel-like coagulum which stained in the same way as the granules in the cells. Bensley (1908) termed this character "tropochromatism" and designated the cells which displayed it, the "tropochrome cells." The other cells containing coarse granules, whose staining properties were not altered after formalin-bichromate fixation, he termed "homeochrome cells." He also pointed out that the tropochrome property was exhibited by the demilune cells of the submaxillary gland of the cat and dog (Figs. 36 and 37).

The tropochrome cells of the rabbit's maxillary gland examined fresh in rabbit's serum are seen to be filled with relatively large spherules of secretion antecedent which are very difficult to see on account of their low refractive power. In preparations fixed in sublimate they present an appearance very similar to mucous cells from which they differ by the fact that the contents of the cell spaces do not stain with any of the ordinary staining reagents for mucin. Furthermore, there is present at the base of the cell a small but appreciable quantity of the chromophile material, stainable in basic dyes, which has been described as a conspicuous component of the serozymogenic type. The mitochondria consist of short rods and filaments scattered through the cytoplasm where they occupy the thin cytoplasmic partitions between the granules. The nucleus is usually shrunken and basal in position in the fixed material. In material fixed in formalin-bichromate the spherules of secretion are preserved and may be colored with the mucin stains above mentioned, presenting the typical dark granules of serous cells. Stormont (1926), after stimulation of the cervical sympathetic nerve, observed definite secretory phases in the tropochrome cells. The nuclei and cytoplasm both changed in response to the stimulation with the dispersion of the granules toward the apex and also the discharge of the granules in the duct lumina. Since the lumina and ducts are filled with a similarly staining substance, it is apparent that the bulk of the secretion of the gland is produced by these cells.

In the rabbit serous granule cells are to be found in the region of the intercalated duct. They are always more or less regular in their arrangement, being situated between a distal group of clear or non-granular cells and the intercalary duct. The cytoplasm is abundant, and filled with darkly staining large granules. This is the so-called homeochrome group of cells.

The homeochrome cells of the rabbit's submaxillary gland occupy the portion of the tubular complex which immediately succeeds the intralobular ducts. They are relatively few in number, and are the direct derivatives of the duct cells. In the fresh condition they are easily visible by reason of the highly refractive coarse granules with which the cells are filled, contrasting sharply under these conditions with the pale and transparent tropochrome

cells. The granules are difficult to preserve but with the aid of formalin-bichromate solutions this is possible. When so fixed the granules stain intensely with iron hematoxylin or with Bensley's neutral gentian. The nucleus is large, oval and situated at the base of the cell. In the base of the cell also may be seen a variable amount of cytoplasm which, however, unlike the serozymogenic cells, contains no chromophile material. The mitochondrial details are not worked out. Cohoe (1907) and Stormont (1926), examining the secretion phases after stimulation with pilocarpine, have shown that the homeochrome granules disappear. The serous cells of the dog's sublingual contain large refractive granules which resemble the homeochrome group of the rabbit's submaxillary more than any of the other serous cells. The granular content is comparable to that of the parotid, although it possesses a lesser amount of chromophile substance.

In the sublingual gland of the horse and the ox one can see the large granule or serous cell which also reacts in its staining properties like the homeochrome cell of the rabbit submaxillary. Here also may be observed the clear or tropochrome group of cells.

The demilunes of the horse and ox submaxillary glands exhibit the characteristic refractive granules seen in the serozymogenic cells. Their reactions and staining qualities are similar to the homeochrome group of the rabbit (Fig. 38).

The tropochrome cell is the predominating type in the submaxillary glands of some other rodents. In the gopher (*Spermophilus*) the tubules of the gland are entirely composed of tropochrome cells exactly similar to those of the rabbit's gland. In the rat, mouse and muskrat, the gland tubules are composed of tropochrome cells, but the terminal segments of the intralobular ducts contain in their cells large coarse, highly refractive granules similar to those present in the homeochrome cells of the rabbit's gland; whence it seems probable that the homeochrome cells of the rabbit are derived primarily from a change of function of the terminal segments of the intralobular ducts. In the submaxillary gland of the guinea pig, neither tropochrome nor homeochrome cells are present, but the tubules are entirely composed of cells of the serozymogenic type, aptly compared by Klein (1882) to the cells of the pancreatic acini.

The submaxillary gland of the prairie dog and squirrel are of the clear variety of cell. When examined in the fresh condition, the cytoplasm is seen to be filled with small granules of a very low refractive index. When these cells are fixed in Orth's or Bensley's alcoholic sublimate mixtures, the granules stain metachromatically to thionin or toluidine blue. According to Bensley these acinotubuli cells are similar to the tropochrome cells of the rabbit submaxillary. The demilunes or crescents of Gianuzzi, in the submaxillary glands of both the cat and dog, when viewed in the fresh condition, are of similar appearance to the clear cells of the tropochrome

35

36

Fig. 35.—Muskrat submaxillary gland. Bensley's fluid fixation, saffranin-o-saure violet stain. (Bensley.)

Fig. 36.—Submaxillary gland of the cat. Bensley's fixation, toluidine blue stain showing metachromatism to mucin (Bensley). M, mucous alveolus; D, serous demilune.

group. Their secretion appears to be finely granular and is very difficult to detect. However, they may be preserved in Orth's or Kopsch fluids, and are found to stain metachromatically to thionin and toluidine blue of a much more intense reaction than do the mucous cells.

3. *The special serous cells of the retrolingual gland of the dog:*

In the retrolingual gland (glandula sublingualis monostamatica of Illing) of the dog there is present a large non-mucous element composed of cells which are markedly different from the demilune cells found in the submaxillary. These have been made the subject of an extensive study by Maximow (1901), to whose monograph the reader is referred. The granular antecedents of these cells do not possess the tropochrome properties shown by the granules in the demilune cells, and, according to Maximow, contain no chromophile material in their cytoplasm. Unlike the homeochrome cells of the rabbit's submaxillary, these cells are well provided with intercellular secretion capillaries. In Altmann preparations, according to Maximow, the cytoplasm between the secretion granules is closely studded with minute fuchsinophile granules (mitochondria).

4. *The submaxillary gland of insectivora:*

In the insectivors the submaxillary gland seems to possess a high degree of specialization, the nature of which has, however, been so far imperfectly investigated.

Kultschizky (1885), and Krause (1895), working upon the hedgehog, observed the typical granule and non-granular cells in the tubules of the submaxillary gland. Krause (1895) has described in considerable detail the submaxillary gland of the hedgehog, which consists, according to him, of two kinds of tubules, clear tubules composed of mucous-like cells, and granular tubules consisting of serous-like cells. Schaffer has described similar differentiations in *Crossopus fodiens*, two species of *Serex* and in the mole (unnamed species). The data offered by these authors are deficient in descriptions of fresh gland, and in the analysis of the cytological structure by modern methods, and for these reasons cannot at present be evaluated for purposes of classification. It is interesting to note, however, that Schaffer (1908) observed in the gland of *Crossopus fodiens*, that the terminal intralobular ducts are composed of cylindrical cells containing coarse granules, with basal mitochondrial rods much the same as in the corresponding gland of the rat, etc. Krause noticed the similarity between the appearance of the hedgehog's and rabbit's submaxillary gland.

The similarity in the behavior of the two glands towards stains in respect to their microchemical properties is very marked. The clear cells of both glands react alike to Krause's methods of staining for mucus. Yet this in no way proves the presence of mucin, for we have no specific micro-

37

38

FIG. 37.—Cat submaxillary. Orth's fixation, toluidine blue stain (Bensley). M, mucous alveolus; T, serous demilune.

FIG. 38.—Ox submaxillary gland. Orth's fixation, toluidine stain (Bensley). M, mucous alveolus; H, serous demilune.

chemical test for it. In general the descriptions suggest a close similarity between the submaxillary glands of rodents and insectivores, although the material and information available are not sufficient to classify them or to homologize with other glands.

V. DUCT ELEMENTS

1. *Intercalated ducts:*

The cells of the intercalary ducts are composed of flat low cuboidal epithelium. They possess a large oval or round nucleus usually situated near the center of the cell. The cytoplasm is relatively small and devoid of granules. Langley (1878), working with osmic-acid preparations, describes a gradual transition from the alveolar secreting cell to the low cuboidal cell of the ductuli. Von Ebner (1872), Nussbaum (1877), Klein (1882), and Cohoe (1907), working on carefully stained sections, are unable to confirm Langley's results and find, on the contrary, that there is an abrupt change from the cuboidal cell of the ductuli to the high columnar cell of the secretory cells of the alveoli. Krause (1895) observed that in the retrolingual gland of the hedgehog the cells of the intercalated duct penetrate into the lumen of the acinus like the centroacinous cells of the pancreas, but to a less degree. M. Heidenhain (1921), in the human submaxillary gland, showed that the intercalary duct cells are few in number and that the transition is abrupt. Pischinger (1924), using human submaxillary material fixed in Müller-formalin and stained with mucicarmine, finds evidence of secretory activity in the intercalated ducts, as judged by the presence of large serous-like granules.

The ductuli react to stains in a manner similar to that of the cells of the intralobular ducts. The intercalary ducts open into the intralobular ducts. Here can be observed a direct change from the low cuboidal, ductuli cell to the high columnar, rodded cell of the intralobular duct. Flint (1902 to 1903) observed in the developing gland of the pig that the cells of the intercalated portion of the duct early appear quite like the parietal cells of the alveoli and that the epithelium may be composed of a double row of cells. Flint observed the intercalary duct connecting with the mucous alveolus to be of the same character as those connecting the serous. Usually in the adult the single layer of cells has replaced the embryonic condition of a double row, although occasionally the double character may persist. Krause and Maximow suggest the possibility of the ductuli being the source (by mitosis) of new secretory gland cells.

2. *The intralobular duct cells:*

The ducts of the "salivary tubes" of Pflüger are lined by a single layer of epithelial cells of a high columnar nature. The membrana propria is quite an appreciable structure upon which these columnar duct cells rest. Maximow

(1901) demonstrated the presence of the "Korbzellen" in the membrana propria surrounded by connective tissue. The nuclei are large spherical bodies normally lying in a central position, although they may assume new positions and shapes dependent upon the secretory condition of the cell. The cytoplasm presents a finely granular appearance and, when preserved in formol or Zenker-Bensley's acetic-osmic bichromate fluids and stained with iron hematoxylin, shows a marked rodded or stippled structure in the basal portion of the cell. This rodded appearance led Pflüger (1866) to believe that these cells were engaged in the process of salivary secretion.

Several observers have described the presence of granules and rodded striation in the intralobular ducts of various species. Large, highly refractive secretory granules may be seen in the terminal intralobular ducts of the rat and mouse, and also may be seen in the shrew (*Crossopus*), according to Schaffer. Tschassonikow demonstrated the presence of stainable secretory antecedents. Mislawsky and Smirnow (1896) by stimulating the auriculotemporal nerve to the parotid gland of the dog, caused a marked diminution in the granular content, as compared with the normal. Cohoe (1907) observed in the exhausted gland, that the granules of the intralobular ducts stained more feebly than in the normal. Takagi (1925) found, that, in the "Unterkieferdrüse" of the cat, the intralobular duct was void of the rodded, striated cytoplasm after a previous stimulation of a bountiful meal, and the cells presented only a very finely granular character. Merkel (1883), Maximow (1901), and Metzner (190-) observed secretory changes following stimulation of the chorda tympani as evidenced by the changes in the size and position of the nuclei of the intralobular duct cells; the nuclei being shrunken in size, staining deeply and situated apexward. Usually the epithelium of the intralobular ducts consists of a single layer of tall columnar cells, in the adult, although an occasional double row may persist.

3. *Ducts as sources of water and reaction spaces:*

There is a great deal of evidence to support the views of Harvey and Bensley (1912) that the ducts are the chief contributors of water to the secretion. Bensley informs me that there is evidence that such is the case in the pancreas, and Stormont has also found the same in the rabbit's submaxillary. Since in the rabbit the tropochrome cells are the ones to give the large amount of organic or viscid material to the secretion, it follows that the ducts are responsible for most of the water in the secretion. That the ducts and homeochrome cells are innervated by the parasympathetic and the tropochrome cells by the sympathetic was also shown by Stormont. It is possible that the ducts may furnish the mechanism by which the osmotic pressure differences between the cell secretion and the fluid in the duct lumina may be regulated.

The secretion antecedents emerging from one gland cell, when added to those antecedents from the other glandular elements, may undergo many changes. The duct lumina serve as cell laboratories, or reaction spaces, in which the interaction of the various secretory antecedents may take place.

VI. DEVELOPMENT OF THE SALIVARY GLANDS

The development of the salivary glands occurs from the evagination of the deeper layer of the stratified epithelium of the mouth. According to Thoma (1919) the anlage for the parotid is the first to appear. Contrary to Metzner (1907, 1909) the order of development of the salivary glands is parotid, submaxillary, sublingual, anterior labial and labial (Hammar, 1901, Schulte, 1913, and Thoma, 1919).

A characteristic epithelial thickening spreads and elongates so that it is separated from the parent epithelium, being joined only by a narrow cord of cells. This cord begins to form a lumen and becomes a tubular structure (Thoma, 1919) opening into the oral cavity. When part of this flange or thickening remains attached to the duct, as often happens, it gives rise to "sprouts" for the accessory and secondary submaxillary glands.

Numerous sprouts are given off along the duct which in turn form other secondary ducts. These newly formed ducts are composed of two or three layers of cells shaped more or less cylindrically. The head of the cord (distal end) proliferates rapidly, forming small outpouchings or buds from which develop the branches. These branches in turn give off small projections at right angles, and they in turn give off more, around whose terminations groups of alveolar or acinar cells occur. In the 52 mm. embryo, differentiation appears, showing clear or serous cells and mucous cells (Thoma-submaxillary gland, 1919). The presence of the crescents of Gianuzzi are suggested, though not definite at this stage.

In the sublingual gland mucous cells are developed by the sixteenth week, while in the parotid, serous acini cells are present at five months. The developing epithelium and gland cells are quickly embedded in a more or less concentrically arranged group of connective tissue cells.

The cellular development for the salivary glands is in general the same. The lingual, labial and lesser sublingual glands remain quite simple, while the submaxillary and greater sublingual glands develop into complex forms.

The differentiated cells of the respective salivary epithelium cords early assume a functional rôle as determined by the microscopical structure.

VII. INNERVATION

The distribution of motor nerves to the glands is from two sources, namely, (1) the thoraco-lumbar sympathetic, and (2) the bulbar-sympathetic or parasympathetic. Thus, the intermedio-lateral column of cells of the spinal cord (T1-L2) gives rise to preganglionic fibers, which travel via the thoraco-cervical sympathetic trunk to form synapses in the superior cervical ganglion. Post ganglionic fibers travel from this point to the respective glands coursing along in the walls of the branches of the carotid artery.

The bulbosympathetic supply is from two sources: the *nucleus salivatorius inferior* of the ninth cranial nerve, and the *nucleus salivatorius superior* of the seventh cranial nerve. The peripheral parasympathetic ganglion of the ninth, is the otic, from which arises the postganglionic fibers of the parotid gland. From the *nucleus salivatorius superior* come fibers via the chorda tympani to the submaxillary ganglion, which in most cases lies

Fig. 39.—A section through a group of distal alveolar cells, showing secretion canaliculi. Stained in iron-alum hematoxylin. Leitz homog. imm. 1/12 oc. 4. (After Cohoe.)

in the submaxillary and sublingual glands themselves, in close proximity to the larger intralobular ducts. Postganglionic fibers go to the glandular elements. Sensory distribution to the salivary glands is by the trigeminal or fifth cranial nerve.

There are two ways by which a gland may become active: (a) by chemical stimulation via the blood steam; and (b) by the nervous mechanism which includes the various reflexes possible by mechanical, chemical, electrical or psychical stimuli.

Activated cells show the crowding of the secretion granules toward the apex, leaving their concentrated position near the middle or base of the cell which is characteristic of the resting condition. In the exhausted cell the cytoplasm is practically devoid of granules, and the lumen of the ducts may show a granular content similar in staining reactions to that of the granules of the serous cells (Fig. 40). The nucleus migrates further outward during secretory activity, thus leaving its normal position in proximity to the base of the cell. As it moves distally it assumes a more spherical shape. The nucleus undergoes enlargement during the activity of the secreting cells. According to Macallum, Maximow and others, the nucleus contributes substances to the cytoplasm during secretion. In the resting cell the nucleus is often oval in outline, rich in chromatin, stains deeply and is near the base of the cell, sometimes surrounded by the chromidial substance.

The cells do not undergo mitosis during secretory activity, which indicates that the gland cells are not destroyed as a result of secretion. Between the cells of a serous acinus can be seen small channels or canals—called secretory capillaries—presumably for the transference of the cellular products.

It is doubtful if the secretory products of the individual cells leave the cells in the form in which they appear to us in the collected secretion; although one can demonstrate by staining reactions, after electrical excitation of the gland cells, the presence of secretory granules in the duct lumina (Fig. 40).

We may experimentally stimulate gland cells to activity by electrical excitation of the secretory-motor nerves to the gland or by drug stimulation of either the nerve ending or the gland cell itself.

That there are differences in the serous cells has been adequately shown by Cohoe (1907) and Bensley (1908), in contrast to the former conception of Erik Müller (1896) that the differences in granular content merely represent different secretory phases of the same cell. Langley, from his physiological experiments, concluded that there is no reason to suppose gland cells connected with the sympathetic are any different from those connected with the parasympathetic via the chorda tympani.

It is possible microscopically to demonstrate the existence of two different groups of secretory motor fibers in the salivary glands (Stormont, 1926). It seems probable that a secretion containing substances foreign to the blood must be under the influence of special nerve fibers.

Considering the special case of the rabbit submaxillary gland, Stormont (1926) has shown that some extremely important deductions may be made as a result of an experimental study.

The results of stimulation of the chorda tympani are quite different from those produced by stimulation of the cervical sympathetic—a difference which some have attributed not so much to true secretory nerves as to the

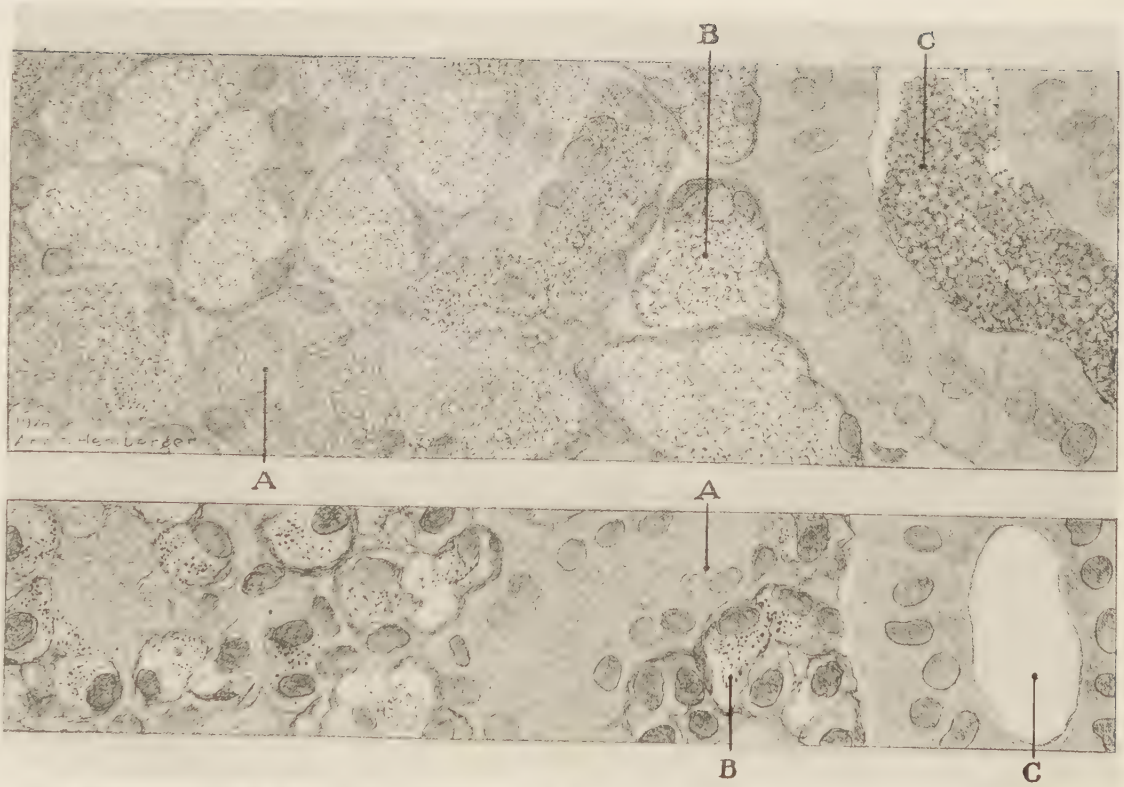

FIG. 40. Submaxillary gland after stimulation of the cervical sympathetic trunk with a faradic current for six hours. Note tropochrome secretory granules fill lumen of duct. No apparent change to the homeochrome groups. A, homeochrome; B, tropochrome; C, intralobular duct filled with tropochrome secretory products. 1. Stimulated gland. 2, Opposite or normal gland. Fixation, Orth's stain. Toluidine blue. Leitz. oil immer. 1.8 mm. oc. 4 60, 1(vl. 25.2) yr. 25.

vasomotor fibers which they contain. To investigate this difference the exact terminations of the sympathetic and parasympathetic in the gland were studied and these findings were correlated with the cytological changes following sectioning of the nerves and those following stimulation either with the electrical current or with drugs.

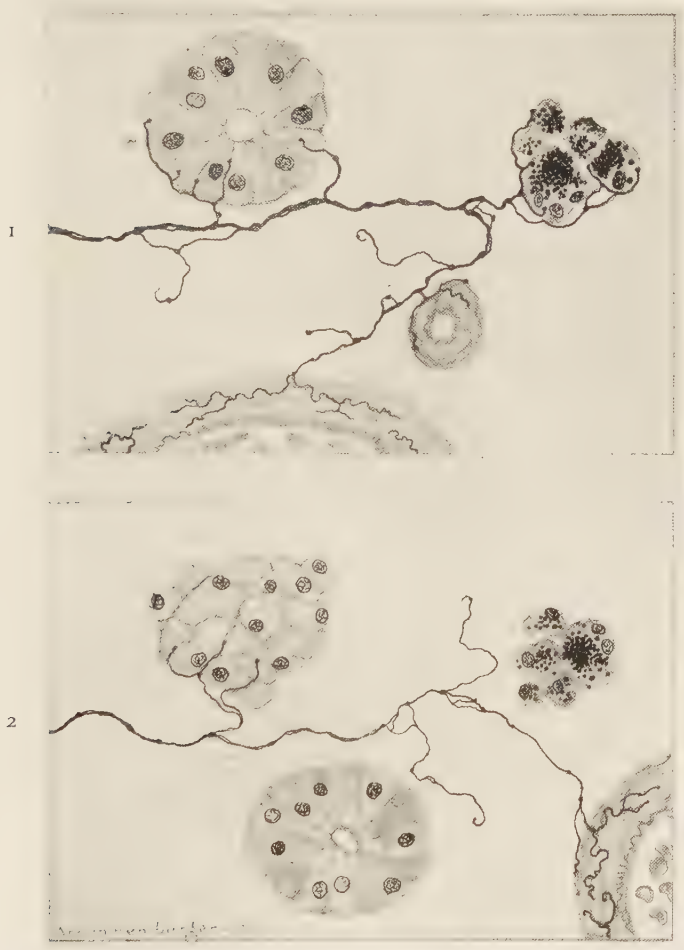

FIG. 41.—Diagram showing nerve distribution as seen in submaxillary gland of rabbit. 1. Parasympathetic distribution to ducts, homeochrome cells and blood vessels. 2. Sympathetic distribution to tropochrome cells and blood vessels. Modified Cox-Golgi technique. Drawn from magnification of Leitz obj. 1/12–48 oc. 12.5.

Conceivably the variation in the kind of saliva secreted as a result of the activity of the nerves to the submaxillary gland may be dependent upon (a) the blood flow, and (b) a specificity of nerve action that presumes these several nerves to act upon all the cells of the gland, or (c) a specificity

of distribution of the nerves to different secretory components of the gland. Carlson, Greer and Becht (1907 to 1908) have shown that when defibrinated blood is passed through the salivary blood channels it fails to cause secretion. The group of nerves to the gland must do more than cause a vasomotor action.

By a modification of the Cox-Golgi technique, the nerve distribution and nerve endings in the gland were studied. A fine distribution of nerves can be seen, particularly in the periphery of the tissue block. In serial sections of 45μ to 50μ the nerves along the larger ducts can be traced as they run towards the smaller ducts and branch in the connective tissue between the acini of the gland to end around the clear or tropochrome cells, the homeochrome cells and the ducts themselves. These endings lie upon the gland cells, at least half-way from the base to the apex, as end bulbs or varicosities. They often wind around a cell. Some end in the walls of the larger blood vessels.

After degeneration of the postganglionic fibers to the gland, following extirpation of the superior cervical ganglion, the remaining parasympathetic supply via the chorda tympani gives a striking picture. Nerve fibers are seen ending on the homeochrome cells, duct cells and blood vessels. There is a complete absence of any of the fine plexuses about the tropochrome cells which are to be seen in the normal gland of the opposite side. In the study of this tissue cytologically, the tropochrome cells alone showed signs of atrophy and of deviations from the normal.

Are these nerve endings secretory? To determine this, both the cervical sympathetic in the neck and the chorda tympani near the hilus of the gland were stimulated for six hours with a faradic current, and again with drug stimulation. An adequate expression of the activity of the gland was best seen in animals which were starved for thirty-six to seventy-two hours previous to stimulation. In agreement with Bunch (1900) following cervical sympathetic stimulation, a marked diminution in volume and vasoconstriction of the gland can be seen in contrast to the vasodilator effect not only of the gland but also of the mucous membrane of the mouth when the chorda tympani was stimulated.

Changes in the tropochrome cells were observed following cervical sympathetic stimulation, as indicated by the presence and character of the secretory granules not only in the cell but also in the duct lumen, by the size of the cells and by the size and position of the nucleus. The gland of the opposite side showed a normal picture.

The results of the electrical stimulation of the chorda tympani were a marked amount of extravascular blood, wreckage of the blood vessels, a very marked diminution of the homeochrome granules, a shifting of the nuclei to the asecretory pole, a great diminution in the size of the homeochrome cells and a shifting of the position of both the mitochrondria and

nuclei of the duct cells. Results similar to the electrical stimulation of the chorda are to be seen following the action of pilocarpine.

It would appear that the nerves bear some relation to secretion. The parasympathetic, besides sending basodilators to the blood vessels, innervates duct and homeochrome cells, while the sympathetic carries vasoconstrictor fibers and fibers to the tropochrome cells.

FIG. 42.—A section of the submaxillary gland of rabbit. Farradic current stimulation of cervical sympathetic trunk for six hours. Note changes in (C) the tropochrome cells; (B) homeochrome cells and (A) duct cells appear normal. Fixation; Bensley's alcoholic sublimate, stained with neutral gentian. Leitz high power 6–48 oc. 12.5 YL. 25 Leitz oil immer. 1/12–48 oc. 12.5.

If the sympathetic fibers are capable of activating the tropochrome group of cells, this fact alone may offer an explanation of the nature of the saliva obtained when the cervical sympathetic is stimulated. In terms of such an hypothesis the contribution of water by the ducts and of the trace of organic material by the homeochrome cells after parasympathetic stimulation would be easily understood.

This, then, may be a mechanism for the maintenance of a balance in the gland as a whole, secured by a different innervation of its various cell groups, rather than by a double innervation of each and every one of its elements.

Following the hypothesis of Claude Bernard (1864), that the active gland is under the influence of the chorda and the resting gland under that

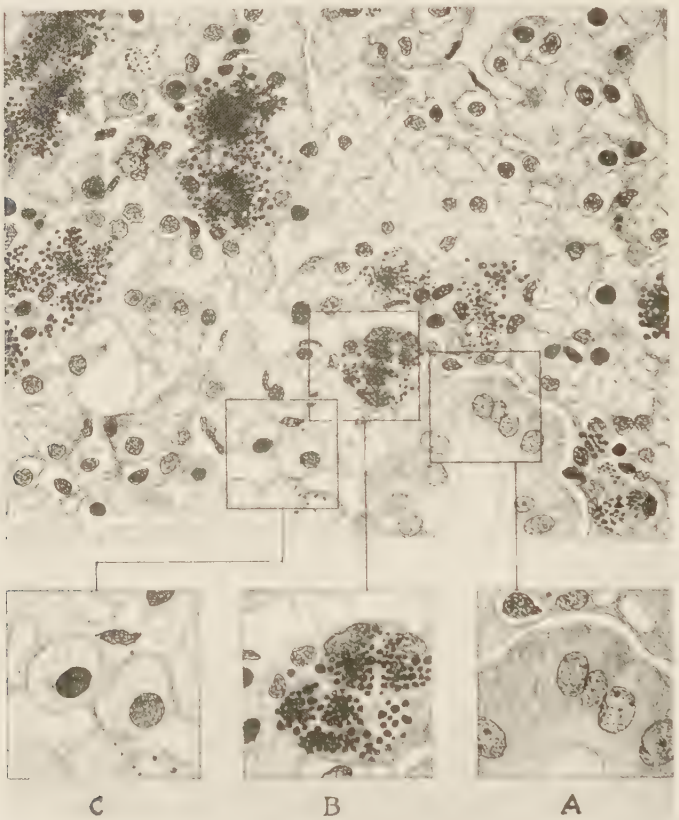

FIG. 43.—Control submaxillary gland, right side of rabbit which received farradic current stimulation of left cervical sympathetic trunk. Entire gland appears quite normal. A. intralobular duct; B, homeochrome cells; C. tropochrome alveolus. Fixation, Bensley's alcoholic sublimate. Stained with neutral gentian. Leitz high power 6–48 oc. 12.5 1/R 25. Letiz oil immer. 1/12–48 oc. 12.5.

of the sympathetic, Gesell (1920 to 1921) suggests that atropine paralyzes the function of liberation of secretion—leaving the function of elaboration more or less intact. In view of the work on the rabbit, it would seem as though another interpretation would be that of the paralysis of nerve endings to the homeochrome and duct cells, leaving the nerve endings of the sympathetic fibers and the tropochrome cells uneffected. Langley (1888)

states that the phenomenon of atropine gives no indication for more than one kind of secretory fiber in the chorda and that it acts on the receptive substance of the cell itself.

VIII. BLOOD SUPPLY AND LYMPHATICS

The salivary glands receive a relatively rich blood supply. The main artery of the gland enters at the hilus, to follow, for the most part, the course of the ducts to reach the lobules—terminating in a rich capillary plexus around the alveolus. Branches of the main arteries form an arterial plexus around the ducts—the ultimate terminals passing downward and dividing into a capillary network just beneath the epithelium lining the ducts. There is a well-marked capsular plexus derived from vessels in the periglandular connective tissue. Venules are formed from the capillaries; veins follow the course of the arteries, leaving the hilus of the lobule to give rise to the venae comites of the main arteries. The growth of a column of cells and budding epithelium is evidently sufficient stimulus for the growth of blood vessels to accompany them. Blood vessels mark out the route followed by the cell troups of the gland in development—forming, in a measure, a record of the ontogeny of its parts (Flint, 1902 to 1903).

The lymphatics also are distributed to the gland by means of the interlobular septa. They are relatively few in number, draining into the cervical vessels and so on into the cervical lymph nodes.

IX. THE SALIVARY GLANDS OF MAN

The salivary glands of man include all the small glandular organs situated in close relation to the mucous membrane of the buccal cavity, known respectively as the labial, buccal, molar, palatine and lingual glands, including a rather complex mass of glands situated in the anterior portion of the tongue known as the anterior lingual glands (glandulae lingualis anteriores—Blandini, Nuhini). In addition to these there are three, and in some cases four large salivary glands situated at some distance from the buccal cavity with which they communicate by long or short ducts. These glands are the parotid, the sublingual, the submaxillary and the variable gland of Bartholin sometimes called the major sublingual gland. This gland evidently corresponds to the retrolingual gland of other mammals (retrolingual gland of Ranvier, glandula sublingualis monostomatica of Illing). It is not clear whether the gland so recognized in man is always the homologue of the retrolingual or whether it is sometimes a displaced portion of the submaxillary gland. The duct sometimes opens alongside of the duct of the submaxillary gland by a separate opening on the caruncula sublingualis; in other cases it joins the submaxilaris duct. Illing found this gland present in five out of forty-four cases in twenty-two subjects.

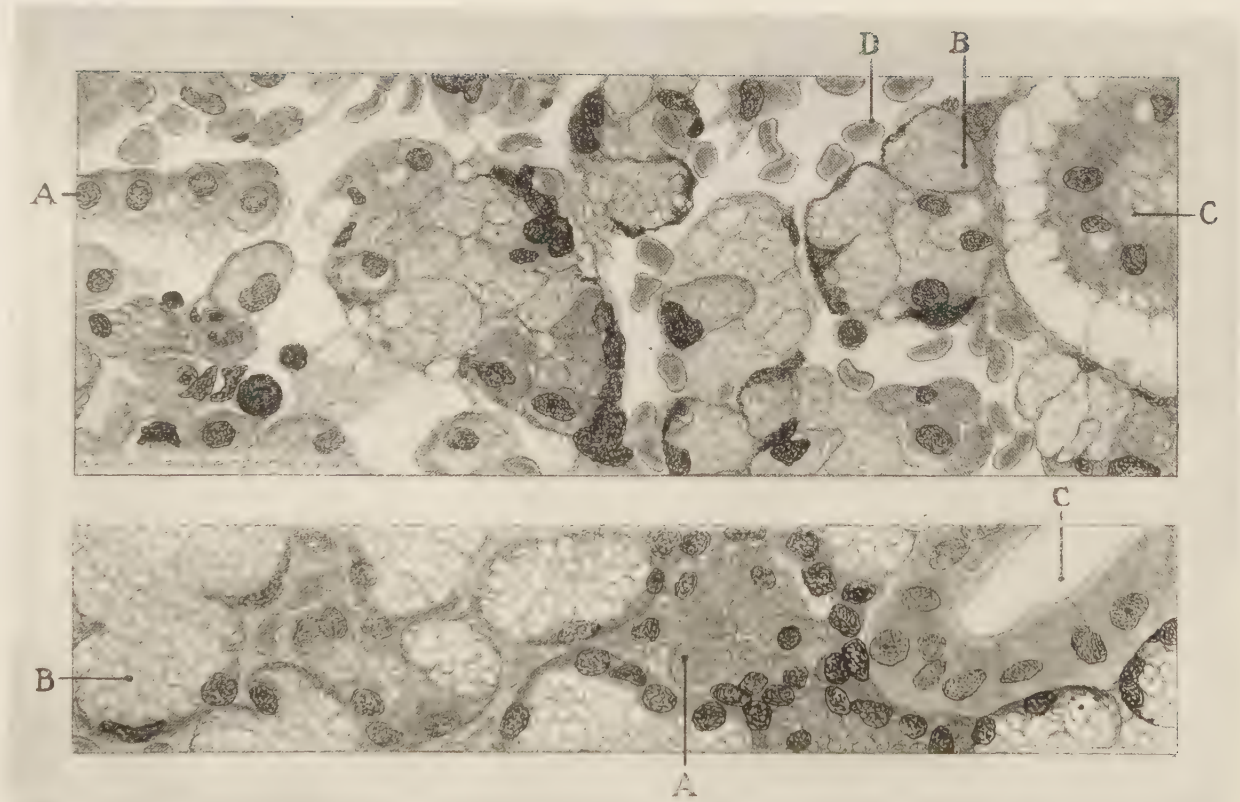

FIG. 44. (1) Y. L. 28. A section of the submaxillary gland of the rabbit. Left chorda tympani stimulated with faradic current for period of six hours. A, exhausted and necrotic homeochrome cells; B, tropochrome cells—show very little change; C, marked shrinkage and exhaustion of intralobular duct; D, Extravascular blood cells. (2) Y. R. 28. Control glandof opposite side. A, homeochrome cells. B, tropochrome cells; C, intralobular duct. Note contrast in cell groups of the two glands. Fixation Orth's fluid stained with aniline acid fuchsin. Leitz oil immer. $\frac{1}{12}$ oc. 4–60.

The sublingual and submaxillary glands are mixed, the sublingual being overwhelmingly mucous in contrast to the decidedly serous character of the submaxillary. The submaxillary contains both mucous and serozymogenic cells. The sublingual needs further study in order to identify the various serous cell groupings. The parotid is presumably of a serozymogenic type, although some small percentage of mucous alveoli are to be found.

In most cases the cells of the intralobular ducts exhibit similar staining reactions to the homeochrome group of serous cells. According to Pischinger the intercalary and intralobular ducts may be considered secretory in nature.

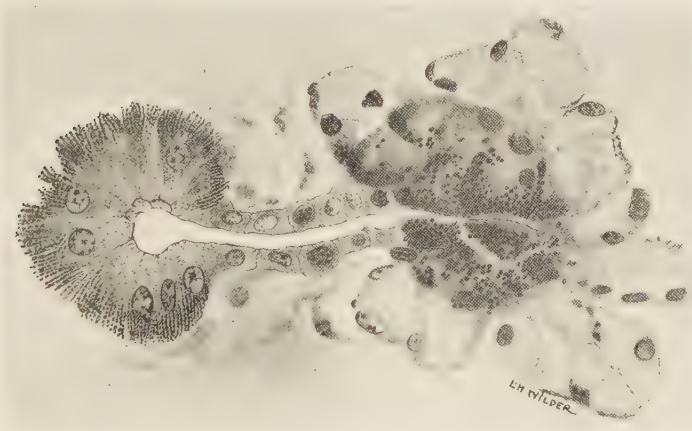

FIG. 45.—A gland alveolus, with its accompanying intercalated duct leading into an intralobular duct. Stained in iron hematoxylin. Leitz homeog. immer. 1/12 oc. 4. (After Cohoe.)

1. *The parotid gland:*

The parotid gland is the largest of the salivary glands, as well as the first to develop. The main duct (Stenson's) opens into the oral cavity opposite the second upper molar tooth. It is a branched tubulo-acinar gland, chiefly serous, although containing a small proportion of mucous alveoli. Mucous acini are also to be found along Stenson's duct in the so-called accessory lobules. Fat cells occur frequently in the connective tissue septa between the alveoli. They increase in number and are more prevalent with age. The cells of serous alveoli are pyramidal or polyhedral in shape. The cytoplasm is abundant and is filled with large, highly refractive granules which do not exhibit metachromatism to dyes such as thionin or toluidine blue after fixation in Orth's or Kopsch fluids. The nucleus is large, oval or spherical in shape and situated towards the center or base of the cell. The chromophile substance is abundant. The mucous cells conform to the characteristic mucous cell in its chemical and staining reactions.

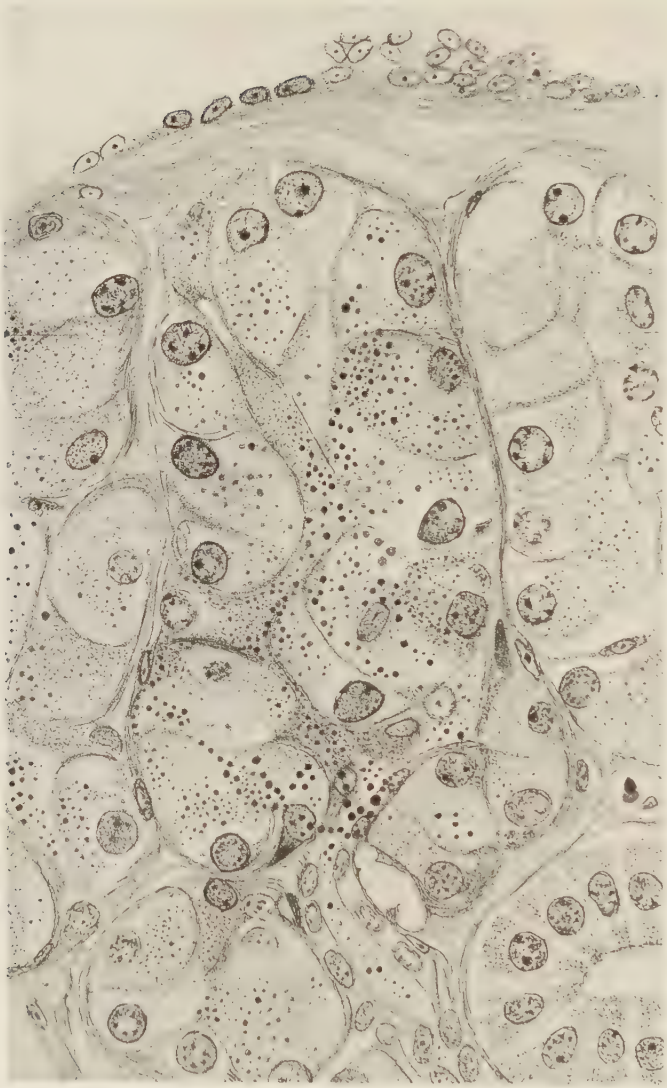

FIG. 46.—Human parotid gland. Oil immer. Leitz $\frac{1}{12}$ oc. 6 Formol-Zenker fixation. Aniline acid fuchsin and Wright's stain.

2. *The submaxillary gland:*

The duct of Wharton, or that of the submaxillary gland, opens into the mouth in front of the tongue. At the orifice of Wharton's duct there may be stratified epithelium, but this quickly becomes a double row of columnar epithelial cells, as in Stenson's (parotid) and Bartholin's major (sublingual) ducts. It is characteristic of the main and interlobular (excretory) ducts to

FIG. 47.—Portion of human parotid gland showing mucous alveoli.

have a double row of conical or columnar epithelial cells. The parenchyma of the gland contains both mucous and serous alveoli, although the serous far outnumbers the mucous. The mucous cells are capped by serous cells called the demilunes or crescent cells. These crescent cells exhibit the same characteristic features as the serous acini. The cytoplasm is abundant, containing a marked amount of large highly refractive granules and chromophile substance. The nucleus is large and spherical. The mucous cells comprise only a small portion of the entire gland. The serous cells are com-

parable in chemical and staining reactions and general appearance to the serozymogenic type.

A definite connective tissue stroma envelops each lobule, as well as the entire gland, and makes the septa. This is especially true for the parotid and submaxillary glands, although in the sublingual, labial and lingual glands no definite capsule is seen.

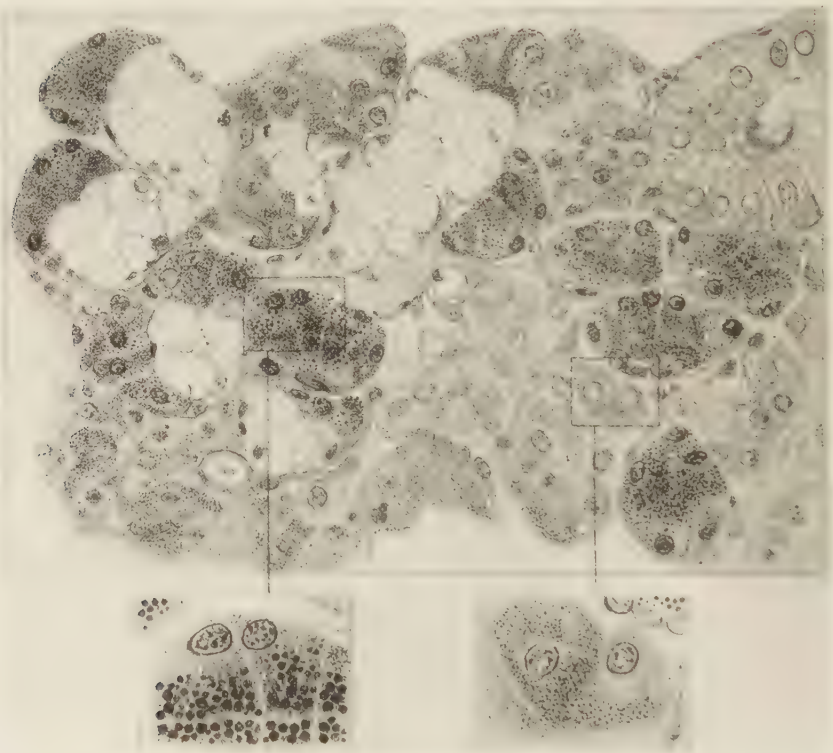

FIG. 48.—Human submaxillary gland showing both mucous and serous groups of cells. Fixation Muller's fluid. Stain, aniline acid fuchsin. Inserts are oil immer. Leitz $\frac{1}{12}$ of the respective fields in the picture as seen through the lens 6–48 oc. 12.5.

However, dense connective tissue septa may be found, which at the periphery spreads out into the adjoining mesenchymal tissue. Cells of the parasympathetic submaxillary ganglion are to be found in the connective tissue around the ducts and in the interlobular septa.

3. *The sublingual glands:*

The sublingual glands consist of the glandulae sublingualis minores and the variable glandulae sublingualis majores. The glands open by one or more ducts near that of Wharton's duct at the side of the frenulum of the

tongue. The duct of the minor is called the Rivinian, and that of the major, Bartholin. The sublingual is a tubulo-alveolar gland. The parenchyma is composed mainly of mucous acini. Demilunes are to be found around some of the mucous alveoli, although many mucous alveoli are to be found that do not possess crescents or demilunes. There are few pure serous acini. The mucous alveoli present the usual mucous cell pictures. The demilunes

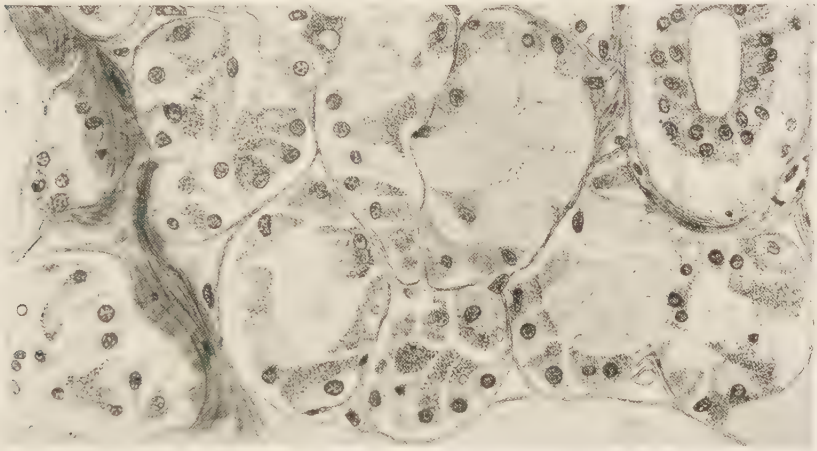

FIG. 49.—Human sublingual gland showing overwhelmingly mucous character. Formol-Zenker fixation, aniline acid fuchsin and Wright stain.

and serous cells are similar to the serozymogenic type of cell. The gland shows a greater proportion of connective tissue septa than either the parotid or submaxillary, although practically void of an investing capsule.

In mucous glands, the tubular and branched character is easily ascertained. The tubular and branched character of the parenchyma of serous glands is not so evident, owing to the fact that the alveoli are close and much convoluted.

X. BIBLIOGRAPHY

Altmann, R. 1894. *Die Elementarorganismen und ihre Bedeutung für die Zellen.* Ed. 2, Leipz.

Anrep, G. V. 1923. The metabolism of the salivary glands. IV. The metabolism of the reducing substance of the submaxillary gland. *J. Phys.*, **57**, 7.

Arey, L. B. 1924. *Developmental anatomy.* Phila.: W. B. Saunders and Co.

Arima, H. 1918. Uber die paradoxe Speichelsekretion bei chronische Atropinvergiftung. *Arch. f. exper. Pathol. u. Pharmakol.*, **83**.

Arnstein, C. 1895. Zur Morphologie der sekretorischen Nervendapparate. *Anat. Anz.*, **10**, 410.

Babkin, B. P. 1914. *Die äussere Sekretion der Verdauungsdrüsen.* Berl.: Julius Springer.

Bainbridge, F. A. 1900–01. Observations on the lymph flow from the submaxillary gland of the dog. *J. Phys.*, **26**, 79.

Barcroft, J. 1907. The velocity and nature of the blood emerging from the submaxillary gland of the cat during stimulation of the cervical sympathetic nerve. Proc. Phys. Soc. in *J. Phys.*, **35**, 29.

Barcroft, J., and Piper, H. 1912. The gaseous metabolism of the submaxillary gland, with especial reference to the effect of adrenalin and the time relation of the stimulus to the oxidation process. *J. Phys.*, **44**, 359.

Bayliss, W. M. 1920. *Principles of general physiology*. Ed. 3., Lond. and N. Y.: Longmans, Green and Company.

Bayliss, W. M., and Bradford, J. R. 1886. The electrical phenomena accompanying the process of secretion in the salivary glands of the dog and cat. (Abstr.) *Proc. Roy. Soc.*, **40**, 203.

Bensley, R. R. 1898. The structure of the mammalian gastric glands. *Quart. J. Mic. Soc.*, **41**, 361.

——— 1903. *The structure of the glands of Brunner.* Decennial Publications of the Univ. of Chicago. 279.

——— 1908. Observations on the salivary glands of mammals. *Anat. Record*, **2**, 105.

——— 1910. On the nature of the canalicular apparatus of animal cells. *Biol. Bull.*, **19**, 179.

——— 1911*a*. Studies on the pancreas of the guinea pig. *Am. J. Anat.*, **12**, 297.

von Bergen, F. 1904. Zur Kenntnis gewisser Strukturbilder. *Arch. f. mikr. Anat.*, **64**.

Bernard, C. 1864. Du rôle des actions réflexes paralysantes dans la phénomène des sécrétions. *J. de l'anat. et de phys.*, **1**, 507.

Boll, F. 1869. Die Bindesubstanz der Drüsen. *Arch. f. mikr. Anat.*, **5**, 334.

Bouin, P. 1905. Ergastoplasme et mitochondria dans les cellules glandulaires séreuses. *Compt. rend. Soc. de biol.*, **58**, 916.

Bowen, R. H. 1926. The Golgi apparatus—its structure and functional significance. *Anat. Record*, **32**, 151.

Bradford, J. K. 1888. Some points in the physiology of gland nerves. *J. Physiol.* **9**, 287.

Bujard, Eng. 1911. Réconstruction plastique des glandes salivaries d'un foetus humaine de 10 semaines environ. *Anat. Anz.*, **38**, 5.

Bunch, J. L. 1900. On the changes in volume of the submaxillary gland during activity. *J. Phys.*, **26**, 1.

Burton-Opitz, R. 1903. A method to demonstrate the changes in the vascularity of the submaxillary gland on stimulation of the secretory nerves. *J. Phys.*, **30**, 132.

Cannon, W. B., and Cattell, McK. 1916. Studies on the condition of activity in endocrine glands. 1. The electrical response as an index of glandular action. *Am. J. Phys.*, **40**, 143.

Carlson, A. J. 1907. Vaso-dilator fibers to the submaxillary gland in the cervical sympathetic of the cat. *Am. J. Phys.*, **19**, 408.

Carlson, A. J., Greer, J. R., and Becht, F. C. 1907–8. On the mechanism by which water is eliminated from the blood in the active salivary glands. *Am. J. Phys.*, **19**, 360.

Carmalt, C. 1913. *Contribution to the anatomy of the adult human salivary glands.* Crocker Research Fund. N. Y., **4**, 523.

Chambers, Robert. 1924. Physical structure of protoplasm. In *General Cytology* (Edited by E. V. Cowdry). The Univ. of Chicago Press, 237.

Chievitz, J. H. 1885. Beiträge zur Entwickelungsgeschichte der Speicheldrüsen. *Arch. f. Anat. u. Phys. Anat.*, Abt. 401.

Cohoe, B. A. 1907. The finer structure of the glandula submaxillaris of the rabbit. *Am. J. Anat.*, **6**, 167.

Cowdry, E. V. 1912. Mitochondria and other cytoplasmic constituents of the spinal ganglion cells of the pigeon. *Anat. Record*, **6**, 33.

DeMoor, J. 1913. Le mécanisme intime de la sécrétion salivaire. *Arch. Internat. de phys.*, **13**, 187.

Eberth, C. J., and Müller, Kurt. 1892. Untersuchungen über das Pankreas. *Ztschr. f. wiss. Zool.*, suppl., **53**, 112.

von Ebner V. 1872. Über die Anfänge der Speichelgänge in den Alveolen der Speicheldrüsen. *Arch. f. mikr. Anat.*, **8**, 481.

——— 1899. In Kölliker's *Handbuch der Gewebelehre des Menschen*, **3**, Leipz.

Eklöf, H. 1914. Chondriosomenstudien an den Epithel- und Drüsenzellen des Magen-Darm Kanals und den Oesophagus-Drüsenzellen bei Säugetieren. *Anat. Hefte*, **51**, 1.

Ferrarini, G. 1922. Sur l'innervation de la parotide. *Arch. ital. de biol.*, **61**, 40.

Ferris, H. C., and Smith, E. E. 1923. Physiological and pathological variations in the composition of human saliva. *J. A. Dent. Assoc.*, Huntington, Ind., **10**, 19.

Flint, J. M. 1902–03. The development of the reticulated basement membrane in the submaxillary gland. *Am. J. Anat.*, **2**, 1.

——— 1903. The angiology, angiogenesis, and organogenesis of the submaxillary gland. *Ibid.*, **2**, 417.

Garmus, Antonious. 1912. Die Permeabilität der Drüsenzellen für Farbstoffe. *Ztschr. f. Biol.*, **58**, 185.

Garnier, C. 1900. Contribution à l'étude de la structure et du fonctionnement des cellules glandulaires séreuses. Du rôle et l'ergastoplasme dans la sécrétion. *J. de l'anat. et de la physiol.*, **36**, 28.

Gerhardt, Ulrich. 1903. Ueber histologische Veranderungen in den Speicheldrüsen nach Durchschneiderung der secretorischen nerven. *Ztschr. f. d. ges. Physiol.*, **97**, 317.

Gesell, R. 1920–21. Studies on the submaxillary gland. Nos. 6, 7, and 8. *Am. J. Phys.*, **54**, 166, 185, 204.

Gildemeister, M. 1913. Über eine Veranderung von Zellmembranen unter nervösen Einfluss. *Résumés 9me congrés. internat. Physiol.* Gröningen, Suppl., **1**, 4.

Goldenberg, E. E. 1923–24. The mutual influence of secretory stimuli in the submaxillary of the cat. *J. Phys.*, **58**, 267.

Hammar, T. A. 1901. Notiz über die Entwicklung der Zunge und der Mundspeicheldrüsen beim Menschen. *Anat. Anz.*, **19**, 570.

Hammarsten, O. 1885. Studien über Mucin und mucinahnliche Substanzen. *Arch. f. d. ges. Physiol.*, **36**, 373.

Harvey, B. C. H., and Bensley, R. R. 1912. Upon the formation of hydrochloric acid in the foveolae and on the surface of the gastric mucous membrane and the non-acid character of the contents of gland cells and lumina. *Biol. Bull.*, **23**, 225.

Hebold, Otto. 1879. *Ein Beitrag zur Lehre von der Sekretion und Regeneration der Schleimzellen.* Inaug. Diss. Bonn. 33.

Heidenhain, Anton. 1870. *Über die acinösen Drüsen der Schleimhäute insbesondere der Nasenschleimhaut.* Inaug. Diss. Breslau. 22 pp.

Heidenhain, M. 1919–1920. Neue Grundlegungen zur Morphologie der Speicheldrüsen. *Anat. Anz.*, **52**, 305.

——— 1921. Über die Teilungsfähigen Drüseneinheiten oder Adenomeren sowie über die Grundbegriffe der morphologischen Systemlehre. *Arch. Entw.*, **49**, 1.

Heidenhain, R. 1865. *Ber. d. K. sächs, Ges. d. Wiss.* Leipz.

——— 1868. Beiträge zur Lehre von der Speichelsecretion. *Studien physiol. Inst. Breslau*, **4**, 88.

——— 1881–83. In Hermann's *Handbuch der Physiologie.* **5**, 29. Leipz.: F. C. W.Vogel.

Held, H. 1899. Beobachtungen am tierischen Protoplasma. 1. Drüsengranula und Drüsenprotoplasma. *Arch. f. Anat. und Physiol.*, Anat. Abt., 284.

Holmgren, E. 1903. Weiteres über die Trophospongien verscheidener Drusenzellen. *Anat. Anz.*, **23**, 289.

Hoven, Henri. 1910. Contribution à l'étude du fonctionnement des cellules glandulaires. *Anat. Anz.*, **37**, 343.

——— 1912. Contribution à l'étude du fonctionnement des cellules glandulaires. Du rôle du chondriome dans la sécrétion. *Arch. f. Zellforsch.*, **8**, 555.

Hoyer, H. 1890. Ueber den Nachweis des Mucins in geweben mittelst der Färbemethod. *Arch. f. mikr. Anat.*, **36**, 310.

Illing, G. 1904. Vergleichende makroskopische und mikroskopische Untersuchungen über die submaxillaren Speicheldrüsen der Haussaugetierre. *Anat. Hefte*, **26**, 385.

Jappelli, G. 1909. Recherches sur la sécrétion de la salive. III. Influence de la fréquence, de l'intensité et de la durée du stimulus électrique sur les propriétés chimico-physiques de la salive. *Arch. ital. di biol.*, **51**, 353.

Jonescu, D. 1909. Sur les conditions de la sécrétion salivaire réflexe et sur l'action de l'asphyxie sur la sécrétion salivaire. *Arch. Internat. Physiol.*, **8**, 59.

Keibel and Mall. 1910. *Manual of human embryology*. Phila.: Lippincott.

Klein, E. 1879. Observations on the structure of cells and nuclei. *Quart. J. Micr. Sci.*, **19**, 125.

——— 1882. On the lymphatic system and the minute structure of the salivary glands and pancreas. *Ibid.*, **22**, 154.

Kohnstamm, O. 1902. Vom centrum der Speichelsekretion usw. *Verhandlungen des Kongress f. innere Medizin.* Wiesbaden: Bergmann.

Kolatchev, A. 1916. "Recherches cytologiques sur les cellules nerveuses des Mollusques." *Arch. Russ. d'Anat., d'histol., et d'embryol.*, **1**, 383.

Kolossow, A. 1898. Eine Untersuchungsmethode des Epithelgewebes, besonders der Drüsenepithelium und der erhaltenen Resultate. *Arch. f. mikr. Anat.*, **52**, 1.

Kölliker, A. 1884. Grundriss der Entwickelungs geschichte des Menschen und der höheren Thiere. Leipz.

——— 1889. *Handbuch der Gewebelehre des Menschen*. Ed. 6, Leipz.

Krause, R. 1895. Zur Histologie der Speicheldrüsen: "Die Speicheldrüsen Igels." *Arch. f. mikr. Anat.*, **45**, 93.

——— 1897. Beiträge zur Histologie der Speicheldrüsen. Die Bedeutung der Gianuzzischen Halbmonde. *Ibid.*, **49**, 707.

——— 1923. Die Methoden zur Darstellung der Stoffwechselorganellen der tierischen Zelle im fixierter Präparat. In Abderhaldens *Handbuch der biologischen Arbeitsmethoden*. Berl. und Wien.

Krause, W. 1876. Allgemeine und mikroskopische Anatomie. In *Handbuch der menschlichen Anatomie*, **1**, Hannover.

Kultschizky, N. 1885. Zur Lehre vom feineren Bau der Speicheldrüsen. *Ztschr. f. wiss. Zool.*, **41**, 99.

Laguesse, M. E. 1893. Sur la formation des ilôts de Langerhans dans le pancréas. *Compt. rend. Soc. de biol.*, **45**, 9, 5, 819.

Langley, J. N. 1878. Some remarks on the formation of ferment in the submaxillary gland of the rabbit. *J. Physiol.*, **1**, 68.

——— 1879–80. On the changes in serous cells during secretion. *Ibid.*, **2**, 261.

——— 1885. The paralytic secretion of saliva. *Ibid.*, **6**, 71.

——— 1888. On the physiology of salivary secretion. *Ibid.*, **9**, 55.

——— 1889. On the histology of the mucous salivary glands and on the behavior of their mucous constituents. *Ibid.*, **10**, 433.

Langley, J. N. 1890. On the physiology of the salivary secretion. *Ibid.*, **11**, 123.
——— 1905–6. On the reaction of cells and nerve endings to certain poisons. *Ibid.*, **33**, 374.
Laserstein, Sigfried. 1894. Uber die Anfänge der Absonderungswege in den Speicheldrüsen und im Pankreas. *Arch. f. d. ges. Physiol.*, **55**, 417.
Lavdowsky, M. 1887. Zur feineren Anatomie und Physiologie der Speicheldrüsen insbesondere der Orbitaldrüse. *Arch. f. mikr. Anat.*, **13**, 281.
Leiberman, P. V. 1911. *Beiträge zur Physiologie der Sekretionsvorgänge.* Diss. Erlangen. 48.
Loewenthal. 1907–8. Drusenstudien. III. Die Unterkieferdrüse des Igels und der weissen Ratte. *Arch. f. mikr. Anat.*, **71**, 588.
Macallum, A. B. 1895. On the distribution of assimulated compounds of iron other than haemaglobin and haematins in animal and vegetable cells. *Quart. J. Micr. Sci.*, **38**, 175.
——— 1898. On the detection and localization of phosphorus in animal and vegetable tissues. *Proc. Roy. Soc.*, **58**, 468.
——— 1905. On the distribution of potassium in animal and vegetable cells. *J. Physiol.*, **32**, 95.
——— 1911. Oberflächenspannung und Lebensercheinungen. *Ergeb. d. Physiol.*, **11**, 644.
Macleod, J. J. R. 1922. *Physiology and biochemistry in modern medicine.* Ed. 4. St. Louis: C. V. Mosby Co.
McWhorter, G. L. 1917. The relations of the superficial and deep lobes of the parotid gland to the ducts and to the facial nerve. *Anat. Record*, **12**, 149.
Mevsky, W. E. 1923. The sympathetic innervation and the process of normal salivary secretion. *J. Physiol.*, **57**, 307.
Malloizel, Lucien. 1902. Sécrétion de la glande sousmaxillaire. *J. physiol. et de path., gén.*, **4**, 749.
Mathews. 1898. The physiology of secretion. *Ann. N. Y. Acad. Sci.*, **11**, 293.
Maximow, A. A. 1901. Beiträge sur Histologie u. Physiologie der Speicheldrüsen. *Schultze's Archiv*, **58**, 1.
Mayer, P. 1897. Über Schleimfärbung. *Mitth. d. zool. Stat. zu Neapel.*, **12**, 303.
Maziarski, St. 1900. Über den Bau der Speicheldrüsen. *Bull intern. de l'acad. des. sc. de cracovie.* Juillet.
Merkel, F. 1883. *Der Speichelröhren. Rektoratsprogramm.* Leipz.: F. C. W. Vogel. 28.
Metzner, R. 1907. Die histologischen Veränderungen der Drüsen bei Tätigkeit. *Handbuch der Physiol.* Nagel, **2**, 900.
——— 1909. Entwicklung, Bau und Funktion von Speicheldrüsen. *Zentralblatt f. Physiol.*, **23**, 286.
Michaelis, L. 1900. Die vitale Färbung der Zellgranula. *Arch. f. mikr. Anat.*, **55**, 565.
Mislawsky, N. A., and Smirnow, A. E. 1896. Weitere Untersuchungen über die Speicheldrüsen. *Arch. f. Anat. u. Physiol., Physiol. Abt.* 93.
Mouret, J. 1895. Contribution à l'étude bes cellules glandulaires (pancréas) *J. de l'anat. et de la physiol.*, **31**, 211.
Müller, Erik. 1895. Ueber Sekretkapillaren. *Arch. f. mikr. Anat.*, **45**, 463.
——— 1896. Drüsenstudien: 1. Die serösen Speicheldrüsen. *Arch. f. anat. u. Physiol.* Anat. Abt. 305. (*Ztschr. f. wissensch. Zool.*, **64**, 624.)
Müller, L. R. 1924. *Die Lebensnerven.* Berl.: Julius Springer.
Nassonov, D. 1924*a*. Der Exkretions Apparat (kontrakteil Vakuole) der Protozoa als Homologen des Golgischen Apparats der Metazoazellen. *Arch. f. mikr. Anat.*, **103**, 437.

Nassonov, D. 1924*b*. Das Golgische Binnennietz und seine Beziehungen zu der Sekretion. *Ibid.*, **100**, 433.

—— —— 1925. Zur Frage ueber den Bau und die Bedeutung des lipoiden Excretions apparates bei Protozoa. *Ztschr. f. Zell. u. Mikr. Anat.*, **2**, 87.

Noll, A. 1902. Das Verhalten der Drüsengranula bei der Sekretion der Schleimzelle und die Bedeutung der Gianuzzischen Halbmonde. *Arch. f. Anat. u. Physiol.*

Nussbaum, M. 1877. Ueber den Bau und die Thatigkeit der Drüsen. *Arch. f. mikr. Anat.*, **13**, 721.

Oppel, A. 1900. Lehrbuch der Vergleichenden Mikropischen Anatomie. **3**, 563. Jena: G. Fischer.

Parsons, F. G. 1911. On the form of the parotid gland. *J. Anat. and Physiol.*, **45**, 239.

Pflüger, E. 1866. *Die Endigungen der Absonderungsnerven*, Bonn.

Pischinger, A. 1924. Beiträge zur Kenntnis der Speicheldrüsen besondere der Glandula sublingualis und submaxillaris des menschen. *Ztschr. mikr. Anat.*, Forschung., **1**.

Prenant, A. 1913. Sur l'origine mitochondriale des grains de pigment. *Compt. rend. Soc. de biol.*, **74**, 926.

Regaud, C., and Mawas, J. 1909*a*. Sur les mitochondries des glandes salivaires chez les mamnifères. *Compt. rend. Soc. de biol.*, **66**, 97.

—— 1909*b*. Ergastoplasme et mitochondries dans les cellules de la glande sous-maxillarie de l'homme. *Ibid.*, **66**, 461.

—— 1919. Mitochondries et symbiotes. *Ibid.*, **75**, 47.

Schachet, S. S. 1915. On the gross morphology, topographical relations, and innervation of the human parotid gland. *Anat. Record*, **9**, 120.

Schafer, E. A. 1912. *Text book of microscopic anatomy*. Lond. and N. Y.: Longmans Green and Co.

Schaffer, Josef. 1897. Beiträge zur Histologie menschlichen Organe. *Sitzungsb. Akad. Wiss.*, Wien, **106**, 353.

—— 1908. Zur Histologie der Unterkieferspeicheldrüsen bei Insektivoren. *Ztschr. f. wiss. Zool.*, **89**, 1.

Schulte, H. von W. 1913. *The development of the salivary glands in man.* Crocker Cancer Research Fund. N. Y., **4**, 25.

Solger, B. 1894. Zur Kenntniss der secernierenden Zeller der Glandula submaxillaris des Menschen. *Anat. Anz.*, **9**, 415.

—— 1896. Über den feineren Bau der glandula submaxillaris des Menschen mit besonders Berücksichtigung der Drüsengranula. *Festschr. z. 70 Geburtstag von Carl Gegenbaur.*, **2**, 179.

—— 1898. Das Progymogen (Bensley) der menschlichen Glandula Submaxillaris. *69 verhandl. d. Gesellsch. deutsch Naturf. u. Ärzte.* Braunschweig, **2**, 240.

Solomovicz, J. 1908. Vom Centrum der Submaxillardrüse. *Neurol. Centralb.*, **27**, 724.

Stöhr, P. 1898. *Lehrbuch der Histologie und der mikroskopischen Technik.* Jena: Fischer. 400 pp.

—— 1905. Über die menschliche Unterzungendrüse. *Sitzungsb. d. phys.-med. Gesellsch. zu Würzb.*, **5**, 76.

Stormont, D. L. 1925. *Nerve endings and secretory activity in the submaxillary gland of the rabbit.* Univ. Chicago Pub. Theses. Also *Anat. Record*, 1926, **32**, 242.

Symington, J. 1912. Topographical anatomy of the salivary glands. *J. Anat. and Physiol.*, **46**, 173.

Takagi, K. 1925. Untersuchungen über die Unterkieferdrüse der Katze mit besondere Berüchsichtigung des chondrioms. *Ztschr. f. mikr. Anat.*, Forschung., **2**, 254,

Thoma, K. A. 1919. A contribution to the knowledge of the development of the submaxillary and sublingual glands in human embryos. *J. Dent. Res.*, **1**, 95.

Tschassonikow. *Archives Russes d'histologie et d'embryologie*, 1.

Wertheimer, E., and Battez, G. 1913. Sur le mécanisme de la sécrétion salivaire provoquée par l'injection d'eau salive dans les vaisseaux. *Compt. rend. Acad. d. sc.*, **141**, 1250.

Wilson, E B. 1925. The cell in development and heredity. Ed. 3, N. Y.: The Macmillan Co.

Zimmerman, K. W. 1898. Beiträge zur Kenntnis einiger Drüsen und Epithelien. *Arch. f. mikr. Anat.*, **52**, 552.

Section VI

THE GASTRIC GLANDS

CONTENTS

Section VI

PAGE

I. Surface Epithelium of Stomach 141
II. Cells of Gastric Glands 147
1. Body chief cells 148
2. Neck chief cells 155
3. Parietal cells 157
4. Cells of Heidenhain 160
III. Intestinal Elements in Mucosa Gastrica 161
IV. Reproduction of Cells of Gastric Glands 161
V. Bibliography 163

Section VI

THE GASTRIC GLANDS

R. R. BENSLEY

THROUGHOUT the vertebrate phylum the mucous membrane of the stomach is subdivided into two major areas, each characterized by the type of gastric gland which it contains. The proximal two-thirds of the stomach is occupied by the proper gastric glands (glandulae gastricae propriae), whose function, in general, is to produce the active elements of the gastric secretion, while the distal third is provided with glands, called the pyloric glands (glandulae pyloricae), whose function is, in the main, the production of mucus. In certain batrachians, notably in the frog, in *Necturus*, and in the larval stages of *Amblystoma*, the anterior groups of gastric glands are especially modified, and have been set aside by comparative anatomists as esophageal glands. The portion of the foregut which they occupy in these species is thus identified with the esophagus.

In mammals the same groups of glands are to be found as in lower vertebrates, but the glandulae gastricae propriae (fundus glands) have been profoundly modified in many mammals, particularly at the transition of the esophagus into the stomach, to produce a new group which, since their description by Edelmann (1889), have been termed, because of their relation to the cardiac orifice of the stomach, "cardiac glands." This term was originally used by many English writers to designate the glandulae gastricae propriae, but should now be reserved exclusively for the special glands which occupy the zone of mucous membrane around the cardiac orifice.

In many mammals belonging to several different orders, the gastric glands have wholly disappeared from smaller or larger areas of the mucous membrane, and the epithelium of these areas has been changed to a stratified epithelial type similar to that of the esophagus. For that reason, and on account of the fact that in the course of phylogenesis such areas have been frequently isolated in special chambers of the stomach, these have frequently been interpreted as of esophageal origin and referred to as esophageal sacs or areas. In some mammals this process of replacement of the glandular mucous membrane has proceeded to such a degree that the whole stomach is without glands and lined only by stratified epithelium. This is the case in the monotremes. In others, as, for example, in the genera *Arvicola* and *Fiber*, it has obliterated the glands of the fundus ventriculi and advanced into the pyloric region and replaced most of the pyloric glands. In such cases the fundus glands are confined to a disc-like mass, located on the greater curvature of the stomach and surrounded on all sides by epithe-

lium of the esophageal type. In the pig the process of transformation is at an early phase, inasmuch as the esophageal type of mucous membrane occupies only a small region around the cardiac orifice of the stomach. In this animal, however, a large proximal area of glands in the fundus region is of the nature of cardiac glands, and this type of gland is interpreted by Bensley (1902) as an intermediate phase in the regression of the fundus glands and their replacement by a mucous membrane of the esophageal type. Similar modifications of the fundamental plan have been described in marsupials by Schafer and Williams (1876).

Whatever their location, these various types of glands are made up of cellular types which have their prototypes in the glandulae gastricae propriae, and the cells of the latter glands will accordingly be made the subject of the discussions in this article. They are of five different sorts: (1) the surface epithelium of the stomach and of the gastric foveolae; (2) the neck chief cells of Bensley (1896); (3) the parietal cells (delomorph cells of Rollett) known to the early histologists as peptic cells; (4) the body chief cells ("Grundhauptzellen" of Oppel), and (5) certain small cells first observed by Heidenhain, found attached to the outside of the fundus gland and containing peculiar granules which may conveniently be known by the name of their discoverer as Heidenhain cells.

Before proceeding to a description of these various types of cellular elements composing the gastric glands, it may be well to point out that, in general, the cytological characters by which we are enabled to distinguish between them are those characters which are imposed upon them by the nature of the secretory products which they form, and by the various antecedent substances to these secretory products which may be recognized in the cell. Indeed, in many glandular cells the fundamental structure of the cells is completely masked by the presecretory materials which are present in them. We know at present next to nothing about the chemical processes which are incident to secretory activity, but enough to justify the presumption that a series, perhaps several series of converging chemical processes, are concerned in the preparation of the specific chemical components of the secretion out of the vastly different materials furnished by the blood. The varying rates of these several processes will determine the amount of any particular antecedent substance in the cell, and the levels at which equilibrium is established will determine the average aspect of the cell, either in the fresh living condition, or in fixed and stained material in which the respective substances are preserved. It is obvious, and it is indeed true, that cells which are strictly homologous with each other and concerned in the same sort of activity, by reason of the different levels at which equilibrium is attained with reference to the rates of the various phases in their presecretory processes, may seem under the microscope to be very different from each other. It is the task of the cytologist, as yet unfortunately only begun, to attempt to recognize as accurately as may be those substances which are concerned in the formation of the secretion, and to piece together ultimately the fragments into a logical sequence, and elucidate the part played in the process by each of the specific organoids of the cell structure and by the invisible components as well.

During the period which began with the important and significant discoveries of Heidenhain and Langley in the secretory history of cells, various substances and structures have in turn received the attention of cytologists as being especially concerned in

the production of secretions. Among these may be mentioned the nucleus which has been credited with exercising an important influence, either directly or indirectly, by means of substances contributed to the cytoplasm. For a time the stainable material of the cytoplasm received a great deal of attention, as, for example, in the researches on ergastoplasm by Garnier (1900) and others in France, the prezymogen of Mouret (1895), the basal filaments of Solger (1894) and the prozymogen of Macallum (1891) and Bensley (1898). With the rediscovery of Flemming's fila and Altmann's bioblasts as mitochondria and chondriomites by Benda, and the development of a new interest in the study of the living cell in which these structures are visible, and of new methods which greatly facilitated their study, the interest shifted to the chondriosomes, as these elements were now almost universally termed, and the chromophile materials or structures were wholly forgotten, because in general the mitochondrial methods were unsuitable for their demonstration, or because the investigator was committed in advance to the erroneous hypothesis that these materials were badly fixed mitochondria. At the present moment the scene has shifted again and both mitochondria and chromophile materials are disappearing from the picture to give place to the reticular apparatus of Golgi as the sovereign structure concerned in the production of secretion.

Although these researches have covered a period of seventy years since Claude Bernard's (1856) discovery of the secretory antedecents in the cells of the pancreas, the theme is yet too young, and the advances all too meager, to justify at this time a critical decision as to the part played by these various structures and substances in the formation of secretions. It would be a mistake, in the writer's opinion, to attach at this time preeminent importance to any of them. It would seem to be better to record the facts elicited by research, and to leave the synthesis and interpretation of these facts to the future, unencumbered by hypotheses which tend to submerge the issues and to invite unprofitable polemics. For these reasons the writer in the descriptions of the gastric epithelial elements which follow will endeavor to adhere to the objective point of view.

I. THE SURFACE EPITHELIUM OF THE STOMACH

The surface of the gastric mucous membrane, and of the foveolae gastricae which open into it, is covered by a single layer of columnar epithelial cells of a sort found only in association with gastric glands. Areas covered by similar epithelium have been reported by Schaffer (189-), Rudinger (1879) and Hewlett (1901) in the upper portion of the esophagus opposite the cricoid cartilage, but even here it is associated with glands that resemble the cardiac glands of the stomach and contain parietal cells and both kinds of chief cells. In Meckel's diverticulum this type has also been reported again associated with gastric glands. In the Virginian opossum Bensley (1903) reported patches of true gastric epithelium surrounding the orifices of the ducts of the glandulae duodenales (Brunneri). The type is fairly constant throughout the vertebrate phylum, and with a few exceptions lines the cavities of all stomachs from fishes to primates. The exceptions to this rule are few; Oppel (1896) reports the occurrence of characteristic goblet cells between epithelial cells of the usual type in *Lophius piscatorius;* a similar condition is found in the anterior portion of the stomach of *Bufo;* ciliated epithelium with goblet cells covers the area of the frog's stomach containing the anterior gastric glands, usually termed

esophageal glands, and the corresponding portion of the foregut of *Necturus* containing peculiar flask-shaped gastric glands. The latter have been found by Bensley in larval *Amblystoma* where they finally transform into characteristic anterior gastric glands.

The cells which compose this epithelium are high cells of the columnar type but highly plastic so that they adapt their shapes to the tensions and extent of the mucous membrane on which they rest (Heiderich, 1911). In a stomach fixed in extension they may be short and wide cylinders, while clipped pieces from the same stomach allowed to contract will show high narrow cells. Where they cover a convex surface they are in general conical in shape with the base of the cone on the free surface, but on concave surfaces may present an irregular quadrilateral section with the broader end on the basement membrane. The individual cells of this complex are separated from one another at the surface by lines of cement substance ("Kittleisten,"—terminal bars), which, according to Bensley (1902), also extends in irregular lines over the slightly arched free end of the cell, giving to it, in some cases where the preparations have been stained with iron hematoxylin, a deceptive resemblance to the outer end of an intestinal cell. The lateral surfaces of the cells appear in well-fixed preparations to be in contact, but in reagents which produce some shrinkage they are separated from one another by narrow spaces crossed by intercellular bridges (Ogneff, 1892), especially well shown also in the preparations made by the osmic acid method of Kolossow (1898).

In the light of the recent observations of Chambers and Rényi (1925) on the interrelations between epithelial cells as revealed by microdissection, it seems probable that both intercellular spaces and bridges in this epithelium are artefacts, and that the cells are merely joined together at the free surface by the substance of the lines of cement.

In the fresh condition, examined in homologous serum, or in amniotic fluid, these cells show a remarkable transparency, but the chief divisions can be seen. The outer extremity of the cell presents the appearance of closely packed minute granules occupying an area of variable extent at the free border (Schulze, 186–). This area corresponds to the theca filled with secretion in the fixed cell. In undamaged cells this mass of secretion granules is sharply limited at its free edge and the cell is in no sense freely open to the exterior. Internal to the theca the cytoplasm is very transparent and consists of an optically structureless matrix in which minute filamentous mitochondria are visible. The nucleus appears under these conditions as an oval clear spot with one or two refractive nucleoli in it located between the theca and the attached pole of the cell.

Fat droplets may occasionally be seen in the cytoplasm of the cells of the surface epithelium. They have been particularly studied by Ogneff (1892) who considers them in connection with a possible participation of the

epithelium of the stomach in resorption. Although rare in the stomach epithelium of mammals, they may be very conspicuous in the large cells of the surface of the stomachs of batrachians, particularly just at the base of the mass of secretion. Ogneff's statement that they occur also between the cells, so far as I know, lacks confirmation.

The presence in these cells of two highly labile materials, namely, the secretion and the mitochondria, makes the preservation of them without alteration a very difficult matter. It is further hindered by the fact that the secretory contents of homologous surface cells from different animals may behave very differently toward fixing reagents and afterward toward stains.

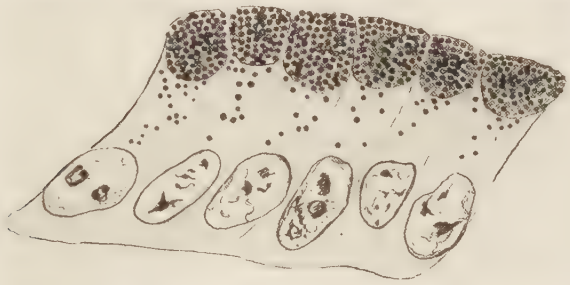

FIG. 50.—Surface epithelium of the human stomach. Alcohol-sublimate-bichromate fixation; hematoxylin and mucicarmine.

These differences are presumably not fundamental chemical differences, although it may be presumed that there is as much specificity chemically between homologous secretions as there is between homologous globulins in the blood. The staining reactions of the secretion are particularly uncertain where aniline dyes are employed, presumably because of their sensitiveness to minute degrees of difference in gel concentration and permeability in the secretion antecedents. The writer has found that of all the stains applicable to the staining of mucins in gastric gland cells, the most uniformly successful are the mucicarmine and muchematein of Mayer modified by a fivefold increase of their contents of hematein or carmine on the one hand and of aluminum chloride on the other and used without preliminary water treatment of the section or dilution of the dye solution. Figure 50 is a drawing of a group of surface epithelial cells from a preparation of human stomach fixed in alcoholic bichromate sublimate and stained with hematoxylin and mucicarmine. The nucleus, only, stains with hematoxylin, and the secretion, only, with mucicarmine. At some distance below this mass may be seen the oval nucleus stained with hematoxylin. This requires no especial description, since it has no special characters other than its shape to distinguish it from the nuclei of glandular cells of other types. It is rich in chromatin in the form of pyramidal masses peripherally located and has

LANE LIBRARY, STANFORD UNIVERSITY

one or two eosinophile nucleoli. On close inspection of such a preparation a very interesting fact comes to light; namely, the carmine-stained secretion is not confined to the theca but occurs also in the form of scattered granules in the area between the theca and the outer pole of the nucleus, in brief, in that area of the cell where the Golgi reticular apparatus is found. Attention was first directed to this inner mass of secretion by Bensley (1898) who studied it particularly in the cells found at the bottom of the foveolae in the stomach of the cat. Krause (1895) had, however, noted that in the mucous cells of the retrolingual gland of the hedgehog the transformation of antecedents into stainable mucin took place first near the nucleus. Later Maximow (1901) studied the phenomenon in the retrolingual gland of the dog, and Bensley (1903) in the cells of the glands of Brunner. The latter says:

"In the writer's opinion the obvious division of the secretion into two masses is due to the fact that the new secretion is formed in the neighborhood of the nucleus in the interior of the cell. This may be due, as suggested above, to the action of enzymes produced by the nucleus, or it may be due to the effect of the presence (of which the writer has not yet been able to obtain evidence) in these cells of structures similar to the so-called trophospongium observed by Holmgren in various epithelial cells."

This alternative has quite recently been taken up vigorously by Nassonow (1923, 1924, 1926) and Bowen (1923, 1924, 1925) who, working with the excellent methods of Kolatchev (1916), have been able to demonstrate, in preparations suitable for study at once from the standpoint of secretion, mitochondria, and Golgi apparatus, and in a wonderfully objective series of studies, the close relation between the elements of the Golgi reticular apparatus and the newly formed secretion granules. It is too soon to speculate about the nature of the nexus between these two constituents, but it is apparent that the Golgi apparatus is in some way or other concerned in secretion. In the stomach of the rabbit the internal mass of new secretion may be considerable, and the same is true of the epithelial cells of the bottoms of the foveolae in the stomach of man and of some other mammals where export of secretion presumably is slow and the cells present a narrow theca along the free margin of the cell and a well-defined mass of granules in the neighborhood of the nucleus.

The mitochondria of the stomach epithelium has been particularly studied by Hoven (1912) and Eklöf (1914). Hoven described the mitochondria as consisting of long filaments which extend from the attached pole of the cell to the mass of secretion in cells in which the latter is poorly developed. In cells with a well-developed theca, he says, the mitochondria are much less numerous and are disposed around the nucleus and below it. In the narrow layer of protoplasm which surrounds the theca also mitochondria were seen, and many were also visible in the small accumulation of cytoplasm at the free surface of the cell.

Eklöf (1914) studied the mitochondria in the gastric epithelium of man, rabbit and dog by the method of Kolster (1913). His results agree in the main with those of Hoven except for the fact that he finds in his preparations the mitochondria in the form of granular units arranged in rows parallel to the long axis of the cells. He notes also that they are particularly concentrated at the base of the theca and are more easily stained in that location. In preparations of surface cells of the stomach made in this laboratory by Wen Chao Ma, by the method of Bensley (1912), the mitochondrial content of these cells is seen to be very rich, consisting of minute filaments particularly concentrated at two points, namely, the immediate

a b

FIG. 51.—Surface epithelium of stomach showing Golgi reticular apparatus. a, from the surface of the stomach. b, from the foveolae. (After Golgi, 1893.)

vicinity of the mass of secretion and the attached base of the cell. They are present in smaller numbers in the remaining cytoplasm, but are scarce in the portion of the cell which research by other methods shows to be the site of the internal reticular apparatus of Golgi.

The Golgi apparatus of the surface cells has been studied by Golgi (1909) D'Agata (1910) and Kolster (1913). According to the former, the apparatus in the superficial cells of the stomach consists of a close network of stainable material situated around the nucleus on the under side of which the strands unite (Fig. 51). Toward the free surface the strands terminate in free ends. In the cells of the sides of the foveolae the apparatus gradually shifts its position, becoming first perinuclear, and then supranuclear in position as the cells deeper in the foveolae are examined. In the *Triton*, D'Agata (1910) found the apparatus normally located in the portion of the cell between the nucleus and the theca, but after mechanical irritation of the surface the cells lost their theca and the Golgi apparatus changed its position to

the base of the cell surrounding the proximal portion of the nucleus. The apparatus has also been studied in these cells by Holmgren (1904) by the methods devised by him, but he contents himself by saying that in general type and location the "Saftkanälchen" of these cells resemble closely those of the intestinal epithelial cells.

In preparations of the human stomach fixed in sublimate and stained with iron hematoxylin Zimmermann (1898) has succeeded in demonstrating the centrioles and spheres in the epithelial cells of the stomach (Fig. 52). According to him they consist of a small stainable particle or pair of particles located in the middle of the mass of secretion, which he considers to be a proof that the secretion mass contains cytoplasmic constituents as well. Around the centriole or centrioles, as the case may be, is visible a minute sphere, and the latter is sometimes connected with the body of the cell by a delicate filament traversing the mass of secretion. In cells about to undergo division the sphere and its contained centrioles retreat into the cytoplasm and the nucleus moves outward so that the mitotic process is effected at a more superficial level than that occupied by the nucleus of the resting cell.

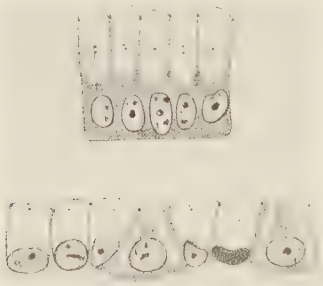

FIG. 52.—Human stomach; sublimate fixation; iron hematoxylin. Centrospheres in stomach epithelial cells. a, surface cells. b, neck chief cells and parietal cells. (After Zimmermann, 1898.)

The presence of glycogen in the cells of the surface epithelium has been demonstrated by Barfurth (1885), Fichera (1904) and Heiderich (1911). The latter has compared the results of the iodine and the carmine methods and reports that the glycogen was contained in large quantities in the bases of the cell. This glycogen disappears from the cell on long fasting and is not influenced by the introduction of glucose into the stomach. The author concludes that the stomach receives its glycogen exclusively by way of the blood stream and not by resorption.

The foveolae gastricae are lined by cells similar to those of the free surface, but there is a gradual change in their character as the gland proper is approached. Tall and columnar at the entrance of the foveolae and provided with a large mass of secretion, they become shorter as the bottom of the foveola is approached, and the theca becomes smaller and smaller. At the bottom of the foveola the theca may be but a narrow margin along the lumen. While this change is manifested, a corresponding change is apparent in the scattered granules which occupy in part the site of the Golgi apparatus. These become more numerous and may form in the lower cells of the foveolae considerable masses of mucin-antecedent in the interior of the cell near the nucleus. This, coupled with the fact that the cells of this region

are frequently seen in mitosis, suggests that there is a disturbance in the equilibrium of processes concerned in the formation of the new secretion and its transport to the surface, and that the cells of this type have for their major function the replacement of the surface epithelium. This idea has been especially elaborated by Bizzozero (1893) who suggests that the cells of the bottoms of the foveolae are incompletely differentiated cells which multiply by mitosis, and gradually migrate up the sides of the foveolae to replace finally the cells lost on the surface. In accordance with this hypothesis, which the writer fully accepts, cells are constantly found on the surface which are in various stages of dissolution, and desquamated cells are frequently found in the slime which covers the surface.

II. THE CELLS OF THE GASTRIC GLANDS

Prior to the classical researches of Heidenhain on the structure of the gastric glands the latter were considered by histologists to be formed exclusively of one type of cell, then known as rennin cells ("Labzellen"), and in the article of F. E. Schulze (1867) these are described as situated in minute crypts of the supporting tissue and opening into the cavity of the gastric glands by minute openings in their connective tissue sheaths, through which a portion of the cell may project. Schulze definitely rejected the opinion held by earlier observers that the cells were desquamated in secretion and discharged with it.

The discovery by Heidenhain (1870), independently confirmed by Rollett (1871), that, in addition to the "Labzellen," which he termed because of their peripheral location "Belegzellen," there was a second type of cell which he termed "Hauptzelle," forming a complete lining to the gland, may be regarded as the beginning of a new era in research on the structure of the glands of the stomach. Much of our present knowledge of the structure of the cells of the stomach is due to Heidenhain (loc. cit.) who studied them intimately in a number of vertebrates and in different phases of their secretory activity. To Heidenhain we owe in particular our conceptions of the nature of the cells composing the glands, of the character of the secretion antecedents in them and the fundamental hypotheses concerning the specific contributions of his two types of cells to the constituents of the gastric secretion. These two types of Heidenhain are known as parietal cells and as chief cells respectively.

In addition to these two types of cells Heidenhain discovered a third type of cell in the form of minute oval elements found adhering to the external surface of the epithelial tube, and particularly conspicuous in preparations made with bichromate solutions in which they stained a deep yellow color.

In 1896 Bensley analyzed cytologically the cell types of the gastric glands of mammals and showed that the cells ordinarily classed as chief cells were of two sorts, differing from one another in cytological structure

and in the nature of their secretion antecedents and products. The chief cells of the neck of the gland were mucous in nature, while those of the body of the gland were similar to the cells of the pancreatic acini and presumably zymogenous in nature. To the first class he applied the term neck chief cells and to the latter body chief cells. In the same and later researches he showed that the neck chief cells, the cells of the pyloric glands and the cells of the cardiac glands belonged to the same type. Hence, a cytological discussion of the neck chief cell comprehends all of the other types. Accordingly we have to consider in the gastric glands proper the following cells: cells of Heidenhain; neck chief cells; body chief cells; parietal cells. In addition special cells have been described in the gastric glands by Nussbaum (1879), Stöhr (1882) and Hamburger (1889) which have not yet been adequately defined cytologically.

1. *The body chief cells:*

The mucous membrane of a mammal's stomach, examined in the fresh condition in homologous serum shows under the low power of the microscope a division into three distinct zones: a deep zone which is more opaque than any other part of the mucous membrane, an intermediate zone which is transparent, and a superficial zone which is less transparent (Fig. 53). The deep opaque zone owes its opacity to the granules in the body chief cells; the intermediate clear zone is the area occupied by the neck chief cells, and the superficial, less transparent zone is the area of the foveolae gastricae. These areas are well shown in the photomicrograph of a fresh section of cat's stomach shown in Figure 53. The transparency of the neck of the gland is due to the fact that the secretion granules of the cells differ but little in refractive index from the medium in which they are immersed. Similarly the parietal cells offer but little resistance to the passage of light. Studied under the high power the body chief cells are seen to contain discrete granules which vary in size and number from species to species and from period to period of functional activity.

Our knowledge of these facts rests particularly on the fundamental observations and experiments of J. N. Langley (1879 to 1882), who showed that the granules in question accumulated during periods of fasting and diminished in number and in size during periods of active secretion. Langley (1880 to 1882) demonstrated also that the pepsin content of the mucous membrane varied directly with the content of chief cells and was independent of the number of parietal cells, thus confirming the earlier conclusions reached by Heidenhain on different grounds, that the body chief cells were the sources of the pepsin of the gastric juice. Langley also confirmed on more satisfactory grounds the conclusion of Ebstein and Grützner (1874) that the pepsin existed in the mucous membrane not as pepsin but as an antecedent which he called pepsinogen.

In view of these facts subsequent observers have used for these granules in the body chief cells the term "zymogen granules." It must be remembered in this connection, however, that while the evidence is convincing that the body chief cells are the sources of pepsin, there is no adequate microchemical method for recognizing the enzyme in the cells, and the term "zymogen granules" applied to the granules represents at the present time merely a plausible approximation.

The degree of loading of the cell with zymogen granules after prolonged rest is a specific character which varies as between species, and in



FIG. 53.—Photomicrograph of section of fresh mucous membrane from the stomach of the cat mounted in aqueous humor showing the granular aspect of the body of the gland and the transparent neck of the gland.

some mammals from point to point in the same stomach. For example, in the stomach of the rabbit the body chief cells of the fundus ventriculi in the period of rest are filled from end to end with coarse granules, while the similar cells from the middle of the great curvature of the same stomach show only a few granules of small size along the lumen of the gland, and an extensive outer granule-free area. Secretory activity in the two locations has the same course and the same result, differing only in degree. In either case the granules are diminished during secretion and the clear area is relatively enlarged. In the fundus region a clear area not visible in the fully loaded cell makes its appearance. During the process of secretion the body chief cell diminishes in size. The cytoplasm of the chief cell shows in the natural condition a remarkable degree of transparency. In it may be seen, either unstained, or after supravital staining with Janus green B

the filaments and rods of the mitochondria. These are very coarse and numerous in the discharged cell, apparently less numerous and smaller in the loaded cell. The fundamental substance of the cell shows no visible structure whatever, although in advanced stages of secretion vacuoles filled with clear fluid may be present, or minute fat droplets in the base of the cell.

When treated with diluted acid the chief cells of the body become turbid, owing to the precipitation of some of their constituent proteins. This phenomenon, discovered by Heidenhain (1870), is also true of the acinous cells of the pancreas and constitutes a difference of primary importance between these cells and the other glandular elements of the stomach to which reference will again be made.

The behavior of the zymogen granules in relation to fixing agents can in no sense be generalized. Langley was the first to succeed in fixing the granules by means of osmic acid. Bensley fixed them with a mixture of bichloride of mercury, potassium bichromate and alcohol in the gastric glands of the cat, but this method was absolutely unsuccessful in the glands of the dog. The introduction of formaldehyde has much improved the situation but the fixation of these elements is still somewhat precarious, and care should be taken in the study of the cells not to confuse imperfect fixation with functional changes. The examination of the fresh material should always serve as a check on the imperfections of fixations and staining.

Figure 54 is drawn from a preparation of the gastric glands of man fixed in Bensley's alcoholic bichromate sublimate solution and stained with toluidine blue. In this preparation the body chief cells show two well-defined zones: a superficial zone containing the cytoplasmic framework occupied by the zymogen granules and a basal zone presenting an obscurely striated appearance, but clearly defined by the depth of staining with toluidine blue due to the presence in the cytoplasm of special substances to which attention was first drawn by Bensley (1896, 1898). Bensley showed that this substance not only was easily localized by its property of staining with nuclear stains, but that it actually contained iron in organic combination as shown by the microchemical method of Macallum (1895). Bensley interpreted this substance as a chromatin-like material of nuclear origin serving as an antecedent substance to zymogen and termed it "prozymogen." This interpretation must now be revised in the light of more recent researches, but the fact remains that these cells contain in their cytoplasm a special iron-holding material which is not present in conspicuous amounts in the cytoplasm of other glandular elements of the stomach, but is present in the similar zymogenous cells of the pancreas.

In the researches which followed Bensley's, the morphological motif has predominated, and the chemical specification of this material has been

overlooked. The increase in osmic acid reducing power noticed by Langley, and the precipitation of the cytoplasm by dilute acetic acid noted by Heidenhain in both types of cells which contain a large amount of this material, namely, the body chief cells and the pancreatic acinous cells, are probably related to the presence of this stainable iron-holding compound in the cytoplasm. The ergastoplasm of Garnier (1900) owes its stainability to the presence of this substance, its form to the precipitation of the substances in

FIG. 54.—Cells from bottom of the fundus gland of man. Alcoholic bichromate sublimate fixation. Toluidine blue erythrosin staining. Shows the basal chromophile material, and the network of cytoplasm separating the spaces occupied in Figure 55 by zymogen granules.

question with other constituents of the cytoplasm by acid fixing fluids. Hoven has adopted the erroneous idea, which has also been accepted by Nassonow and Bowen recently, but contested by Regaud and Mawas (1909) and others, that the ergastoplasm of Garnier is simply badly fixed mitochondria. These writers overlooked entirely the chemical aspects of the situation and also the fact that the fibrillar form is not an essential property of the ergastoplasm of Garnier, which may be seen side by side with the mitochondria in preparations fixed in Regaud's fluid and stained by Bens ley's acid fuchsin methyl green. The basal substance in this case stains

green, the mitochondria red. The term ergastoplasm, however, should be abandoned because of the fact that, as employed, it connotes a heterogeneous class of different things.

The inner zone of the body chief cells in Figure 54 shows a very regular network of trabeculae formed by the thin laminae of cytoplasm which separate the spaces in which, in the fresh cell, the zymogen granules are lodged.

Figure 55 shows a portion of the body of the gland from the same stomach, stained with Bensley's neutral gentian. In this case the zymogen granules

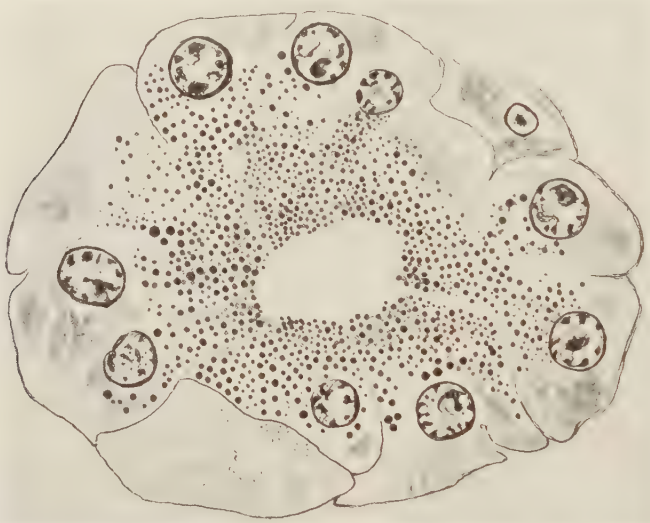

FIG. 55.—A group of body chief cells from the same material as Figure 54, but stained in Bensley's neutral gentian to show the zymogen granules occupying the free ends of the cells.

are stained and occupy the inner pole of the cell occupied in the former figure by the network of cytoplasm.

The mitochondria of the body chief cell were first studied by Altmann (1890), whose excellent figure of these elements is reproduced in Figure 56. It will be seen that the mitochondria consist of thick rods or long filaments arranged in the direction of the long axis of the cell. Much attention has been paid to the appearance presented by these elements in different functional phases of the cell by Müller (1898), Hoven (1912), Schultze (1911), Regaud and Mawas (1909), Noll and Sokoloff (1905), Lim and Ma (1926) and by others. The majority of these workers agree that the mitochondria are less abundant in the loaded cell than in the discharged cell and that they show changes in morphology related in time to the changes in the granular contents of the cell. It is apparent that unusual difficulties attend

investigations of this sort, since the technique is difficult and uncertain and the changes in volume of the cell during secretion would by themselves account for considerable apparent differences in the relative amounts of constituent substances and structures. From these researches, however, one gets the impression that zymogen granules in process of forming may be closely associated with mitochondria, just as the work of Nassonow and others shows that they are closely associated with the Golgi reticular apparatus. The reasons for this close association are at present unknown. The changes in the mitochondria during the activity of the cell are shown in the accompanying Figures 57 and 58, after Noll and Sokoloff (1905).

FIG. 56.—Fundus gland of cat, prepared by the Altmann method showing filamentous mitochondria in body chief cells and rod-shaped and granular mitochondria in the parietal cells. P, parietal cells; Z, zymogenic chief cells of the body. (After Altmann, 1890.)

The Golgi reticular apparatus of the body chief cells has been studied by Golgi (1909) and Kolster (1913). The former contents himself with the statement that the apparatus is found chiefly in the usual position between the nucleus and the lumen and resembles that found in other glandular cells. Kolster is more specific. By means of the Golgi arsenic method and the Cajal uranium nitrate method he found the apparatus in the body chief cells as a minute closed system situated between the nucleus and the lumen. In thick sections it was difficult to discern a net structure in it, but thinner sections showed it to be formed of a network of fine fibrillae. He suspected connections between the apparatus and the nucleus in some instances. Von Bergen (1904), on the contrary, demonstrated in the chief cells of the fundus glands of the cat a rather open type of network, located in the usual

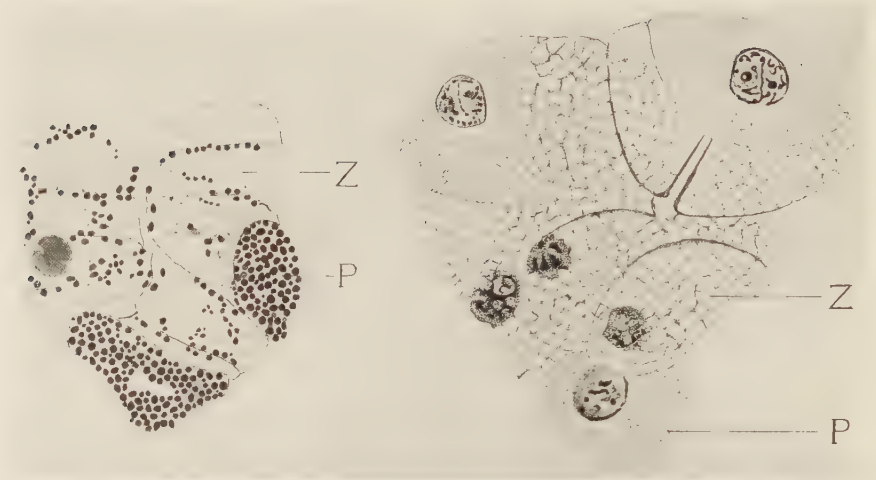

FIG. 57.—Body chief cells, z; and parietal cells; p; in the fasting stomach of the dog. a, Altmann preparation showing granular mitochondria. b, Van Gehuchten's fluid; hematoxylin and eosin preparation. (After Noll and Sokoloff, 1905.)

FIG. 58.—Body chief cells from the fundus glands of the dog's stomach at the beginning of the tenth hour of digestion. Altmann preparation showing increase in filamentous mitochondria. p, parietal cells; z, zymogenic body chief cells. (After Noll and Sokoloff.)

situation, but spreading in some cases with wide meshes across the full diameter of the cell. In many cells, however, the results were negative, a fact which the author explains by the assumption that the developing hydrostatic pressure exerted by the vacuoles containing secretion causes a collapse of the apparatus.

2. *The neck chief cells:*

The neck chief cells constitute the immediate lining of the gastric glands in the upper narrower portion of the gland which was termed by Heidenhain "Drüsenhals." That the cells of this region of the gland were different in some respects from those deeper in the gland was first mentioned by Bizzozero (1892) who thought that they constituted a gradual transition between the cells of the surface epithelium and those constituting the glands. Oppel (1896) noted that the cells of the upper third of the gland in the badger differed from those in the other two-thirds, inasmuch as they had a clearer protoplasm and peripheral flattened nucleus. Bensley (1896), in a preliminary note, and later (1898) in a more extended discussion with illustrations of the cellular types in the gastric gands of mammals, established the fact that the cells of the neck of the gland were wholly different in structure, content and function from those of the body of the gland. This finding was promptly confirmed by other observers, notably by Zimmermann (1898), Cade (1901), Liebert (1904), Harvey (1907) and Lim (1922). The presence of these cells in the neck of the gland, and the absence in this location of the zymogen-containing chief cells of the body of the gland, is responsible for the transparency of this region of the mucous membrane in fresh surviving tissues.

The secreting cells of this type contain granular antecedents to their secretion, but these granules are so transparent that they offer little resistance to the passage of light through the preparation. According to Noll and Sokoloff (1905) the cells contain, in the fresh condition, transparent granules. In fixed preparations these cells are best demonstrated by the usual methods for staining mucin, namely, by mucicarmine and muchematein. Preparations fixed in alcohol or aqueous bichloride or the alcoholic bichromate sublimate fluid of Bensley are particularly suitable for this staining. When so prepared the neck chief cells are deeply colored by reason of the mucin antecedents which fill them, while the body chief cells remain uniformly unstained. In such preparations it may be seen that the cells of this type, while in the main restricted to the neck of the gland, sometimes occur scattered through the body of the gland, and in man and pig whole gland tubules in the fundus region may be entirely formed of neck chief cells and parietal cells to the exclusion of the type usually found in the lower portions of the gland. In sections the cells in question present themselves as wedge-shaped elements along the neck of the gland, alternating in

groups of three or more with the parietal cells, which, in this location, have a broad surface of contact with the lumen. In ordinary preparations in which the secretion is unstained they present the clear aspect and coarsely reticular structure characteristic of mucous cells in general. At the upper end of the neck where they sometimes pass by gradual change into the

FIG. 59.—Van Gehuchten, hematoxylin and eosin preparation showing diminished size of cells, increased chromophile material, diminished area occupied by zymogen granules (unstained). P, parietal cells; Z, zymogenic body chief cells. (After Noll and Sokoloff, 1905.)

epithelium of the foveolae, they may contain in the fasting stomach little secretion, but very soon on the way down the gland cells fully distended with secretion are met with. In the latter the secretion is divided into two masses as described above for the surface epithelium, an inner mass which is interpreted as the new-formed secretion and an outer one near the lumen

of the gland. If the sections are treated with great care and contact with water avoided, the secretion stained with mucicarmine or muchematein shows itself in the form of the small granules described for the living cell. If water has been allowed to come into contact with it, however, the granular form is lost and the reprecipitated mucin adheres to the cytoplasmic trabecules, giving the coarse reticular structure usually seen in mucous cells. The nuclei of these cells are spherical except where the secretion has been allowed to imbibe water and swell, in which case the characteristic irregular flat and cupped nuclei of the mucous type is displayed. The cytoplasm of these cells contains, distributed throughout the basal cytoplasm and between the masses of granules and particularly along the free margins, small mitochondrial filaments, which are not, however, either so numerous or so large as in the body chief cells. Unfortunately no data are available as to the character and situation of the apparatus in these cells. At the junction of neck and body there is no transition between neck chief cells and body chief cells, but an abrupt change from one type to the other. To recapitulate, the neck chief cells contain neither chromophile material nor zymogen granules, but contain instead a chemically different antecedent which has all the properties of a mucin.

In the stomachs of reptiles and batrachians the neck chief cells are represented by the large clear mucous cells which occupy a similar position in the complex glands of these lower forms, and in the Chelonia they may as in man occupy wholly some divisions of the gland.

The cells of the pyloric glands and those of the cardiac glands are essentially of the same type and display the same reactions as the neck chief cells of the gastric glands proper.

3. *The parietal cells:*

The parietal cells are the oldest known type of cell in the gastric glands of mammals. Prior to Heidenhain's discovery of the chief cells they were considered to be the only cells in the glands and since that discovery the nature of their relation to the lumen of the gland and their secretory contributions to the gastric secretion have been the subject of numerous investigations. Most numerous in the neck of the gland they are also found occasionally underneath the epithelium of the foveolae and even at the surface of the mucous membrane. Heidenhain (1870) thought that they were completely parietal in position and that they were separated from the lumen by a continuous layer of chief cells. Stöhr (1882) found in his preparations a process extending from the parietal cell between the chief cells, connecting the former to the lumen, but it was not until the Golgi silver bichromate method was applied to the glands of the stomach by Müller (1892), Golgi (1893), Langendorff and Laserstein (1894) and others, that the true relation of the cells to the lumen was ascertained.

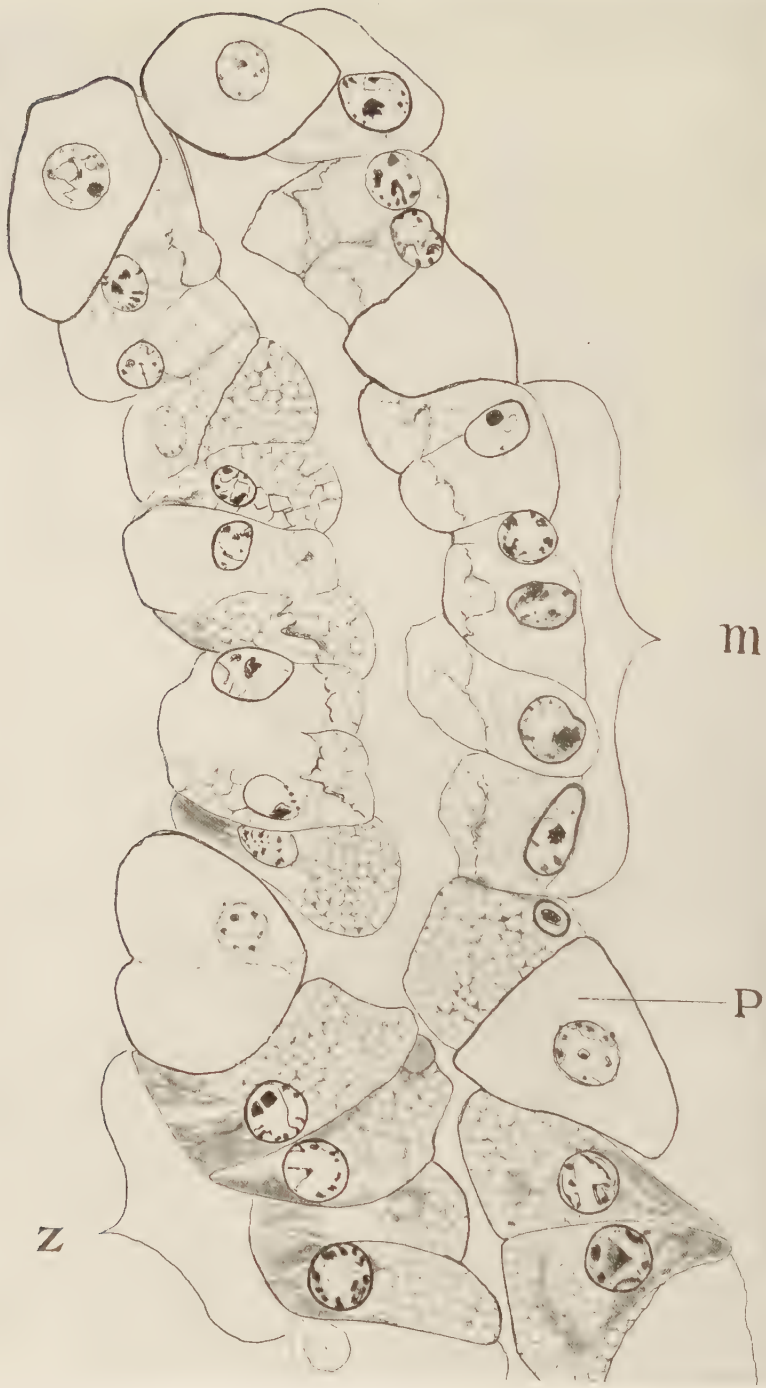

FIG. 60.—Neck of gland from human stomach. Alcohol, bichromate, sublimate fixation; toluidine blue-erythrosin staining. M, neck chief cells; Z, body chief cells; P, parietal cells.

According to the results of these observers the parietal cells are not only connected with the lumen by a channel which passes between the contiguous surfaces of the chief cells, but contain also an intricate system of intracellular secretion channels in the form of a network of irregular canals, occupying for the most part the central area of the cell between the nucleus and the convex periphery, and communicating by one or several of the intercellular channels referred to above with the lumen of the gland. In the body of the gland these connections with the lumen are more often single, but in the neck of the gland, where the parietal cell abuts by a large surface directly on the lumen, the intracellular secretion canals may communicate with it at several points.

There has been much discussion of the actual relation of these secretion canaliculi to the surface of the cell, but since the demonstration of the canals in ordinary stained preparations by Bensley (1898), Müller (1898), and Zimmermann (1898), it has been generally recognized that they are actually intracellular, although branches of the minute tube which connects the parietal cell with the lumen may penetrate between the adjacent surfaces of parietal and chief cells, serving, however, chiefly to receive the secretion of the latter. The intracellular location of the canals has been particularly apparent in the preparations made by the vital staining technique of Harvey and Bensley (1912). These observers found that in a secreting stomach the secretion inside of the parietal cells, as well as that in the lumen of the gland proper could be stained supravitally with neutral red. This method now constitutes the most certain and satisfactory means of demonstrating the intracellular secreting canaliculi. Whether the secretion canaliculi are permanent or only temporary channels in the cell is at present uncertain, but certain facts seem to indicate a certain degree of permanence. For example, even in the fasting stomach it is possible to demonstrate the canals in fixed and strained preparations, and in the fasting stomach of the dog and cat the spirilla which are normal inhabitants of the gastric glands may be seen in the interior of the parietal cell apparently in contact with the cytoplasm. When the canal is apparent a thin film of exoplasmic condensation is also visible along its edge. In preparations stained supravitally with neutral red, the contents if observed for some

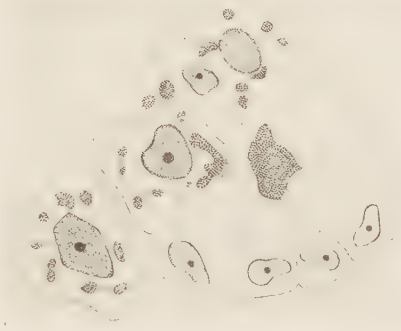

FIG. 61.—Cross section of fundus gland of man; Golgi preparation showing intracellular secretion canaliculi in parietal cells. (After Zimmerman, 1898.)

time show a tendency to break up into droplets, which probably accounts for the vacuoles often seen in parietal cells.

In the fresh condition in serum the parietal cell presents a coarsely granular appearance, due to the presence in it of numerous small granules of low refractive power. These granules appear to be spherical in outline only slightly elongated in one diameter, but may in some instances be very definite short thick rods. These granules were first demonstrated by Altmann, whose excellent figure (Fig. 56) has not been improved upon in the various mitochondrial researches which have followed. He noted clearly the tendency to rod formation and of course identified them with his bioblasts in other material. Noll and Sokoloff (1905), Eklöf (1914), Hoven (1912), Lim and Ma (1926) and others also identify these elements as mitochondria. According to Eklöf they consist rather of chains of granules joined together by an intermediate substance. The other observers, in the main, confirm Altmann's observations.

The cytoplasm between these granules in the fresh cell is glass-clear without visible structure, and in the final fixed material appears as a homogeneous matrix, or if the fixation has been in acid fluids or in sublimate solutions as in Zimmermann's material, a finely granular material. The only differentiation in this ground substance is in the form of a slight exoplasmic condensation visible along the border of the intracellular secretion canaliculi.

The parietal cell contains one or more centrally located nuclei of the usual structure. In man the number of nuclei may reach as many as six, and two, three or four nuclei to a parietal cell are common. On the other hand, many parietal cells contain but a single nucleus. The multinuclear condition is supposed to be attained by amitosis, but this is merely a conjecture based on the lack of mitoses.

The Golgi apparatus has been studied in the parietal cells by Kolster (1913) who finds that the apparatus in the parietal cells of the upper portion of the gland is different from that in the lower. In the former the apparatus is in the form of a coarse net which encircles the nucleus, while in the cells of the body of the gland it consists of a net of much finer meshes, more peripherally placed so that the cell appears to be surrounded by a net of fine Golgi threads. In both instances it may be noted that the reticular apparatus is independent of the network of secretion capillaries and has no tendency to a polar position as in most other epithelial cells.

4. *The cells of Heidenhain:*

By this name I propose to designate certain small cells of uncertain function first described by Heidenhain in 1870 from the gastric glands of the rabbit. They occupy a parietal position on the surface of the glands in this and other animals, and were particularly noted by Heidenhain on

account of the deep yellow stain which they took in bichromate solutions. They resemble the cells described by Nicolas (1891), Kull (1924) and others in various portions of the alimentary canal and particularly studied by Kull under the name of "cells of Nicolas." Harvey and Bensley found that in fresh preparations these cells were closely studded with minute granules which stained crimson in neutral red, or blue in the various Nile blues employed by them as indicators. They possess a centrally located nucleus similar to that of the other epithelial cells. These are in all probability the cells described by Twort (1924) recently under the title "The Demonstration of a Hitherto Undescribed Type of Cells in the Glands of the Stomach."

5. The cells of Nüssbaum and Stohr:

The cells frequently described under these names and discovered by the observers whose names they bear, have not yet been sufficiently clearly defined cytologically to justify their discussion at this time.

III. INTESTINAL ELEMENTS IN THE MUCOSA GASTRICA

A number of authors including Lubarsch (1897), Schaffer (1897), Hari (1901), Schridde (1904), and others, have studied the patches of intestinal epithelium which occur in the human stomach, not only in the pyloric division but in the fundus and cardiac regions as well. In these areas not only is intestinal epithelium with goblet cells and crusta-bearing cells present, but glands of Lieberkühn, containing both of these types and, in addition, Paneth granule cells. The cytology of these types will be discussed in the section on page 183. It may be pointed out, however, that in a recent comprehensive study of the structures in question by Chuma (1923) it was found that the intestinal elements were lacking in all autopsies on newborn and children. Among the adults examined, 59 cases in all, intestinal epithelium was found in 15 cases only, and in every case was associated with other pathological conditions of the stomach. Chuma was of the opinion that this condition was the result of disease, and that intestinal epithelium never occurred in the normal healthy stomach. It follows, if Chuma is correct in this deduction, that the capacity to develop into the epithelial types found in the intestine is possessed by the hypoblast of the fetal foregut and that this property is retained even in the differentiated epithelium of the adult stomach. The alternative hypothesis that these patches represent dislocated midgut hypoblast has little to commend it.

IV. REPRODUCTION OF THE CELLS OF THE GASTRIC GLANDS

When discussing the surface epithelium (p. 141) it was pointed out that at the bottoms of the foveolae, cells are constantly found in mitosis. This phenomenon, first studied in detail by Bizzozero (1893), is correlated with the fact that from the bottom of the foveola to the surface there is a gradual

change in the aspect of the epithelial cells in the sense that they go through a series of changes preparing for full secretory activity. This is interpreted by Bizzozero to mean that the cells in this location are the sources from which the surface cells are replenished. The replacement of the cells of the glands proper presents, on the other hand, a difficult problem for which we do not yet know the solution. In the neck of the gland the neck chief cells are not infrequently found in mitosis, and the replacement of these cells is satisfactorily accounted for by the division of cells themselves and by the addition of new cells from the mitotic focus in the bottom of the foveolae, because in some mammals there is also a gradient of structure between the relatively undifferent cells of the foveolae and the neck chief cells. As regards the body chief cells and the parietal cells the solution is still doubtful. Mitoses are exceedingly rare, though they occur in both types of epithelial cells. Harma (1910) who studied the conditions obtaining in the stomachs of young mice observed both chief cells and parietal cells in mitosis. He made no attempt, however, to identify with certainty the chief cells, and since he found the ones in mitosis chiefly in the neck of the gland it is possible that he was studying neck chief cells, which were well known to divide by this method (Bensley, 1898). As regards the parietal cells his figures are convincing, so that it seems probable that at least in the growth period the parietal cells to some extent multiply by direct division. Whether there is another method or not is unknown. Bizzozero thought that the chief cells were recruited from cells farther up in the gland but he mistook the neck chief cells for intermediate stages in this change. Bizzozero's hypothesis would require a change of secretory function of the cells in their progress down the gland. In this connection it may be pointed out that Harvey (1906, 1907) found that, in the fundus glands adjacent to a recent gastroenterostomy, the chief cells took on for a time muciparous functions and reverted later to the zymogenous type. Some light may be expected on these subjects from the analytical study of regeneration in the mucous membrane of the stomach in artificial defects experimentally produced. The researches of Griffini and Vassale (1888) and of Malesani (1909) indicate that such defects are repaired, and that glands are produced in the regenerated mucous membrane, but their histological investigation was not done with sufficiently discriminative technical methods to enable us to discern to what extent the most highly differentiated glandular elements participated in the repair. It is worthy of note, however, that Malesani obtained the surprising result that a large contributor to this regeneration was the chief cell of the gland, although he found the surface epithelium of the stomach also participating. It is not quite certain, however, from his figures and methods whether the participating chief cells are the muciparous ones of the neck of the gland or the zymogenous ones of the body.

V. BIBLIOGRAPHY

Altmann, R. 1890. *Die Elementarorganismen und ihre Beizehungen zu den Zellen.* Leipzig: Veit and Co. 145 pp.

Arnold, J. 1911. Ueber feinere Strukturen und Anordnung des Glykogens im Magen-Darmkanal. *Arch. f. mikr. Anat.*, **77**, 346.

Barfurth, D. 1885. Vergleichende histochemische Untersuchungen über das Glykogen. *Arch. f. mikr. Anat.*, **25**, 300.

Bensley, R. R. 1896. The histology and physiology of the gastric glands. *Proc. of the Canad. Inst.*, **1**, 11.

——— 1898. The structure of the mammalian gastric glands. *Quart. J. Micr. Sci.*, **41**, 361.

——— 1902. The cardiac glands of mammals. *Am. J. Anat.*, **2**, 115.

——— 1903. The structure of the glands of Brunner. *Univ. of Chicago, Decennial Publications*, **10**, 279.

——— 1904. *Stomach.* In "A Reference Handbook of the Medical Sciences." New York: Wm. Wood and Co., **7**, 361.

——— 1912. Studies on the pancreas of the guinea pig. *Am. J. Anat.*, **12**, 297.

von Bergen, F. 1904. Zur Kenntniss gewisser Strukturbilder (Netzapparate, Saftkänälchen, Trophospongien) im Protoplasma verschiedener Zellenarten. *Arch. f. mikr. Anat.*, **64**, 498.

Bernard, Claude. 1856. *Mémoire sur le pancréas et sur le rôle du suc pancréatique dans les phenomènes digestifs, particulièrement dans la digestion des matières grasses neutres.* Paris. 165 pp.

Bizzozero, G. 1893. Ueber die schlauchförmigen Drüsen des Magendarmkanals und die Beziehungen ihres Epithels zu dem Oberflächenepithel der Schleimhaut. *Arch. f. mikr. Anat.*, **42**, 82.

Bowen, R. H. 1923. The origin of secretory granules. *Proc. Nat. Acad. Sci.*, **9**, 349.

——— 1924. On a possible relation between the Golgi apparatus and secretory products. *Am. J. Anat.*, **33**, 197.

——— 1925. Notes on the topography of the Golgi apparatus in gland cells. *Science*, **61**, 545

Cade, A. 1901. Étude de la constitution histologique normale et de quelques variations fonctionelles et expérimentales des mammifères. *Arch. d'anat micr.*, **4**, 1.

Carlier, E. W. 1899. Changes that occur in the newt's stomach during digestion. A cell study. *La Cellule*, **16**, 403.

Chambers, R. 1915. Micro-dissection studies on the physical properties of protoplasm. *Lancet-Clinic*, Mar. 27, 8 pp.

Chambers, R., and Rényi, G. S. 1925. The structure of the cells in tissues as revealed by microdissection. *Am. J. Anat.*, **35**, 385.

Chuma, M. 1923. Zur normalen und pathologischen Histologie der Magenschleimhaut. *Virchow's Archiv*, **247**, 236.

Collip, J. B. 1920. *University of Toronto Studies*, Physiol. Ser., 1920, No. 35.

D'Agata, G. 1910. Sur les modifications de l'appareil réticulaire interne dans l'épithélium de la muqueuse gastrique. *Arch. ital. de. biol.*, **54**, 425.

Dawson, A. B. 1925. Microchemical studies on the formation of hydrochloric acid by the stomach. *Anat. Record*, **29**, 335.

Dawson, A. B., and Ivy, A. C. 1925. Contributions to the physiology of gastric secretion. *Am. J. Physiol.*, **73**, 304.

Duesberg, J. Trophosphongien und Golgischer Apparat. *Verh. d. Anat. Ges.*, Vers. 28, 11.

Eberth, C. J., and Müller, G. R. 1892. Untersuchungen über das Pankreas. *Ztschr. f. wiss. Zool.*, **53** (Suppl.,) 112.

Ebstein, W. 1870. Beiträge zur Lehre vom Bau und den physiologischen Funktionen der sogenannten Magenschleimdrüsen. *Arch. f. mikr. Anat.*, **6**, 515.

Ebstein, W., and Grützner, P. 1874. Ueber Pepsinbildung im Magen. *Pflüger's Arch. f. d. ges. Physiol.*, **8**, 122.

Edelmann. 1889. Vergleichend anatomische und physiologische Untersuchungen über eine besondere Region der Magenschleimhaut (Cardiadrüsenregion) bei den Säugethieren. *Deut. Ztschr. f. Thiermed.*, **15**, 165.

Eklöf, R. 1914. Chondriosomenstudien an den Epithel- und Drüsenzellen bei Säugetieren. *Anat. Hefte*, **51**, 1.

Fichera, G. 1904. Ueber die Verteilung des Glykogens in verschiedenen Arten experimenteller Glykosurie. *Beitr. z. pathol. Anat. u. z. allgem. Pathol.*, **36**, 273.

Garnier, A. C. 1900. Contribution à l'étude de la structure et du functionnement des cellules glandulaires séreuses. Du rôle de l'ergastoplasme dans le sécrétion. *J. de l'anat. et de physiol.*, **36**, 22.

Golgi, C. 1893. Sur la fine organisation des glandes peptiques des mammifères. *Arch. ital. de biol.*, **19**, 448.

——— 1909. Sur une fine particularité de structure de l'épithélium de la muqueuse gastrique et intestinale de quelques vértébrés. *Ibid.*, **51**, 213.

Griffini, L., and Vassale, G. 1888. Ueber die Reproduktion der Magenschleimhaut. *Ziegler's Beiträge*, **3**, 423.

Groebbels, F. 1924. Beiträge zur histologische Physiologie der Verdauungsdrüse. 1. Magen. *Zeitschr. f. Biol.*, **80**.

Haane, G. 1905. Ueber die Cardiadrüsen und die Cardiadrüsenzone des Magens der Haussäugethiere. *Arch. f. Anat. u. Physiol.*, Anat. Abt., 1.

Hamburger, E. 1889. Beiträge zur Kenntniss der Zellen in den Magendrüsen. *Arch. f. mikr. Anat.*, **34**, 225.

Hamperl, H. 1926. Die färberische Darstellung der Hauptzellgranula in der menschlichen Magenschleimhaut. *Virchow's Archiv*, **259**, 179.

Hari, P. 1901. Ueber das normale Oberflächenepithel des Magens und über Vorkommen vom Randsaumepithelien und Becherzellen in des menschlichen Magenschleimhaut. *Arch. f. mikr. Anat.*, **58**, 685.

Harms, W. 1910. Ueber den Ersatz der Haupt und Belegzellen. *Anat. Hefte*, **41**, 393.

Harvey, B. C. H. 1906. The chromaffine characters of certain parietal cells of the stomach. *Brit. Med. J.*, **2**, 1703.

– – 1907. A study of the structure of the gastric glands of the dog and of the changes they undergo after gastroenterostomy and occlusion of the pylorus. *Am. J. Anat.*, **6**, 207.

Harvey, B. C. H., and Bensley, R. R. 1912. Upon the formation of the hydrochloric acid in the foveolae and on the surface of the gastric mucous membrane, and the non-acid character of the gland cells and lumina. *Biol. Bull.*, **23**, 225.

Heidenhain, R. 1870. Untersuchungen über den Bau der Labdrüsen. *Arch. f. mikr. Anat.*, **6**, 368.

– 1883. *Handbuch der Physiologie*, von L. Hermann. Bd. v.

Heiderich, F. 1911. Zur Histologie des Magens. 1. Das Oberflächenepithel. *Anat. Hefte*, **43**, 149.

Hewlett, A. W. 1901. The superficial glands of the esophagus. *J. Exper. Med.*, **5**, 319.

Holmgren, E. 1904. Beiträge zur Morphologie der Zelle. II. Verschiedene Zellarten. *Anat. Hefte*, **24**, 99.

Hoven, H. 1912. Contribution à l'étude du fonctionnement des cellules glandulaires. Du rôle du chondriome dans la sécrétion. *Arch. f. Zellf.*, **8**, 555.

Ivy, A. C., and Oyama, Y. 1921. Studies on the secretion of the pars pylorica gastri. *Am. J. Physiol.*, **57**, 51.

Kolatchev, A. 1916. Recherches cytologiques sur les cellules nerveuses des mollusques. *Arch. russes d'anat., d'histologie, et d'embryol*, **1**, 383.

Kolossow, A. 1898. Eine Untersuchungsmethode des Epithelgewebes besonders der Drüsenepithelien und die erhaltenen Resultate. *Arch. f. mikr. Anat.*, **52**, 1.

Kolster, R. 1913. Ueber die durch Golgi's Arsenik- und Cajal's Urannitrat-Silbermethode darstellbaren Zellstrukturen. *Verhandl. der Anat. Ges.*, Vers. 27, 124.

Krause, R. 1895. Zur Histologie der Speicheldrüsen. Die Speicheldrüsen des Igels. *Arch. f. mikr. Anat.*, **45**, 93.

Kull, H. 1924. Die chromaffinen Zellen des Verdauungstraktus. *Ztschr. f. mikr. anat. Forsch.*, **2**, 163.

Langendorff, O., and Laserstein, S. 1894. Die feineren Absonderungswege der Magendrüsen. *Arch. f. d. ges. Physiol.*, **55**, 578.

Langley, J. N. 1879–80. On the changes in serous glands during secretion. *J. Physiol.*, **2**, 261.

———, 1880–82. On the histology of the mammalian gastric glands and the relation of pepsin to the granules of the chief cells. *J. Physiol.*, **3**, 269.

——— 1882. On the histology and physiology of pepsin-forming glands. *Phil. Trans. Roy. Soc. Lond.*, **172**, 663.

———, **and Sewall, H.** 1879–80. On the changes in pepsin-forming glands during secretion. *J. Physiol.*, **2**, 281.

Liebert, A. 1904. Ueber die Fundusdrüsen beim Rhesusaffen. *Anat. Hefte*, **23**, 495.

Lim, R. K. S. 1922. The gastric mucosa. *Quart. J. Micr. Sci.*, **66**, 187.

———, **and Dott, N. M.** 1923. Observations on the isolated pyloric segment and its secretion. *Quart. J. Exper. Physiol.*, **13**, 159.

———, **and Ma, W. C.** 1926. Mitochondrial changes in the cells of the gastric glands in relation to activity. *Quart. J. Exper. Physiol.*, **16**, 87.

Macallum, A. B. 1891. Contributions to the morphology and physiology of cells. *Trans. Can. Inst.*, Toronto, **1**, 247.

—— 1895. On the distribution of the assimilated compounds of iron other than haemoglobins and haematins in animal and vegetable cells. *Quart. J. Micr. Sci.*, **38**, 175.

Malesani, A. 1909. Contributo allo studio della rigenerazione della mucosa gastrica. *Arch. Ital. di anat. e. di embriol.*, **8**, 359.

Matthews, A. P. 1899. The changes in structure of the pancreas cells. *J. Morphol.*, **15**, 171.

Maximow, A. 1901. Beiträge zur Histologie und Physiologie der Speicheldrüsen. *Arch. f. mikr. Anat.*, **58**, 1.

Mönnig, G. 1909. *Zur Histologie der Cardiadrüsen von Sus scrofa.* Inaug. Diss., Zürich. 67 pp.

Mouret, J. 1895. Contribution à l'étude des cellules glandulaires (pancréas). *J. de l'anat. et de physiol.*, **31**, 211.

Müller, E. 1892. Zur Kenntniss der Ausbreitung und Endigungsweise der Magendarm- und Pankreas-Nerven. *Arch. f. mikr. Anat.*, **40**, 390.

—— 1895. Ueber Sekretkapillaren. *Ibid.*, **45**, 463.

—— 1898. Drüsenstudien. II. Ueber die Fundusdrüsen des Magens. *Ztschr. f. wiss. Zool.*, **64**, 624.

Nassonow, D. N. 1923. Das Golgische Binnennetz und seine Beziehungen zu der Sekretion. Untersuchungen über einige Amphibiendrüsen. *Arch. f. mikr. Anat.*, **97**, 136.

Nassonow, D. N. 1924*a*. Das Golgische Binnennetz und seine Beziehungen zu der Sekretion. *Ibid.*, **100**, 433.

—— — 1924*b*. Das Exkretionsapparat (kontraktile Vakuole) der Protozoa als Homologen des Golgischen Apparats der Metazoazellen. *Ibid.*, **103**, 437.

—— 1926. Die physiologische Bedeutung des Golgi-Apparats im Lichte der Vitalfärbungsmethode. *Ztschr. f. Zellforsch. u. mikr. Anat.*, **3**, 472.

Nicolas, A. 1891. Recherches sur l'épithélium de l'intestin grêle. *Intern. Monatssch. f. Anat. u. Physiol.*, **8**, 1.

Noll, A., and Sokoloff, A. 1905. Zur Histologie der ruhenden und thätigen Fundusdrüsen des Magens. *Arch. f. Anat. u. Physiol.*, Physiol. Abth., 94.

Nussbaum, M. 1879. Ueber den Bau und den Thätigkeit der Drüsen. *Arch. f. mikr. Anat.*, **15**, 532.

Ogneff, J. 1892. Einige Bemerkungen über das Magenepithel. *Biol. Centralbl.*, **12**, 689.

Oppel, A. 1896. *Lehrbuch der vergleichenden mikroskopischen Anatomie der Wirbeltiere.* Theil I. Der Magen. Jena: G. Fischer.

Oshikawa, Dr. Beiträge zur Histologie des Magens und der Magengeschwüre. *Virchow's Archiv*, **248**, 217.

Paschkis, K., and Orator, V. 1923*a*. Zur normalen Histologie des Magens. *Wien. klin. Wochensch.*, **136**, 26.

—— 1923*b*. Beiträge zur Normalhistologie de menschlichen Magens. *Ztschr. f. Anat. u. Entw.*, **76**, 494.

Pirone, R. 1904. Recherches sur la fonction sécrétoire des cellules glandulaires gastriques. *Ztschr. f. allg. Physiol.*, **4**, 62.

Regaud, C. 1908. Sur les formations mitochondriales de diverses espèces cellulaires. *Compt. Rend. Ass. Anat.*, **10**, 15.

—— — 1911. Participation du chondriome à la formation des grains de ségrégation dans les cellules des tubes contournés du rein. *Compt. Rend. de la Soc. de Biol.*, **66**, 1034.

Regaud, C., and Mawas, J. 1909. Sur la structure du protoplasme (ergastoplasma, mitochondries, grains de ségrégation) dans les cellules sérozymogènes des acini et dans les cellules des canaux excréteurs de quelques glandes salivaires de mammifères. *Comptes Rend. Ass. Anat.*, Réun. 11, 220.

Rollett, A. 1871. Bemerkungen zur Kenntniss der Labdrüsen und der Magenschleimhaut. *Unters. aus. d. Inst. f. Physiol. u. Hist. in Graz*, **2**, 143.

Rüdinger, N. 1879. *Beiträge zur Morphologie des Gaumensegels und des Verdauungsapparats.* Stuttgart, 49 pp.

Schafer, E. A., and Williams, J. 1876. On the structure of the mucous membrane of the stomach in the kangaroos. *Proc. Zool. Soc. London*, **1**, 165.

Schaffer, J. 1897*a*. Ueber die Drüsen der menschlichen Speiseröhre. *Sitzngsb. d. k. Akad. d. Wissensch.* (Math. Naturw. Classe.), **106**, 175.

—— 1897*b*. Beiträge zur Histologie menschlicher Organe. *Ibid.*, **106**, 353.

Schridde, H. 1904. Ueber Magenschleimhaut-Inseln vom Bau der Cardialdrüsenzone und Fundusdrüsenregion und den unteren oesophagealen Cardialdrüsen gleichenden Drüsen im obersten Oesophagus-Abschnitt. *Arch. f. path. Anat.*, **175**, 1.

Schultze, O. 1911. Ueber die Genese der Granula in dem Drüsenzellen. *Anat. Anz.*, **38**, 257.

Schulze, F. E. 1867. Epithel und Drusenzellen. *Arch. f. mikr. Anat.*, **3**, 145.

Solger, B. 1894. Zur Kenntniss der secernierenden Zellen der Glandula submaxillaris des Menschen. *Anat. Anz.*, **9**, 415.

—— 1896. Ueber den feineren Bau der Glandula submaxillaris des Menschen, mit besonderer Berücksichtigung der Drüsengranula. *Festsch. Carl Gegenbaur*, **2**, 179.

Stella-Gangi, P. 1922. Contributo alla fine struttura delle cellule delomorfe (o parietale) dello stomaco. *Monit. zool. ital.*, **33**, 33.

Stöhr, P. 1882. Zur Kenntniss des feineren Baus der menschlichen Magenschleimhaut. *Arch. f. mikr. Anat.*, **20**, 221.

Théohari, A. 1899. Étude sur la structure des cellules principales, de bordure, et pyloriques, de l'estomac à l'état de repos et à l'état d'activité sécrétoire. *Arch. d'anat. micr.*, **3**, 11.

Twort, F. W. 1924. The demonstration of a hitherto undescribed type of cell in the glands of the stomach. *Brit. J. Exper. Path.*, **5**, 352.

Zimmermann, K. W. 1898. Beiträge zur Kenntnis einiger Drüsen und Epithelien. *Arch. f. mikr. Anat.*, **52**, 552.

——— 1925. Beitrag zur Kenntniss des Baues und der Funktion der Fundusdrüsen im menschlichen Magen. *Erg. der Physiol.*, **24**, 281.

Section VII

THE INTESTINAL EPITHELIUM

CONTENTS

Section VII

PAGE

I. Columnar Absorbing Cells 172
1. Boundaries 173
2. Intercellular spaces 174
3. Cuticle 175
4. Cytoplasm 175
5. Mitochondria 176
6. Golgi apparatus 176
7. Fat absorption 177
8. Water absorption 178
9. Absorption of iron 178
10. Protein absorption 178
II. Principal Cells of Crypts 180
III. Goblet Cells 181
IV. Paneth Cells 183
V. Basal Granular Cells 185
VI. Cells of Duodenal Glands 187
VII. Transitional Epithelium of Anal Region 189
VIII. Bibliography 189

Section VII

THE INTESTINAL EPITHELIUM*

CHARLES CLIFFORD MACKLIN
AND
MADGE THURLOW MACKLIN

THE intestinal epithelium forms a tube of simple columnar cells, some twenty-five to thirty feet in length in the human adult, which is directly continuous above with the epithelium of the pylorus, and below with that of the anus. Because of the great amount of evagination and invagination which obtains in it, the surface area is enormously increased. It is, by almost all workers, considered to be entirely of entodermal origin, and its most characteristic specialization is that of absorption. We have evidences of this throughout the tube, and particularly in its cephalic section. As a barrier between the living tissue and the lumen contents, it protects the body from a variety of irritants, and it is highly specialized for secretion, producing digestive juices in considerable variety from an assortment of glandular elements. This varifunctioned mechanism is intimately related to the underlying blood and lymph capillaries, and is, moreover, most closely correlated with the sympathetic nervous system through an almost infinite number of fine nerve endings which link the cells with the neighboring submucous and muscular plexuses (p. 1022).

This epithelial field presents two main regions, corresponding to the small and large intestine. In the former the surface is marked by a multitude of finger-like and sometimes leaf-like processes, the intestinal villi, measuring from 0.2 to 1 mm. in height, and standing some 10 to 40 to the square millimeter. These are more thickly set, and are higher, in the upper part of the small intestine than in the ileum. They may cover the lymphoid follicles (Anile, 1915), although often these are devoid of villi. They disappear at the valvula coli, the large intestine, except in the fetus, being without them. Prominent semilunar, transverse ridges, the plicae circulares, clothed with villus-bearing mucosa, are found particularly in the upper region of the small intestine. Throughout the enteric tract there occur multitudes of long, narrow invaginations, the crypts of Lieberkuehn, whose mouths, in the small intestine, open between the villi. In some regions, as in Peyer's patches and the vermiform process, they are crowded out by lymphoid tissue. In strongly distended intestines both villi and crypts become much less conspicuous, and may be almost obliterated, the epithelial layer then tending to flatten out (Johnson, 1913). The crypts of the large intestine are considerably longer than those of the small, and in the rectum may reach 0.7 mm.

*Figures in this section will be found on plates following bibliography.

In the intestinal epithelium a number of highly specialized cell types may be recognized. By far the most numerous elements are the "principal cells" (Zipkin, 1904) which are found throughout the tract, on the villi and in the crypts. They present variations with location. For purposes of description we shall refer to the well-differentiated principal cells of the villi by Heidenhain's (1888) term "columnar absorbing cells," reserving the designation "principal cells" for application to the remaining elements of this type appearing in the crypts and on the surface.

Closely allied to the principal cells are the numerous and conspicuous goblet cells. Less obvious, but quite abundant, are the cells of Paneth; and finally we have, fairly universally distributed, the basal granular or chromaffin elements. To these we may add the cells of the duodenal glands, and those of the glands and transitional regions of the anus.

I. THE COLUMNAR ABSORBING CELLS

The intestinal villus, primarily an absorptive organ, consists of an epithelial covering, fitting closely, like the finger of a glove, over the succulent, vascular and motile core. The villi, as Hambleton (1914), King and his co-workers (1922) and others have pointed out, are capable of various movements, as shortening and elongation, and slow waving from side to side. The epithelium is able to adapt itself to these changes by adjustment of the individual cells (as shortening and lengthening, with widening or narrowing), and even by folding of the epithelial coat, for conspicuous transverse ridges and furrows are a feature of the villus, particularly when strongly contracted. The cells appear to be able to undergo considerable amounts of compression and stretching without injury. Under normal conditions they adhere closely to the basement membrane.

By far the most numerous, characteristic and important element of the villus surface is the highly specialized columnar absorbing cell. Its form (Figs. 4,11,15) is very variable, the individual differences being referable to pressure from neighboring cells, and to variations in functional state; but it may be represented diagrammatically as that of a truncated cone, the smaller, basal end resting on the basement membrane. The larger end, covered by cuticle, presents itself toward the lumen, where it may project freely, as at the villus tip, or may be directed toward the surfaces of the similar cells of a neighboring villus, being separated therefrom by a layer of mucus. Since the outer surface is of considerably greater area than the base, it follows that the total expanse facing the lumen of the intestine is much greater than that abutting upon the basement membrane, and this difference is greatest at the villus tip, where the cell architecture is comparable to that of the stones in a dome. The basal region is often rendered relatively narrower by reason of the intercellular spaces which frequently occur

between the bases of the cells (Fig. 23). The cell height is given as from 20μ to 26μ, and varies with the extended or contracted condition of the villus, the cells, in the latter condition, being longer and thinner. Such alterations may have an influence on their functional efficiency. The width of the outer end averages about 9μ, while that of the inner is quite variable, being about 6μ, or less. In cross sections the cells are prismoid, and packed closely together like the cells of a honeycomb.

The nucleus is oval in form, and elongates or widens in association with the changes of the cell, these variations not being of primary importance (Deimler, 1904; Martin, 1910, and others). It is situated usually rather nearer the base than the surface and, according to Vernoni (1908, 1909), moves nearer to the cuticle in the unfed condition. The position varies somewhat in the cells of the row, so that the line of the nuclei is irregular. The nuclear membrane is thin, though distinct, and the nuclear sap contains a moderate amount of chromatin. Oppel (1904) sees in it a delicate network of threads with a few coarse, irregular chromatin clumps at junctions of cross fibrils. In addition to these there are always one or more oxyphil nucleoli (Schaffer, 1891). It seldom, if ever, undergoes mitotic division in the adult form (Hock, 1899; Heidenhain, 1899; Greschik, 1912), although Clara (1926*a*) found occasional mitoses on the villus of the newly hatched chick.

1. *Boundaries:*

The cells are limited outwardly by a very definite cuticular border. Along the sides, the boundaries are very thin, though usually distinct. In the peripheral region they are common for adjacent cells, and it is assumed that there is a tough, flexible cement substance intervening. Here the cells are held firmly together, even against considerable tension. This is well seen in a villus in which the core has shrunk away from the epithelium by reason of the contracting effect of certain fixatives. Here the epithelium is stretched and made thin on account of the fluid which has been forced beneath it from the core (Fig. 19). The same change often occurs in villi which are allowed to stand for a few minutes unfixed (Macklin and Macklin, 1926*a*, *b*). This phenomenon has been termed "ballooning." In such an event the form of the cells may be changed from tall columns to cubes, but in spite of the obvious stretching, the cells remain held firmly to one another, and it is not until later maceration changes have set in that they are disunited. This cement substance is readily dissolved by certain reagents, such as Ranvier's alcohol and dilute acetic acid.

The outer ends of the cells are further held together by a lattice-work of "terminal bars" (Fig. 15), possibly formed by a thickening of cement substance, and like it derived from the epithelial cells. In fresh mounts it may be seen in surface views, appearing very refractile. In side views often only

the ends of the bars are visible in the optical section. The network is quite elastic, yielding to the various movements which characterize the villus.

2. *Intercellular spaces:*

The common partition of neighboring cells may be split from the region of the nucleus to the basement membrane, so that frequently the lower portions of adjacent cells have boundaries of their own, with an intercellular space, of variable dimensions, between (Figs. 15, 23).

These spaces are not always obvious, the basal ends of the cells being frequently in contact. They are dilated when chyle is passing through. Then, in the sections, they appear roughly triangular, the bases resting on the basal membrane. It would really appear that we are dealing, not with isolated spaces, but with one continuous space, holding the basal ends of the epithelial cells, which are thus bathed in the surrounding fluid. This space is apparently in communication with the tissue fluid spaces of the core through the permeable basement membrane or, possibly, by actual minute perforations in the latter. Thus substances passed by the cell into the intercellular space are readily transferred to the immediate environment of the capillaries and lymphatics. Because of the intercellular space the excretory area of the cell is enormously increased, for it is not then required to discharge all of its products through the narrow base; indeed, it may be that most of these products pass through the sides into the intercellular space. Arcangeli (1906) reports an elongation of the cell during absorption, with a narrowing of the base as absorbed material is passed into the intercellular spaces. Champy (1911-1912) thought that fluid from Holmgren's canals was passed into them. A resemblance to the conditions in glands of internal secretion has been noted by Macallum (1894) and others. The spaces form a highway for leucocytes (Fig. 15L) which appear to be able to force their way through the cement substance into the lumen (Tavernari, 1916*a*, *b*).

Intercellular bridges, which may cross these spaces (Fig. 11) in the subnuclear region have been described (Reuter, 1903; Heidenhain, 1911; Schaeppi, 190–, 1916). Schaeppi (190–) looked upon them as transmitting impulses from cell to cell. They have not been discerned in fresh material, and have been considered by some to be artefacts.

The basal, narrow end of the cell abuts upon the basement membrane, to which it is attached. When the cell body is separated from the basement membrane by the aforementioned "ballooning" phenomenon, a thin film of the basal cytoplasm remains adherent to the basement membrane (Macklin and Macklin, 1926*b*). The actual mode of attachment is disputed. Although Schäfer (1912) states that the bases are smooth, other observers (Grünhagen, 188–; Heidenhain, 1911; Schaeppi, 1916) find that the cell sends out protoplasmic processes which interlock with the basement membrane and underlying stroma, and in this way bind the cells down (Figs. 3, 4).

3. *Cuticle:*

The cuticular or "striated" border of Henle limits the cell outwardly (Fig. 15). The individual element is a refractile, polygonal, plate-like structure, held to its neighbors by almost imperceptible films of cement substance (Fig. 29) which join the terminal bars below. In surface view these plates form a mosaic, broken here and there by the mouths of the goblet cells (Fig. 29, Muc.). Collectively they make a flexible membrane, covering all of the exposed portion of the intestinal mucosa, which is directly continuous with the cuticle of the cells of the crypts of Lieberkuehn.

The finer structure of the cuticle has been described by Zipkin (1904), Studnička (1925) and others. According to Clara (1926*a*) it consists of two zones (Fig. 7), a distal, broader, striated, more lightly staining layer; and a proximal, narrower, darker, and quite sharply delimited stratum. It is composed of a ground substance in which are embedded the "rods," which give to it the striated appearance. Each rod has an outer and an inner portion, corresponding to the two zones, and separated by a line or membrane. The outer limb is longer, structureless and homogeneous; the inner is shorter, darker and surrounded by a protein-like substance which stains well with iron hematoxylin. At the junction of these two parts is a line of "border granules," while at the base of the inner limb are others, ellipsoidal in shape, and more easily seen than are the former. The ellipsoidal granules can be distinguished from each other provided the intervening protoplasm is not stained; otherwise, they form a continuous dark basal stripe. They occupy the distal end of the cell, and appear to be points of anchorage for the rods. The line connecting their outer ends is said to mark the ultimate limit of the cell. The rods have been looked upon by Prenant as cilia which have lost their power of movement, and R. Heidenhain (1888) considers them to be protoplasmic prolongations of the cell which possess the power of contractility. The exact significance of the cuticle is hard to determine. It exists on cells which are apparently secretory, as well as on absorbing cells (Clara, 1926*a*).

4. *Cytoplasm:*

The cytoplasm of the columnar absorbing cell is a homogeneous colloidal sol in which occur the syntheses and transportation activities characterizing this element. In the fresh condition a multitude of very fine granules may be seen in it. The usually larger supranuclear division presents a clear, thin, "subcuticular zone," or hyaloplasm (Peterfi, 1914), and below, a zone which, in fixed preparations, is often of alveolar structure, containing a number of mitochondria (Asher, 1908; Demjanenko, 1909; Champy, 1911; Peterfi, 1914) and a double centrosome (Zimmermann, 1898), the latter being usually placed quite close to the subcuticular area. Lower still, and

yet above the nucleus, the protoplasm is clearer, and houses few mitochondria except in cases of prolonged starvation. Here is lodged the Golgi apparatus (Fig. 30), which in man is a rather wide, coiled canal (Holmgren, 1902).

The subnuclear zone, narrower and usually less voluminous than the supranuclear, shows a more lightly staining protoplasm, and contains thickly packed granular mitochondria in the form of an inverted cone (Asher, 1908; Demjanenko, 1908; Peterfi, 1914).

5. Mitochondria:

Asher (1908) reported that the mitochondria in the cells of intestinal epithelium were much fewer, larger and harder to stain than in glandular cells. Champy (1911) showed that the mitochondria have a bipolar distribution in the cells of the villus (Fig. 14), which in his mind suggests a secretory, as well as an absorptive, function. In the supranuclear zone most observers picture them as often rod-like and arranged parallel to the long axis of the cell, whereas in the subnuclear zone they are, for the most part, granular.

The changes in mitochondria with activity are of interest. In starvation their number is reported to be markedly increased (Asher, 1908, Fig. 2"; Demjanenko, 1909; Zillinberg-Paul, 1909; Champy, 1911; Peterfi, 1914; Bissachi, 1916). Indeed, Bissachi finds the condition of the mitochondria a criterion of the functional state of the cell. Also it is the consensus of opinion that during digestion and absorption they become less numerous, and less thread-like in form (Champy, 1911). Asher (1908) found them less distinct in the fed rat (Fig. 28) and Demjanenko (1909) and Peterfi (1914) stated that they were especially decreased in the subcuticular zone, being less affected in the subnuclear area. Zillinberg-Paul (1909) reported that after pilocarpine injection the mitochondria were fewer, smaller and more scattered. She says the picture can only be interpreted as indicating that the cells secrete toward the blood stream—never into the lumen of the intestine.

M. Heidenhain (1899, 1911) described fibers which run through the cell in a longitudinal direction. Although indistinct in the subnuclear region they become plainer as they pass upward around the nucleus, and occasionally appear to have rotated spirally through the cell. He thought that they performed a double function, protecting the cells from lateral pressure due to growth, and assisting, in some way, in the transport of water. Schaeppi (1916) spoke of them as "tension fibers" and denied to them any part in water absorption. Champy (1911, 1912) and Szymonowicz (1924) regarded them as mitochondria.

6. Golgi apparatus:

The Golgi apparatus (Fig. 30) is quite conspicuous in appropriately stained principal cells, and appears as a system of coiled canals which

always occupies the supranuclear region. In the resting cell it lies nearer to the nucleus than to the cuticular border. Its changes in size and position during fat absorption will be discussed later.

7. *Fat absorption:*

The special changes in the cytoplasm during the absorption of fat may be briefly referred to. Although Kischensky (1902) found occasional fat droplets in the cuticular border, most workers have not confirmed this. The lipoid first appears in the form of droplets immediately beneath the cuticle, having been synthesized from the absorbed fatty acids and glycerin by the reverse action of lipase in the epithelial cells (Bayliss, 1918, p. 375). Mottram, Cramer and Drew (1922) showed that fat normally traverses the cell as fine droplets, distributed throughout the cytoplasm, and often in the form of long streams (Fig. 5). This they term "absorption by streams." Furthermore, they hold that this picture is obtained only when the proper vitamins are present in the food, for when pure fat minus vitamins was fed they obtained cells in which the fat was almost altogether in the form of large droplets situated mainly in the supranuclear part of the cell (Fig. 6). Absorption of fat, under these conditions, was inefficient. It is noteworthy that most of the earlier workers pictured fat as it is shown in Figure 6, and it is to be inferred that they were dealing with the absorption of fat minus vitamins. Schafer (1885) obtained pictures of fat absorption comparable to those described by Mottram and his co-workers when vitamins were used, and it is of interest that Schafer's animals (young puppies) were fed with milk, rich in these accessory food factors. The vitamins, according to Mottram and his colleagues, make for the finer emulsification and more rapid assimilation of fat, with attendant nutritional benefit.

Reuter (1903) shows the fat passing out of the cell body into the intercellular spaces, and thence into the lymph spaces of the core (Figs. 9, 10).

There has been some attempt to correlate the Golgi apparatus with the absorption of fat. Biscossi (1908) stated that the fat traversed the cytoplasm entirely within the canals of the Golgi network. Cramer and Ludford (1925) claim to have shown that when fat plus vitamins is fed, the Golgi apparatus of the columnar absorbing cells enlarges so that it almost reaches the cuticular border, and holds within its coils the fat droplets. If foods other than fat or if fat minus vitamins are fed to the animals, the Golgi apparatus shows no change. They conclude that the latter structure is normally concerned in fat absorption. They observed no change in the mitochondria during the absorption of fat.

In this connection the rôle of the lymphocyte may be briefly mentioned. It has been observed that during digestion the number of lymphocytes in the epithelial layer is increased (Schafer, 1885; Demjanenko, 1909, and others), and it has been held that they assist in the transport of fat by

ingesting it and carrying it to the lacteals (Zawarykin, 1883; Schafer, 1885; Clark and Clark, 1917; Mottram, Cramer and Drew, 1922; and Mottram, 1923); while Grünhagen (1887), Heidenhain (1888), Ramond (1904) and others deny such functional importance to them.

8. *Water absorption:*

The changes in the columnar absorbing cell during absorption of water are not clear. The participation of the tension fibers in this process, already mentioned (Heidenhain, 1899, 1911; Schaeppi, 1916), would seem unproved.

9. *Absorption of iron:*

A certain amount of work has been done on the optical evidence of iron in transit through the columnar absorbing cell. Macallum (1894) fed organic and inorganic iron compounds to experimental animals and found that he could detect evidence of iron (by the Prussian blue reaction) within the cytoplasm, either as a diffuse coloration or in the form of granules, only following the administration of considerable quantities, for when the dose given was relatively small the cells showed no trace of it, although its presence was demonstrable in the subepithelial elements. He suggests that iron normally passes through the cells very rapidly, in quantity presumably below the limit of visibility, and does not accumulate within them in demonstrable mass unless they are fatigued. The writers have noted that, when an isolated loop of small intestine of the cat was partially filled with a 2 per cent aqueous solution of ferric ammonium sulphate, returned to the abdomen, and allowed to remain there with circulation intact for fifteen minutes and then fixed at once in 10 per cent formalin, the columnar absorbing cells, after treatment with potassium ferrocyanide on the slide, showed Prussian blue only in the cuticle, the protoplasm being quite clear. The cuticular border stood out sharply as a densely stained blue line. Apparently the cuticle is capable of absorbing and concentrating the iron. Macallum's suggestion would seem to explain its absence from the cytoplasm. The presence of iron throughout the cuticle, rather than in the infinitesimal cement lines, points to the exclusion of the latter from consideration as a highway for such absorbed substances, and indicates that the cuticle is the real gateway to the organism. Iron in the cuticle was noted and figured by Macallum (1894).

10. *Protein absorption:*

Various accounts are to be found purporting to describe changes in the columnar absorbing cells during protein absorption. Mingazzini (1900*a*, *b*) described a curious vacuolation and swelling particularly in the basal region of these cells, and interpreted it as an accumulation of nutritive elements

absorbed by the cells from the lumen, and awaiting removal by the underlying blood and lymph vessels. He thought he could discern a gradual enlargement of this mass during the early part of absorption, with a subsequent diminution of it as it was presumably absorbed by the collecting system. This accumulation might become so great as to separate widely the outer portion of the epithelium from the basement membrane, leading to the formation of a large space. The length of each cell was much increased during the period of accumulation of chylous material, and subsequently returned to normal as the load was delivered. With each period of digestive activity there was thus a sort of ebb and flow of chylous material in the basal protoplasm. Reuter (1901, 1903) found a similar formation, and considered it as indicative of protein absorption. Others supported this view (Drago, 1901; Beguin, 1903; Monti, 1903, 1907; Tavernari, 1916*a*, *b*, and others). Many workers, however, disagreed with the above interpretation of these phenomena, considering them to be artefacts (De Luca, 1905, Ferrata and Moruzzi, 1905; Arcangeli, 1906; Corti, 1906; Demjanenko, 1909, and others). The authors have found that, when the villi are fixed during absorption, without delay, these appearances do not occur, provided fixation is properly done. They have discovered that, if pieces of intestine are removed while the circulation is still intact, or *immediately* after its cessation, and plunged into a mixture of 10 per cent formalin in Ringer's solution, the epithelium is always in close apposition with the basement membrane, and that the spherule complex described by Mingazzini and his followers (and which has come to be known as the "Mingazzini phenomenon") does not occur. Furthermore, the authors have found (Macklin and Macklin, 1926*a*, *b*) that if the intestine is allowed to lie a few minutes after the circulation has stopped, before being fixed, the appearances described by Mingazzini and others become plainly evident, and this is so in starved animals as well as in those absorbing various food substances. These changes are thus obviously agonal or early post-mortem phenomena and are in no way associated with absorption. They are really only the early stages of the "ballooning" phenomenon shown in Figure 19, and are due mainly, if not entirely, to the expulsion, from the core, of fluid into the basal region of the cells, as a consequence of the contraction of the muscular elements of the villus, stimulated apparently by the asphyxia of circulatory arrest. These changes may also be produced, as R. Heidenhain (1888) pointed out, by the shrinking action of certain unsatisfactory fixatives.

Cramer and Ludford (1925) state that there is no change in the mitochondria during fat absorption, and since other workers, as we have seen, have reported extensive changes in these bodies during absorption, it is possible that they are to be associated with the taking up of protein products.

The conjecture of Kultschitzky (1897) that the basal granular cells are absorbers of protein derivatives has, as we shall see, been shown to be erroneous.

Thus we must conclude that the analysis of cytological changes in the columnar absorbing cells during protein absorpton is in an undeveloped condition. Somewhat more is known of the process in the more primitive intestinal epithelial cells of lower forms. In tricald flatworms, Willier, Hyman and Rifenburgh (1925) have found that fragments of raw liver are phagocytized by these cells and, within the food vacuoles, are digested, finally disappearing into the cytoplasm, to reappear, apparently, as droplets of fat.

II. THE PRINCIPAL CELLS OF THE CRYPTS

The transition of the principal cells from the villus to the intestinal glands is gradual, with no line of demarcation, which speaks against any sudden change of function from absorption to secretion. The cells become shorter, and there are some minor differences in morphology, involving a loss of the features of specialization characteristic of the columnar absorbing cell. The cuticle, although showing a progressive thinning when traced from the villus into the crypt, is nevertheless unbroken, and forms a covering for all of these cells, which are largely protective in function although quite possibly capable of absorption. Goblet and other cells are scattered amongst them.

The principal cells of the small (Figs. 1, 12, 13) and large (Fig. 20) intestinal glands, although found throughout the length of the crypts, are concentrated mainly in the body and neck. The cuticle is considerably thinner than that on the surface principal cells, and is not so obviously differentiated; indeed, the presence of a true cuticle is denied by Schwalbe (1872), Patzelt (1882), Piersol (1920) and others. Clara (1926*d*) states that the cuticle of the crypt cells varies in different forms and in different cells of the same form. The cells are considerably shorter than those of the villus, but their general morphological details are quite similar. The cytoplasm in fixed preparations has the appearance of being more alveolar, and at the distal pole is a lighter zone indicating the place of collection of secretion. This is quite distinct from the subcuticular light zone of the columnar absorbing cell. The Golgi apparatus and mitochondria are practically identical with those of the villus cell. The mitochondria behave similarly in starved and fed rats, but less markedly (Asher, 1908). To Corti (1925), the Golgi apparatus in the cells of the crypts and villi of the small intestine of a human subject during digestion appeared uniform in size, shape and position. "Tension fibers" resembling those of the columnar absorbing cell have been reported by Schaeppi (1916). The cytoplasm stains more darkly, and

mitotic figures, both in the small and large intestine, are found in these cells. This has led some workers to consider them largely regenerative and as replacing the cells of the surface regions, which give no evidence of dividing. Bizzozero (1888, 1889, 1892, 1893) thinks of these crypt cells as recruits which slowly make their way upward, shifting their footing upon the basement membrane to replace the worn-out absorbing, goblet and other cells of the surface parts. Clara (1926*a*, p. 642) found no good evidence in support of this view. Starling (1926) states that the mitotic figures are more numerous during absorption of a protein meal. Some workers, as Kultschitzky (1897), think that they have absorptive functions. The general tendency, however, is to look upon them as mainly secretory.

In the large intestine there is a surface of epithelium, unmarked by villi, which joins that of the crypt mouths. It is made up of columnar principal cells, with well-marked nuclei situated rather nearer the base than the surface, and a finely granular cytoplasm, which is specialized to ends of protection and absorption. These cells possess striated cuticular borders which extend into the necks of the crypts (Stöhr and Lewis, 1913). Gradually changing their morphology as they descend into the crypt necks, they encounter a quickly increasing company of goblet cells.

III. THE GOBLET CELLS

The goblet cells, secreting mucus, are found throughout the intestinal tract, scattered among the elements of the exposed surfaces as well as in the crypts. They are especially abundant in the glands of the large intestine, where their product facilitates the passage of the progressively drying feces. The number is said to be increased during starvation, principally on the villi (Monti, 1903; Bezzola, 1904; Pugliese, 1905; Vernoni, 1908).

Their morphology varies enormously in different functional phases. The undeveloped goblet cell (Fig. 14) bears a close resemblance to the principal cell, and has been thought by many workers to have arisen from it and to be capable of reversion to it (Klose, 1880; Patzelt, 1882; Paneth, 1888; List, 1886, 1889; Hoyer, 1890; Clara, 1926*d*). It is not, according to these workers, a cell sui generis. The fact that its numbers may be speedily increased (as during inanition) points to a readily accessible source, and many workers have seemed to find this in the principal cells. Mottram (1923) noted that, following exposure of the intestinal tract to radium emanations, there was an undue secretion of mucus, accompanied by a mucoid degeneration of previously non-mucous epithelial cells, but evidence that definitive goblet cells were evolved would seem to be lacking.

It is difficult to understand how an element so highly differentiated as, for instance, the columnar absorbing cell could be capable of such rapid de- and re-differentiation, and one is tempted to look for a progenitor in the

form of an unspecialized principal cell. It is usually affirmed that the goblet cells themselves show no mitotic figures (although Schaffer, 1922, denies this) and v. Ebner (1899) pointed out that it is extremely rare to find two of them in contact, there being almost always non-mucous cells intervening, so that they do not appear to multiply. By no means all workers agree that the principal cells and goblet cells are interchangeable, Bizzozero (1888, 1889), Majewski (1894), Monti (1903) and others holding that each cell is of a specific type.

In its undeveloped condition the goblet cell has the form of a thin column. The first indication of metamorphosis, according to Paneth (1888), is the appearance of a light area in the distal third, lodging a few granules of mucus of pronounced basophilic reaction. These increase in number and size, with corresponding enlargement of the surrounding light area, which is set in a cup-like depression of the optically homogeneous dense protoplasm. This cytoplasmic wall, or theca (Fig. 21), gradually becomes thin as its substance is used up in the production of granules, which, by accumulation, cause the cell body to swell into a characteristic ovoid form (Figs. 2, 20, 23) whence is derived the name "goblet cell," the theca representing the body of the goblet, the granule mass the contents, and the slender nucleus-bearing stem and expanded base completing the picture. So thickly are the granules set that, unless special precautions are used in the fixation and staining of the material, the upper part of the cell, in preparations in which mucin stains are used, appears uniformly dark. With appropriate technique, however, the granules may be discerned. The *fully* distended cell, according to Clara (1926*d*), is of a wide columnar form, the nucleus being flattened in the basal region.

Galeotti (1895) looked upon the nucleus as the source of the mucus granules. Clara (1926*d*) describes them as arising first in the zone immediately above the nucleus, and as wandering up to the subcuticular region, there remaining until matured. They increase in number and size, and, just before the rupture of the cuticle, may become a confluent mass through the imbibition of water. He found very young cells in which a few granules were present in the region of the nucleus, with none as yet toward the surface, although such forms were rare.

How the filled cells discharge their load of granules is not altogether understood. It is the general view that the contents ooze out until the cell is completely evacuated, when it is reduced to a slender delicate element (Paneth, 1888) about one-fourth the width of the neighboring columnar cells, with a dark, homogeneous protoplasm and a rather dense, deeply set nucleus. By growth this cell becomes indistinguishable from its neighbors, and may undergo a repetition of the cycle. Clara (1926*d*) finds cells beginning to elaborate the granules of the second cycle of secretion before they have discharged their first accumulation, thus eliminating any resting

stage, and it seems quite possible that the delivery of mucus by a cell may be continuous over a prolonged period.

Many authors regard the goblet cell as being without a cuticular border, but some, as Paneth (1888) and Clara (1926*d*), aver that it possesses such a structure, which gradually becomes thin as the cell fills, and disappears as a recognizable structure before its final rupture, but it is soon regained as the cell returns to its original form. Striations have even been noted in it, in the younger cells. Von Ebner (1899) describes a stoma at the free end of the cell for the discharge of mucus which, of course, is uncovered by cuticle.

Mucus has been shown to be of several varieties (Kossel, 1891), one being derived from mucin, one from nuclein, and one (in bile) not derived from either. It has been thought that glycogen was mixed with the mucus within the cells (Arnold, 1911; Krieger, 1914) or that a polysaccharide complex was present in the mucin molecule (Leathes, quoted by Clara, 1926*d*).

The nucleus is smaller, more darkly staining and lies nearer to the basement membrane than is the case with the columnar absorbing cells, Clara (1926*d*) stating that the latter position is constant, even though the cell is emptied of its contents. Others consider that the nucleus rises in the cell and becomes more lightly staining after the mucus has been evacuated.

In the undeveloped goblet cell, mitochondria are present in all regions except the extreme distal end, as in Figure 14. Their distribution is similar to that in the principal cells, which, however, according to Asher (1908) and Eklöf (1914) contain a greater number of mitochondria than the mucus-secreting elements. As the mucin granules accumulate, the mitochondria are crowded into the thecal and basal protoplasm.

The Golgi apparatus (Holmgren, 1902) is not so characteristically arranged as in the columnar absorbing cell, but usually occupies the same relative position. Cowdry (1924, p. 337) states that Golgi (1909) reported a change in position of the Golgi apparatus in mucus-secreting intestinal epithelial cells, which to him (Cowdry) is somewhat similar to that noted in the thyroid and chorioid plexus. Nassonow (1923) attributes the manufacture of the mucin granules to the activity of the Golgi apparatus.

IV. THE PANETH CELLS

These conspicuously granular cells (Fig. 16), first described by Schwalbe (1872) and later given prominence by Paneth (1888), are now regarded as important elements of the intestinal epithelium. In man they are lodged in the fundus of the crypts of Lieberkuehn throughout the small intestine (Bloch, 1903; Kaufmann-Wolf, 1911; Schaffer, 1922) and are also found upon the free surface of the villi (Kaufmann-Wolf, 1911) and in Brunner's glands (Oppel, 1904). Although Schmidt (1905) failed to find them in the

human large intestine, Bloch (1903) reports their presence here, but in less abundance than in the small intestine.

Szymonowicz (1924) states that they may be absent from some parts of the intestine, and that they are not to be found in all animals. They are, however, gradually coming to be found in regions and in animals where they were formerly understood to be absent. Thus, despite the fact that Möller (1899) failed to find them in the pig, cat and dog, Trautmann (1910) found them in the latter two, and they are now known to occur in the intestinal canal of many mammals and also in birds (Clara, 1924, 1926c). Martin (1910) and Hamperl (1923) reported them in the large intestine of domestic animals.

Although the cells of Paneth in different forms are not identical (Kull, 1912), and show more variations than do, for instance, the goblet cells, yet recent work has disclosed a set of characters sufficiently uniform to permit of their being considered as a specific type.

On the villus the Paneth cells are usually of columnar shape, while in the crypts they are polyhedral. They possess a darkly staining cytoplasm whose distal region is, in the resting condition, filled with conspicuous large granules (Nicolas, 1890). These granules are visible in the fresh condition, and are quite refractive, though less so than fat (Paneth, 1888). They are soluble in ether, alcohol and dilute acids (Klein, 1906). Although they are very evident if the fixation and staining be favorable, yet improper technique leaves in their place only a vacuolated protoplasm. They are larger than those of any other intestinal epithelial cell except, possibly, those of young goblet elements, from which they may readily be distinguished. They stain well in iron hematoxylin and mucicarmine, and in neutral gentian (Klein, 1906).

The base of the cell is occupied by a dense protoplasm which appears striated, due to the basal filaments which tend to run in a general direction parallel with the long axis of the cell (Figs. 12, 13). Klein (1906) demonstrated by Macallum's (1895) methods the prozymogenic nature of these basal filaments, which, in other secreting cells, had originally been described by Solger (1894) and found by Macallum (1895) to contain iron. They were shown by Bensley (1896) to be common to many serozymogenic cells, and their presence is looked upon as an indication of an externally secreting cell. In those animals which feed constantly, as the guinea pig, the secretion granules of Paneth cells are few in number and small, and the basal filaments are correspondingly reduced, having apparently been used up in the production of the granules (Fig. 12). If such animals be starved, the Paneth cells accumulate secretion granules and, in the resting cell, the basal filaments tend to be more conspicuous (Fig. 13).

Thus the appearance of the Paneth cells strongly suggests glandular elements, and they are so regarded by most workers, as Paneth (1888);

Zipkin (1904); Schmidt (1905); Klein 1906); Cordier (1923), the latter worker causing them to extrude their granular content by injections of pilocarpine. That this secretory function is related to digestion is evident from a number of facts. The taking of food causes them to discharge their granules into the lumen, leaving behind an alveolar cytoplasm comparable to that of the discharged pancreas or the parotid cell (Zipkin, 1904; Klein, 1906). Their exact function is not known, although various theories have been propounded. Miram (1912), working with mice, found that they did not alter after carbohydrate feeding, had a doubtful rôle in protein digestion but a definite part in fat digestion, since they showed a notable depletion in secretion granules after meals of pure fat. A numerical reciprocal relation with the basal granular cells has been suggested by Tang (1922).

The mitochondria are segregated in the basal region (Cowdry, 1918, p. 73). Holmgren's canals are present and occupy relatively more space than in the columnar absorbing cells, being present throughout almost all of the cytoplasm. They are bordered by fine granules in the Paneth cells, in contrast to the smooth edges of the apparatus in the columnar absorbing cells (Holmgren, 1902). The nucleus is oval and lies at the base of the cell when the latter is filled with secretion, but rises higher following discharge of the granules.

The Paneth cells have been regarded as originating from the principal cells (Paneth, 1888; R. Heidenhain, 1888). Kull (1911) looks upon them as having developed from goblet cells in the human subject, and mouse, but not in other forms. A few workers consider them to be undeveloped goblet cells (Bizzozero, 1888, 1889; Kostitch, 1923). They are thought by some to constitute a cell type sui generis (Zipkin, 1904; Clara, 1926c). The latter author states that the Paneth cells, although not normally arising from principal cells in the adult, may possibly so evolve under abnormal conditions; since it has been shown that in cases of chronic intestinal irritation, such as is produced by carcinoma, the number of Paneth cells may be increased.

V. THE BASAL GRANULAR CELLS

These cells are spoken of variously as the "gelben Zellen," the basal "gekörnten Zellen," the "chromaffin cells" and the "argentaffine cells," and they were formerly also sometimes termed "Kultschitzky cells." They are found more or less constantly throughout the intestinal tract of man, scattered here and there among the other elements. They are present in the stomach, pancreatic duct, on the villi and in the crypts of the small and large intestine, and in Brunner's glands. Although possibly the rarest of the specifically differentiated elements of the intestinal epithelium, they collectively form a very important organ apparently of glandular character. Special fixation and staining technique is requied to make them visible, so that it is only in recent years that we have become seized of their impor-

tance. Nicolas (1891) first differentiated them from the Paneth and goblet cells by virtue of their safranophil granules, and they have since been described under various names and in various animals by many workers as Kultschitzky (1897), Zimmermann (1898—human), Möller (1899), Bloch (1903), Schmidt (1905—human), Ciaccio (1906, 1907), Kaufmann-Wolf (1911—human), Kull (1913), Masson (1914—human), Suda (1918), Greschik (1912, 1922), Tang (1922), Chuma (1923), Parat (1924*a*, *b*—human embryos), Twort (1924), Hamperl (1925), and Clara (1926*b*).

Like the principal cells, their form varies somewhat with their location. In the crypts (Figs. 24, 25), where they are most numerous, they are often flask-shaped, their basal end being narrower than the body above; the base, however, may be the widest part (Fig. 8). The distal end may be so thin that it appears to terminate before reaching the lumen; indeed, Masson (1914) has described two types of these cells, the point of distinction being that in some the apex reaches the lumen and in others it does not. On the villi (Fig. 26) their form is more nearly cylindrical.

The nucleus is always in the proximal half of the cell and is usually round (Fig. 8) and vesicular, being definitely poorer in chromatin than the nuclei of the principal cells, with a looser network in the middle of the nucleus and a condensation of chromatin about the edge. Oxyphil nucleoli are lacking (Hamperl, 1925; Clara, 1926*b*). There are occasional nuclei that resemble those of the principal cells. Mitotic figures have been reported by Masson (1914).

The cells are characterized by the possession of granules which show a strong affinity for chromium salts, whence their designation by Kull (1913) as "chromaffin cells," the name, although an expression of their chemical affinities, implying no relationship to those similarly named cells of the sympathetic system. The granules reduce silver nitrate, staining black, and so we have the term "argentaffine cell," used by Masson (1914). These granules are much smaller than are those of the Paneth cells, and in the human subject, at least, rarely rise above the level of the nucleus, being confined to the subnuclear zone in contrast to the Paneth cells where they lie in the supranuclear region. The nucleus often acts as a ball valve, preventing the granules from rising above it in the cell. In other animals, as the guinea pig, the granules extend beyond the nucleus (Fig. 8). In some forms usually, and in the human rarely, the granules fill in the entire cell with the exception of a small vacuolar zone at the apex (Fig. 8). These cells were at first regarded by Kull (1913) as entirely different forms from the cells described by Kultschitzky (1897), which contained subnuclear acidophil granules, and which have been known as "Kultschitzky cells," although various other workers had stood for the identity of the two elements. Kull, in 1925, convinced himself that the two cells were the same, the acidophil granules of Kultschitzky being merely the younger stage of the safranophil granules of

the chromaffin cell. The term "Kultschitzky cell" should, therefore, be dropped.

The origin of the basal granular cells is unknown. There are those who regard them as derived from entoderm (Masson, 1914; Parat, 1924*a*, *b*; Clara, 1926*b*) and those who look upon them as wandering into the entoderm from some outside source, as Kull (1913,1925). Not all workers agree that there is here a distinct cell type (Ellenberger, 1911; Eklöf, 1914). Kultschitzky (1897) thought they were concerned with the absorption of protein, the granules representing protein derivatives in passage through the cell. He reported that their number was increased with digestive activity, although this has been denied by most other workers, Kull (1913) and Suda (1918) not finding that feeding or starvation altered the number of the cells. Tang (1922) claimed to have found evidence of a reciprocal relation between the Paneth and chromaffin cells; where one was strongly developed, the other was lacking. Cordier (1921,1923) reports that they are externally secreting cells, comparable to the Paneth or pancreatic cells, being discharged after the injection of pilocarpine. On the other hand, they have been looked upon as an endocrine gland, secreting into the blood stream, and Kull (1925) thinks that their protoplasm projects into the capillary lumina. Parat (1924*a*, *b*) also holds to the endocrine theory, suggesting that they pour secretin into the blood, but Cordier (1925) claims to have disproved this theory. Masson (1923) calls them a "sympaticotropen gland" or "neurocrine" in function, secreting into neither the blood nor lymph stream, but pouring their secretion directly upon the nerve endings in the mucosa. In connection with the endocrine function which has been attributed to them might be mentioned the work of Ivy and Fisher (1924) and Dixon and Wadia (1926) who find that an appreciable amount of insulin or an insulin-like substance may be extracted from the intestinal mucosa.

The exact functional significance of the basal granular cells remains to be discovered, there being no convincing evidence that they belong to the endocrine group of organs; and specific correlation is lacking between the discharge of their granules and the digestion of any particular food-stuff. To the histo-physiologist they present an inviting problem.

Their pathology is more fully known than is their physiology, since they have been shown to be the origin of certain tumors of the appendix and intestine (Oberndorfer, 1907, 1909; Hübschmann, 1910; Saltykow, 1912; Masson, 1914, 1921*a*, *b*, 1922*a*, *b*, 1923, 1924; Gosset and Masson, 1914; Masson and Berger, 1923; Hasegawa, 1923; Danisch, 1924; Cordier, 1924; Forbus, 1925; Martin, et al., 1925).

VI. THE CELLS OF THE DUODENAL GLANDS

The duodenal glands or glands of Brunner occur, in man, only in the duodenum, occupying the outer part of the mucosa (Fig. 17) and, particularly,

the submucosa. To Bensley (1903) we owe our most complete and accurate knowledge of them, and his account has been drawn upon very heavily in the following description. In general morphology they are very similar to the glands of the pyloric region of the stomach and may be regarded as direct continuations of these; indeed, a distinguishing feature of the human Brunner's glands is that they contain a relatively small number of parietal cells which are identical in every way with those of the fundus glands of the stomach. They have occasional multiple nuclei, and show distinct intracellular secretory ducts.

The glands belong to the branched tubulo-alveolar class, the terminations of the ducts branching into tubules, and these either into tubules of the same size or into slightly expanded acini. The epithelium rests upon a delicate reticular basement membrane throughout the system. Bensley finds that the ducts always open into one of the crypts of Lieberkuehn, although Schaffer (1891), Castellant (1898) and others claim to have observed them opening independently on the surface of the intestine. Bensley pictures a sharp transition between the epithelium of the intestinal gland, and that of the duct of the duodenal gland (Fig. 17 P, B).

The cells of the alveoli are irregularly cuboidal or pyramidal in form, differing in minor details in different regions, but showing a characteristic morphology throughout the gland. The height varies from 15μ to 21μ. In fixed and stained preparations the body presents a large-meshed reticulum of rather fine fibrils, in which is carried the secretion. In the center of the cell the fibrils are coarser, but the meshes are smaller. This zone, in the human, corresponds to a band of dense cytoplasm (Fig. 18), BC, which separates the secretion into two masses, a proximal and a distal (Fig. 18, PZ and DZ), in the cells of the cat, mink and other animals. This band may be absent, bringing about the union of the two zones (Fig. 18), CC.

Brunner's glands show no secretion granules in the fresh condition. They do not contain basal filaments when fixed, and show only a trace of organic iron, thus indicating that they are not serous in character. They stain heavily with mucin stains, and are considered by Bensley as pure mucous glands. He describes three well-defined physiological stages, which present distinct histological pictures. The first is a condition of maximum loading with secretion, in which the cells appear large and transparent, with flattened or crescentic nuclei in the basal region, surrounded by a small quantity of finely reticular cytoplasm. The cell body is clear, and shows a coarse network of trabeculae. The second stage, in which the cell has either partly discharged its secretion, or has not yet accumulated its full amount, he terms the intermediate condition. Here the nucleus is more oval, the basal cytoplasm is greater in amount, and two distinct secretory zones are seen. The proximal zone is characterized by coarser trabeculae than the distal. The third, or discharged condition, shows a nucleus, spheri-

cal or oval, lying near the center of the cell. The basal cytoplasm is still further increased, and the secretion may be confined either to the free border of the cell or be present in two masses—a dense one on the free border and a less dense one in the center of the cell. The new secretion is probably always formed at the base, near the nucleus. They are to be looked upon as mucus-secreting glands which have as yet given no proof of secreting any digestive ferment. Asher (1908) reported that mitochondria were increased in starved rats and decreased in fed ones, but that the change was less marked than in the columnar absorbing cells.

In passing from the tubules to the ducts there is a gradual transition in the cell morphology, the human cells, as shown by Zimmermann (1898), in Figure 22, being low cuboidal elements with an oval, dense nucleus somewhat flattened against the basal border, and a light superficial region of the cytoplasm containing a diplosome. A conspicuous band of dense cytoplasm separates these cytoplasmic zones. The ducts apparently secrete the same type of material as the acini but in lesser quantity.

VII. THE TRANSITIONAL EPITHELIUM OF THE ANAL REGION

In the region of the anus the crypts shorten and disappear, and the highly differentiated intestinal cells give place to stratified epithelium in which goblet cells are often found. A many-layered, squamous type of epithelium, with dermal papillae, marks the region of the sphincter, and passes over upon the *zona cutanea*.

A few intramuscular glands occur as off-shoots of the epithelium in this transitional zone. These are branched tubular glands, which extend through the internal sphincter, and may even penetrate the longitudinal muscle. Cuboidal cells, in one or two layers, are found in the branches and ampullae, but in the main ducts there are polygonal cells in several layers. Lymphoid tissue is often found around their endings.

VIII. BIBLIOGRAPHY

Anile, A. 1915. Contributo alla conoscenza dell villo intestinale. *Boll. del. soc. di Nat. in Napoli*, **28**, 126.

Arcangeli, A. 1906. I cambiamenti nell 'epitelio intestinale del Box salpa L. durante l'assorbimento. *Arch. Ital. di Anat. e di Embriol.*, **5**, 150.

Arnold, A. 1911. Über feinere Strukturen und die Anordnung des Glykogens im Magen-Darmkanal. *Arch. f. mikr. Anat.*, **77**, 346.

Asher, L. 1908. Das Verhalten des Darmepithels bei verschiedenen funktionellen Zuständen. *Ztschr. f. Biol.*, J. F. Lehmann's Verlag, München, **51**, 115.

Bayliss, W. M. 1918. *Principles of general physiology*. Ed. 2, London: Longmans, Green and Co.

Beguin, F. 1903 4. L'intestin pendant le jeûne et l'intestin pendant le digestion. *Arch. d'Anat. Micr.*, **6**, 385.

Bensley, R. R. 1896. The histology and physiology of the gastric glands. *Proc. Canadian Inst.*, Toronto, **1**, 11.

——— 1903. The structure of the glands of Brunner. *Univ. of Chicago Decennial Publications*, first series, **10**, 277 (bibliography).

Bezzola, C. 1904. Contributo alla conoscenza dell'assorbimento intestinale. *Boll. d. Soc. Med. Chir. di Pavia*, **4**, 260.

Biscossi, A. 1908. Sui cambiamenti dell'epitelio dei villi intestinali attribuiti ai vari stadi di assorbimento. *Arch. Ital. di Anat. e di Embriol.*, **7**, 244.

Bissachi, P. 1916. Del condrioma delle cellule epiteliali del villo intestinale nel digiuno prolungato e nella rialimentazione dopo in questo. *Bull. d. sc. med.*, Bologna, **9**, (4), 445.

Bizzozero, G. 1888. Über die Regeneration der Elemente der schlauchförmigen Drüsen und des Epithels des Magendarmkanals. *Anat. Anz.*, **3**, 781.

——— 1889. Über die schlauchförmigen Drüsen des Magendarmkanals, und die Beziehungen ihres Epithels zu dem Oberflächenepithel der Schleimhaut. *Arch. f. mikr. Anat.*, **33**, 216.

——— 1892. *Ibid.*, **40**, 325.

——— 1893. *Ibid.*, **42**, 82.

Bloch, C. A. 1903. Anatomische Untersuchungen über den Magen-Darmkanal des Säuglings. *Jahrb. f. Kinderh.*, Berl., **58**, 121.

Bowen, R. H. 1924. On a possible relation between the Golgi apparatus and secretory products. *Am. J. Anat.*, **33**, 197.

Castellant, J. L. A. 1898. *Quelques recherches sur les glandes de Brunner.* Thèse pour le Doctorat en Médicine, Faculté de Médicine et de Pharmacie de Lille. 63 pp.

Champy, C. 1911–12. Recherches sur l'absorption intestinale et le rôle des mitochondries dans l'absorption et la sécrétion. *Arch. d'anat. micr.*, **13**, 55.

Chuma, M. 1923. Zur normalen und pathologischen Histologie der Magenschleimhaut, unter besonderer Berücksichtigung des Vorkommens von Darmschleimhaut, Panethschen Zellen, und hyalinen Körpern. *Arch. f. path. Anat. u. Physiol.*, **247**, 236.

Ciaccio, C. 1906. Sur une nouvelle espèce cellulaire dans les glandes de Lieberkühn. *Comp. rend. soc. biol.* (1), **60**, 76.

——— 1907. Sopra speciali cellule granulose della mucosa intestinale. *Arch. di. anat. ed embriol.*, **6**, 482.

Clara, M. 1924. Über einige bisher wenig bekannte Zellformen im Darmepithel der Vögel. 88 *Vers. d. Naturf. u. Arzte in Innsbruck.*

——— 1926*a*. Beitrage zur Kenntnis des Vogeldarmes. II. Teil. Die Hauptzellen des Darmepithels. *Zeitsch. f. mikros.-anatomis. Forsch.*, **6**, 1.

——— 1926*b*. Beiträge zur Kenntnis des Vogeldarmes. III. Teil. Die basalgekörnten Zellen im Darmepithel. *Ibid.*, **6**, 28.

——— 1926*c*. Beiträge zur Kenntnis des Vogeldarmes. IV. Teil. Über das Vorkommen von Körnerzellen vom Typus der Panethschen Zellen bei den Vögeln. *Ibid.*, **6**, 55.

——— 1926*d*. Beiträge zur Kenntnis des Vogeldarmes. V. Teil. Die Schleimbildung im Darmepithel mit besonderer Berücksichtigung der Becherzellenfrage. *Ibid.*, **6**, 256.

Clark, E. R., and Clark, E. L. 1917. A study of the reaction of lymphatic endothelium and of leucocytes, in the tadpole's tail, toward injected fat. *Am. Jour. of Anat.*, **21**, 421.

Cordier, R. 1921. À propos des cellules argentaffines de l'intestin. *C. R. de l'assoc. des Anat.*, Paris.

——— 1923. Contribution à l'étude de la cellule de Ciaccio-Masson et de la cellule de Paneth. *Compt. Rend. d. l. Soc. Biol.*, **88**, 1227.

Cordeir, R. 1924. Les cellules argentaffines dans les tumeurs intestinales. *Arch. Internat. de Méd. Expériment.*, **1**, 59.

——— 1925. À propos de la signification physiologique de la cellule argentaffine. *Compt. Rend. d. l. Soc. Biol.*, **93**, 65.

Corti, A. 1925. Il lacunoma delle cellule dell'epitelio intesinale dell'uomo. *Arch. Ital. di Anat. e di Embriol.*, **22**, 457.

Corti, H. 1906. Sui meccanismi funzionali della mucosa intestinale assorbenti di mammifero. *Atti del Congresso dei Naturalisti Italiani*, Milano, 546.

Cowdry, E. V. 1918. The mitochondrial constituents of protoplasm. *Contrib. to Embryol. of the Carnegie Inst. of Wash.*, No. 271, 39.

——— 1924. Cytological constituents—mitochondria, Golgi apparatus, and chromidial substance. In *General Cytology*. Chicago: The University of Chicago Press, p. 311.

Cramer, W., and Ludford, R. J. 1925. On cellular changes in intestinal fat absorption. *J. Physiol.*, **60**, 342.

Danisch, F. 1924. Zur Histogenese der sogenannten Appendix-carcinoide. *Beiträge z. path. Anat. u. z. allg. Path.* (Ziegler's Beiträge), **72**, 687.

Deimler, K. M. 1904. *Vergleichende Untersuchungen über die Pylorus-drüsenzone des Magens und die Duodenaldrüsenzone des Darmkanals der Haussäugetiere.* Inaug. Diss., Zurich.

De Luca, U. 1904. Ricerche sopra le modificazioni dell'epitelio de'villi intestinali nel periodo di assorbimento e nel periodo di digiuno. *Bullettino della B. Accademia Medica di Roma*, **31**, 249.

Demjanenko, K. 1909. Das Verhalten des Darmepithels bei verschiedenen funktionellen Zuständen. *Zeitsch. f. Biol.*, **52**, 153.

Dixon, W. E., and Wadia, J. H. 1926. The action of intestinal extracts. *Brit. Med. Jour.*, **1**, 820.

Drago, U. 1901. Cambiamenti di forma e di struttura dell'epitelio intestinale durante l'assorbimento dei grassi. *Ricerche fatte nel laboratorio di Anatomia normale*, **8**, 65.

v. Ebner, V. 1899. In Koelliker, *Handbuch der Gewebelehre des Menschens*. Leipzig: W. Englemann, **3** (1st half), 174.

Eklöf, H. 1914. Chondriosomenstudien an den Epithel- und Drüsenzellen des Magen-Darmkanals und den Oesophagus-Drüsenzellen bei Säugetieren. *Anat. Hefte*, 1 Abt., Bd. **51**, 1.

Ellenberger, W. 1911. *Handbuch der vergleichenden mikroskopischen Anatomie der Haustiere*, **3**.

Ferrata and Moruzzi. 1905. Sulla membrana basale delle cellule di rivestimento dei villi intestinal. *Rendic. d. Ass. med.-chir. di Parma*, **6**, 125.

Forbus, W. D. 1925. Argentaffine tumors of the appendix and small intestine. *Johns Hop. Hosp. Bull.*, **37**, 130.

Galeotti, G. 1895. Über die Granulationen in den Zellen. *Internat. Monatsschr. f. Anat. u. Phys.*, **12**, 440.

Golgi, C. 1909. Sur une fine particularité de structure de l'épithélium de la muqueuse gastrique et intestinale de quelques vertébrés. *Arch. Italiennes de Biol.*, **51**, 213.

Gosset and Masson, P. 1914. Tumeurs endocrines de l'appendice. *Presse Médicale*, **22**, 237.

Greschik, E. 1912. *Mikroskopische Anatomie des Enddarmes der Vögel. "Aquila."* **19**.

——— 1922. *Über die Panethschen Zellen und basalgekörnte Zellen im Dünndarm der Vögel. "Aquila."* **29**.

Grünhagen, A. 1887. Über Fettresorption und Darmepithel. *Arch. f. mikr. Anat.*, **29**, 139.

Hambleton, B. F. 1914. Note upon the movements of the intestinal villi. *Amer. Jour. Physiol.*, **34**, 446.

Hamperl, H. 1923. Ein Beitrag zur Kenntnis des Dünn- und Dickdarmes der Insektivoren und Chiropteren. *Wien. Akad. Anz.*, **14**.

——— 1925. Über die gelben (chromaffinen) Zellen im Epithel des Verdauungstraktes. *Zeitsch. f. mikr.-anat. Forsch.*, **2**, 506.

Hasegawa, T. 1923. Ueber die Carcinoide der Wurmfortsatzes und des Dünndarmes. *Arch. f. path. Anat. u. Physiol. (Virchow's Archiv.)*, **244**, 8.

Heidenhain, M. 1899. Über die Struktur der Darmepithelzellen. *Arch. f. mikr. Anat.*, **54**, 184.

——— 1911. *Plasma und Zelle.* Jena: Gustav Fischer.

Heidenhain, R. 1888. Beiträge zur Histologie und Physiologie der Dünndarmschleimhaut. Supplement zum B. 43, *Arch. f. die ges. Physiol. (Pflüger's Arch.)*, s., 103.

Hock, J. 1899. *Untersuchungen über den Übergang der Magen- in die Darmschleimhaut, mit besonderer Berücksichtigung der Lieberkühnschen Krypten und Brunnerschen Drüsen bei den Haussäugetiere.* Inaug. Diss. Giessen.

Holmgren, E. 1902. Weiteres über die Trophospongien der Leberzellen und der Darmepithelzellen. *Anat. Anz.*, **22**, 313.

Hoyer, H. 1890. Über den Nachweis des Mucins in Geweben mittels der Färbenmethode. *Arch. f. mikr. Anat.*, **36**, 310.

Hübschmann, P. 1910. Sur le carcinome primitif de l'appendice vermiculaire. *Revue Méd. de la Suisse Rom.*, **30**, 317.

Ivy, A. C., and Fisher, N. F. 1923–24. The presence of an insulin-like substance in gastric and duodenal mucosa and its relation to gastric secretion. *Amer. Jour. of Physiol.*, **67**, 445.

Johnson, F. P. 1913. The effects of distention of the intestine upon shape of villi and glands. *Amer. Jour. of Anat.*, **14**, 235.

Kaufmann-Wolf, M. 1911. Kurze Notiz über Belegzellen, Panethsche Zellen, und basal gekörnte Zellen im Darm des Menschen. *Anat. Anz.*, **39**, 670.

King, C. E., Arnold, L., and Church, J. G. 1922. The physiological rôle of the intestinal mucosal movements. *Amer. Jour. of Physiol.*, **61**, 80.

Kischensky, D. P. 1902. Zur Frage über die Fettresorption im Darmrohr und den Transport des Fettes in andere Organe. *Beiträge z. path. Anat. u. z. allgem. Pathol.* (Ziegler), **32**, 197.

——— 1902. Zur Frage über die Resorption des Fettes im Darmkanal und über den Transport desselben in andere Organe. *Centralb. f. Allg. Path. u. Path. Anat.*, **13**, 1.

Klein, S. 1906. On the nature of the granule cells of Paneth in the intestinal glands of mammals. *Amer. Jour. of Anat.*, **5**, 315.

Klose, K. 1880. *Beitrag zur Kenntnis der tubulösen Darmdrüsen.* Inaug. Diss. Breslau, 1880.

Kossel, A., Behrens, W., and Schiefferdecker, P. 1889 and 1891. *Die Gewebe des menschlichen Körpers und ihre mikroskopische Untersuchung.* Bd. 1, 1889; Bd. 2, 1891.

Kostitch, D. 1923. Sur la présence des cellules à grain du type Paneth dans les culs-de-sac glandulaires du gros intestin. *Compt. Rend. de la soc. de Biol.*, **90**, 259.

Krieger, H. 1914. *Über den Glykogengehalt der Magenwand und der Wand der Duodenaldrüsenzone des Darmes bei Felis domestica.* Inaug. Diss. Dresden.

Kull, Harry. 1911. Über die Entstehung der Panethschen Zellen. *Arch. f. mikr. Anat.*, **77**, 541.

——— 1912. Über die Panethschen Zellen verschiedener Säugetiere. *Anat. Anz.*, **41**, 609.

——— 1913. Die "basal gekörnten Zellen" des Dünndarmepithels. *Arch. f. mikr. Anat.*, **81**, 185.

——— 1925. Die chromaffinen Zellen des Verdauungstraktes. *Zeitschr. f. mikr. anat. Forsch.*, **2**, 163.

Kultschitzky, N. 1897. Zur Frage über den Bau des Darmkanals. *Arch. f. mikr. Anat.*, **49**, 7.

List, J. H. 1886*a*. Über Becherzellen und Leydigsche Zellen. *Arch. f. mikr. Anat.*, **26**, 543.

——— 1886*b*. Zur Frage der Secretion und der Struktur der Becherzellen. *Arch. f. mikr. Anat.*, **27**, 48.

——— 1889. Über den feineren Bau schleimsezernierender Drüsenzellen nebst Bemerkungen über den Sekretionsprozess. *Anat. Anz.*, **4**, 84.

Macallum, A. B. 1894. On the absorption of iron in the animal body. *Jour. Physiol.*, **16**, 268.

——— 1895. On the distribution of assimilated compounds of iron other than hemoglobin and haematins in animal and vegetable cells. *Quart. J. Micr. Sc.*, London, **38**, 175.

——— 1924. *On the absorption of organic colloids by the intestinal mucosa.* Report of the ninety-second meeting of the British Association for the Advancement of Science, Toronto, p. 424.

Macklin, Charles C., and Macklin, Madge Thurlow. 1926*a*. Histological absorption phenomena in the small intestine. *Anat. Record*, **32**, 216. (Abstract.)

——— 1926*b*. Is the Mingazzini phenomenon, in the villus of the small intestine, an evidence of absorption? *J. Anat.*, **61**, No. 1, 144.

Majewski, A. 1894. Über die Veränderungen der Becherzellen im Darmkanal während der Sekretion. *Internat. Monatschr. f. Anat. u. Physiol.*, **11**, 177.

Martin, F. P. 1910. *Vergleichende histologische Untersuchungen über das Oberflächen- und Drüsenepithel der Darmschleimhaut der Haussäugetiere.* Inaug. Diss. Leipzig.

Martin, J. F., Dechaume, J., and Ravault, P. P. 1925. Carcinoïdes intestinaux et cellules de Kultschitzky. *J. de Méd. de Lyon*, **6**, 415.

Masson, P. 1914. Le glande endocrine de l'intestin chez l'homme. *Compt. Rend. Acad. des Sciences*, **158**, 59.

——— 1921*a*. Les névromes sympathiques de l'appendicite oblitérante. *Lyon Chir.*, **18**, 281.

——— 1921*b*. Les lésions nerveuses de l'appendicite chronique. *C. R. Acad. des Sciences*, **173**, 262.

——— 1922*a*. La neurogénèse dans la muqueuse de l'appendice pathologique. Rôle des cellules argentaffines dans ce phénomène. *C. R. de l'assoc. des Anat.*, 1922 (April).

——— 1922*b*. Les lésions du plexus nerveux periglandulaire dans l'appendicite chronique. *Bull. et mém. Soc. méd. d. hôp. de Par.*, 3s., **46**, 956.

——— 1923. Volumineux névromes appendiculaires ayant provoqué l'éclatement des musculeuses. *Bull. de la Soc. Anat.*, **93**, 305.

——— 1924. Appendicite neurogène et carcinoïdes. *Ann. d'anat. path. méd.-chir.*, Paris, **1**, 3.

Masson, P., and Berger. 1923. Sur un nouveau mode de sécrétion interne; la neurocrinie. *C. R. Acad. des Sciences*, **176**, 1748.

Mingazzini, Pio. 1900*a*. Cambiamenti morfologici dell'epitelio intestinale durante lo assorbimento delle sostanze alimentari. *Ricerche fatte nel Laboratorio di Anatomia normale d. R. Universita di Roma*, **8**, 41.

——— 1900*b*. La secrezione interna nell'assorbimento intestinale. *Ibid.*, **8**, 115.

Miram, K. 1912. Zur Frage über die Bedeutung der Panethschen Zellen. *Arch. f. mikr. Anat.*, **79**, 105.

Möller, W. 1899. Anatomische Beiträge zur Frage von der Sekretion und Resorption in der Darmschleimhaut. *Zeitsch. f. Wiss. Zool.*, **66**, 69.

Monti, R. 1903. Le funzioni de secrezione e di assorbimento intestinale studiati negli animali ibernanti. *Mem. R. Istit. Lomb.*, **11**, 1.

——— 1907. Nuovo contributo allo studio dell'assorbimento intestinale. *Rendic. del R. Istit. Lomb. di sc. e lett.*, Ser. II, **40**, 1.

Mottram, J. C. 1923. Some effects of exposure to radium upon the alimentary canal. *Proc. Roy. Soc. Med.*, Sec. of Electro-Ther., **16**, 41.

Mottram, J. C., Cramer, W., and Drew, A. H. 1922. Vitamines, exposure to radium and intestinal fat absorption. *Brit. J. Exp. Path.*, **3**, 179.

Nassonow, D. N. 1923. Das Golgische Binnennetz und seine Beziehungen zur Sekretion. Untersuchungen über einige Amphibiendrüsen. *Arch. f. mikr. Anat.*, **97**, 136.

Nicolas, A. 1890. Sur les cellules à grains du fond de glands de Lieberkühn chez quelques mammifères et chez le lèzard. Note preliminaire. *Bull. de science de Nancy*, 2 Année, Nr. 5.

——— 1891. Recherches sur l'épithélium de l'intestin grêle. *Internat. Monatssch. f. Anat. u. Phys.*, **8**, 1.

Oberndorfer, S. 1907. Karzinöide Tumoren des Dünndarms. *Frankf. Zeitschr. f. Path.*, **1**, 426.

——— 1909. Appendix Tumoren. *Ergebnisse der allgem. Path. u. path. Anat.*, **13**, 586.

Oppel, A. 1904. Verdauungsapparat. *Ergebn. d. Anat. u. Entwicklungsgesch.*, **14**.

Paneth, J. 1888. Über die secernierenden Zellen des Dünndarm-Epithels. *Arch. f. mikr. Anat.*, **31**, 113.

Parat, M. 1924*a*. Contribution à l'histophysiologie des organes digestifs de l'embryon. L'apparition correlative de la cellule de Kultschitzky et de la sécrétine chez l'embryon. *Compt. rend. soc. biol.*, **90**, 1023.

——— 1924*b*. Ibid. *Compt. rend. de l'ass. des anatomistes*, XIX Reunion, Strazburg.

Patzelt, V. 1882. Über die Entwicklung der Dickdarmschleimhaut. *Sitzungsb. d. k. Akad. d. Wissensch.*, Wien, **86**, 3 Abth.

Peterfi, Tiberius. 1914. Histologische Veränderungen der Darmepithelzellen während der Resorption. *Verband. der Anat. Gesellschaft auf der achtundzwanzigsten Versammlung in Innsbruck*, vom 13. bis 16. April, 1914, Ergänzungsheft zum 46 Band (1914) des Anatomischen Anzeigers, p. 168.

Piersol, G. A. 1920. *Normal histology*. Philadelphia and London: J. B. Lippincott and Co.

Pugliese, A. 1905. Cambiamenti morfologici dell'epitelio delle ghiandiole digestive e dei villi intestinale nei primi giorni della rialimentazione. *Bull. Sc. Med. Bologna*, 8.s., **5**, 267.

Ramond, F. 1904. Du mode d'absorption des graisses par l'intestin grêle. *Arch. de Méd. Experimentale*, **16**, 655.

Reuter, K. 1901. Zur Frage der Darmresorption. *Anat. Anz.*, **19**, 198.

——— 1903. Ein Beitrag zur Frage der Darmresorption. *Anat. Hefte*, **21**, 1 Abt., 123.

Saltykow, S. 1912. Beiträge zur Kenntnis der Karzinöiden Darmtumoren. *Verh. d. Deutsch. pathol. Gesellsch.*, **15**, 302.

Schafer, E. A. 1885. On the part played by amoeboid cells in the process of intestinal absorption. *Int. Monats. f. Anat. u. Physiol.*, **2**, 6.

——— 1912. *Text book of microscopic anatomy*. London: Longmans, Green and Co.

Schaeppi, T. 1907. Über den Zusammenhang der Epithelzellen des Darmes. *Arch. f. mikr. Anat.*, **69**, 791.

——— 1916. Über die Anheftungsweise und den Bau der Darmepithelzellen. *Ibid.*, **87**, 341.

Schaffer, J. 1891. Beiträge zur Histologie menschlicher Organe. I. Duodenum. II. Dünndarm. III. Mastdarm. *Sitzungsb. d. k. Akad. d. Wissensch., Math. naturw. Cl. Wien*, **100**, Part III, 440.

——— 1922. *Lehrbuch der Histologie und Histogenese.* Ed. 2, Leipzig: W. Englemann.

Schmidt, J. E. 1905. Beiträge zur normalen und pathologischen Histologie einiger Zellarten der Schleimhaut des menschlichen Darmkanals. *Arch. f. mikr. Anat.*, **66**, 12.

Schwalbe, G. 1872. Beiträge zur Kenntnis der Drüsen in den Darmwandungen insbesondere der Brunner'schen Drüsen. *Arch. f. mikr. Anat.*, **8**, 92.

Solger, B. 1894. Zur Kenntnis der secernierenden Zellen der Glandula submaxillaris des Menschen. *Anat. Anz.*, **9**, 415.

Starling, E. H. 1926. *Principles of human physiology.* Ed. 4, Philadelphia: Lea and Febiger.

Stöhr, P., and Lewis, F. T. 1914. *A text-book of histology.* Ed. 2, Philadelphia: P. Blakiston's Son and Co.

Stöhr, P., and Möllendorff, W. v. 1924. *Lehrbuch der Histologie.* Jena: Gustav Fischer.

Studnička, F. K. 1925. Die Cuticula und die Grenzschichten der tierischen Zellen. *Ztschr. f. Zellforsch. u. mikr. Anat.*, **2**, 408.

Suda. 1918. Chromophile Zellen des Magen und Darmepithels. *Med. Zeitschr. f. Kyoto*, **15**.

Szymonowicz, L. 1924. *Lehrbuch der Histologie.* Ed. 5, Leipzig: Curt Kabitzsch.

Tang, E. H. 1922. Über die Panethschen Zellen sowie die gelben Zellen des Duodenums beim Schwein und den anderer Wirbeltieren. *Arch. f. mikr. Anat.*, **96**, 182.

Tavernari, F. 1916*a*. Quelques aspects de la villosité intestinale dans la période de l'absorption. *Arch. ital. de Biol.*, 1916, 313.

——— 1916*b*. Alcuni aspetti del villo intestinale nel periodo dell'assorbimento. *Bull. d. sc. med. Bologna*, s. 9, **4**, 245.

Trautmann, A. 1910–11. Zur Kenntnis der Panethschen Körnchenzellen bei den Säugetieren. *Arch. f. mikr. Anat.*, **76**, 288.

Twort, F. W. 1924. The demonstration of a hitherto undescribed type of cell in the glands of the stomach. *Brit. Jour. of Exper. Path.*, **5**, 352.

Vernoni, G. 1908, 1909. Intorno al fondamento istologico di alcune funzioni del villo intestinale. *Archivio Ital. di Anatom. e di Embriol.*, **7**, 264.

Willier, B. H., Hyman, L. H., and Rifenburgh, S. A. 1925. A histochemical study of intracellular digestion in triclad flatworms. *Jour. of Morphol. and Physiol.*, **40**, 299.

Zawarykin, T. 1883. Über die Fettresorption im Dünndarm. *Arch. f. die ges. Physiol.* (Pflüger), **31**, 231.

Zillinberg-Paul, O. 1909. Fortgesetzte Untersuchungen über das Verhalten des Darmepithels bei verschiedenen funktionellen Zuständen. *Zeitsch. f. Biol.*, **52**, 327.

Zimmermann, K. W. 1898. Beiträge zur Kenntniss einiger Drüsen und Epithelien. *Arch. f. mikr. Anat.*, **52**, 552.

Zipkin, R. 1904. Beiträge zur Kenntnis der gröberen und feineren Strukturverhältnisse des Dünndarmes von Inuus rhesus. *Anat. Hefte*, **23**, 113.

PLATE I*

FIG. 1.—Principal cells from the depths of a crypt of Lieberkühn, human duodenum. The cell boundaries, striated cuticle and terminal bars in cross section are seen. Diplosomes near the free surface. Lymphocyte in the act of traversing the intercellular space. (After Zimmermann, 1898.)

FIG. 2.—A goblet cell, partially filled, in longitudinal section. Note relation of terminal bars to stoma. Centrosome in middle of granule mass. See Fig. 1. (After Zimmermann, 1898.)

FIG. 3.—Columnar absorbing cells from longitudinal section through villus of white rat, showing mode of attachment of base to basement membrane. a, a′ are cells whose basal processes insert themselves into the basement membrane; b, b′, b″ are cells with perforating basal processes. B, goblet cell; L, leucocyte. (After Schaeppi, 1916.)

FIG. 4.—Similar cell to those shown in Figure 3, to exhibit the basal processes. (After Schaeppi, 1916.)

FIG. 5.—Columnar absorbing cells from a villus of the duodenum of a rat, in act of absorbing fat plus vitamin B. The fat passes through in streams of very fine droplets, as shown. This is "absorption by streams." (After Mottram, 1922.)

FIG. 6.—Similar cells to those of Figure 5, but absorbing fat *minus* vitamins. Note that fat is in the form of very large droplets, mainly in the supranuclear region. This is "absorption by drops." (Ibid.)

FIG. 7.—Diagram of the striated cuticular border, from a preparation stained with iron hematoxylin, showing the various parts. OL, outer limb of rod. BG, border granule. IL, inner limb of rod. S, sheath. BE, basal ellipsoid. C, cytoplasm. D, this region is shown only slightly differentiated, in contrast to the others, in which the differentiation has been carried farther, and discloses the sheath. (After Clara, redrawn, 1926*a*.)

FIG. 8.—Basal granular cell of a guinea pig. In this animal the granules fill almost the entire cell. Note shape, and large, round, vesicular nucleus. Compare with Figure 16, Plate II, for position in crypt. (After Kull, 1913.)

FIG. 9.—Columnar absorbing cells, showing fat absorption (apparently without vitamins). To show particularly the fat droplets in the intercellular spaces. Compare with Figure 10. (After Reuter, 1903.)

FIG. 10.—A transection of the basal regions of the cells seen in Figure 9, showing the fat droplets in the intercellular spaces. (Ibid.)

FIG. 11.—Columnar absorbing cells from mouse, to show the intercellular bridges uniting the cells across the intercellular space. (After Schaeppi, 1907.)

FIG. 12.—Fundus of intestinal gland of guinea pig, six hours after taking food. Staining with iron alum hematoxylin and mucicarmine. Shows the discharged condition of the Paneth cells, P. (After Klein, 1906.)

FIG. 13.—Fundus of intestinal gland of guinea pig, but after twenty-four hours' fast, and shows the Paneth cells (P) loaded with secretion granules. Staining by orange-rubin-toluidine blue. (After Klein, 1906.)

FIG. 14.—Columnar absorbing cells, and goblet cell, from white mouse, to show mitochondria. (After Cowdry, 1918.)

* Consecutive figures 62 to 75.

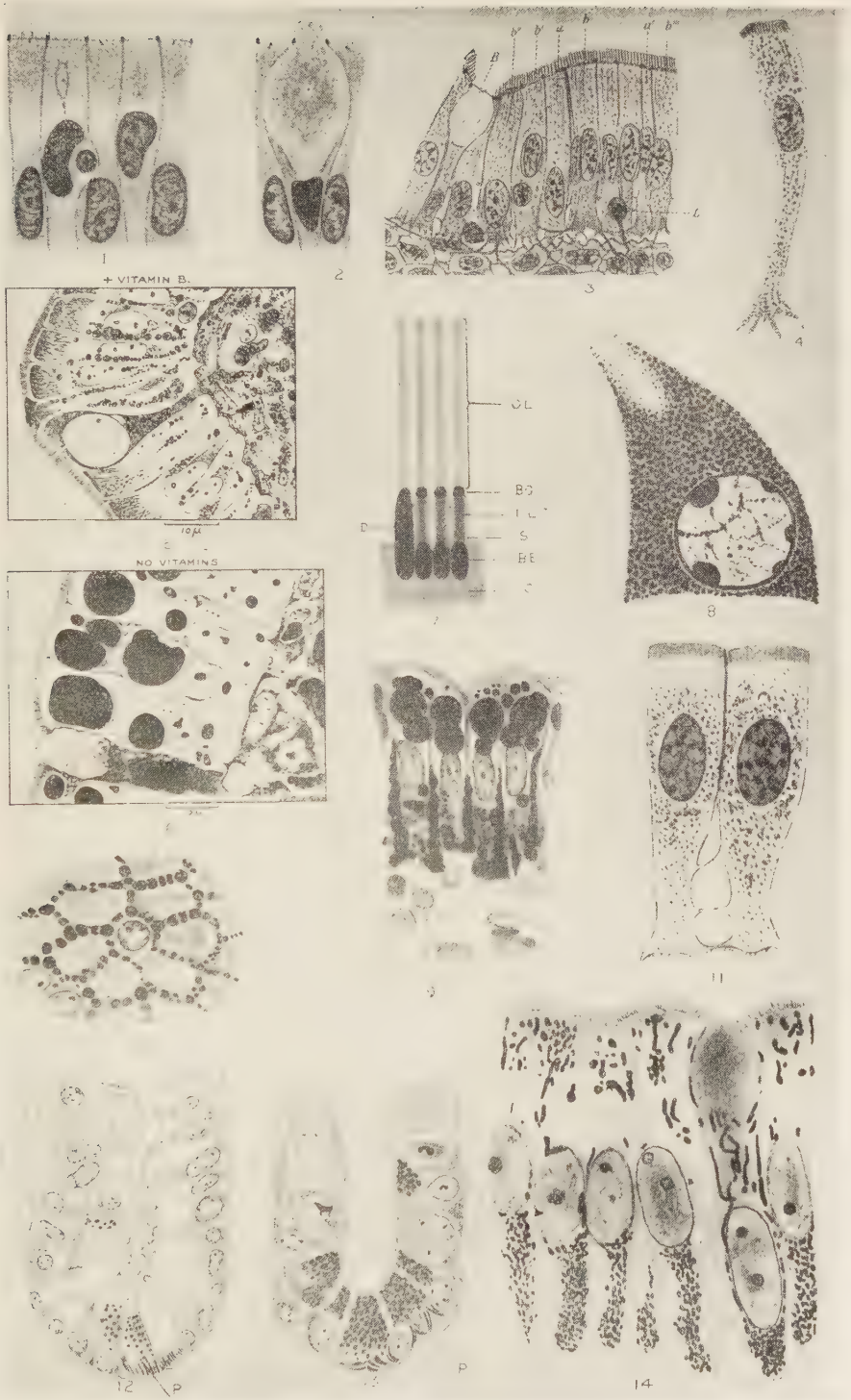

PLATE I, Figures 1–14.—Intestinal epithelium.

PLATE II *

FIG. 15.—Columnar absorbing cells of the mouse, somewhat schematic. In the right half of the figure the cuticular border is omitted in order to disclose the network of terminal bars. C, cuticular border. CT, connective tissue. IS, intercellular space. L, lymphocyte. TB, terminal bar network. (After Stöhr and v. Möllendorff, 1924.)

FIG. 16.—Intestinal gland of guinea pig, showing basal granular cells (densely stained) and cells of Paneth (large granules). The relation to principal and goblet cells is seen. (After Kull, 1913.)

FIG. 17.—A portion of a lobule of a gland of Bunner of man, located in the tunica mucosa. The duct of the gland opens into a gland of Lieberkühn, where a sudden change in the character of the cells takes place. The cells of the duct become richer in secretion the farther they are from the point of entrance into the intestinal gland, the nuclei at the same time becoming more flattened. In many of the cells may be seen a transverse band of cytoplasm separating the secretion into two masses. B, first cell of Brunner's gland. MM, muscularis mucosae. P, Paneth cell. (After Bensley, 1903.)

FIG. 18.—Transverse section of two tubules of the glands of Brunner of the opossum. The drawing shows the structure of the cells composing these tubules in the condition of incomplete loading. The secretion is subdivided into a proximal and a distal mass by a band of cytoplasm (BC). Some basal cytoplasm still remains at the attached end of the cell, and around the nucleus. BC, band of cytoplasm separating two masses of secretion. CC, Cells in which the two masses are becoming confluent. DZ, Distal clear zone containing distal mass of secretion. PZ, Proximal clear zone containing proximal mass of secretion. (After Bensley, 1903.)

FIG. 19.—End of villus of dog, which was fixed in fluid containing picric acid, which has had the effect of causing the core to shrink and squeeze out its content of fluid into an artificial space beneath the epithelium. The latter has become stretched and the cells changed to cuboidal form, but they are held together by their cement substance. Cells still attached to basement membrane are tall and narrow. (After R. Heidenhain, 1888.)

FIG. 20.—Fragment of human colon epithelium, near mouth of crypt, showing four principal, and two goblet cells. In the principal cells the diplosome is shown in a small light space near the upper surface. In one of the goblet cells a centrosome is shown in the middle of the secretion mass. Relation of terminal bars to these cells is seen. (After Zimmermann, 1898.)

FIG. 21.—Goblet cells seen in transection through centrosome, showing edge of theka. (After Zimmermann, 1898.)

FIG. 22.—Transitional cells between the excretory ducts and the acini of Brunner's glands, human. The cell is cuboidal, with a light superficial area, containing a diplosome. (After Zimmermann, 1898.)

* Consecutive figures 76 to 83.

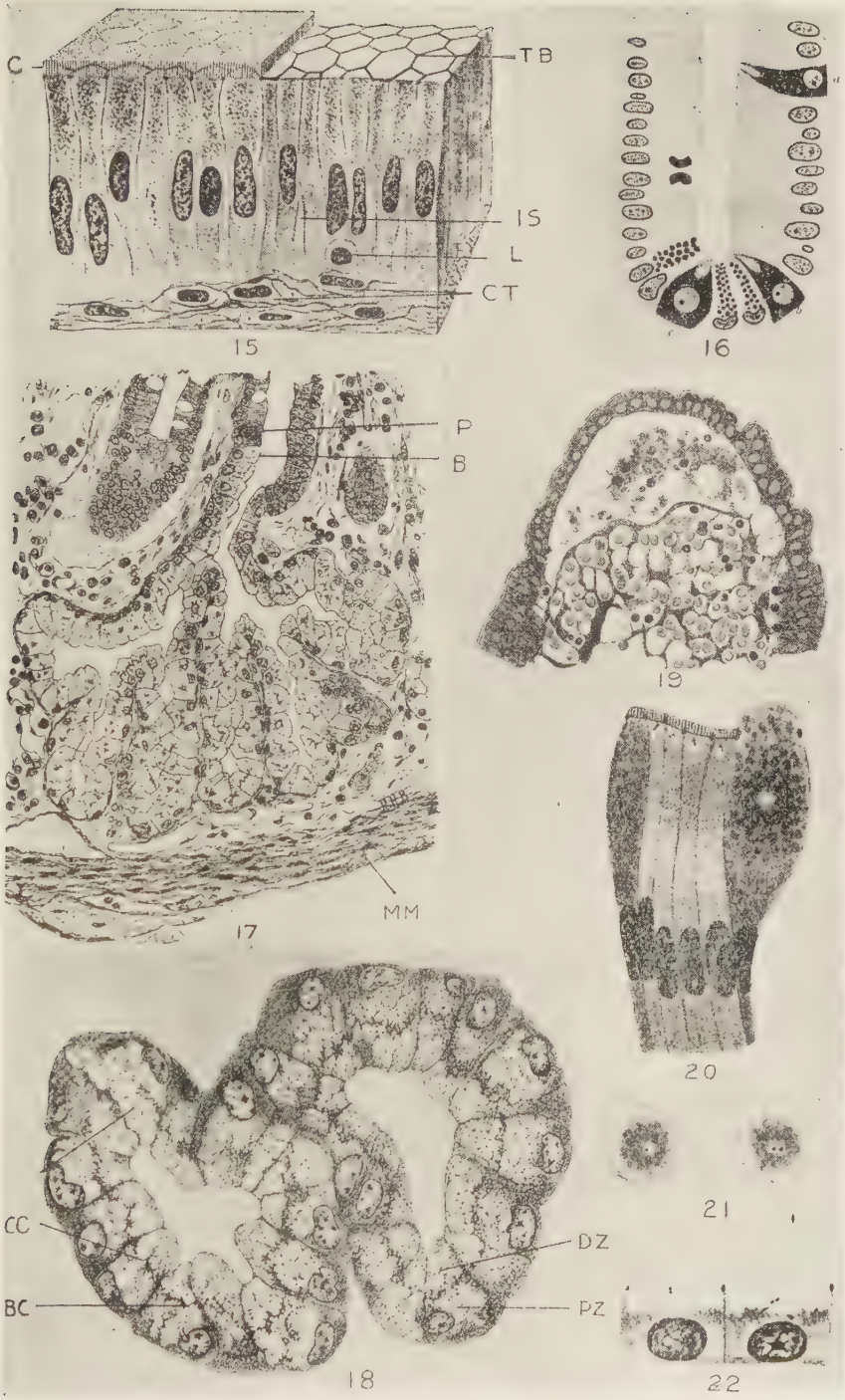

PLATE II, Figures 15–22.—Intestinal epithelium.

PLATE III *

Fig. 23.—Columnar absorbing cells from dog, showing the dilated intercellular spaces, and relation of these to the tissue-fluid spaces of the core. Three goblet cells. (After Kultschitzky, 1897.)

Fig. 24.—Longitudinal section through part of crypt of Lieberkühn, showing (a) cells with acidophilic granulation, which have been later found to be young basal granular cells. (Ibid.)

Fig. 25.—Fundus of crypt (as in Fig. 24).(Ibid.)

Fig. 26.—Shows a young basal granular cell, with acidophilic granules (a) among columnar absorbing cells of the villus of the dog. (Ibid.)

Fig. 27.—Columnar absorbing cells of rat, showing the accumulation of mitochondria in the starved condition. (After Asher, 1908, redrawn.)

Fig. 28.—Similar cells to those of Figure 27, but from a rat after feeding; shows the diminished mitochondrial content. (Ibid.)

Fig. 29.—Surface view of fresh columnar absorbing cells from cat, showing polygonal outline of cuticle plates, and mouth of goblet cell (Muc.). (C. C. Macklin.)

Fig. 30.—Human columnar absorbing cells, showing the intracellular apparatus. (After Holmgren, 1902; from M. Heidenhain, 1911.)

* Consecutive figures 84 to 91.

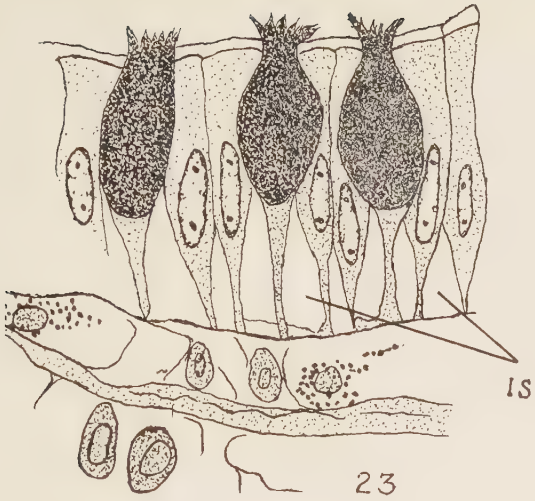

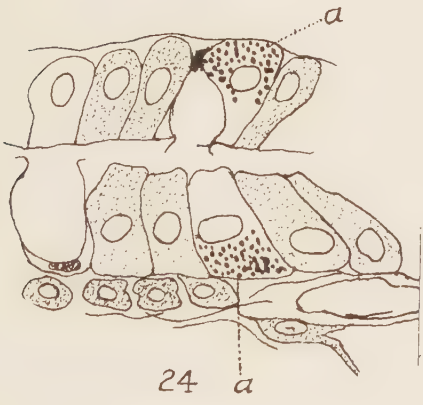

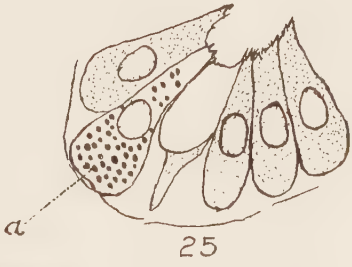

PLATE III, Figures 23–30.—Intestinal epithelium.

Section VIII

THE CYTOLOGY OF THE LIVER AND ITS FUNCTIONAL SIGNIFICANCE

CONTENTS

SECTION VIII

PAGE

I. GENERAL EMBRYOLOGY OF LIVER 206
II. COMPARATIVE ANATOMY OF LIVER 206
III. MAMMALIAN HEPATIC LOBULE 207
IV. CYTOLOGY OF IMPORTANT CELL GROUPS IN LIVER 211
1. Hepatic cell 211
General characteristics—Internal organization—Changes during physiological activity.
2. Stellate cell 217
General characteristics—Internal organization—Changes during physiological activity.
3. Biliary channels 218
Intrahepatic biliary system—Extrahepatic biliary system.
V. CYTOLOGICAL CHANGES ASSOCIATED WITH KNOWN FUNCTIONS OF LIVER . . 224
1. Secretion of bile 224
2. Carbohydrate metabolism 226
3. Protein metabolism 227
4. Fat metabolism 227
5. Detoxicating action 228
6. Circulation tissue 229
VI. SPECIALIZATION OF FUNCTION OF CELLS IN HEPATIC LOBULE 230
VII. REGENERATION 231
VIII. CYTOLOGICAL CHANGES IN MORE REPRESENTATIVE PATHOLOGICAL PROCESSES IN LIVER 231
IX. HEPATIC EXTRACTS 232
X. BIBLIOGRAPHY 233

Section VIII

THE CYTOLOGY OF THE LIVER AND ITS FUNCTIONAL SIGNIFICANCE

FRANK C. MANN

PROBABLY no other organ in the body has so many and such diversified functions as the liver. It might thus be assumed that cytologically the organ would be made up of a variety of highly specialized cell groups, differing markedly, and each performing some specific function or functions. On the contrary, one finds that normally no other organ of the body presents a picture in which, on casual observation, all the cells appear so similar. The liver pattern appears as geometrically laid out, with all portions symmetrical and all units alike. However, when the details of the hepatic cell are considered, it appears to be as variable an anatomical unit as is known. Its form, relative size and internal structure are varying constantly with the manifold physiological activity of the organism of which it forms a vitally important and intimate part. The fact that the liver performs many diversified functions, and that there are no specialized cell groups in the organ, would imply that the varying organization of the hepatic cell is of great physiological significance. The cytology of the liver would thus seem to offer a fruitful and fascinating field for investigation and research. Unfortunately at present, definite and complete knowledge concerning most of the functions of the liver are lacking, and the observations on the cytology of the various component cells of the organ are contradictory.

Knowledge concerning the functions of the liver has been obtained by several different methods of investigation. The most important studies have been with the following methods: (1) the effect of different hepatic injuries on various physiological processes; (2) the effect of total and partial removal of the organ; and (3) the cytological changes in the organ following various physiological procedures and pathological processes. It is thus seen that a study of the cytology of the liver has only been one method, although an invaluable one, of determining some of the physiological activities of the organ. While we shall attempt to correlate as many of the data as appear justifiable, at present it is only possible to present a more or less disconnected story concerning the cytology of the liver in relation to its function and to indicate in a brief manner the apparently large and enticing field for future endeavor.

One of the most interesting, and from the clinical standpoint, most important parts of the liver is the biliary tract. The anatomy, physiology and pathology of this system through which the liver discharges its external

secretion forms a large and growing portion of medical literature. Although a review of the known facts of the most important part of the biliary tract, the gall bladder, has recently been made, a brief comment of the cytological aspect of the biliary tract, together with a review of the most recent advances, will be given.

I. GENERAL EMBRYOLOGY OF THE LIVER

The liver is first evident in a human embryo of 2.5 mm. body length. It arises as a ventral diverticulum of the foregut and lies between the paired vitelline veins as they continue toward the heart. Portions of the embryonic septum tranversum, into which this diverticulum early extends, forms the suspensory ligament of the adult liver. From the anterior and the ventral wall of this primitive cul de sac, which is in wide communication with the lumen of the entoderm, an extensive cell proliferation gives rise to a mass of deeply staining cells with abundant granular protoplasm. Thus at 4.5 mm. the embryonic liver may be differentiated into two parts: the diverticulum lined with columnar epithelium, and the anastomosing hepatic parenchyma.

The original diverticulum subsequently differentiates into vesica fellea, ductus cysticus and ductus choledochus, while the proliferating parenchyma forms the functional secretory units, the biliary canaliculi and the hepatic ducts. Coincident with the rapid cell proliferation is the development of the sinusoidal circulation. Primitive vitelline veins and the umbilical veins become involved in the extensive growth of the hepatic cells, so that these veins are broken down and give rise to the numerous vascular channels which permeate the liver of the adult. Thus, the parenchymal cell, arising by proliferation from the diverticulum, is associated on the one hand with the sinusoid of endothelial origin, and on the other hand with the canaliculus which is continuous with the major portions of the intrahepatic channels. The tubular organization of the liver, characteristic of the embryonic condition, is gradually transformed into a lobular structure, more definite in some livers than in others, each lobule becoming the functional anatomical unit of the adult gland. In this connection it is important to note that very early in the development of the embryo the liver acquires a double vascular system, one of which drains from the source of food supply. This principle is maintained throughout life. It should also be observed that the early development of the liver and its relatively large size are indicative of its importance even in embryonic development.

II. COMPARATIVE ANATOMY OF THE LIVER

Among the lower invertebrates which are known to have a liver, it is restricted to a zone differentiated from the mesenteron by its striking color. It is usually associated with a pancreas so that the entire structure, containing pancreatic alveoli and hepatic cells, is known as an hepatopancreas. The cells of this structure are usually pigmented and contain the usual hepatic granulation. Among vertebrates a definite organization is first established, and a rather distinct phylogenetic transformation, from the tubular gland of the lower types to the definitely lobular one of mammals, is recognized.

In Amphioxus, considered by many as ancestral to all vertebrates and by others as a degenerative type, a diverticulum of entoderm which forms a cecal pouch is the liver. Its function as a gland may be relatively slight, and yet oily granulations and pigment contents of the cells affirm their biliary nature. Its origin as a diverticulum from the alimentary tract further confirms its relationship to the liver of higher vertebrates, which arises in the same way.

Among fishes, a definitely tubular hepatic gland is first evident. The number of cells comprising a single tubule is variable, but four to ten hepatic cells may be counted in a cross section. These cells vary in diameter from 5 to 15μ, and all of them are in contact with the biliary canaliculus coursing through the center of the secretory unit. Vascular channels course between the tubules and yellow pigmentation abounds in the cytoplasm of the cells adjacent to these sinusoids. In many species of fishes, pancreatic tissue is also found in the liver.

Within the amphibian group, partial lobulation is suggested, although the primitive tubular condition still obtains. Pigment granules have a seasonal distribution and appear in some way correlated with the onset of metabolic activity, during the breeding season. Pigment is not of hepatic formation, but has been traced directly into the hepatic ce ls, from an origin associated with digestion. In Proteus, the hepatic cell is unusually large, the cytoplasm is reticulate and oil droplets abound within the meshes of the reticulum.

In reptiles, the tubular organization obtains, and yet pseudo-lobulation is suggested. Cell dimensions are variable, these being greater in the Chelonians than among the Lacertilia and the Ophidians. Intercellular bile capillaries are numerous, and Braus recognized intracellular clefts or bile communications within the cytoplasm. In Aves the hepar is transitional between that type more piscine or amphibian and that more mammalian. The tubular arrangement of the hepatic parenchyma abounds in the chick liver, but in the adult with increasing vascularity lobulation is the result. Hepatic cells are small and their cell boundaries are very indistinct, a characteristic distinctly mammalian.

In all embryonic mammals, the parenchyma of the liver is tubular, and with development, as in birds, lobulation is accomplished. Throughout phylogenesis, complexity of hepatic organization seems to go hand in hand with the degree of vascularity of the organ. Specialization into lobules perfects the means of vascular distribution and thereby permits the endocrine function so intimately correlated with the mammalian liver.

Our knowledge of the comparative anatomy of the liver, while incomplete, would indicate that the organ has not only increased in importance with the increase in physiological specialization and complexity but that the character of its functions has also gradually changed. The simple tubular gland, constructed seemingly especially for the production of an external secretion, has gradually changed to the more complex structure in which the elaboration of an external secretion has been made secondary to activities of the nature of an internal secretion.

III. THE MAMMALIAN HEPATIC LOBULE

The lobule of the liver was first recognized grossly by Wepfer (1664) in the pig. Subsequent studies on the unit revealed that the cells comprising it were grouped in a more or less radiating arrangement around the terminal twigs of the hepatic vein, and thus the term, hepatic lobule, came into general use. Kiernan (1833), however, recognizing secretory activity as a basis for morphological organization, made a suggestion which Brissaud and Sabourin (1888) developed into the concept that the portal lobule with the biliary duct as axial, should be considered as the actual unit of the liver. Likewise, Mall (1906) continued to use the term portal lobule to designate

that area surrounding a portal space from which many of the hepatic structures radiate. Mall used the term hepatic lobule to designate that unit whose function is essentially related to the circulation of the blood, which is radially constructed around the terminal twigs of the hepatic vein.

There are thus two possible units of organization of the liver. The one emphasizes the function of the liver in elaborating an external secretion and the other emphasizes its physiological dependence on the vascular system and its functions similar to those of a ductless gland. Not only because of its long usage, but more because the hepatic lobule appears anatomically to be the most useful unit for obtaining a comprehensive idea of the structure of the liver, and also because at present the endocrine-like functions of the liver appear to be the most important, the term hepatic lobule will be used here as the basis of the anatomical organization.

The embryonic liver consists of but a single lobule, which subsequently forms but two; then later, in an 11 mm. embryo, six lobules have been differentiated. By the further growth of the hepar, in which the cells become associated with the capillaries of both the hepatic and portal veins, the number of lobules increases until in the adult dog there are 480,000 hepatic lobules, each measuring approximately 0.7 mm. in height and 0.7 mm. in diameter (Mall, 1906). In the liver of either dog or man these lobules are not well differentiated, while in the pig and camel heavy strands of connective tissue completely isolate each lobule. This framework, more extensive in some livers than in others, is a continuation of the external enveloping capsule of Glisson, and consists of an abundance of elastic tissue, together with certain collagenous materials. It serves as a vehicle for the blood vessels, the nervous and lymphatic structures, as well as for the major biliary channels.

The parenchyma of the hepatic lobule is arranged in trabeculae which extensively anastomose with each other, in a more or less radial arrangement around the central vein. These trabeculae are usually but two cells in width and are separated from each other by branching sinusoids, through which the blood flows from the branches of the portal vein and hepatic artery into the central vein, and thence through the sub-lobular circulation into the hepatic vein. A biliary canaliculus lies in the center of each trabecula and courses from the center of the lobule toward the periphery and thus in a reverse direction to that taken by the blood stream. These canaliculi, usually surrounded by but two secreting cells, are recognized with difficulty and appear to possess delicate membranes, the product of the ectoplasm of the hepatic cell. Frequently canaliculi give rise to intercellular branches, which in some instances seem to surround the cell, forming quite definite meshes. Intracellular passages were described by Pflüger (1869), when by means of injections he noted very fine passages entering the cells and dividing and extending around the nucleus as small

networks. Kupffer (1873) also observed small intracellular spaces within the hepatic cells. The source of these intracellular ducts is a matter of conjecture. By some they are considered as of intracellular origin, arising as small spaces within the fibrillar stroma and subsequently joining the intercellular canaliculi, while to others they represent side branches which permeate the cell and end in enlarged vacuoles near the nucleus. These knob-like terminations are regarded as secretory and appear to arise by the confluence of small droplets and to be associated with the physiological activity of the cell. Browicz (1897) concludes that the nuclear spaces of the hepatic cell stand in direct communication with this intracytoplasmic system and that the latter are continuous with the intercellular canaliculi. More recent workers (Arnold, 1908 and Sterling, 1911) have concluded that there are no intracellular passages. It is obvious that there are many chances for erroneous observations to be made in regard to such structures and that their presence has not been proved.

The supporting structure of the lobule comprises a delicate system of fine threads which extend throughout and are continuous with the capsule of Glisson. These fibers are usually without cell bodies or nuclei, and, in the main, follow the course of the sinusoids, surrounding them as very fine nets. Oppel (1891) recognizes two types of supporting fibers in the lobule. Of these, one is a larger, conspicuous fiber which courses radially with but slight change in direction, from center to periphery, while the other group of fibers comprises a mesh of smaller caliber and extends around the hepatic cells and the larger fibrous mesh.

The endocrine-like function of the liver is made certain by the extensive vascularity of the hepatic lobule. Anastomosing sinusoids coursing centripetally through the lobule convey the blood from the perilobular branches of the portal vein to the central and thus to the hepatic vein. According to Gilbert and Villaret (1909), partial or total injection of the lobular sinusoids may be accomplished at will, depending on the time of the injection. These authors differentiate two zones within the lobule, on the basis of the structure of the related circulatory channels. Around the central vein and its adjacent sinusoids, there is a greater amount of connective-tissue fibrils and muscle bundles than at the periphery of the lobule. When the portal vein is injected immediately after death, the injecta accumulates in the center of the lobule, due to the contraction of the elastic tissue of the peripheral lobular channels. Likewise, an injection into the hepatic vein immediately after death fills the peripheral sinusoids of the lobule. On the other hand, an injection into the hepatic vein several hours after death shows an accumulation in the central vein and the adjacent sinusoids only; contractility and elasticity of the sinusoidal walls have disappeared.

These sinusoidal spaces are enclosed by a membrane not typically endothelial. Many authors regard the vascular wall as a syncytium in which

Herring and Simpson (1906) identify two kinds of cells. Of these, certain ones possess small nuclei with very little granular protoplasm and more closely resemble typical endothelial cells. These cells lie usually close to the periportal space with their long axes parallel to the direction of the sinusoid. The other cells within the syncytium are larger, and possess larger nuclei and stellate cell bodies, which Kupffer (1876) first recognized by the gold chloride method. They appeared as deep black bodies on a red field near the vascular channels. The cells were smaller than the hepatic cells; they occurred singly at more or less regular intervals, and appeared to lie just outside of the capillary wall. Long, attenuated cytoplasmic extensions frequently encircled the capillaries or even extended into the areas between the hepatic cells. They were never observed to extend into the intracellular structures. They were phagocytic, engulfing erythrocytes or any other foreign particles. Later, Kupffer (1899) regarded these stellate cells as definite integral parts of the vascular endothelium, rather than as elements extraneous to it.

Direct communications between the vascular channels and the cytoplasm of the hepatic cell have been described by many students. Schafer (1901) injected the livers of cats and rabbits through the portal vein with a carmine gelatin solution, and he noted direct continuity from the vascular channels into the hepatic cells. The inclusions were of the same consistence as in the sinusoid and thus apparently could not have been induced by pressure through the walls of the cell as many observers suggested. Later Herring and Simpson (1906) made injections wth relatively low pressure into the aorta and observed that definite channels, exceedingly fine, could be demonstrated in the cytoplasm of the hepatic cell. These frequently became ring-shaped, encircling the nucleus, although none was ever seen to enter the nuclear material directly. Holmgren (1901) also described channels within the hepatic cells which he regarded as enclosing the elongated cytoplasmic extensions of the Kupffer cells. These observations have been questioned and the same criticisms as regards the intracellular canaliculi would apply to them.

The earlier studies on the lymphatic organization of the liver resulted in two entirely opposing concepts. Mac-Gillavry (1864), and others working with him at that time and later, concluded that perivascular lymphatic channels extend around the sinusoids within the hepatic lobule. He was not supported by Hering (1871), who considered the lymphatic channels restricted to the periportal spaces, associated with the portal vein and the hepatic artery. Disse (1890) described actual communications between the hepatic vein and the periportal lymphatic channels. Herring and Simpson (1906) were unable to identify any lymphatic structures actually within the lobule. Baum (1922) believed he had demonstrated that the lymph vessels of the surface of the liver may open directly into the portal venous system. Lee

(1925) states that the lymphatic vessels form a rich plexus through Glisson's capsule and sheath, and that they extend up to, but not within, the hepatic lobule. They form many anastomoses in the walls of the hepatic and portal veins, but do not make any contact with the hepatic cell.

The nerves of the liver originate from both the sympathetic trunk and the vagus nerve. They reach the liver by following the hepatic artery along which structure they form a fair-sized bundle. They have been traced to the gall bladder, large bile ducts, along the arteries and over the capsule of the organ. Their relationship to the hepatic lobule and particularly the hepatic cell is not known. Most of the fibers would appear to be vasomotor in character.

IV. THE CYTOLOGY OF THE IMPORTANT CELL GROUPS IN THE LIVER

1. *The hepatic cell:*

The variability of the structure of the hepatic cell due to functional activity makes the description of the cytology of the normal cell difficult. I have made an attempt to describe the cell as found under basal conditions and following increased physiological activity.

General Characteristics. Among primitive vertebrates in general, the form of the inactive hepatic cell is more or less pyramidal, the base lying on the endothelium of the vascular channel, while the apex is directed toward the biliary canaliculus. In mammals, on the other hand, in which group a rather extensive rearrangement of the hepatic parenchyma has occurred, the cells are more polyhedral than pyramidal. Although the particular form of the cell, either pyramidal or polyhedral, may be characteristic for the larger group, the cellular dimensions within the individual are extremely variable and depend, as suggested, on the degree of physiological activity. In general, the axes of the polyhedral hepatic cell of man range from 26 to 35μ in diameter, while those in the dog are smaller, usually measuring from 18 to 22μ.

Internal Organization. Together with all living tissue, the hepatic cell comprises the constant constituents of nucleus and highly organized cytoplasm. In polyhedral cells the nucleus is centrally situated, while in the pyramidal type it is generally more peripheral, that is, nearer the vascular sinusoid. Whereas the uninuclear condition is the rule, multinuclear hepatic cells are frequently encountered. Although four or six independent nuclei have been observed in hepatic cells, binuclearity is the more usual variation from the normal. Such multinuclearity has been considered as due either to incomplete caryocinesis, probably associated with hyperactivity, or to fusion associated with degeneration. Arapow (1901) recognized that following various foods binuclearity of hepatic cells of white mice was far more common.

A nuclear membrane is readily differentiated, more or less distinct from the internal nuclear structures. Within it, the linin fibers form a somewhat irregularly distributed network throughout the nucleus. Very fine granulations of varying sorts are observed at the nodal points of this linin structure. These fibers are acidophilic and form the achromatic portion of the nucleus. Scattered throughout the nucleus and in the interstices of the linin meshes is the nucleoplasm, often intensely colored by certain stains, while the chro-



FIG. 92.—An hepatic lobule of the pig, illustrating the structure of the hepatic unit. Note the central vein; the radiating trabeculae of hepatic cells; the sinusoids partially lined with stellate cells, and the vessels and ducts supported in the interlobular spaces. × 100.

matin, strongly basophilic, is scattered irregularly in small variable masses throughout the nucleus. Even as the size of the cell varies directly with its physiological activity, so the amount of chromatin is thought by many writers to vary with the functioning status of the cell at the time of observation. Nucleoli are usually present in hepatic nuclei. They are generally round, often oval, and are scattered irregularly among the linin fibers. Their reaction is strongly acidophilic. Furthermore, under varying conditions, crystals of pigment, probably hemoglobin or some reduction product, occur in the nucleoplasm of the hepatic cells.

Hepatic cells, grouped together into functional units known as lobules, are rather definitely delineated from each other. Cell membranes, originally considered as definite structures, separate adjacent cells from each other. More accurate, perhaps, are the recent statements in which the fact is recognized that a membrane as such does not exist, but that its apparent presence is due to highly concentrated or condensed regions of the ectoplasm of the cells. This condensed layer of protoplasm is permeable, permitting the constant interchange of substances between the cell and the adjacent vascular or biliary channels. Kupffer (1875) believed that the cytoplasm of the hepatic cell of cold-blooded vertebrates was made up of a clear, colorless fluid. The extent of the fibrillar arrangement in the cell was shown by Flemming (1882) to vary with the height of activity. Among mammals, this



FIG. 93.—A group of hepatic cells around the central vein of the liver of a spermophilus stained with Best's carmine stain for glycogen. The animal has been well fed previous to death. Note the character and location of glycogen granules which almost obscure the other elements of the hepatic cells. × 440.

same cytoplasmic reticulum obtains. As a rule, these fibrillae converge from the periphery of the cell toward the nucleus, and not toward the biliary tract as is common in the hepatic cells of cold-blooded vertebrates. In the meshes of the reticulum are the glycogenic, fatty, proteid and pigmented enclosures, which will be considered in more detail in a later section. At the periphery of the cell, the reticular fibers are less extensive and the enclosed meshes accordingly larger; more centrally the fibers closely approximate each other, so that at the nucleus these meshes are practically invisible.

Besides the clear hyaloplasm of the interstices of the reticulum of the cytoplasm, there are numerous morphological units. Structures which have been designated differently by various observers are regions of cytoplasmic condensation, more or less accentuated in the vicinity of the nucleus. These granules are significant in physiological processes such as glycogen formation or secretory activity. In this sense they are similar to mitochondria, and Prenant (1910) would so have grouped these earlier described cytoplasmic inclusions.

Altmann (1889) apparently first established the existence of granules and filaments in the hyaloplasm of the hepatic cell. In studies on the liver of *Rana esculenta*, he recognized numerous granules within the hepatic cell which were strongly acidophilic. He observed that these granules varied in size and in disposition with the particular stage of digestion. A filament was recognized simply as an attenuated granule, filled by reserve materials produced within it. Likewise plasmasomes, shown by Arnold (1908) to be so intimately associated with glycogen deposition, are of the nature of the granules of Altmann and should probably be designated as mitochondria.

Mitochondria of the hepatic cell, as of other cells, are of variable structure. They are rod-like, filamentous or granular and they frequently form

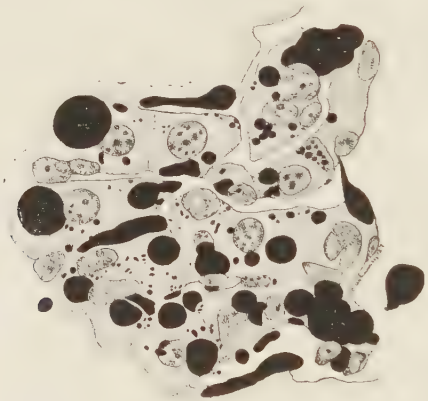

FIG. 94.—A group of hepatic cells around the central vein of the liver of a guinea pig. The animal had been fasted for a period of six hours and the specimen fixed in formalin and stained with Scharlach R. Note the indistinct cell outlines and the large amount of fat (round globules) which appears in the liver following the physiological condition of fasting. The elongated masses are endothelial cells. × 950.

networks of considerable extent. They are especially variable in the hepatic cell of mammals, and seem to be more abundant in the vicinity of the nuclei. They are bacilliform and are often curved in the shape of an arc or twisted into a coil or, more commonly, simply granular. Intermediate stages are abundant and one is inclined to feel that all are probably related in the sense of having a common origin. Filamentous mitochondria are usually uniform in diameter, although they may have variable lengths. Increase in diameter is induced by the absorbed materials rather than by any proliferation of the mitochondrial elements. The shape and position of these structures are likewise variable. Although normally more paranuclear, under certain conditions the filamentous mitochondria become spherical and migrate to the periphery of the cell. Under normal physiological activity, changes in shape are usual. Imbibition of known substances from

the cytoplasm into the mitochondria is well established, but just what processes are involved is still a conjecture. That it is not a transformation of one material into another seems likely. More probably actual absorption occurs accompanied by chemical dissociation with resultant synthesis which gives rise to the various inclusions noted during digestion.

Changes during Physiological Activity. It is difficult to describe and give a compositive picture of the hepatic cell during various physiological activities, not only because of the marked variability which occurs but also because of the contradictory observations and varied nomenclature of the

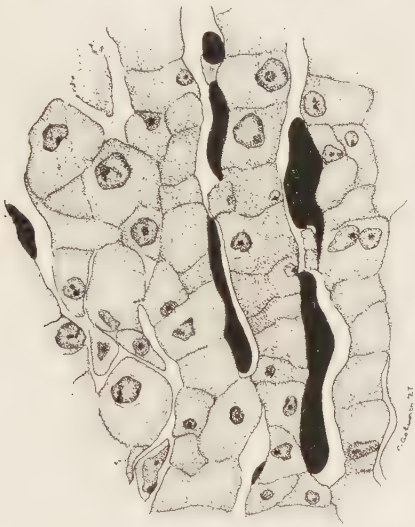

FIG. 95.—A field of an hepatic lobule of the dog. The specimen had been fixed in Zenker and stained with Berlin blue and alum carmine. This technique stains all the iron-containing cells a dominant blue. Note that all the iron is stored in the endothelial cells. × 950.

different investigators. It would appear that one of the difficulties has been due to failure to standardize properly the physiological condition of the animal whose liver was studied. Many of the structural details of the hepatic cell which have been described as indicative of a more or less specific hepatic function depend on a technique for their demonstration which does not allow positive conclusions. Furthermore, the perplexing question of the significance of the mitochondrial changes is ever present.

The physiological conditions following which the cytology of the active and inactive hepatic cell has usually been studied have been those associated with the withdrawal of food and occasionally also water, for various periods and at different intervals subsequent to the ingestion of various kinds of foods. Several different species of animals have been employed by

investigators. Some of the most interesting observations have been made on the hibernating animal. It is readily seen that under the conditions of observation it has been impossible to study many phases of hepatic cell activity. I shall describe those commonly accepted changes which appear to occur most often.

Cytological study of the normal physiology of the hepatic cell falls somewhat definitely into three periods. The first period embraces the contributions of Kupffer (1875), Heidenhain (1880), Langley (1882), Ranvier (1885) and Lahousse (1887); the second period includes the major contributions of Altmann (1889, 1894), while the third period, following that of Altmann, includes the contributions of Ferrari (1897), Arnold (1901), Gilbert and Jomier (1907), Policard (1910), Fiessinger (1911) and Noël (1923).

The activity of the liver differs in the fasting and digesting states, both in character and degree. The least active appearing liver is observed in the hibernating animal. However, it should be recalled that a totally inactive liver is not compatible with life; at least some of the hepatic cells must be carrying on the vital functions allotted to them if the organism is to live. The liver of the fasting animal and that of an animal recently fed are different grossly. The liver, following a fast, is smaller than normal and lacks somewhat the characteristic color. If the fast has been a matter of a few days, in many species a characteristic fatty appearance develops. The liver of the digesting animal, while affected somewhat differently by the various foodstuffs, appears larger than the liver of the fasting animal; it has the characteristic dark red or a pale color, depending on the time after taking food, and is very friable.

While the cytology of the liver at various periods after withdrawal of food and after the ingestion of various foods has recently been discussed in detail by Noël (1923), it would appear to be of more value to confine ourselves to the more general and more accepted considerations, particularly as much of the more recent work awaits confirmation. In this connection it should be noted that much of the finer detail of the arrangement of the protoplasm of the hepatic cell of the animal which has fasted for only a short time may not be due to any specific change in the structure of the cell but rather to the decrease in the storage material which, as it accumulates in the cell following feeding, hides the more delicate structure.

The changes found in the hepatic cell following fasting depend on many factors, such as the length of time food has been withheld, the bodily activity and environment of the animal and somewhat on the species of animal. In general, the following change occurs in the hepatic cells following the withholding of food: the cells become smaller and appear contracted; the cell outlines become indistinct, and the cells merge together; the granules in the protoplasm become fine and homogeneous and are more eosinophilic in nature; the nuclei become more irregular, granular and

distinct, and the protoplasmic details of the hepatic cell appear to merge together. The fasting hepatic cell first loses its glycogen, although there is rarely complete loss of this substance; then apparently the protein structure of the cell diminishes with the appearance and accumulation of fat. A considerable amount of pigment becomes evident in the hepatic cell of the fasting animal. The amount of fat which is discernible by the usual histological methods in the liver of the fasting animal of some species is enormous.

The hepatic cell, during the active state associated with digestion, increases in size, and its outlines become distinct, the points of contact between cells being clearly visible. The intracellular changes occurring depend somewhat on the kind of food ingested and the character of the material deposited. Shortly after the taking of food the protoplasmic details become very distinct. In the deposition of the food material many of the minutiae of the cell structure become hidden or actually disappear. The nuclei become more indistinct and the nuclear granules change in character, becoming more uniform and possibly finer. The intercellular spaces become wider as the vascularity is increased and as the hepatic cell becomes more active. However, after the hepatic cells are filled with storage material, their increase in size may compress the vascular structures and produce the pale color frequently encountered some time after the ingestion of large amounts of food. The hepatic cell of the well-fed animal appears to contain very little pigment.

2. *The stellate cell (v. Kupffer):*

The second important cellular component of the liver, the stellate cell or cell of v. Kupffer, is usually considered as not belonging especially to the hepatic tissue but rather to the system of monophages. It would add little of value to discuss the histogenetic status of these cells or their relationship to similar cells elsewhere in the body, the reticulo-endothelial system, and so forth, especially as the monophages and monocytes are considered in Section XIV. It is essential, however, that the stellate cells be considered as an integral part of the liver and in relation to hepatic function. If the impression is given that these cells, as found in the liver, may not be wholly the same as supposedly similar cells found elsewhere, it may not be misleading.

General Characteristics. Since their first description these cells have received considerable attention. They have been found in many species of animals but appear to be absent in a few species. In some animals they are markedly more abundant than in others. These cells are now recognized as endothelial in nature; they incompletely line the branching capilliform sinusoids between the trabeculae of hepatic cells and are an integral constituent of the capillary wall. They are intimately associated with the hepatic lobules

and are not found in the extralobular tissue. Their distribution is fairly regular. As their name implies, they are star-shaped, since they are not grouped together but fit into interstices and bends of the irregular trabeculae and between small groups of hepatic cells with the cell body projecting into the sinusoid. The cell body is slightly longer than the usual hepatic cell and its shorter diameter is only equal to about half the length. Reticular filaments pass from the cell body over the surface of the trabeculae between the hepatic cells and form a fine network over the surface of the latter. In general, this group of cells forms an incomplete endothelial lining of the trabeculae and separates the hepatic cell from the cavity of the sinusoid.

Internal Organization. The internal organization of the cell varies greatly with its activity. It contains a large nucleus, oval in shape, which is usually situated near the middle of the cell body or slightly distant from the center toward either end. Occasionally there may be two nuclei. The appearance of the protoplasm depends on what the cell has ingested. In the inactive cell it is slightly granular or homogeneous.

Changes during Physiological Activity. The phagocytic capacity of the stellate cell to take up finely divided foreign bodies or certain dyes from the blood stream is truly enormous. They will become so filled with such material that they would appear to have no room for more. When they are thus engorged they present a very pretty picture, the best examples of which are those of v. Kupffer (1899). The stellate cells are not very fastidious in their tastes and will take up a very wide variety of substances. Their history subsequent to being filled with matter is not wholly clear. It would appear that they then become detached from the wall of the trabecula and pass to the capillaries of the lung where they are disintegrated. New cells form from those that remain around the sinusoids. The rate at which the cells leave the liver and are re-formed is supposed to be very rapid. If this course of events is correct it would apparently preclude wholly blocking this group of cells with dye, as has so often been attempted.

3. *The biliary channels:*

The third special cellular component of the liver, that making up the biliary channels, has to do with the drainage of the products of the exocrine function of the liver cell. This is accomplished by the aid of an extensive system of branching tubules and ducts which extend from the most remote portions of the hepatic lobule, where the external secretion is first extruded from the hepatic cell, to the site of discharge of bile into the duodenum. The purpose of this biliary system is not only to drain away a secretion containing certain excretory products but also to discharge into the intestine at the proper time certain constituents which are important for digestion. It is thus seen that this system must not only be adpated for drainage and storage of bile but must also be controlled by a mechanism by which the

discharge of bile and the activity of the liver in secreting bile can be correlated with the activity of the gastrointestinal tract. This correlation must not be for digestion in general but for the specific food substance, for the normal digestion of which the bile is essential. It is needless to add that much of this mechanism is still not understood.

The Intrahepatic Biliary System. The intrahepatic portion comprises a large number of interlobular bile ducts which course in the portal canals, and the extensively branched intralobular canaliculi which are in intimate contact with the hepatic cell. Observers differ in their conclusions concerning the manner in which the biliary canaliculi are related to the hepatic cell. These ducts are exceedingly fine, especially in the central portion of the lobule, and they are made visible only by the most careful technique. In general, biliary canaliculi course within the hepatic trabeculae from the center to the periphery of the lobule. In lower vertebrates in which the tubular organization of the liver obtains, the canaliculus lies in the axis of the tubule surrounded by five or six cells, while in man each passes through the center of a trabecula and is surrounded by two or rarely three cells in section. Occasionally intercellular branches arise from the canaliculi. These course between the cells, or, as frequently observed, they completely encircle hepatic cells and form true meshes around them. As previously stated, observers differ as to existence of intracellular biliary passages. It is true that with the Golgi method small branches have been seen to pass directly from the canaliculus through the cell membrane and terminate in small globules within the protoplasm near the nucleus. Since these structures are by no means constant, appearing only at the time of physiological activity, one may well question the existence of any intracellular mechanism of a duct nature. Each canaliculus, increasing in dimension toward the periphery of the lobule, is enclosed by a continuous cuticular structure, probably formed by the apposition of the membranes of the cells which form the trabecula. There is no definite evidence, however, that any such fusion has formed the canaliculus.

The larger intrahepatic biliary passages, which course in the portal canals within the capsule of Glisson, increase in size as they continue outward toward the hilus of the liver. The walls of these ducts comprise a fibrous layer, in which are scattered muscle fibers insufficient in number to form a definite sheath, and a lining epithelium. The fibrous layer, relatively thin, deep within the liver, becomes gradually thicker and is composed of numerous elastic fibers and connective tissue cells. A continuation of certain connective tissue elements along the canaliculus from the portal canal into the lobule has been described (Kölliker, 1867), but the extent of this development and the relationship to the hepatic cell are questionable. A definite epithelium is identified at the periphery of the lobule where the canaliculi continue into the bile channels of the portal canals.

The epithelium of these smaller ducts is of the pavement type, and there is a more or less abrupt transition in passing from the cuticular canaliculus to the epithelium of the duct. Gradually nearer the hilus of the liver the epithelium of these intrahepatic ducts becomes cuboidal; thence it is of the high columnar type characteristic of all the extrahepatic channels. Certain dilatations or pockets are observed scattered along the larger bile ducts both within and without the liver. These are called parietal sacculi, as named by their discoverer (Beale, 1856). They have been noted to increase in size after removal of the gall bladder and have been considered as possibly compensating for the loss of the viscus (Sweet, 1924). The parietal sacculi are not very numerous in several species of animals, which fact would appear to decrease their physiological importance.

The Extrahepatic Biliary System. The extrahepatic biliary system comprises the gall bladder with its cystic duct, the hepatic ducts and the common bile duct. There is an extraordinary variation in the relationship of these structures in different species and individuals. In many species the gall bladder is absent. These structures all show an organization similar to that of the duodenum from which they arose as a common diverticulum and are thus composed of three major parts, the mucous membrane or epithelium, the muscularis and the outer protective serosa. The cells of the epithelium are of the high cylindrical type. The epithelial cells of some larvae develop cilia which beat in a direction toward the gut. Ciliation disappears in the adult, however, except in Petromyzon where it persists throughout life. In frogs and toads the epithelium of the common duct remains ciliated throughout life and in many cases ciliation continues for a short distance on the cells lining the intestine. Ciliated epithelium occurs in the biliary channels of certain reptiles but there is no evidence that it occurs in either the avian or the mammalian groups. In dogs the epithelial cell of the hepatic duct is the highest of any of the mammals, being approximately five times as high as it is broad. Granules of mucin lie in the distal third of the cell and the surface of the cell is usually covered with a thin film of mucus, while the oval nuclei lie in the basal third with their longer axes at right angles to the height of the cell.

Goblet cells are often present in the extrahepatic biliary ducts. They are more abundant in ruminants than in man (Cohn, 1892), and in the latter they are far more numerous in the intestinal portion of the ductus choledochus. A cross section of an extrahepatic duct invariably presents a picture of greatly convoluted epithelium. The extent of these folds varies as to species. Among cattle the folds are very high, and frequently in the common duct secondary and tertiary ridges characterize the folded epithelium. In the hepatic and common ducts these ridges are longitudinal or diagonal, while in the cystic duct circular folds complicate the picture of the epithelial surface. Glands of both a mucous and serous function and

lined with a like columnar epithelium lie in the subepithelial membrana propria. In man these glands are small and pear-shaped, or they may be branched and tortuous, measuring 50 to 90μ in diameter. They open singly or in groups into the crypts between adjacent ridges of the epithelium. The fundus of the gland is usually embedded in the membrana propria and is largely surrounded by reticulate or elastic fibers with occasional smooth muscle bundles. These muscle bundles have been described as even reaching to the neck of the gland, but their entire distribution is altogether too scanty to regard them as forming any definite muscular layer (Böhm and Davidoff, 1898).

Sappey (1889) described fasciculi of smooth muscle fibers which are abundant in certain mammals but relatively rare in man. Hendrickson (1898) made an inclusive study on all portions of the extrahepatic biliary tract. Studies on dogs show that muscle fibers are more or less abundant in the cystic duct and that they course in longitudinal, transverse and diagonal directions. In the hepatic duct, on the other hand, only longitudinal fibers abound, while in the choledochus smooth muscle fibers course in all three directions, but are so infrequent as to form no continuous muscle layer. In the rabbit, muscle fibers are far less numerous and may only be detected by the celloidin section method; however, smooth muscle fibers in the longitudinal, transverse and diagonal directions are present in the cystic and the hepatic ducts, but the diagonal ones are absent from the common duct. In man certain characteristics of the rabbit and the dog abound. In the cystic duct the three-directional smooth muscle fibers are present and are more abundant nearer the neck of the gall bladder than more proximally. MacAlister (1867) recognized smooth muscle fibers in the Heisterian valves. Hendrickson (1898) showed that the circular muscles of the valves are formed by the transverse muscle bundles of the duct and that certain of the longitudinal muscle fibers bend at right angles to their usual course and enter the valves, but that the diagonal fibers bear no relation whatsoever to them. In both the hepatic and the common ducts of man only very small amounts of smooth muscle tissue are present, so that a definite muscularis, as such, may not be designated. A more abundant disposition of muscle fibers is restricted to the duodenal end of the common duct. Glisson (1681) noted a contraction of this structure but made no complete anatomical description, and it was reserved for Oddi (1887) to give an adequate description of the sphincteric mechanism that has since come to be known as the sphincter of Oddi, although it had been previously described by Gage. Certain of the rodent hepatic ducts, such as those of the rat, contain no smooth muscle bundles (Ranvier, 1885), although a sphincter-like structure is present at the duodenal end (Mann, 1920). In this animal the wall of the duct is formed by longitudinal bundles of connective tissue which interlace and form an extensive network of branching fibers.

The absence of the gall bladder, as in the rat, is probably of no consequence in this connection, as the horse, likewise without the vesicle, has well-organized muscle bundles reaching up even to the finest bile ducts. The sphincter at the end of the choledochus is an interesting structure both from the anatomical and physiological standpoint, but it is outside the scope of this chapter to discuss it.

The serous coat of the hepatic ducts, continuous with the serosa of adjacent organs, is composed of a large number of interlacing elastic fibers. The layer is rich in blood vessels, lymph channels and nerves.

The organization of the wall of the gall bladder is similar to that of the hepatic ducts and thus composed of three major tunics, the mucosa, muscularis and serosa. The mucosa, rather extensively convoluted, comprises an epithelial layer of simple cylindrical cells and a deeper tunica propria with its rather extensive vascular plexuses. The extent of convolution of the mucosa varies as to species. Among cattle, for example, the folds are high, and secondary or even tertiary ridges project from the major folds, so that the surface is marked by bays or grooves of varying sizes and depths. Frequently in some animals these ridges are so closely packed and extend in such varying directions that the entire picture of the mucosa is one of granulations, but a honeycomb appearance is the more usual one. The height of the folds and the width of the bays vary with the degree of pressure within the vesicle. In a fasting animal, with greater distention of the vesicle, these bays are slightly more pronounced, but even with an internal pressure of 325 mm. of mercury, much greater than the secretory pressure of the liver, the small folds are not obliterated (Boyden, 1925). In a completely contracted gall bladder the rugae are very close together and, being wider at their free ends, their intersections appear as tufted elevations which nearly fill the lumen of the vesicle. In the normal distended mucosa three zones may be differentiated in the cylindrical cell: first, an outer, narrow, lighter zone; then a middle, darker, more granular one, and then a lighter basal zone in which lies the oval nucleus. Fatty globules and other constituents absorbed from bile are found within the cell. Goblet cells are not infrequent, although some authors report their absence from the mucosa of the gall bladder. Scattered glands, composed of an epithelium similar to that of the vesicle, extend from the surface into the deeper tunica propria and muscularis layer. They vary in shape and in size, according to the individual. In man they are relatively rare and more or less restricted to the neck of the bladder, while in ruminants they are quite abundant. They are frequently branched, pursue tortuous courses and open singly or in groups on the epithelial surface. Von Rokitansky sinuses (1855) and Luschka ducts are diverticula of the mucosa of the gall bladder which extend down into the muscularis and perimuscularis layers (Aschoff, 1905). True Luschka ducts (1858), according to Halpert (1926), are structures having their own independent wall, which

do not communicate with the lumen of the vesicle. Luschka (1858) regarded them as metamorphosed remnants of the embryonic liver.

The muscular tunic of the gall bladder is not an extensive one and yet probably sufficiently functional to effect the expulsion of the contents. The predominating fibers are circular and these are more abundant at the neck than at the fundus of the vesicle. Longitudinal fibers course the length of the bladder and curve over the fundus, and yet do not form a distinct stratum, but occur rather in isolated bundles. Elastic tissue abounds within the muscle tunic and the whole is invested with abundant connective tissue. Boyden (1925) has shown that in the cat the muscularis is made up of from eight to ten superimposed circular fibers, and that in the guinea pig there is an increase in thickness of the muscle layer from 0.04 to 0.4 mm. during contraction. Chiray and Pavel (1925) have shown the muscularis in guinea pigs to be composed of two layers; one is attached to the serosa and formed of transverse fibers which diverge from one another, while the other layer is nearer the tunica propria and courses more in the longitudinal direction. Oval meshes are thus formed. In the dog there are four or five layers of muscle fibers separated from each other by strands of connective tissue. On the basis of the arrangement of the smooth muscle fibers, Chiray and Pavel would affirm two kinds of contraction, one large and very slow, the other small, frequent and rhythmic. Potter and Mann (1926) had obtained evidence of such contraction by studying the pressure changes in the biliary tract.

The serosa of the gall bladder is usually very thick. Aschoff (1905) differentiates a fibrosa, just external to the muscularis, a subserosa containing blood vessels and lymph channels and an external serosa. Elastic fibers are abundant. Lymphatic nodules occur in the deeper layers as well as in other layers of the wall of the gall bladder. The lymphatics of the gall bladder are well developed and anastomose freely with those of the liver (Sudler, 1901).

A review of the data bearing on the possible function of the gall bladder has recently been made (Mann, 1924), so it is only necessary here to emphasize the more important facts and add the more recent developments. It need no longer be debated that the gall bladder is a very active structure and of definite physiological significance. The most important evidence concerning hepatic function is: (1) when the gall bladder is removed the extrahepatic biliary tract usually dilates (Judd and Mann, 1917); (2) the gall bladder is capable of greatly concentrating the bile which enters it (Rous, Peyton and McMaster, 1921), and (3) the presence of the gall bladder prevents the development of jaundice for many hours after obstruction of the common bile duct (Mann and Bollman, 1925). These facts can only be explained on the basis that the gall bladder actually accomplishes something in the organism.

The cause of the dilatation of the extrahepatic biliary tract after removal of the gall bladder depends for the most part on structures outside the liver, that is, the sphincter at the end of the choledochus. As might be inferred from its structure, the gall bladder possesses great ability to concentrate the bile which reaches it. The bile in the gall bladder may be concentrated to about ten times that of the bile coming directly from the liver. This is probably mainly accomplished by absorption of water from the bile by the mucosa of the gall bladder. This mechanism for concentrating the bile makes it possible for the gall bladder to store all the solid constituents of the bile secreted by the liver during several hours. The moot question whether or not the gall bladder ever emptied was definitely settled by Boyden (1925). He found that the gall bladder of a cat fed on a mixture of egg yolk and cream became empty within about four hours after ingestion. Various hypotheses have been presented with regard to the mechanism of how the gall bladder empties. Certain investigators hold that changes in intraabdominal pressure, particularly in relation to respiration, are the essential factors (Winkelstein and Aschner, 1926). However, by employing the method of Boyden for emptying the gall bladder, Higgins and Mann (1926) were able to observe the emptying directly. They found that the gall bladder emptied by a slow contraction of its muscularis, forcing the contained bile into the duodenum. Hamrick (1926) obtained similar results by observing the changes in shape and size of the exposed gall bladder following a meal of egg yolk and cream. The evidence clearly indicates that certain constituents of the bile are stored in the gall bladder and discharged under the stimulus of a specific food substance. The discrepancy between the small capacity of the gall bladder and the amount of bile secreted is compensated for by the extraordinary ability of the gall bladder to concentrate its contents. The discharge of bile into the duodenum is due to the contraction of the muscles of the viscus.

V. CYTOLOGICAL CHANGES ASSOCIATED WITH KNOWN FUNCTIONS OF THE LIVER

While the liver has many functions, those which are definitely known and which may be associated with demonstrable cytological changes are few. It may be of value, however, to discuss these definitely proved functions of the organ in relation to the cytology and to note those instances in which the cell structures may be significant.

1. *The secretion of bile:*

The secretion of bile is probably the best known, although not the most important function of the liver. While the number of definitely proved facts concerning the secretion of bile is large, the cytological aspect of the

process can be briefly told. The variation in the activity of the liver as regards the secretion of bile is considered to be indicated by the variation in number and character of the mitochondria. This conception of the mitochondria as an indication of the secretory activity of the liver differs in no way from their postulated importance in glandular activity as a whole and has been sufficiently considered elsewhere.

The bile has many constituents, but at present three appear more important than the others. These are bile salts, cholesterol and bilirubin. Very little is known about the bile salts, either as regards their origin or site of production. At present the best evidence would seem to indicate that they are made in the liver (Smyth and Whipple, 1924). In this connection the acidophilic granules described by Forsgren (1918) would appear of some significance. He found that certain bile capillaries were filled with a hyaline, markedly acidophilic material and that the cells adjacent to these capillaries contained acidophilic granules. Such granules were only found in the cells near the periphery of the lobule. He thought that this acidophilic material was indicative of the bile acids. However, it should be noted that, even if his surmise were correct, it would not necessarily mean that the bile acids were made in the liver but might simply indicate the site where they were excreted from the lobule.

Our knowledge of the relation of cholesterol to the liver is very deficient, although apparently no more so than with regard to the rôle of this substance in the organism as a whole. At present no positive statements can be made with reference to the cytology of the liver in relation to cholesterol metabolism.

The bile pigment is the constituent of the bile which has been the subject of the most investigation and discussion of any of the substances excreted by the liver. Numerous researches were carried out and contradictory conclusions drawn concerning this pigment and particularly the relation of the hepatic cell to its formation. The path by which bilirubin was supposed to be absorbed, whether through the lymphatics or blood vessels, following obstruction to the biliary outflow, has also been the subject of much controversy. The cytological evidence with regard to any of these conceptions of the part the hepatic cell and lobule played in the formation and reabsorption of bile pigment has never been satisfactory. The reason for this becomes very evident since the presentation of definite proof that most of the bilirubin made in the body is formed outside the liver and that the hepatic cell probably has only an excretory function in regard to this pigment (Mann, Sheard and Bollman, 1926). It should be noted that the path by which the hepatic cell normally excretes bilirubin has not been demonstrated.

It is usually possible to find a pigment in some hepatic cells of almost every normal liver. In all probability this pigment is usually hemoglobin,

although there are several other pigments which could be taken up by the hepatic cell. The liver readily takes up hemoglobin, and its presence in the hepatic cell has been demonstrated (Browicz, 1898; Policard, 1910). A considerable amount of iron is also found in the liver, but the stellate cells take up this material much more readily than the hepatic cells.

2. *Carbohydrate metabolism:*

In order for the metabolism of the body to be maintained with a wide range of intensity of physiological activity, it is necessary that there be a foodstuff capable of providing considerable energy, which can be supplied to the organism in constantly varying amounts, while an adequate supply is still maintained at the site of utilization. This is accomplished by the metabolism of glucose and the activity of the liver in maintaining the blood sugar level. The liver thus has a vital function in relation to carbohydrate metabolism. This function is to maintain, within rather narrow limits, under varying conditions of carbohydrate intake and utilization, a constant concentration of glucose in the blood (Mann and Magath, 1922). In order to do this it has the ability to transform the glucose and some other sugars into a form in which they can be stored in the hepatic cell and re-transformed into glucose when needed and also the power to make glucose from certain amino acids. The cytological method has been valuable in determining some of the facts concerning glycogenesis and glycogenolysis in the liver.

Ever since the discovery of glycogen numerous attempts have been made by cytologists to determine the history of this substance in the hepatic cell. It is now known that some of the earlier observations dealt with material other than glycogen. It is considered that the deposition of glycogen is accompanied by a change in the character of the protoplasm of the hepatic cell, but there is no demonstrable relation between such glycogen deposition and changes in the mitochondria (Arnold, 1898; Bang and Sjövall, 1916; Noël, 1923). A complete statement of the sequence of events in the hepatic cell associated with the transformation of glucose into glycogen, the storage of glycogen and its later change back into glucose is not now possible. The evidence in regard to the distribution of glycogen in the lobes of the liver is conflicting (Petersen, 1904; Grube, 1905; Rosenberg, 1910; Dowler and Mottram, 1918). Cytologically the picture is variable, probably because of failure of the different observers to obtain the same physiological condition of the animal. As would be anticipated from the function of the liver in maintaining the blood sugar level under the wide variation of bodily activity, the cytological picture of the liver relative to glycogen is an ever-changing one. These changes depend on such factors as character of the food, time after taking food and activity of the animal. The earlier observations appeared to show that glycogen was deposited more or

less uniformly throughout the hepatic lobule (Afanassiew, 1883). More recent observations show that when glycogen is being formed in increasing amounts in the liver, it appears first and in more abundance in the cells adjacent to the central vein (Noël, 1923). The other cells of the lobule gradually accumulate a store of glycogen, those around the periphery of the lobule being the last to obtain their store. While the glycogen becomes rather evenly distributed throughout the cells of the hepatic lobule following the ingestion of sufficient carbohydrate, those around the central vein usually have the largest amount. In general, the withdrawal of glycogen takes place in a reverse order from the course of its deposition; the cells around the central vein appear to retain the glycogen longest. The site of the glycogen masses in the hepatic cell and their distribution are not uniform. They are situated slightly away from the periphery of the cell. Glycogen granules are not often found in the nuclei of normal hepatic cells. A small amount of glycogen deposited extracellularly in the liver has been noted (Arndt, 1924).

3. *Protein metabolism:*

The liver has a very important relation to protein metabolism. Its major activities in this respect are deaminization and formation of urea and the destruction of uric acid (Bollman, Mann and Magath, 1924 to 1926). However, no cytological changes have been observed which appear to be of significance with regard to these functions. It is known that following the injection of amino acids, a considerable amount of these substances can be recovered from the liver (Folin and Denis, 1912; Van Slyke and Meyer, 1913 to 1914). Large quantities of albumin have also been obtained from the liver after a meal of protein. Certain cytological changes have been observed following the taking of protein food (Arapow, 1901; Berg, 1920; Noël, 1923). In general, these changes appear more indicative of a storage phenomenon than of a profound metabolic activity and may possibly be the cytological aspect of the deposit protein which has most recently been studied by Boothby, Sandiford, Sandiford and Slosse, (1925). Noël (1923) describes some star-shaped granules to which he ascribes a function in relation to protein metabolism. The elaboration of this structure is associated with mitochondrial activity.

4. *Fat metabolism:*

There is no definite proof that the liver has an important rôle in the metabolism of fat, although there is much suggestive evidence that the utilization of this important foodstuff also depends somewhat on the liver. The most important data suggesting such a function of the liver have been obtained by the cytological method. Many and varied bodily conditions greatly change the character and amount of fat in the liver, but such changes

are more often noted in a variety of pathological states. It is thus difficult to determine whether a given finding concerning the amount and character of the fat in the liver is due to physiological activity or to a pathological condition.

The demonstration of the fat globules in the liver began with the work of Kölliker (1857). The fat in the liver has been classified on the basis of its distribution and character. However, no classification has been found wholly satisfactory. In general, it is probably true that the fat which appears in the hepatic cell in the form of globules or oil drops is of physiological significance and that which appears in the form of granules is indicative of a pathological state of the hepatic cell (McCrae and Klotz, 1910). The globules appear in the hepatic cells following the ingestion of an excess of fats as well as after fasting and other more or less physiological conditions. Noël (1923) believes that the formation of the fat globules depends on the mitochondria. The distribution of the fat-containing cells in the lobule is quite variable. The fat globules may first appear in the cells at the periphery of the lobule but usually they have a very diffuse distribution. The fat granules usually appear in the cells around the central vein. Sometimes the amount of fat contained in the liver is enormous. I have observed specimens of the liver of a hibernating spermophile (*Spermophilus citellus*) in which every cell in the lobule was so completely distended with fat that it presented a so-called signet-ring appearance. It would seem hardly possible that such a liver could be capable of normal physiological activity, yet a short time after the hibernating animals awaken and take food, the liver presents a normal appearance. There is evidence, however, that the fatty liver which is associated with certain toxic conditions is greatly injured and possibly an important factor in the cause of death (LeCount and Singer, 1926). The demonstrable fat in the liver varies inversely with the glycogen content in both physiological conditions and pathological states. The reason for this inverse relationship is not known.

5. Detoxicating action:

One of the most important functions ascribed to the liver is that of acting as a detoxicating agent toward a large number of toxic substances which gain access to the body. It is highly probable that this function has been over-emphasized, although there is definite evidence that the liver is of great importance in eliminating foreign substances from the blood stream. This subject has recently been reviewed by Gunn (1923) and by Opie (1925). Most of the experiments purporting to prove that the liver is of great significance in destroying alkaloids and other soluble toxic substances are inconclusive because of a faulty method of experimentation. The method usually consisted in comparing the effect of the substance when injected into a systemic vein and when injected into the portal vein. It

can readily be seen that in the former case, with the substance entering the general circulation directly, there is the possibility of a more general reaction being produced than in the latter in which the injected substance passes through a set of capillaries before entering the general circulation. When the experiments are properly controlled by injecting the toxic substance into an artery, such as the femoral artery, instead of a vein, the leg appears to be as good a detoxicating agent as the liver (Koessler and Hanke, 1925). However, the liver does have the ability, either directly or indirectly, to diminish the action of soluble toxic substances. Certain substances produce a much more marked reaction in an animal with greatly reduced hepatic tissue than in the normal animal (Mann and Bollman, 1926). The only cytological evidence of a detoxicating action of the liver on soluble toxic substances is provided by the characteristic lesions which follow the administration of certain poisons, such as chloroform and phosphorus. However, it is quite possible that the action of such substances in the liver does not differ, so far as the functional significance of their action is concerned, from the specific effect of other substances on other organs, as the more or less specific production of nephritis by a variety of poisons.

The liver is a most important agent in removing particulate and colloid material from the blood stream. The experiments of Drinker and his associates (1921, 1923) proved this important phase of hepatic activity very conclusively. They injected small particles of manganese dioxide and found that 90 per cent of the injected material could be recovered in the liver, lungs and spleen, and that the largest amount was found in the liver. The liver also has the same importance and predominance in removing many different kinds of bacteria from the blood stream (Opie, 1925; Manwaring and Fritschen, 1923). The liver is also of great significance in the formation of opsonins (Manwaring and Coe, 1916), in anaphylaxis, destruction of foreign protein (Manwaring and Crowe, 1917) and other similar phenomena. It should be noted that in most, if not all, of these activities of the liver, the stellate cells are the important physiological agent. This predominance of the action of the liver in removing foreign material from the blood suggests the possibility that the stellate cell may act somewhat differently from apparently similar cells in other organs.

6. *The circulation tissue:*

The liver in embryonic life is one of the sites of the formation of red blood cells. Throughout life it bears a close relation to the circulatory tissue. Certain constituents of the blood appear to depend directly or indirectly on the action of the liver. The coagulation of the blood is affected by the action of the liver, although how this is brought about is not definitely determined. The fibrinogen content of the blood appears to bear some relation to the liver because, in conditions in which the liver is profoundly

affected, as after the administration of chloroform and other hepatic poisons, the fibrinogen content of the blood appears to parallel the condition of the liver (Foster and Whipple, 1921; Schultz, Nicholes and Schaefer, 1925). Furthermore, regeneration of fibrinogen seems to depend on the presence of the liver (Meek, 1912). It should again be emphasized that the stellate cells are important factors in iron metabolism. Lampson (1920) has shown that under acute conditions the liver is capable of adding a large number of red cells to the circulation. It is also quite probable that the liver is an important factor in maintaining the fluid volume of the blood.

VI. SPECIALIZATION OF FUNCTION OF THE CELLS IN THE HEPATIC LOBULE

One of the most interesting problems of the liver is concerned with the question of whether each hepatic cell can, and at the same time does, perform all the manifold functions of the organ or whether there is a division of functions among the units of the hepatic lobule. There are some considerations which would suggest that there is a division of functions among the hepatic cells. An anatomical consideration is the fact that the structure of the lobule, with the blood all entering at the periphery (one source being arterial and the other venous), and all leaving at the center, and with the duct draining away the external secretion of the liver leaving at the periphery, would make it possible for the hepatic cells to be subjected to different conditions as regards ease of excreting bile, amount of oxygen reaching the various cells and the reaction of the circulating blood. As previously noted, there is a cytological difference in the hepatic cells under various physiological and pathological conditions, depending on their distribution in the lobule.

The evidence seems to indicate that a certain group or zone of cells in the lobule may enter into a certain physiological activity to a greater extent than other cells in the lobule and that both the character and amount of activity of the hepatic cell is determined somewhat by its relative position in the hepatic lobule. Such evidence depends on the studies of the liver of the fasting and fed animal, of which those of Noël (1923) have been the most extensive and detailed. However, it would also appear that each hepatic cell has the ability to perform all the functions of the liver. The evidence for this view depends on the observations made on the activity of the various hepatic poisons on the hepatic lobule. It is possible to destroy all the cells in the lobule except a few around the periphery without greatly disturbing the known functions of the liver (Williamson and Mann, 1923).

It would appear that the change in activity of the liver is brought about in the same manner as has been shown to occur in the capillary (Krogh, 1924) and kidney (Richards and Schmidt, 1924). Not all cells in a lobule

and not all lobules are in the same degree of activity. The same may also be true for lobes (Dowler and Mottram, 1918).

Variations in the activity of the liver which are so necessary for many of its functions are probably brought about mainly by varying the relative number of active and inactive cells and lobules rather than a general increase in activity of all the cells.

VII. REGENERATION

One of the most striking and important characteristics of the liver is its capacity for regeneration. The rate and degree of hepatic regeneration after injury by poison or disease or following removal is truly astonishing in view of the fact that the hepatic cell is so markedly differentiated. Complete recovery following severe damage to the hepatic parenchyma by chloroform will take place within a few days (Whipple and Sperry, 1909). Within forty-eight hours after the surgical removal of 70 per cent of a dog's liver, the remaining portion will have returned to within 75 per cent of its original weight, and within a few weeks to the preoperative condition, both by weight and volume (Ponfick, 1895). The stimulus for this great regeneration, as well as the exact mechanism, is not known. This ability of the liver to regenerate after removal depends for the most part on an intact portal circulation (Mann and Magath, 1922). If the portal blood has been diverted some time previous to partial removal of the liver, regeneration either does not occur or occurs only to a relatively slight degee. Immediately after the removal of a large amount of hepatic tissue, the remaining portion appears to take up a large amount of fluid. The cells also hypertrophy. The small number of cells found undergoing mitotic cell division at the time of an undoubted great increase in size of the liver strongly suggests that amitotic cell division occurs; this is still debated. The vexed question of whether the hepatic cell regenerates from a duct cell, hepatic cell or an intermediate cell has also not been settled.

VIII. CYTOLOGICAL CHANGES IN THE MORE REPRESENTATIVE PATHOLOGICAL PROCESSES IN THE LIVER WHICH MAY BE OF PHYSIOLOGICAL SIGNIFICANCE

While the liver is often the seat of disease similar to that found in other organs and while the reaction of the hepatic tissue to these diseases is in general likewise similar, many of the lesions of the liver are more or less specific and bear some relation (although at present not understood) o the anatomy and physiology of the organ.

In the majority of acute lesions of the liver, the first cytological evidence of hepatic injury is noted in the cells around and adjacent to the central vein. This lesion, which starts at the center of the lobule and extends toward

the periphery, is termed central necrosis. It is the hepatic lesion which is produced by most of the more or less specific hepatic poisons as chloroform, and hydrazine, as well as by spontaneous disease of the organ. The primary involvement of the cells around the periphery of the lobule, peripheral necrosis, is a much rarer lesion than central necrosis. Peripheral necrosis has been described in eclampsia and phosphorus poisoning, although central necrosis is produced by the latter substances.

No adequate explanation for the development of these specific lesions has so far been made, although many hypotheses have been suggested (Whipple and Sperry, 1909). However, it would appear that the vascular arrangement, whereby the periphery of the lobule receives the blood first, might be an important factor. Another consideration which may be pertinent in this regard is the fact, as has been previously noted, that there is a variation in the activity of the hepatic cell depending on the relative position in the hepatic lobule. The variation may also be important with reference to the action of toxins, either on the basis that they excrete the substances or because their state or activity makes them more vulnerable to the action of the poisons.

IX. HEPATIC EXTRACTS

While at present there is no cytological evidence or chemical proof of any specific physiological principle in the liver, which functions in a manner similar to the action of the active principle of glands of internal secretion, many attempts have been made at isolation of such a substance from hepatic tissue. These attempts have so far been unsuccessful and the extracts have contained many substances, some of which were very toxic. However, two of these extracts have appeared to be of sufficient importance to warrant their being used clinically.

Howell and Holt (1918), while working on the coagulation of the blood, isolated a substance from the liver which they called heparin. While found most abundantly in the liver, the substance could be isolated from other tissues. Heparin is described as a water-soluble phosphatide. Its chemical composition is fairly constant as regards nitrogen and phosphorus. It is effective in retarding or preventing the coagulation of the blood and causes the formation of a notable amount of antithrombin. It has been used clinically to prevent the coagulation of the blood.

Several investigators have obtained a substance in extracts from the hepatic tissue which acts as a depressor of blood pressure. In most instances such substances have been considered as one of the more common depressor substances, such as histamine, choline, or peptone which are found in extracts of many of the tissues of the body. However, at approximately the same time three different groups of investigators obtained an extract from the liver which contained a depressor substance which did not appear to be the same as those previously obtained. James and Laughton (1925) obtained a depressor substance from the liver which would greatly reduce blood pressure for a long time. This substance had a markedly antipressor action in reducing hypertension caused by certain depressor

drugs (James, Laughton and MacCallum, 1925). This substance appears not to be one of the common depressor substances. Macdonald (1925) used an extract of the liver in treating some cases of hypertension and obtained a marked and fairly long-continued decrease in the blood pressure. However, toxic manifestations of the extract were frequent and severe. Major (1925) also used hepatic extract in cases of hypertension and noted improvement in some cases. Major, Stoland and Buikstra (1926) studied the effect of liver extract in cases of hypertension produced by guanidine compounds and found that the extract was effective in lowering the blood pressure. They concluded that the active depressor substance was not choline, histamine or peptone.

The evidence would indicate that a more or less specific antipressor substance has been isolated from the liver, which is apparently not one of the more common depressor substances. This antipressor principle appears to have decreased blood pressure in a few cases of hypertension to a remarkable degree, but has been without effect in the majority of instances.

It should be noted that in view of our present knowledge of the function of the liver there are no good reasons to suppose that a specific physiological antipressor substance should be elaborated in this organ. The hypothesis that the liver destroys such substances as guanidine, and that these are responsible for the hypertension, is based on two as yet unproved assumptions. Be that as it may, it is still possible that an active antipressor substance may be obtained from hepatic tissue.

X. BIBLIOGRAPHY

Afanassiew, H. 1883. Ueber anatomische Veränderungen der Leber während verschiedener Thätigkeitzustände. *Arch. f. d. ges. Physiol.*, **30**, 385.

Altmann, Richard. 1889. Die Structur des Zellkernes. *Arch. f. Anat. u. Entw.*, 409.

——— 1894. *Die Elementarorganismen und ihre Beziehungen zu den Zellen.* Ed. 2, Leipzig: Veit and Company.

Arapow, A. B. 1901. Contribution à l'étude des cellules hépatiques binucléaires. *Arch. d. Sc. biol.*, **8**, 184.

Arndt, H.-J. 1924. Vergleichend-histologische Beiträge zur Kenntnis des Leberglykogens. *Virchow's Archiv*, **253**, 254.

Arnold, J. 1898. Ueber Structur und Architectur der Zellen. *Arch. f. mikr. Anat.*, **52**, 134.

——— 1901. Zur Kenntnis der Granula der Leberzellen. *Anat. Anz.*, **20**, 226.

——— 1908. Haben die Leberzellen Membranen und Binnennetze? *Ibid.*, **23**, 257.

Aschoff, Ludwig. 1905. Bemerkungen zur pathologischen Anatomie der Cholelithiasis und Cholecystitis. *Verhandl. d. deutsch. path. Gesellsch.*, **9**, 41.

Bang, Ivar, and Sjövall, Einar. 1916. Studien über Chondriosomen unter normalen und pathologischen Bedingungen. *Beitr. z. path. Anat. u. z. allg. Path.*, **62**, 1.

Baum, H. 1922. Ueber die Einmündung von Lymphgefässen in der Leber in das Pfortadersystem. *Verhandl. d. anat. Gesellsch.*, **31**, 97.

Beale, L. S. 1856. *On some points in the anatomy of the liver of man and vertebrate animals.* London: J. Churchill. 80 pp.

Berg, W. 1920. Ueber funktionelle Leberzellstrukturen. I. *Arch. f. mikr. Anat.*, **94**, 518.

Böhm, A. A., and Davidoff, M. v. 1898. *Lehrbuch der Histologie des Menschen.* Ed. 2, Wiesbaden.

Bollman, J. L., Mann, F. C., and Magath, T. B. 1924–26. Studies on the physiology of the liver. VIII. Effect of total removal of the liver on the formation of urea; X. Uric acid following total removal of the liver; XV. Effect of total removal of the liver on deaminization. *Am. J. Physiol.*, **69**, 371; **72**, 629; 1926, **78**, 258.

Boothby, W. M., Sandiford, Irene, Sandiford, Kathleen, and Slosse, J. 1925. The effect of thyroxin on the respiratory and nitrogenous metabolism of normal and myxedematous subjects. I. A method of studying the reserve or deposit protein with a preliminary report of the results obtained. *Tr. Assn. Am. Phys.*, **40**, 195.

Boyden, E. A. 1925. The effect of natural foods on the distention of the gall bladder, with a note on the change in pattern of the mucosa as it passes from distention to collapse. *Anat. Record*, **30**, 333.

Brissaud and Sabourin. 1888. Sur la constitution lobulaire du foie et les voies de la circulation sanguine intra-hépatique. *Compt. rend. Soc. de biol.*, s. 8, **5**, 757.

Browicz, T. 1897. Ueber den Bau der Leberzelle. (Abst.) *Bull internat. Acad. d. sc. de Cracovie*, 186.

——— 1898. Das mikroskopische Bild der Leberzelle nach intervenöser Hämoglobininjection. *Ibid.*, 357.

Chiray, M., and Pavel, I. 1925. La contractilité de la vésicule biliare. *J. de physiol. et de path. gén.*, **23**, 318.

Cohn, T. 1892. *Histologisches und Physiologisches über die grossen Gallenwege und die Leber.* Breslau.

Disse, J. 1890. Ueber die Lymphbahnen der Säugethierleber. *Arch. f. mikr. Anat.*, **36**, 203.

Dowler, V. B., and Mottram, V. H. 1918–19. The distribution of blood, glycogen and fat in the lobes of the liver. *J. Physiol.*, **52**, 166.

Drinker, C. K., and Shaw, L. A. 1921. Quantitative distribution of particulate material (manganese dioxide) administered intravenously to the cat. *J. Exper. Med.*, **33**, 77.

Drinker, C. K., Shaw, L. A., and Drinker, Katherine R. 1923. The deposition and subsequent course of particulate material (manganese dioxide and manganese metasilicate) administered intravenously to cats and to rabbits. *J. Exper. Med.*, **37**, 828.

Ferrari, T. 1897. Contributo allo studio della fisio-patologica della cellula epatica. *Riv. veneta de sc. med.*, **26**, 195.

Fiessinger, Noël. 1911. *La cellule hépatique particulièrement chez des mammifères et chez l'homme.* Paris: Masson et Cie. P. 385.

Flemming, Walther. 1882. *Zellsubstanz, Kern- und Zelltheilung.* Leipzig: F. C. W. Vogel. 424 pp.

Folin, Otto, and Denis, W. 1912. Protein metabolism from the standpoint of blood and tissue analysis. First and third papers. *J. Biol. Chem.*, **11**, 87; **12**, 141.

Forsgren, E. 1918. Zur Kenntnis der Histologie der Leberzellen und der Gallensekretion. *Anat. Anz.*, **51**, 309.

Foster, D. P., and Whipple, G. H. 1921. Blood fibrin studies. IV. Fibrin values influenced in cell injury, inflammation, intoxication, liver injury and the Eck fistula. *Am. J. Physiol.*, **58**, 407.

Gilbert, A., and Jomier, J. 1907. Structure de la cellule hépatique aux divers temps de la digestion et dans les divers regimes. *Bull. et mém. Soc. anat. de Par.*, **82**, 313.

Gilbert, A., and Villaret, M. 1909. Contribution à l'étude de la circulation du lobule hépatique; la vascularisation artérielle du parenchyme lobulaire. *Compt. rend. Soc. de biol.*, **67**, 521.

Glisson, Frances. 1681. *Anatomia hepatis.* Hagae: A. Leers. 552 pp.

Grube, K. 1905. Ueber die Verteilung des Glykogens in der Leber. *Arch. f. d. ges. Physiol.*, 483.

Gunn, J. A. 1923. Cellular immunity: congenital and acquired tolerance to nonprotein substances. *Physiol. Rev.*, **3**, 41.

Halpert, Béla. 1926. A note on the "true Luschka duct" and the "Rokitansky-Aschoff sinuses" of the human gallbladder. (Abst.) *Anat. Record*, **32**, 232.

Hamrick, R. A. 1926. Thesis. (Unpublished.)

Heidenhain, R. 1880. Physiologie der Absonderungsvorgänge. In *Handb. d. Physiol.*, von L. Herrmann.

Hendrickson, W. F. 1898. A study of the musculature of the entire extra-hepatic biliary system, including that of the duodenal portion of the common bile-duct and of the sphincter. *Bull. Johns Hopkins Hosp.*, **9**, 221.

Hering, E. 1871–72. Von der Leber. In Stricker, Salomon, *Handbuch der Lehre von den Geweben des Menschen und der Thiere.* Leipzig: W. Engelmann. P. 429.

Herring, P. T., and Simpson, S. 1906. On the relation of the liver cells to the blood-vessels and lymphatics. *Proc. Roy. Soc. London*, Series B, **68**, 455.

Higgins, G. M., and Mann, F. C. 1926. Observations on the emptying of the gall-bladder. *Am. J. Physiol.* (In press.)

Holmgren, E. 1901. Einige Worte über das Trophospongimus verschiedenen Zell-arten. *Anat. Anz.*, **20**, 438.

Howell, W. H., and Holt, Emmett. 1918–19. Two new factors in blood coagulation in heparin and pro-antithrombin. *Am. Jour. Physiol.*, **47**, 328.

James, A. A., and Laughton, N. B. 1925. The control of blood pressure with liver extracts. *Can. Med. Assn. J.*, **15**, 701.

James, A. A., Laughton, N. B., and MacCallum, A. B. 1925–26. Studies on the control of blood pressure with hepatic extract. *Am. J. Physiol.*, **75**, 392.

Judd, E. S., and Mann, F. C. 1917. The effect of removal of the gallbladder—an experimental study. *Surg., Gynec. and Obst.*, **24**, 437.

Kiernan, F. 1833. The anatomy and physiology of the liver. *Phil. Tr. Roy. Soc. London*, **173**, 711.

Kölliker, A. v. 1857. Einige Bemerkungen über die Resorption des Fettes im Darme, über das Vorkommen einer physiologischen Fettleber bei jungen Säugethieren und über die Funktion der Milz. *Verhandl. d. phys. u. med. Ges. zu. Urnz.* **7**, 174.

——— 1867. *Handbuch der Gewebelehre des Menschen.* Ed. 5, Leipzig: W. Engelmann. 730 pp.

Koessler and Hanke. 1925. Cited by Wells, H. G.: *Chemical pathology.* Ed. 5, Philadelphia; W. B. Saunders Company. P. 681.

Krogh, August. 1924. *The anatomy and physiology of capillaries.* New Haven: Yale Univ. Press. 276 pp.

Kupffer, C. v. 1873. Ueber gewisse Strukturverhältnisse der Saügetierleber. *Versamml. deutsch. Naturf. u. Ärt. zu Wiesbaden*, **46**, 169.

——— 1875. Ueber Differenzierung des Protoplasm an den Zellen tierischer Gewebe. *Schrift. d. naturw. Vereins f. Schleswig-Holstein*, **3**, 229.

——— 1876. Ueber Sternzellen der Leber. *Arch. f. mikr. Anat.*, **12**, 353.

——— 1899. Ueber die sogenannten Sternzellen der Säugethierleber. *Ibid.*, **54**, 254.

Lahousse, E. 1887. Contribution à l'étude des modifications morphologiques de la cellule hépatique pendant la sécrétion. *Arch. de biol.*, **7**, 167.

Lampson, P. D. 1920–21. The part played by the liver in the regulation of blood volume and red corpuscle. *J. Pharm. and Exper. Therap.*, **16**, 125.

Langley, J. N. 1882. Preliminary account of the structure of the cells of the liver, and the changes which take place in them under various conditions. *Proc. Roy. Soc. London*, **34**, 20.

LeCount, E. R., and Singer, H. A. 1926. Fat replacement of the glycogen in the liver as a cause of death. *Arch. Pathol. and Lab. Med.*, **1**, 84.

Lee, F. C. 1925. On the lymph vessels of the liver. *Contrib. to Embryol., Carnegie Institute*, **74**, 15, 63.

Lund, C. C., Shaw, L. A., and Drinker, C. K. 1921. Quantitative distribution of particulate material (manganese dioxide) administered intravenously to the dog, rabbit, guinea pig, rat, chicken, and turtle. *J. Exper. Med.*, **33**, 231.

Luschka, H. 1858. Die Drüsen der Gallenblase des Menschen. *Ztschr. f. rat. Med.*, 4, 189.

MacAlister, A. 1867. Contributions to the comparative anatomy and physiology of the gall bladder. *Med. Press and Circ.*, 4, 129, 150.

McCrae, John, and Klotz, Oskar. 1910. The distribution of fat in the liver. *J. Exper. Med.*, 12, 746.

Macdonald, W. J. 1925. Extractives of liver possessing blood pressure reducing properties. *Can. Med. Assn. J.*, 15, 697.

Mac-Gillavry, T. H. Zur Anatomie der Leber. *Sitzungsb. d. k. Akad. d. Wissensch.*, 1, 207.

Major, R. H. 1925. Effects of hepatic extract on high blood pressure. *J. Am. Med. Assn.*, 85, 251.

Major, R. H., Stoland, O. O., and Buikstra, C. R. 1926. Observations on the effects of liver and extracts in hypertension produced by guanidine compounds. *Bull. Johns Hopkins Hosp.*, 38, 112.

Mall, F. P. 1906. A study of the structural unit of the liver. *Am. J. Anat.*, 5, 227.

Mann, F. C. 1920. A comparative study of the anatomy of the sphincter at the duodenal end of the common bile-duct, with special reference to species of animals without a gallbladder. *Anat. Record*, 18, 355.

——— 1924. The functions of the gallbladder. *Physiol. Rev.*, 4, 251.

Mann, F. C., and Bollmann, J. L. 1925. The relation of the gallbladder to the development of jaundice following obstruction of the common bile duct. *J. Lab. and Clin. Med.*, 10, 540.

——— 1926. Liver function tests. *Arch. Pathol. and Lab. Med.*, 1, 681.

Mann, F. C., and Magath, T. B. 1922*a*. The effect of removal of the liver on the blood sugar level. *Arch. Int. Med.*, 30, 73.

— — 1922*b*. The production of chronic liver insufficiency. *Am. J. Physiol.*, 59, 485.

Mann, F. C., Sheard, Charles, and Bollman, J. L. 1926. An evaluation of the relative amounts of bilirubin formed in the liver, spleen and bone marrow. *Am. J. Physiol.*, 78, 384.

Manwaring, W. H., and Coe, H. C. 1916. Endothelial opsonins. *J. Immunol.*, 1, 401.

Manwaring, W. H., and Crowe, H. E. 1917*a*. The rôle of hepatic tissues in acute anaphylactic shock. *J. Am. Med. Assn.*, 69, 772.

——— 1917*b*. Rôle of hepatic tissues in actue anaphylactic reaction. *J. Immunol.*, 2, 517.

Manwaring, W. H., and Fritschen, William. 1923. Study of microbic-tissue affinity by perfusion methods. *J. Immunol.*, 8, 83.

Meek, W. J. 1912. Relation of the liver to the fibrinogen content of the blood. *Am. J. Physiol.*, 161.

Noël, R. 1923. Recherches histo-physiologiques sur la cellule hépatique des mammifères. *Arch. d. anat. micro.*, 19, 1.

Oddi, R. 1887. D'une disposition à sphincter spéciale de l'ouverture du canal cholédoque. *Arch. ital. de biol.*, 8, 317.

——— 1888. Sulla tonicita dello sfintere del coledoco. *Arch. per le sc. med.*, 12, 333.

Opie, E. L. 1925. Pathologic physiology of liver in relation to intoxication and infection. *J. Am. Med. Assn.*, 85, 1533.

Oppel, Albert. 1891. Ueber Gitterfasern der menschlichen Leber und Milz. *Anat. Anz.*, 6, 165.

Petersen, O. V. C. E. 1904. Ueber die Lagerung des Glykogens in den Leberzellen beim Kaninchen. *Anat. Anz.*, 25, 72.

Pflüger, E. 1869. Ueber die Abhängigkeit der Leber von dem Nervensystem. *Arch. f. d. ges Physiol.*, 2, 459.

Policard, A. 1910. La structure de la cellule hépatique en fonctionnement normal chez le chien. *Compt. rend. Soc. de biol.*, **68**, 37.

Ponfick, E. 1895. Experimentelle Beiträge zur Pathologie der Leber. *Arch. f. path. Anat.*, (Suppl.), **138**, 81.

Potter, J. C., and Mann, F. C. 1926. Pressure changes in the biliary tract. *Am. J. Med. Sc.*, **71**, 202.

Prenant, A. 1910. Les mitochondries et l'ergastroplasme. *J. de l'anat. et de la physiol.*, **46**, 217.

Ranvier, L. 1885. Les membranes muqueuses et le système glandulaire. *J. de microg.*, **9**, 7, 55.

Richards, A. N., and Schmidt, C. F. 1924–25. A description of the glomerular circulation in the frog's kidney and observations concerning the action of adrenalin and various other substances upon it. *Am. J. Physiol.*, **71**, 178.

v. Rokitansky, Carl. Cited by Halpert.

Rosenberg, Oskar. 1910. Histologische Untersuchungen über das Leberglykogen. *Beitr. z. path. Anat. u. z. allg. Path.*, **49**, 284.

Rous, Peyton and McMaster, P. D. 1921. The concentrating activity of the gall bladder. *J. Exper. Med.*, **34**, 47.

Sappey, Marie P. C. 1889. *Traité d'anatomie descriptive.* Paris: V-A. Delahaye and Company. **3**, 273.

Schafer, E. A. 1901. On the existence within the liver of channels which can be directly injected from the blood vessels. *Proc. Roy. Soc. Edinburgh*, **24**, 65.

Schultz, E. W., Nicholes, J. K., and Schaefer, J. H. 1925. Studies on blood fibrin; its quantitative determination; normal fibrin values, and factors which influence quantity of blood fibrin. *Am. J. Path.*, **1**, 101.

Smyth, F. S., and Whipple, G. H. 1924. Bile salt metabolism. I. Influence of chloroform and phosphorus on bile fistula dogs. *J. Biol. Chem.*, **59**, 623.

Sterling, Stefan. 1911. Beiträge zur Histologie der Leber bei Säugern. *Arch. f. Entw.*, 57.

Sudler, M. T. 1901. The architecture of the gall-bladder. *Bull. Johns Hopkins Hosp.*, **12**, 126.

Sweet, J. E. 1924. The gall-bladder: its past, present and future. *Internat. Clin.*, s. 34, **1**, 187.

Van Slyke, D. D., and Meyer, G. M. 1913–14. The fate of protein digestion products in the body. Studies III, IV, and V. *J. Biol. Chem.*, **16**, 197.

Wepfer, J. J. 1664. *De dubiis anatomicis.* Epistola ad J. H. Paulum, Norimb.

Whipple, G. H., and Sperry, J. A. 1909. Chloroform poisoning. Liver necrosis and repair. *Bull. Johns Hopkins Hosp.*, **30**, 278.

Williamson, C. S., and Mann, F. C. 1923. Studies on the physiology of the liver. V. The hepatic factor in chloroform and phosphorus poisoning. *Am. J. Physiol.*, **65**, 267.

Winkelstein, A., and Aschner, P. W. 1926. Mechanism of the flow of bile from the liver into the intestines. *Am. J. Med. Sc.*, **171**, 104.

Section IX
CYTOLOGY OF THE PANCREAS

CONTENTS

Section IX

PAGE

I. Pancreatic Acinous Cell . . . 241
1. Zymogen granules . . . 241
2. Chromodial substance . . . 243
3. Mitochondria . . . 244
4. Golgi apparatus . . . 244
5. Fat globules . . . 245
6. Nucleus . . . 246
II. Cells of Islands of Langerhans . . . 246
1. Specific granules . . . 246
2. Mitochondria . . . 249
3. Golgi apparatus . . . 250
4. Fat globules . . . 250
III. Centroacinous Cells and Epithelium of Ducts . . . 251
IV. Histogenesis . . . 253
V. Relation of Acini to Islands of Langerhans . . . 254
1. Identification of islet tissue . . . 254
2. Enumeration of islands of Langerhans . . . 255
3. Attempts to transform acini into islets, etc. . . . 256
VI. Reaction of Cells to Injury . . . 257
1. Inanition . . . 258
2. Phosphorous poisoning . . . 258
3. Fatty degeneration . . . 258
4. Focal necrosis . . . 259
5. Hydropic degeneration . . . 259
6. Hyaline degeneration . . . 259
VII. Regeneration . . . 260
VIII. Changes Following Ligation of Pancreatic Ducts . . . 261
IX. Islands of Langerhans and Carbohydrate Metabolism . . . 263
X. Bibliography . . . 268

Section IX

CYTOLOGY OF THE PANCREAS

EUGENE L. OPIE

THE secreting acini of the pancreas communicating freely with the ducts of the gland, and the islands of Langerhans, which have no outlet by way of the ducts, furnish opportunity to compare side by side the minute structure of two tissues of which the functions differ widely. Out of this relation has arisen a variety of problems which for solution demand the aid of cytological methods. The pancreas has been the tissue preferred by histologists who have attempted to correlate glandular secretion with intracellular change and those who believe that the islands of Langerhans are endocrine organs find in the pancreas the opportunity to compare the cytological basis of internal and external secretion. Unfortunately there is as yet no unanimity among histologists concerning the relation of islands of Langerhans to secreting acini and, although the view has steadily lost adherents, some still maintain that secreting acini may be transformed into islands of Langerhans, and conversely, the islets into acini. Evidence concerning the function of the pancreatic islets was first obtained by study of the pancreas of those who had died with diabetes mellitus on the one hand and of pancreatic lesions unassociated with glycosuria on the other. It is obviously desirable that, in spite of heretofore almost insuperable difficulties, the relation of these lesions to known intracellular structures be determined accurately in man as well as in animals used for experiment. Changes following duct ligation have had an important part in the struggle to determine the relation of the islands of Langerhans to carbohydrate metabolism and it is now clearly recognized that these changes must be defined in terms of cell structure. Furthermore, the discovery of insulin has fostered the hope that its elaboration within cells of the pancreas may be correlated with structural changes.

I. THE PANCREATIC ACINOUS CELL

1. Zymogen granules:

The pancreatic cell, it is well known, has an inner zone containing round refractive zymogen granules (described by Claude Bernard in 1856) and a basal zone which contains the nucleus. The latter, when unstained, is homogeneous save for longitudinal striations which are seen only with high magnification. In hardened tissue the zymogen granules stain deeply with acid dyes, whereas the cytoplasm of the basal zone stains with hema-

toxylin and other basic stains. The longitudinal striations in the basal zone are mitochondrial filaments (Figs. 96 and 97).

Brief references may be made to the studies of Heidenhain (1875) who first defined the morphological changes accompanying secretion. During a period from six to ten hours after a full meal given to a dog kept without food during twenty-four hours, coincident with discharge of pancreatic secretion, the zymogen granules decrease in number until they occupy only the inner tip of the cell and the cell diminishes in size. During the period from ten to twelve hours after taking of food, granules accumulate within the

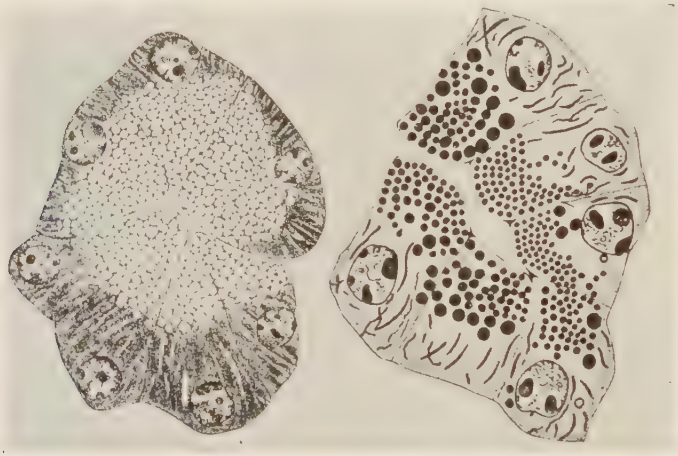

FIG. 96. FIG. 97.

FIG. 96.—Pancreatic acinus of a guinea pig in which the cytoplasm of the cells has been stained with toluidine blue to show the chromidial substance of the outer zone. The unstained spaces in the inner zone represent zymogen granules and the unstained striations in the outer zone, mitochondria. (From Cowdry, 1924, after Bensley, 1911.)

FIG. 97.—Section of the same tissue stained with acid fuchsin and methyl green to show zymogen granules and mitochondria which are unstained in Figure 96. (From Cowdry, 1924, after Bensley, 1911.)

apical zone and the cell increases in size. When animals are fed at short intervals, part of the gland will be in one stage of secretion and part consisting of groups of acini will be in another. A clear zone surrounding the zymogen granule has been described (Tsukaguchi and Takagi, 1921). It is said to be present during the period of secretion, to increase as the granule it surrounds decreases and to persist after complete disappearance of the granule. Saguchi (1920), on the contrary, finds that the zymogen granules are nearly uniform in size and although he, agreeing with many other observers, thinks that the zymogen granules liquefy within the cytoplasm before they are discharged, attributes no significance to the formation of vacuoles.

Changes in the cells caused by stimulation with acid introduced into the duodenum have been compared by Babkin, Rubaschkin and Ssawitsch (1909) with changes caused by stimulation of the vagus or of the sympathetic nerve. With acid stimulation there is abundant secretion poor in protein and enzymes. Within the pancreatic cells the zymogen granules diminish slowly and the contents of the ducts have the microchemical characters of zymogen although they contain no granules. With stimulation of one or other nerve, pancreatic juice is rich in protein and enzymes. Zymogen granules disappear very rapidly from the pancreatic cells and large droplets of secretion like that within the ducts but with staining characters different from the zymogen granules appear within the cytoplasm of the cells.

The secretory activity of the pancreatic cell has been in turn correlated with changes in the various intracellular structures which from time to time have engaged the attention of histologists (see Cowdry, "General Cytology," Sect. VI). Some claim to have found evidence that zymogen granules are formed directly from the nucleus (Galeotti), or from the so-called paranucleus (Ogata; Mouret). Altmann has claimed that the filaments, which are often designated by his name, break into particles which form zymogen, and with more recent interest in mitochondria there has been repeated but unfruitful effort to bring these structures into evident association with secretion. R. Heidenhain has found that the basophilic zone decreases as zymogen granules accumulate, and many have subsequently attempted to show that chromidial substance is transformed into zymogen. Finally evidence has been found that the Golgi apparatus or intracellular network is intimately concerned in the formation or discharge of products of secretion. In each instance one group of observers has maintained the correlation of a structural change with the function of secretion, while another group has denied it.

2. Chromidial substance:

No striation is demonstrable in the basal part of the pancreatic cell after fixation by osmic or by chromic acid but with fixing fluids containing acetic acid fibrillary structures are found. Beside the nucleus they run chiefly in a vertical direction, whereas below the nucleus their course is generally horizontal, vertical and horizontal fibrils being often continuous. These fibrils are very fine and with alum hematoxylin take the color of chromatin but are apparently not identical with chromatin, for with other dyes they fail to reproduce the color reactions of the nuclear network (Saguchi, 1920). Garnier (1900) has named them "formations ergastoplasmiques basales" and the term ergastoplasm has been widely used. Matthews (1899), Garnier and others have supported the view that these filaments may be continuous with the nuclear chromatin and receive from it material which is transformed into zymogen granules. The basal substance Bensley (1911) finds is homogeneous and forms filaments only when precipitated by the action of acid. The possibility that the filaments are preformed structures rendered visible by acid, as Saguchi believes, cannot be denied.

3. *Mitochondria:*

By appropriate methods of fixation and staining, mitochondria appear as rods or filaments which are straight, curved or undulatory. Swellings occur in places upon the filaments (Figs. 98 and 99) and may have a bleb-like character because the central part is unstained. The filaments neither ramify nor anastomose. They are more abundant about the nucleus than elsewhere. On either side of the nucleus their course is parallel to the long axis of the cell but below it their general direction is horizontal. When zymogen granules are scant, mitochondria have an irregular course above the nucleus but when they are closely packed mitochondria are seldom

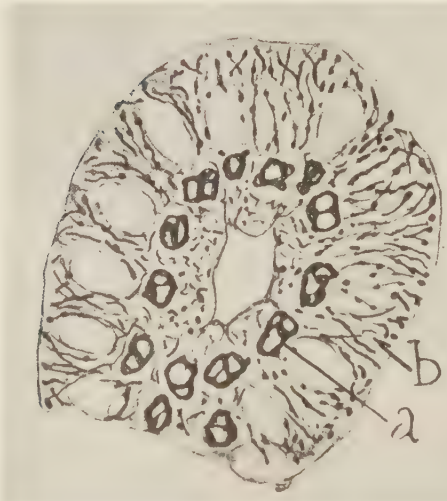

Fig. 98.

Fig. 99.

Fig. 98.—Mitochondria and Golgi apparatus in cells of pancreatic acinus: a, Golgi apparatus; b, mitochondria. (After Cajal, 1914.)

Fig. 99.—Mitochondria and Golgi apparatus of acinous cell of pancreas under high magnification: a, Golgi apparatus; b, mitochondria filament; c, bulbous swelling of filament. (After Cajal, 1914.)

found within the granular zone (Saguchi, 1920). During the stage of secretion induced in the toad Key (1916), by secretine or by pilocarpine, found no diminution of mitochondria and no change in the structure of the filaments or of their bleb-like swellings.

4. *Golgi apparatus:*

An intracellular network (Figs. 98, 99, 100), similar to that discovered by Golgi in nerve cells, was first found in cells of the pancreas by Negri and is demonstrable by silver impregnation or is blackened by prolonged treat-

ment with osmic acid. It cannot be seen in the living cell and has not been stained by vital dyes. Staining with iron hematoxylin after hardening in Flemming's solution has disclosed a network apparently identical with that found by impregnation with silver (Holmgren, 1904). Cowdry (1923; see "General Cytology," Fig. 30, p. 342) has bleached preparations of the Golgi apparatus and has found by staining with iron hematoxylin that clear canals take the place of the blackened network.

The intracellular network lies between the nucleus and the lumen but nearer the former and occupies an area of irregular outline, which varies much in extent. It consists of thick or thin cords which ramify and anastomose. Holmgren (1904) and Cajal (1914), studying the pancreatic cells of the cat, have found that the intercellular network penetrates the zone

FIG. 100.—Golgi apparatus in normal secreting cells of the pancreas. (After Cajal, 1914.)

occupied by zymogen granules but Bergen (1904) has denied this relation. Nassonov (1923) has found in amphibia that zymogen granules in the resting cells first appear within the meshes of the network and believes that the Golgi apparatus has a part in the elaboration of pancreatic secretion. Holmgren, and Saguchi (1920) find that the intracellular network is continuous with the intercellular canals and some have thought that it is concerned with discharge of secretion; but Bensley (1911) and Nassonov (1923) could not confirm this observation. It is noteworthy that an intracellular network is present within the epithelial cells of the pancreatic ducts but is much smaller and less complex than that of the secreting cells (Nassonov).

5. *Fat globules:*

Fat, demonstrable by osmic acid as gray granules, is normally present in the pancreatic cell but assumes a black color when the tissue is fixed in a solution containing a reducing agent such as formalin or pyrogallic acid (Saguchi, 1920). These fat granules stain with fat stains such as Sudan III and scarlet red. Almost all cells contain fat granules limited to the area between the nucleus and the basal surface of the cell. Their number varies greatly and one or more heaps of granules may occur in contact with the basal

surface. Laguesse (1900) states that fat disappears during active secretion but reappears during the resting stage. After administration of pilocarpine Mislawsky (1913) and Maximow (1916) found fat granules in large numbers.

6. *Nucleus:*

The nucleus of the pancreatic cell contains a chromatin network formed by fine threads and nodules. The chromatin granules are in contact with the inner surface of the nuclear membrane, which is formed by a thin layer of chromatin. Within the meshes of the chromatin network are found one or more usually several spherical bodies, which stain with acid dyes such as eosin or acid fuchsin. These have been called "plasmosomes" (Ogata) and "nucleoli" (Mouret). Chromatin granules are closely applied to the surface of this nucleolus, and, fused together, form a shell about it (Ogata, Arnold, 1912; Saguchi, 1920).

Cells with two nuclei occur and Dolley (1925) has found that fully one-half of the pancreatic cells of the white rat have double nuclei, but in man and in the dog this condition is only occasionally found. Mitotic figures are seldom if ever observed in the normal adult pancreas. Ukai (1926*d*) found mitoses to be of rather frequent occurrence in the acinous cells of newborn rabbits, but in fully grown animals none was detected.

The name "nebenkern" or "paranucleus" has been given to structures situated within the cytoplasm and staining like nuclear material. They were first described by Nussbaum and by Gaule in 1881. Some of them are irregular in shape, being filamentous, spindle-shaped, creseentric or comma-like, and it is claimed they are derived from the nucleus or from the chromidial substance of the cytoplasm (ergastoplasm). Other chromatin-like bodies designated "nebenkerne" are spherical and have an even contour Saguchi (1920) has seen them within vacuoles and thinks that they are fragments of nuclei from degenerate cells taken into the cytoplasm of normal glandular cells. Dolley has suggested that some of these structures may be formed by degeneration of one of the two nuclei often present in pancreatic cells.

II. CELLS OF ISLANDS OF LANGERHANS

1. *Specific granules:*

The cells of the islands of Langerhans contain characteristic granules which are distinguishable from the zymogen granules of the secreting cells. Granules which stain brilliantly with safranine or with gentian violet have been found by Laguesse (1901) in the islands of Langerhans of the viper. They are closely crowded together throughout the cytoplasm and are visible in fresh cells examined in serum. Similar granules occur in the islet cells of mammals. An important advance in the study of the specific granules of the islands of Langerhans has been made by Lane (190-). In the pancreas of the guinea pig hardened in a variety of fixing agents he has determined the presence of two types of granules, one fixed by alcohol

(50 to 70 per cent), nitric acid (10 per cent) and formol, the other fixed by a solution of potassium bichromate and mercuric chloride. In both instances the granules assume a violet color when treated with gentian violet and are readily distinguishable from zymogen granules. They are not demonstrable in tissue fixed by picric acid (saturated) or by chromic acid (1 per cent), both of which are excellent fixatives for zymogen granules of the pancreatic cells.

The islands of Langerhans (Figs. 101 and 102) contain two types of cells:

A-cells have granules precipitated by alcohol, are relatively large and have a large elliptical or spherical nucleus with scant chromatin contents.

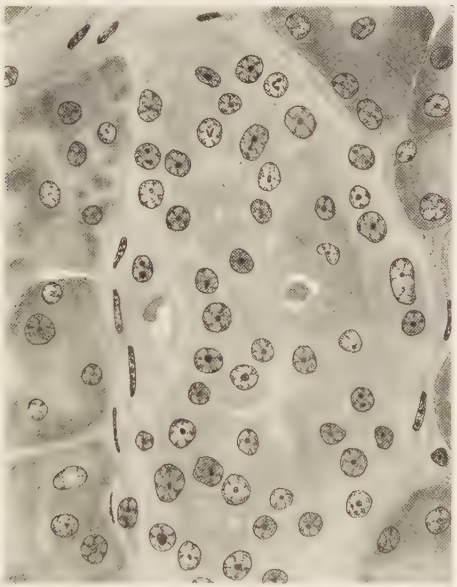

FIG. 101.—Islands of Langerhans from human pancreas stained with hematoxylin and eosin and showing apparent uniformity of cells. (After Cowdry, 1922.)

In some cells the granules are packed together throughout the cytoplasm, but in others they form a mass close to the adjacent capillary. These cells usually occur in sharply defined groups in the center of the islet, sometimes excentrically placed and seldom near the edges.

B-cells, which contain granules precipitated by aqueous chrome-sublimate, are smaller and much more numerous (Fig. 103). There are entire cords of them interrupted by groups of A-cells. Their cytoplasm is packed throughout with granules. The nucleus is small, placed centrally and contains a large amount of chromatin. When by the method introduced by Bensley (1911) granules of both types of cells are stained in the same specimen, it is evident that there are some islet cells with no granules. Their

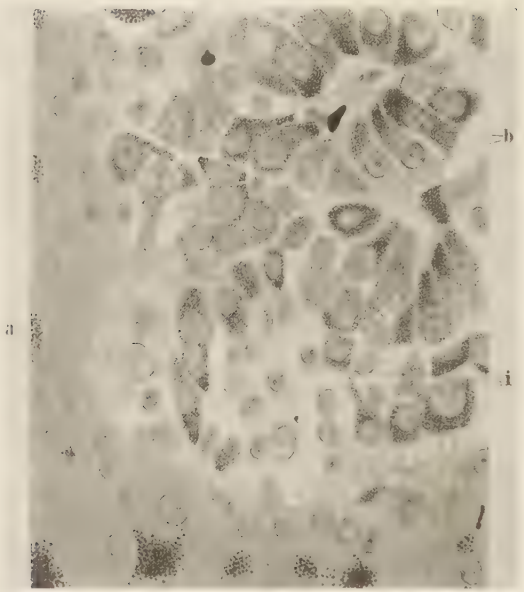

FIG. 102.—Islands of Langerhans fixed in chrome sublimate mixture and stained with the neutral gentian method of Bensley, showing the polymorphism of the cells: a, A-cells; b, B-cells, and i, indifferent cells. (After Cowdry, 1922.)

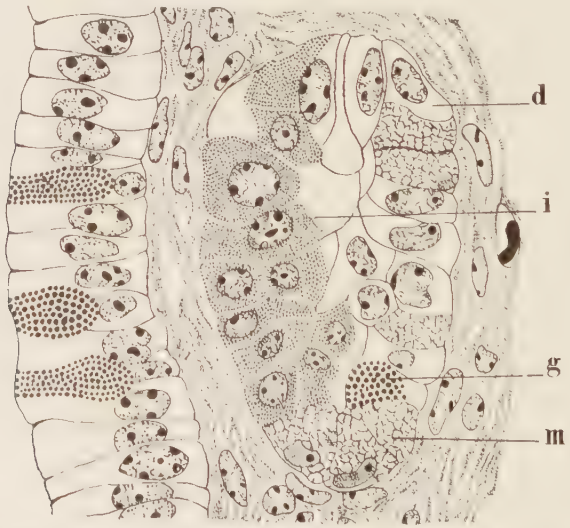

FIG. 103. Section of gland near its origin from the duct, showing several types of epithelial cells, acetic osmic bichromate fixation and safranin acid violet staining: i, islet cells; m, mucous cells; g, goblet cell; d, undifferentiated epithelium. (After Bensley, 1911.)

nuclei resemble those of A-cells and the occurrence of cells with a few granules otherwise identical with those of A-cells suggest that A-cells arise by differentiation from these clear cells.

By identification of specific granules, Bensley has found that the islet cells may be sharply distinguished from the secreting cells so that neither in the normal pancreas nor in the pancreas exhausted by stimulation with secretine, has he observed cells which cannot on the basis of positive characters be at once recognized as acinous cells, islet cells or duct cells. Centro-acinous cells resemble those of intralobular ducts. Those investigators who have found transitions from acinous cells to islet cells, formed they think by loss of zymogen granules and chromidial substance, have, he states, failed to use means which would identify the specific granules of B-cells.

Bensley regards as pathological the fine granules which Mankowski (1902) has stained with safranin in the acinous cells of guinea pigs. These granules, which Bensley has found particularly abundant in the pancreas of guinea pigs kept for some time on a diet containing no green food, appear in the outer part of the cell. Their appearance is simultaneous with the disappearance of both chromidial substance and mitochondrial filaments. Finally zymogen disappears and the granules fill the entire cell, but they are not islet granules, for they are larger and more highly refractive and are insoluble in reagents which dissolve the islet granules.

In a painstaking study of the islands of Langerhans, published almost ten years after that of Bensley, Saguchi (1920) has found two types of cells with characteristic granules, a considerable number of cells in which no granules are demonstrable and numerous intermediate forms. Acinous cells are transformed, he thinks, into islet cells, the most conspicuous features of the transformation being disappearance of zymogen granules, alteration of mitochondria and of the Golgi apparatus, characteristic of the former, and the formation of specific granules typical of the latter. He has apparently made little use of the methods introduced by Lane and Bensley and bases his conclusions upon cells interpreted as transitional and upon the immediate contact of the two types of cells.

Two distinct kinds of cells have been found in the pancreas of guinea pigs, rabbits and cats by Ukai (1926*a*) who has fixed tissue with Zenker's fluid and stained it with acid fuchsin and aniline blue by the method of Mallory, with Weigert's iron hematoxylin and with eosin-methylene blue. A-cells contain granules which stain with fuchsin and with eosin, whereas the smaller B-cells are basophilic and stain blue. These cells correspond with those described by Lane. He has found no transitions between cells of the islands of Langerhans and acinous cells.

2. *Mitochondria:*

Mitochondria have been observed in the islet cells by Bensley (1911), v. Herwerden (1912) and many others. They occur as delicate filaments and

small granules (Fig. 104A) and the long coarse filaments of the acinous cells are entirely lacking. Saguchi (1920) has found no mitochondria in cells containing specific granules and has expressed the opinion that these granules represent mitochondria. Ukai (1926*a*) on the contrary has discovered that A-cells contain fine mitochondrial granules of uniform size varying in quantity in different cells whereas B-cells contain somewhat larger granules at times rod-like, at times punctiform, distributed more sparsely within the cytoplasm.

FIG. 104.—A, Mitochondria; and B, Golgi apparatus in the cells of the islands of Langerhans of the rabbit. (After Cajal, 1914.)

3. *Golgi apparatus:*

An intracellular network (Fig. 104B) demonstrable by silver impregnation has been found in islet cells (Holmgren, 1904). Bensley (1911, 1915) has stated that it is recognizable in both fresh and fixed tissue. Saguchi, studying the tissues of the frog, has claimed that filaments and granules demonstrable by the uranic nitrate-silver method of Cajal do not form a definite network and are not revealed by all of the methods which identify the network of the acinous cells. Nevertheless Saguchi finds a structure comparable to the Golgi network in islet cells, although the anastomosing filaments are irregularly disposed within the cell and in many cells are entirely absent.

4. *Fat globules:*

Lipoid globules, demonstrable by osmic acid and by fat stains, are often found in the cells of the islands of Langerhans. Examining the pancreas of a human fetus 20 cm. in length Stangl (1901) has detected fat droplets in the

islets, but none elsewhere. In older fetuses and in newborn infants he has found fat particles in the islets and a few small droplets in the outer zone of the acinous cells. As age increases, visible fat increases in the islets and is demonstrable in the absence of pathological lesions in the secreting cells, centroacinous cells and in the epithelium of the ducts. On the contrary, Symmers (1909) has maintained that visible fat in the islets is pathological and in most instances referable to the use of alcohol. His suggestion that the fat found by Stangl in the pancreas of infants is referable to the maternal use of alcohol is at least questionable.

FIG. 105.—Section of an acinus of the pancreas of a guinea pig, showing the centroacinous cells with contained mitochondria. (After Bensley, 1911.)

III. THE CENTROACINOUS CELLS AND THE EPITHELIUM OF THE DUCTS

Within the acini, and in contact with the apices of the secreting cells are the centroacinous cells (Fig. 105) first described by Langerhans. They are fusiform, often flat and in some instances have short projections which penetrate between the secreting cells. The nucleus differs from that of the acinous cells, being smaller, oval and rich in chromatin. These cells resemble those of the terminal ducts, with which they appear to be continuous, as though the duct projects into the lumen of the acinus. Both centroacinous

cells and cells of intralobular ducts have an optically homogeneous cytoplasm in which Bensley (1911) has found irregularly scattered mitochondrial rods and granules. They contain no specific granules and no chromidial substance. In the cells of the small ducts Nassonov (1923) has found an intracellular network demonstrable by impregnation methods, which is of very simple structure and is much less conspicuous than that of the secreting cells.

Certain methods devised by Bensley (1911) are adapted to determine the relation of the islets to the small ducts of the gland. Pyronin introduced

Fig. 106.—Duct with branches showing the highly branched tubules connecting the duct with an islet. (After Bensley, 1911.)

into the aorta stains the duct cells more readily than those of the islets and acridine red is equally effective. By means of these stains every duct cell and every centroacinous cell in the pancreas may be colored. This method is in many respects more satisfactory than duct injection or the impregnation of the products of secretion contained in the ducts with silver. By methylene blue or pyronin injected into the aorta (Bensley, 1911) a system of fine anastomosing tubules can be found about the pancreatic duct (Fig. 106). They join the larger duct and its chief tributaries and branch freely in the connective tissue surrounding them. In preparations stained with neutral red, it is evident that this intricate web of tubules is in contin-

uity with islands of Langerhans, which vary in size from the smallest to the largest found in the pancreas. Furthermore, among the flat cells, which form the tubules, are found single cells having the character of islet cells.

By vital staining it may be shown that: (1) islets occur in the interstitial tissue about the duct and its primary branches, with which they are connected by the network of tubules just described; (2) islets are present within pancreatic lobules and are connected with interlobular ducts by longer or shorter branches; (3) islets situated within pancreatic lobules are connected with intralobular ducts; (4) islets in the interstitial tissue, or within lobules, are unconnected with ducts, having presumably lost this connection. Bensley, who has described the foregoing relations, states in agreement with Laguesse (1910) that the islands of Langerhans may be in continuity with acini, but he does not define the mode of union.

IV. HISTOGENESIS

Embryological studies demonstrate very clearly the epithelial origin of the islands of Langerhans and set at rest some of the older views concerning their nature. The common origin of the secreting acini and of the islands of Langerhans (Fig. 107) from primitive outgrowths of the duodenum has been clearly proved by studies of Laguesse (1895, 1910), Pearce (1903), Kuster (1904) and others. In embryo sheep two months old tortuous anastomosing tubules are formed by a single layer of epithelial cells (Laguesse). Here and there occur cells which stain more deeply with safranine than those about them and like the border cells of the stomach are situated upon the outer surface of the tubule. These cells proliferate to form solid outgrowths upon the tubule and give origin to the islands of Langerhans. Within the cells which mark the site of formation of islets are granules which stain with eosin, acid fuchsin or safranine.

In the human embryo about the third month islands of Langerhans are connected with lumen-containing structures by solid stalk-like processes which at this period begin to atrophy (Pearce, 1903); but in stillborn infants islets may be found in continuity with ducts (Weichselbaum and Kyrle, 1909).

At what period of development the specific granules of the islet cells make their appearance is not definitely known. In the large isolated islands of Langerhans of a human fetus 31 cm. long, Weichselbaum and Kyrle have found brightly stained cells in the center and smaller dark cells at the periphery. In the islets of newborn rabbits Ukai (1926*a*) has observed that basophile cells (B-cells) predominate, whereas fuchsinophile cells (A-cells) are present in small number at the periphery of the islets. New formation of islands of Langerhans from ducts does not cease (Weichselbaum and Kyrle) during fetal life, for these structures in the adult organ may be found continuous with ducts of which cells are undergoing mitosis.

V. THE RELATION OF ACINI TO ISLANDS OF LANGERHANS

1. *Identification of islet tissue:*

The granules found in islet cells on the one hand and in acinous cells on the other, in the opinion of those who have used the methods employed by Lane (1907), serve to identify the two structures. Bensley (1911) has recognized the desirability of combining in one method the several procedures of Lane and, with this purpose in view, has used differential staining instead of differential fixation. A suitable fixing fluid contains osmic acid, bichromate of potassium and a very small quantity of acetic acid. By the application of aniline-acid-fuchsin and methyl green, the granules of the A-cells are stained red and those of the B-cells, lilac. Bensley has found that preparations of this kind demonstrate the absence of true transitions between acini and islets and are suitable for the study of those procedures, for example, secretory exhaustion, inanition, etc., which it is claimed transform acini into islet tissue. Furthermore, they may be employed to deter-

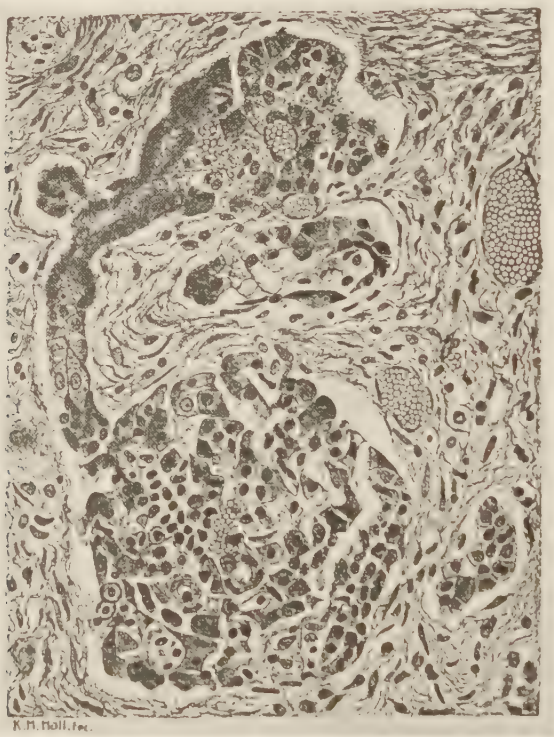

FIG. 107.—Shows continuity of an islands of Langerhans and of an acinus with small ducts in a syphilitic fetus of seven months. (After Pearce, 1904.)

mine whether the acini of the adult pancreas are under usual conditions transformed into islets, as some histologists still maintain.

2. *Enumeration of the islands of Langerhans:*

Those who have claimed that various procedures transform acinous tissue into islet tissue have found evidence that the islet tissue has undergone rapid increase during the course of their experiments. The attempt has been made to confirm or disprove these views by counting the islands of

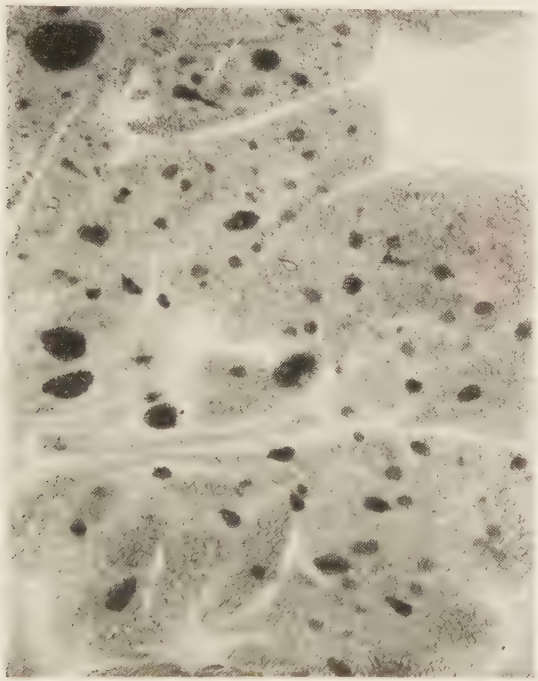

FIG. 108.—Islands of Langerhans of the guinea pig stained by neutral red injected into the blood vessels, showing variations in the islets and the general appearance of material used for their enumeration. (After Bensley, 1911.)

Langerhans (Opie, 1900; Heiberg, 1906; Cecil, 1912) and by the estimation of the total area of islet tissue in sections (De Witt, 1906). The figures obtained are by no means negligible and serve to demonstrate, for example, the great abundance of islet tissue in the tail of the gland, but the extent of the tissue examined in relation to the whole organ is small and the results of the enumeration are often widely divergent. Bensley has sought for a method by which all of the islets in the pancreas of a small animal such as the guinea pig may be counted directly. Vital staining by means of Janus

green injected in solution of 1 in 15,000 into the aorta gives a blue color to the pancreas. With air excluded the tissue reduces the dye to a safranine which is red and the change proceeds so much more rapidly in the acinous tissue than in the islets that soon they are the only structures which remain blue. The preparation may be made permanent by injecting ammonium molybdate by way of the duct and now every islet in the entire organ is blue, whereas the remaining tissue is red. Neutral red may be used in the same way and has the advantage that the dye may be restored by direct oxidation from the air, if reduction has proceeded too far. By dividing the pancreas into a large number of small pieces the islets in each piece may be counted (Fig. 108) and the whole number in the pancreas determined.

Direct enumeration of the islets sets at rest the argument of those who have claimed that the quantity of islet tissue is too small to influence carbohydrate metabolism. Bensley has found 56,000 islets in the pancreas of a guinea pig and in a newborn animal has counted 551 in one milligram of tissue. The average number is below these figures.

3. *Attempts to transform acini into islets by stimulation with secretion, by inanition, etc.:*

Those, who have studied the pancreas by methods which demonstrate specific granules of the islet cells on the one hand and zymogen granules on the other, have found that islet and acinous cells are readily distinguishable with no transitions from one to the other. Others, who have maintained the opinion that islets are transformed into secreting acini, have been "wholly undismayed by the difficulties involved in the peculiar blood supply of the islets and in the apparent lack of lumina and duct connections" (Bensley, 1915). Nevertheless, the cytological studies of Lane, Bensley and others have not brought about uniformity of opinion, for Saguchi (1920), Seyforth (1920) and others, using varied methods, still claim that transitional stages between secreting acini and islands of Langerhans are readily demonstrable.

Much effort has been made to determine whether stimulation of pancreatic secretion, perhaps to exhaustion of the gland, will, with loss of zymogen granules, transform acini into islets. Lewaschew long ago maintained that this transformation occurred in cats and dogs after prolonged overfeeding and after administration of pilocarpine. By the continued administration of secretine Dale (1905) found in the dog changes which he believed to represent the transformation of the greater part of lobules into islets, and, in the toad, he maintained, almost the whole pancreas underwent a similar change. Vincent and Thompson (1907) were unsuccessful when they attempted in dogs to transform acini into islets by the administration of pilocarpine, but found, they thought, a definite increase of islet tissue after the injection of secretine, far less, however, than that after inanition.

Subsequent experiments with pilocarpine have failed to confirm the opinion that islet tissue is increased. Cecil (1912), who identified islands of Langerhans by methods adapted to demonstrate the granules described by Lane, discovered by enumeration of the islets no increase after the administration of secretine to dogs. Bensley (1911), employing his differential method by which all of the islets in the pancreas of a guinea pig may be counted, has found no increase after such prolonged stimulation with secretine that most of the acini have wholly lost their zymogen granules (see Division VI).

Inanition, it has been claimed, may transform secreting acini into islands of Langerhans (Vincent and Thompson, 1907; Laguesse, 1911). De Witt (1906) has counted and measured the islets of guinea pigs after withdrawal of food and after a continued diet of meat or carbohydrate and has detected no deviation from the normal. Allen (1913), who has availed himself of the differential staining methods for identification of islet cells, found no increase in cats after inanition and after injection of various carbohydrates and of fats.

VI. REACTION OF THE CELLS TO INJURY

Human tissue removed at autopsy affords unfavorable opportunity for the study of pathological cytology. The mitochondria are so delicate that they disappear from the pancreas a short time after death, whereas in the nervous system and in other tissues which autolyze slowly they may be studied more successfully (Cowdry, 1916). Our present knowledge concerning the intimate details of cell injury has been obtained in great part from experimental studies, but it is nevertheless desirable to discuss briefly the more important types of injury recognizable in the human pancreas, for eventually each degenerative change must be subjected to cytological analysis.

Changes on the borderline between the normal and pathological are found in the secreting tissue of the pancreas and suggest the possibility that continued stimulation with final exhaustion may cause destruction of the cells. In the human pancreas are occasionally found groups of acini in which the chromidial substance is lost so that the cells assume a homogeneous bright pink color when stained with eosin (Opie, 1900, 1910). The affected area is often approximately the size of an island of Langerhans and has doubtless often been mistaken for a stage of transition between acinous and islet tissue. Somewhat similar changes can be produced experimentally by continued stimulation with secretine. In the rat, subjected to multiple daily doses of secretine during two weeks, Dolley (1925) has found that the zymogen granules and the chromidial substance may disappear from the acinous cells. Simultaneously, he says, the chromatin of the nucleus disap-

pears and nuclei become small and shrunken. Final disappearance of the nucleus and destruction of the cell may occur.

Under the designation "physiological degeneration," Saguchi (1920) has described changes found in scattered cells of the normal gland. Chromatin of the nucleus, he finds, is fused to form large granules or thick cords and the nuclear membrane becomes irregularly thickened. The nucleolus may be somewhat enlarged. At the same time the cell body decreases in size and may undergo repeated fragmentation. The resultant fragments, which are usually spherical, contain in some cases nuclear particles, in other instances, none. Zymogen granules may be found within the fragments. Saguchi states that the fragments may be taken up by neighboring normal glandular cells within which they disintegrate and finally disappear. Phagocytosis by acinous cells doubtless requires further verification and it is noteworthy that mononuclear phagocytes which usually ingest disintegrated cells were not found by Saguchi.

1. *Inanition:*

With inanition Okuneff (1923) has found that disintegration of mitochondria into granules and droplets is conspicuous in the liver and kidney. In the pancreas as well the change occurs in spots, and granules are formed at the expense of the mitochondrial filaments. There is coincident decrease of zymogen granules.

2. *Phosphorus poisoning:*

Alterations in mitochondria of the pancreas, caused by experimental phosphorus poisoning, has been studied by Scott (1916), in white mice. These structures, which are the first constituents of the acinous cell to undergo change, become shorter and thicker and lose their bleb-like swellings. The spherical and ovoid particles thus formed now come together like agglutinated bacilli and give rise to one or more clumps situated most frequently in the basal part of the cell. With severe intoxication the clumped particles actually fuse to form droplets and these droplets have characters which suggest that they are lipoid. No relation to the fatty infiltration, present in the pancreas but much less conspicuous than in the liver, is evident. Clumping of mitochondria and fusion to form droplets are apparently peculiar to the pancreas (see "General Cytology," p. 327, Figs. 18 to 26).

Coincident with changes in mitochondria there is a progressive disintegration and final disappearance of the Golgi apparatus as described by Cowdry (1923; see "General Cytology," p. 345 and Fig. 34).

3. *Fatty degeneration:*

The presence of fat demonstrable by osmic acid or by Sudan III within the cells of the normal pancreas has already been mentioned. The term fatty degeneration may be used to designate the abnormal accumulation of visible fat within cells and does not necessarily imply that this fat is formed within the cell. Weichselbaum and Stangl (1902) found more fat in the islands of Langerhans in individuals who had died with diabetes mellitus than in other individuals of the same age. Symmers (1909) has denied this

relation but has maintained that prolonged use of alcohol causes fatty degeneration of the islands of Langerhans; for in individuals who have used alcohol in excess this change has occurred, whereas it has been absent in those who have given no history of alcoholic indulgence.

4. *Focal necrosis:*

A lesion comparable to that which affects the liver with typhoid fever occurs in the pancreas and implicates equally islands of Langerhans and secreting acini. Whipple (1907) has found that focal necrosis of the pancreas is frequently seen at autopsy and is usually associated with lobar pneumonia or some other bacterial infection. It has, as a rule, little tendency to involve the islands of Langerhans, but in the presence of lesions of these structures, diabetes mellitus may occur (Opie, 1910).

5. *Hydropic degeneration:*

In this form of degeneration, found by Weichselbaum (1911) in many of those who have died with diabetes mellitus, the cells of the islands of Langerhans assume a transparent appearance due to distention with watery fluid. The nucleus becomes smaller, and atrophy and finally complete disappearance of cells may occur, so that the islets are represented only by groups of very small cells with deeply stained nuclei. With the methods of staining introduced by Bensley, Homans (1915) has found that hydropic degeneration, characterized by swelling of cells and vacuole formation, affects only the B-cells and is preceded by loss of the peculiar granules of these cells, the A-cells remaining unchanged. Hydropic degeneration has been produced by Allen (1913) and by Homans (1914, 1915) in dogs and cats.

6. *Hyaline degeneration:*

This lesion is significant, because, in association with diabetes mellitus, it may attack the islands of Langerhans and leave unaffected the acinous tissue of the organ (Opie, 1902). The term hyaline degeneration is wholly descriptive and is applied to the ill-defined group of degenerative processes of which the common character is the formation of homogeneous or hyaline material. In the islands of Langerhans hyaline occurs as conspicuous masses in contact with capillaries, the endothelium of which is well preserved. The islet cells are partly or completely destroyed and replaced. Hyaline of epithelial origin, according to the old classification of P. Ernst, stains yellow with Van Gieson's stain, whereas hyaline derived from white fibrous tissue containing distinctive elements of collagenous fibers stains red. By this method the hyaline of the islands of Langerhans stains yellow with picric acid. With phosphomolybdic acid hematoxylin, as used by Ribbert, or with aniline blue used by Mallory for demonstration of white fibers and reticulum,

it assumes a deep blue color and becomes very conspicuous. When the degenerative change begins, the affected cells undergo slight enlargement and their cytoplasm which is still granular becomes colored diffusely blue by the stain just mentioned. Later, the nucleus disappears and hyaline material replaces the cell. With fusion of smaller particles, homogeneous masses are formed in contact with the capillaries. Weichselbaum (1911) finds evidence that this hyalin is derived from newly formed fibrous tissue within the islands of Langerhans. Views concerning the nature of the change must be tentative and further study of it is desirable.

VII. REGENERATION

When a considerable part of the pancreas is removed, the remaining part shows little if any gross evidence of regeneration. Nevertheless cell proliferation, affecting especially ducts and islands of Langerhans, is demonstrable by histological examination.

Regeneration of the pancreas of dogs and guinea pigs, Kyrle (1908) has found, proceeds chiefly from the ducts. The epithelium undergoes a twofold differentiation. On the one hand, anastomosing strands of cells arising from small ducts form islands of Langerhans, and on the other hand, groups of cells acquire the ability to produce zymogen granules and form acini. At a later period mitotic division shows that there is some scant proliferation of cells in preexisting acini and islets. Ukai (1926c) has destroyed a part of the pancreas of rabbits by cauterization and in a few instances by trauma, and has studied the subsequent evidence of regeneration by means of a staining method adapted to the recognition of both the islet and acinous cells. The islands of Langerhans show greater resistance to injury than the secreting acini. Within three days the epithelium of the small ducts, lying close to the site of injury, undergoes proliferation by mitosis and at times by amitosis, so that several layers of cells may be formed. After from three to seven days, projections grow out from the ducts and form both strands grouped as islet and gland-like sacs. The cells at the periphery of the new islets contain fuchsinophile granules like those of the A-cells; whereas cells nearer the duct, from which the islet has developed, are basophile in character, like B-cells. The cells of the new gland-like sacs are likewise in large part basophile, but in some of them zymogen granules make their appearance. Islands of Langerhans regenerate with much greater activity than secreting acini. From the gland-like sacs acini resembling those of the normal gland are seldom formed. No trasnitions between newly formed islets and old or new acini are found.

Hypertrophy of the islands of Langerhans has been observed in association with human lesions, which destroy some of these structures and presumably force to unusual functional activity those which remain. Abnor-

mally large islands of Langerhans may be found along the margin of a tumor advancing within the pancreas (Pearce, 1904). In many instances, in combination with destructive lesions of the islands of Langerhans and usually in association with diabetes mellitus, surviving islands may undergo hypertrophy and perhaps vicariously assume the function of those which have been injured (Cecil, 1909).

A peculiar form of hypertrophy of the islets has been observed in a few instances of diabetes mellitus (Reitman, Ssobolew, 1904; MacCallum, 1907; Cecil, 1909, etc.) and may be designated, for convenience, "adenoma-like hypertrophy." The cells of islets assume a cylindrical form with nuclei centrally placed. These islands are unusually large, and, some have thought, are in continuity with surrounding acini.

VIII. CHANGES FOLLOWING LIGATION OF PANCREATIC DUCTS

Ligation of the pancreatic ducts has attracted much attention because in the opinion of many of those who have studied the ensuing changes the pancreas is reduced by this means to a pure endocrine organ, the islands of Langerhans alone surviving. This conclusion is not universally accepted and among those who have occluded the pancreatic ducts there is wide difference of opinion concerning the changes which follow (see review by Allen, 1913).

Vassale (1889) has found that islands of Langerhans in rabbits persist within the sclerotic tissue, and the same observation has been made by Schultze (1900) in guinea pigs and by many others. Some of those who have ligated the pancreatic ducts (e.g., Lombroso, 1905, in dogs) have at times found no sclerosis. Failure to occlude all of the ducts, or the regeneration of the duct with reestablishment of its continuity with the duodenum, doubtless explains in these exceptional instances the absence of inflammatory atrophy of the gland. Some of the investigators, who have found that islands of Langerhans persist in the sclerotic tissue, claim that acini survive as well. Islets and acini have been found to be equally injured by Pratt and Spooner (1911), but most of those who have found degeneration of both structures state that the acini disappear more rapidly than the islets (Mankowski, 1902; Carraro, 1909, etc.) These discrepancies are in part reconciled by the observation (Pende, 1910; Massaglia, 1915) that islands of Langerhans survive the secreting acini, but become injured when sclerosis is far advanced.

To give precision to experiments directed to determine what structures are injured and destroyed by duct ligation, methods, which identify cells of acini on the one hand and islet cells on the other, are essential. The study has become a problem of applied cytology, because the arrangement of the cells in columns and the absence of a lumen are insufficient for the identification of islet tissue.

In a rabbit, six months after ligation of the pancreatic duct, Laguesse and Gontier de la Roche (1902), using staining methods which show granules within cells of the islets, found these structures to be the sole remnant of the pancreas, and the same condition was found in a guinea pig fifteen months after ligation of the duct by Kirkbride (1912), who used Bensley's neutral gentian stain.

In the experiments of E. Clark described by Bensley (1915), vital staining with Janus green or with neutral red has been used, and after fixation, granules characteristic of the islet cells have been stained by appropriate methods. Degeneration of acinous cells follows promptly duct ligation in guinea pigs, so that at the end of seven days cells identified as acinous, because they are imbricated over the ends of intralobular ducts, have lost their zymogen granules. In these cells, as well as in the remains of the duct system, are many mitoses and in the subsequent regenerative processes, it may be assumed, according to Bensley, that these "dedifferentiated" acinous cells and cells of ducts participate in equal measure. Toward the end of the first month regenerative changes are conspicuous and new islands of Langerhans and new acini are formed. At the same time the original islets are invaded by newly formed fibrous tissue and their cells atrophy. After five and a half months, nearly all of the islet tissue which is present has been formed since ligation of the duct. The oval and spherical islets of the original pancreas have disappeared and replacing them are branching masses of islet cells which contain characteristic granules. At this time there is still recognizable a considerable amount of acinous tissue in the form of bulb-like acini, in which zymogen granules are abundant. Few animals have been maintained beyond this period but there seems to be a progressive increase of islet tissue and destruction of acini in excess of their regeneration. At what period the last vestiges of acinous tissue disappear has not been determined, but in an animal kept 533 days after duct ligation the pancreas has been found to be represented by islets embedded in a mass of fat having the shape of the original pancreas. Racemose masses with bulbous protuberances and cords forming irregular networks are composed of characteristically stained islet cells. There are, furthermore, complicated nets of duct-like tubules composed of undifferentiated cells but acinous tissue has not been found. There has been no glycosuria.

Changes following duct ligation in rabbits after periods varying from four hours to 980 days have been studied by Ukai (1926) with methods well adapted to the identification of the various cells of the pancreas. The centroacinous cells disappear when the lumina of acini become dilated and are not found after twelve days. Zymogen granules have disappeared from cells of acini after thirty-three days, but at a later period (134 days), are present here and there within cells lining dilated pouches which have formed upon small branches of the duct. Nevertheless, after 178 days, these granule-containing cells have disappeared. Regenerating sprouts from the small ducts are first seen four days after ligation and are most conspicuous from eight to twenty days after ligation, but with increasing sclerosis destruction exceeds regeneration. The ducts themselves finally disappear so that only the main duct with short blind pouches finally persists (900 days). Cells of the preexisting islands of Langerhans may at first increase in size

and number, but new formation of islets is a more important regenerative change. Islands of irregular shape are found in continuity with epithelial sprouts from the ducts. In this newly formed islet tissue, cell division is in places incomplete and structures like giant cells are formed. Many islets undergo regressive changes but after seven weeks their number is somewhat increased and they persist isolated in fatty tissue, which finally replaces newly formed fibrous tissue. After 900 days, the islands of Langerhans, although reduced in number, in part remain well preserved.

It is evident that as the result of duct ligation the acinous tissue disappears more rapidly than the islands of Langerhans and is regenerated with greater difficulty. Finally comes a time when the acinous tissue, recognizable by the presence of zymogen granules, has completely disappeared, although islands of Langerhans, in large part if not all newly formed and more or less injured by coincident sclerosis of the organ, still persist and are recognizable by means of the distinctive granules of their cells. Acinous-like pouches formed by cells which have lost their zymogen granules remain and the ducts contain cells which appear to be capable of differentiation into acinous cells on the one hand and into islet cells on the other.

IX. THE ISLANDS OF LANGERHANS AND CARBOHYDRATE METABOLISM

The occurrence of pathological changes in the pancreas in association with diabetes mellitus and the production of experimental diabetes by extirpation of the pancreas, first successfully accomplished by von Mering and Minkowski, have proved that the organ exerts a controlling influence upon carbohydrate metabolism. Changes in the islands of Langerhans in association with diabetes mellitus were first recognized by the writer (1900), previous references to the subject being conjectural. Lesions of the pancreas, such as interacinar pancreatitis, implicate the islands of Langerhans and are associated with diabetes mellitus, whereas lesions which cause widespread destruction of the secreting parenchyma but spare the islands of Langerhans, such as interlobular pancreatitis following occlusion of ducts, are not accompanied by glycosuria (Opie, 1901). Hyaline degeneration (Opie, 1902) may destroy almost every island of Langerhans and, causing diabetes mellitus, leave the secreting parenchyma unchanged.

From the literature on the subject, Sauerbeck (1904) and Opie (1910) have collected 288 instances of diabetes mellitus described by many authors in which histological examination of the pancreas has been made. In 86.5 per cent of these diabetics there have been lesions of the pancreas involving the islands of Langerhans and particularly significant is a small group in which, in spite of lesions of the islets, the acinous tissue has remained normal. In the remaining instances (13.5 per cent), both islets and acini have been described as normal. Some pathologists have failed to find what they regard as significant lesions of the islands of Langerhans in association

with diabetes, but the trend of opinion is shown by the foregoing figures. In a large series of cases subsequently published by Cecil (1909) the pancreas has been normal in only 11 per cent of instances, and, in a larger series published by Weichselbaum (1911) and by Heiberg (1911), alterations in the islets have been found in all instances.

Those who have discussed the relation of islands of Langerhans to diabetes have emphasized the significance of instances in which, with diabetes, the islands of Langerhans have remained normal. Bensley says: "The pathological observations in human diabetes are . . . inconclusive since many authors report cases of grave diabetes in which the islets are apparently unaffected." Even if important though inconspicuous lesions, such as hydropic degeneration, be left out of consideration instances in which both islets and acini are apparently normal may be cited as evidence that neither structure is concerned in the production of existing diabetes. Yet few if any writers now deny that destruction of the pancreas causes diabetes and if, in some instances of diabetes, the pancreas is indeed proved to be normal the pathogenesis of the disease must be sought elsewhere.

More intimate knowledge of cell structure has increased the facility with which islets and acini may be identified and has added weight to the opinion of those who have maintained that islands of Langerhans and acini, although derived from the same duodenal outgrowth, are independent structures. Although opinion is by no means unanimous, cytological studies have supported the view that the acini cannot be transformed into islet tissue.

Numerous observers have found that ligation of the pancreatic duct does not cause glycosuria, and in a number of instances, in the absence of glycosuria, more or less complete examination of the pancreas has disclosed destruction of secreting acini and survival of the islands of Langerhans. In a dog, MacCallum (1909) has removed by operation the atrophied pancreas seven months after ligation of the duct. Intense glycosuria followed and microscopic examination of the part excised showed that pancreatic tissue was represented by what seemed to be islands of Langerhans. E. Clark (Bensley, 1915) examined the entire pancreas of a guinea pig which had lived with no glycosuria during 533 days after duct ligation and showed, by appropriate cytological methods, that islands of Langerhans, and duct-like structures containing no zymogen granules, alone persisted. It is doubtful if this experiment has fulfilled the requirement laid down by Bensley, namely, the total exclusion of one kind of tissue; for the duct-like structures which have been found, even though they consist of cells with no zymogen granules, are in part doubtless the "dedifferentiated" acinous cells described by Bensley.

It is noteworthy that several observers (Tiberti, quoted by Massaglia; Massaglia, 1915) have found glycosuria following duct ligation at a time when it may be assumed that advancing sclerosis has caused severe injury

to the islands of Langerhans. Since at this time secreting acini have disappeared it might be claimed, doubtless erroneously, that the loss of the secreting acini has disturbed carbohydrate metabolism.

For those, who have with well-directed ingenuity, used cytological methods in the attempt to correlate changes in the histological elements of the pancreas with functional disturbances and have thus hoped to obtain unanimity of opinion concerning the function of the islands of Langerhans and their relation to other components of the gland, the results have been disappointing. Duct ligation fails to furnish indisputable proof that the islands of Langerhans persisting alone suffice to maintain normal metabolism of sugar.

Nevertheless these studies have reinforced deductions based upon the pathological histology of the human pancreas. The time-honored method of correlating alteration of structure with symptoms of disease has shown that the islands of Langerhans control carbohydrate metabolism. The basis of this view has been the following: (*a*) Destruction or removal of the pancreas causes impaired assimilation of sugar and glycosuria. (*b*) Lesions of the islands of Langerhans are accompanied by glycosuria even though the secreting parenchyma shows trivial or no changes. (*c*) Lesions, which like those following duct occlusion in man or in animals, destroy the secreting parenchyma and spare the islands of Langerhans are unaccompanied by disturbed carbohydrate metabolism and glycosuria.

When approximately nine-tenths of the pancreas of the dog is removed, and the remnant is left in communication with the duodenum, changes occur in the islands of Langerhans which Allen (1913) attributes to exhaustion caused by excessive endocrine activity. The diabetes which follows is at first relatively mild, and if the animal is killed soon after operation no changes are found in the islets, but later there is complete inability to utilize dextrose and all of the islands of Langerhans are the site of degenerative changes. The cytoplasm of the cells is replaced wholly or in part by clear vacuoles and the nuclei are pycnotic. Cells finally disappear, and in animals which have long survived the operation (approximately two months) recognizable islets have disappeared. Secreting acini remain unaffected, but when animals have died after long-continued diabetes, vacuolar degeneration similar to that of islet cells is occasionally found affecting the cells of the small ducts (Allen, 1922).

The possibility that hydropic degeneration of islet cells is caused by hyperglycemia suggests itself. Allen (1922) performed partial pancreatectomy, leaving a part of the pancreas sufficient to prevent diabetes, and then maintained hyperglycemia during a long period by carbohydrate diet. No hydropic degeneration ensued.

The staining methods applied by Lane to the study of the granules in the islet cells gives further insight into the changes which occur when, by

partial extirpation, a few islands of Langerhans are presumably stimulated to continued hyperactivity. After removal of five-sixths of the pancreas of the cat or nine-tenths of the pancreas of the dog, the main ducts being left in situ, Homans (1914 1915) found that the granules of B-cells, which undergo hydropic degeneration, are diminished in quantity or disappear,

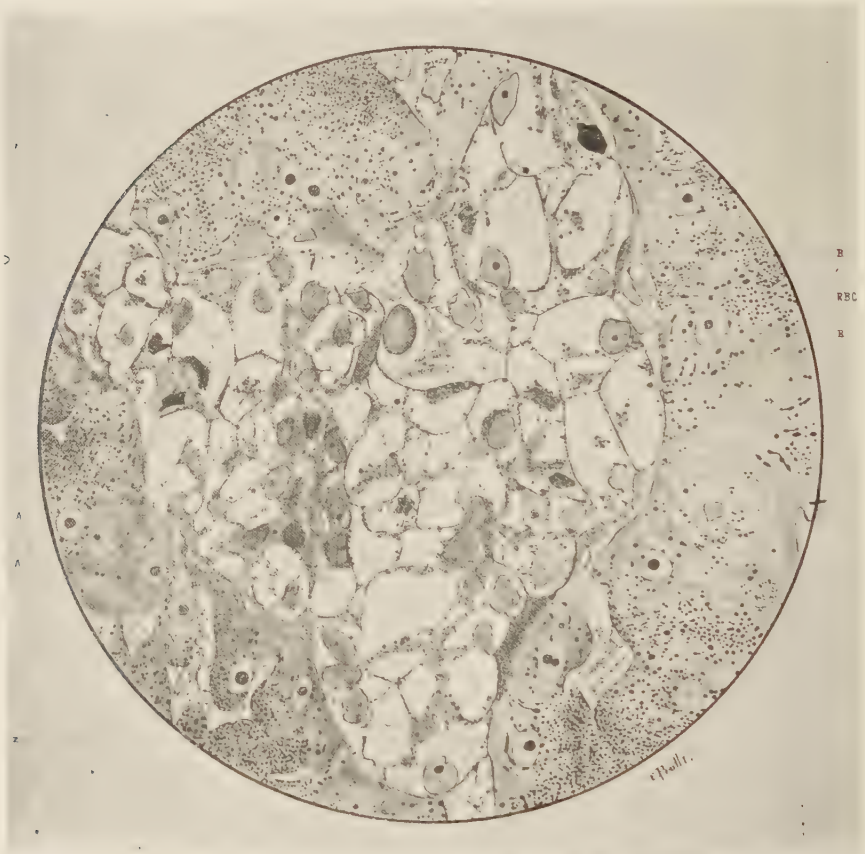

FIG. 109.—Islands of Langerhans, forty-three day safter removal of five-sixths of the pancreas, leaving the duct *in situ*. Rapid diabetes with wasting. Tissue fixed in acetic osmic bichromate mixture and stained with fuchsin and methyl green. (After Homas, 1914), magnification × 900.

whereas no changes occur in the A-cells. Inasmuch as the B-cells far outnumber the A-cells, atrophy of the islets may be recognized even though methods for identification of granules are not used. With destruction of B-cells, consequent upon hydropic degeneration, A-cells alone remain to identify the islands of Langerhans.

To complete the discussion of the endocrine function of the islands of Langerhans brief reference must be made to the discovery of insulin. The extract with which Banting and Best (1922*a*) first succeeded in controlling carbohydrate metabolism was obtained from the pancreas of dogs rendered

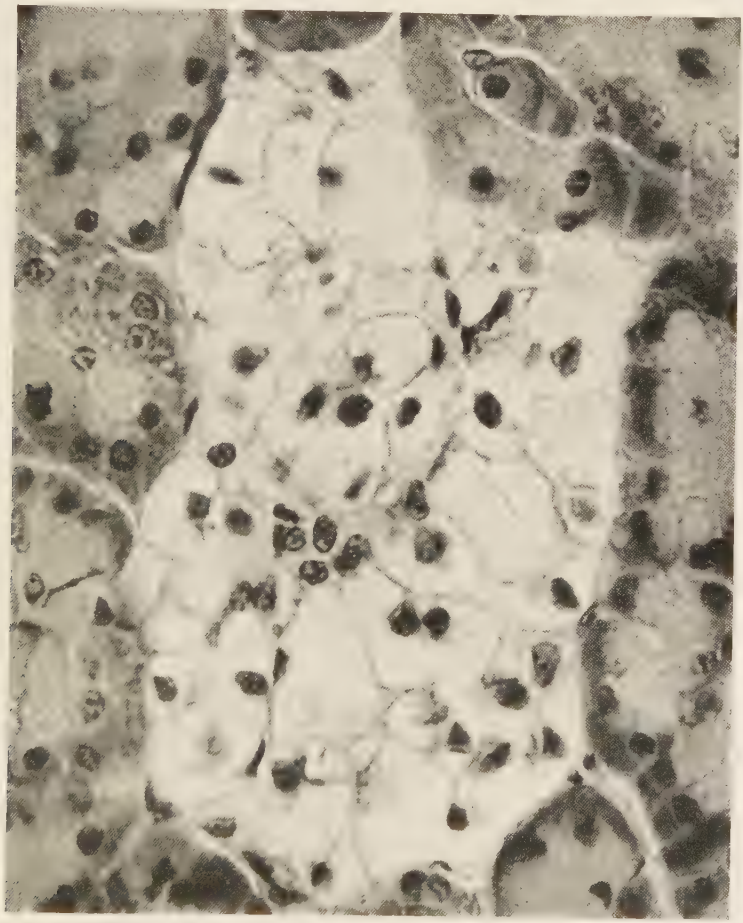

FIG. 110.—Hydropic degeneration of islands of Langerhans of the dog with experimental diabetes following removal of greater part of the pancreas. In the central part of the island are cells which are little changed, and by special granule stains are found to be A-cells. Photomicrograph, magnification × 720. (After Allen, 1922.)

atrophic by ligation of the ducts. The pancreatic tissue removed after from seven to ten weeks contained, they say, healthy islets in abundance but no acini. The elimination of secreting tissue, they believe, is essential to the production of an effective preparation; for extracts of whole pancreas have had but little value. Extracts of pancreas of a fetal calf, which contains no

proteolytic enzymes, have later been used to control diabetes and finally by special methods of extraction the deleterious substances contained in the whole adult pancreas have thus been eliminated.

Insulin has been found by Macleod (1922) to occur in extracts prepared from the "principal islet" found by Rennie in teleostean fish. This organ, it has been claimed, consists of isolated islet tissue alone, while within the neighboring pancreas there is no islet tissue. All of those who have studied the pancreas of these fish do not agree that the "principal islet" on the one hand contains no acinous tissue, whereas the remaining pancreas, on the other hand, contains no islets. Nevertheless, Vincent, Dodds and Dickens (1924) have found that the principal islet yielded from six to seven times as much insulin as the zymogenic tissue.

Although the discovery of insulin has aided very little in the solution of the difficult questions concerning the functions of the various histological elements of the pancreas, which have been discussed in this section, it has defined these problems with greater precision, for now inquiry may be made concerning the site of formation of insulin, whereas before its discovery hyperglycemia and glycosuria were the only criteria by which the disturbed endocrine function of the pancreas might be measured. Nevertheless the discovery of insulin, perhaps chiefly by reason of its name and its efficacy, have brought almost universal acceptance of the "insular theory" of diabetes. Should it be assumed that this verdict reflects the uncertainty of scientific judgment, consolation may be had in the reflection that the labored study of structural change has had no small part in the discovery of this useful remedy.

X. BIBLIOGRAPHY

Allen, F. M. 1913. *Studies concerning glycosuria and diabetes.* Boston: W. M. Leonard, 1179 pp.

——— 1922*a*. Hydropic degeneration of islands of Langerhans after partial pancreatectomy. *J. Metab. Res.*, **1**, 1.

——— 1922*b*. The role of hyperglycemia in the production of hydropic degeneration of islands. *Ibid.*, **1**, 73.

Arnold, G. 1912. The role of chondriosomes in the cells of the guinea pig's pancreas. *Arch. f. Zellforschung*, **8**, 252.

Babkin, B. P., Rubaschkin, W. J., and Ssawitsch, W. W. 1909. Über die morphologischen Veränderungen der Pankreaszellen. *Arch. f. mikr. Anat.*, **74**, 68.

Banting, F. G., and Best, C. H. 1922*a*. The internal secretion of the pancreas. *J. Lab. and Clin. Med.*, **7**, 251.

1922*b*. Pancreatic extracts. *Ibid.*, **7**, 464.

Bensley, R. R. 1911. Studies on the pancreas of the guinea pig. *Am. J. Anat.*, **12**, 297.

1915. Structure and relationships of the islets of Langerhans. *Harvey Lectures*, **10**, 250.

Bergen, F. von. 1904. Zu Kenntnis gewisser Strukturbilder im Protoplasma verschiedener Zellarten. *Arch. f. mikr. Anat.*, **64**, 498.

Cajal, S. Ramon y. 1914. Aigunas variaciones fisiológicas y pathológicas del aparato reticular de Golgi. *Trab. d. lab. de invest. biol., Univ. de Madrid,* **12,** 127.

Carraro, A. 1909. Sulla rigenerazione del pancreas. *Lo Sperimentale,* **63,** 937.

Cecil, R. L. 1909. A study of the pathological anatomy of the pancreas in ninety cases of diabetes mellitus. *J. Exper. Med.,* **11,** 266.

——— 1912. The effect of certain experimental procedures on the islands of Langerhans. *Ibid.,* **16,** 1.

Cowdry, E. V. 1916. The general functional significance of mitochondria. *Am. J. Anat.,* **19,** 423.

——— 1923. The significance of the internal reticular apparatus of Golgi in cellular physiology. *Science,* **58,** 1.

Dale, H. H. 1905. On the islets of Langerhans of the pancreas. *Philos. Trans. Roy. Soc.,* London, **197,** ser. B, 25.

De Witt, L. 1906. Morphology and physiology of areas of Langerhans in some vertebrates. *J. Exper. Med.,* **8,** 193.

Diamare, V. 1899. Studii comparativi sulle isoli di Langerhans di pancreas. *Internat. Monatschr. f. Anat. u. Physiol.,* **16,** 155.

Dolley, D. H. 1925. The general morphology of pancreatic cell function in terms of the nucleocytoplasmic relation. *Am. J. Anat.,* **35,** 153.

Garnier, C. 1900. Du rôle de l'ergastoplasme dans la sécrétion. *J. de l'Anat. et de la Physiol.,* **36,** 22.

Heiberg, K. A. 1906. Beiträge zur Kenntnis der Langerhansschen Inseln im Pankreas, nebst Darstellung einer neuen mikroskopischen Messungsmethode. *Anat. Anz.,* **29,** 49.

——— 1911. Studien über die pathologisch-anatomische Grundlage des Diabetes mellitus. *Virchow's Archiv,* **204,** 175.

Herwerden, M. A. von. 1912. Ueber die Beziehungen des Langerhans'schen Inseln zum uebrigen Pankreasgewebe. *Anat. Anz.,* **42,** 430.

Holmgren, E. 1904. Beiträge zur Morphologie der Zelle. *Anat. Hefte,* **25,** 97.

Homans, J. 1914. Degeneration of the islands of Langerhans associated with experimental diabetes in the cat. *J. Med. Res.,* **30,** 49.

——— 1915. A study of experimental diabetes in the canine and its relation to human diabetes. *Ibid.,* **33,** 1.

Key, J. A. 1916. On the relation of mitochondria to zymogen granules. *Anat. Rec.,* **10,** 215.

Kirkbride, M. B. 1912. The islands of Langerhans after ligation of the pancreatic ducts. *J. Exper. Med.,* **15,** 101.

Kuster, H. 1904. Zur Entwicklung der Langerhans'schen Inseln im Pankreas beim menschlichen Embryo. *Arch. f. mikr. Anat.,* **64,** 158.

Kyrle, J. 1908. Ueber die Regenerationsvorgänge im tierischen Pankreas. *Arch. f. mikr. Anat.,* **72,** 141.

Laguesse, E. 1895. Recherches sur l'histogénie du pancréas chez le mouton. *J. de l'Anat. et Physiol.,* **21,** 475.

——— 1900. Sur les variations de la graisse dans les cellules sécretantes séreuses (pancréas). *Compt. rend Soc. Biol.,* **52,** 706.

——— 1901. Sur la structure du pancréas chez quelques ophidiens et particulièrement sur les îlots endocrines. *Arch. d'Anat. micr.,* **4,** 157.

——— 1910. Sur l'évolution des îlots endocrines dans le pancréas de l'homme adulte. *Ibid.,* **11,** 1.

——— 1911. Preuve expérimentale du balancement dans les islôts endocrines du pancréas. *J. de Physiol. et de Path. Gén.,* **13,** 5.

Laguesse, E., and Gontier de la Roche, A. 1902. Les îlots de Langerhans dans le pancréas du cobaye après ligature. *Compt. rend. Soc. de Biol.*, **54**, 854.

Lane, M. A. 1907. The cytological characters of the areas of Langerhans. *Am. J. Anat.*, **7**, 409.

Lombroso, U. 1905. Sur la structure histologique du pancréas, après ligature et section des conduits pancréatiques. *J. de Physiol. et de Path. Gén.*, **7**, 3.

MacCallum, W. S. 1907. Hypertrophy of the islands of Langerhans in diabetes mellitus. *Am. J. Med. Sci.*, **133**, 432.

——— 1909. On the relation of the islands of Langerhans to glycosuria. *Bull. Johns Hopkins Hosp.*, **20**, 265.

MacLeod, J. J. R. 1922. The source of insulin. A study of the effect produced on blood sugar by extracts of the pancreas and principal islets of fishes. *J. Metab. Res.*, **2**, 149.

Mankowski, A. 1902. Ueber die mikroskopischen Veränderungen des Pankreas nach Unterbindung einzelelner Theile und über einige mikrochemische Besonderheiten der Langerhans'schen Inseln. *Arch. f. mikr. Anat.*, **59**, 286.

Massaglia, A. 1915. Die Langerhans'schen Inseln. *Frankfürter Zeit. f. Path.*, **16**, 216.

Matthews, A. 1899. The changes in structure of the pancreas cells. *J. Morph.*, **15**, Suppl., 171.

Maximow, A. 1916. Sur la structure des chondriosomes. *Compt. rend. Soc. de biol.*, **79**, 465.

Mislawsky, N. 1913. Ueber das Chondrion der Pankreaszellen. *Arch. f. mikr. Anat.*, **81**, 394.

Nassonov, D. N. 1923. Das Golgische Binnennetz und seine Beziehungen zu der Sekretion. *Arch. f. mikr. Anat.*, **97**, 136.

Okuneff, N. 1923. Studien über Zellveränderungen im Hungerzustande. *Arch. f. mikr. Anat.*, **97**, 187.

Opie, E. L. 1900*a*. Histology of the islands of Langerhans of the pancreas. *Bull. Johns Hopkins Hosp.*, **11**, 205.

——— 1900*b*. Pathological changes affecting the islands of Langerhans of the pancreas. *J. Boston Soc. Med. Sci.*, **4**, 251.

——— 1901. On the relation of chronic interstitial pancreatitis to the islands of Langerhans and to diabetes mellitus. *J. Exper. Med.*, **5**, 397.

——— 1902. The relation of diabetes mellitus to lesions of the pancreas. Hyaline degeneration of the islands of Langerhans. *Ibid.*, **5**, 527.

——— 1910. *Disease of the pancreas*. Ed. 2, Philadelphia and London: J. B. Lippincott Co. 387 pp.

Pearce, R. M. 1903. The development of the islands of Langerhans in the human embryo. *Am. J. Anat.*, **2**, 445.

——— 1904. Cancer of the pancreas and glycosuria. *Am. J. Med. Sci.*, **128**, 478.

Pende, N. 1910. Diabète pancréatique expérimentale par ligature du conduit de Wirsung. *Arch. ital. de biol.*, **54**, 157.

Pratt, J. H., and Spooner, L. H. 1911. A study of the internal function of the pancreas in carbohydrate metabolism. *Arch. Int. Med.*, **7**, 665.

Saguchi, S. 1920*a*. Studies on the glandular cells of the frog's pancreas. *Am. J. Anat.*, **26**, 347.

——— 1920*b*. Cytological studies of Langerhans's islets. *Ibid.*, **28**, 1.

Sauerbeck, E. 1904. Die Langerhansschen Inseln der Pankreas and ihre Beziehung zum Diabetes mellitus. *Lubarsch-Ostertag Ergebn. d. allge. Path. u. path. Anat.*, 7 Jahr., 2 Abt., 538.

Schulze, W. 1900. Die Bedeutung der Langerhans'schen Inseln im Pankreas. *Arch. f. mikr. Anat.*, **59**, 491.

Scott, W. J. M. 1916. Experimental mitochondrial changes in the pancreas in phosphorus poisoning. *Am. J. Anat.*, **20**, 237.

Seyforth, C. 1920. *Neue Beiträge zur Kenntnis der Langerhans'schen Inseln im menschlichen Pankreas und ihre Beziehung zum Diabetes mellitus.* Jena, 104 pp.

Stangl, E. 1901. Zur Histologie des Pankreas. *Wiener klin. Woch.*, **14**, 964.

Symmers, D. 1909. The occurrence of fat in the islands of Langerhans. *Arch. Int. Med.*, **3**, 279.

Tsukaguchi, R., and Takagi, K. 1921. On the mode of functional changes in the glandular structures. *Japan Med. World*, **1**, 7.

Ukai, S. 1926*a*. Ueber die feiners Struktur des Pankreas. *Mitt. u. allg. Path. und path. Anat.*, **3**, 1.

——— 1926*b*. Regenerationsphänomene nach der Unterbindung des Ductus pancreaticus. *Ibid.*, **3**, 27.

——— 1926*c*. Regenerationsphänomene nach Kauterisation und Verwundung. *Ibid.*, **3**, 65.

——— 1926*d*. Einige kritische Betrachtungen. *Ibid.*, **3**, 173.

Vassale. 1889. Ricerche microscopiche e sperimentale sulle alterazioni del pancreas consecutive alla legatura del dotto di Wirsung. *Reggio-Emilia.* Quoted by Massaglia.

Vincent, S., Dodds, E. C., and Dickens, F. 1924. The pancreas of teleostean fishes and the source of insulin. *Lancet*, **2**, 115.

Vincent, S., and Thompson, F. D. 1907. On the relation between the islets of Langerhans and the zymogenous tubules of the pancreas. *Internat. Monatschr. f. Anat. u. Physiol.*, **26**, 61.

Visentini, A. 1909. Ueber die anatomische und funktionelle Wiederherstellung der unterbundenen und durchschnittenen Pankreasausführungsgänge. *Virchow's Archiv*, **195**, 555.

Weichselbaum, A. 1911. Ueber die Veränderungen des Pankreas bei Diabetes mellitus. *Wiener klin. Woch.*, **24**, 153.

Weichselbaum, A., and Kryle, J. 1909. Ueber das Verhalten der Langerhansschen Inseln des menschlichen Pankreas im fötalen und postfötalen Leben. *Arch. f. mikr. Anat.*, **74**, 223.

Weichselbaum, A., and Stangl, E. 1902. Weitere histologisch Untersuchungen des Pankreas bei Diabetes mellitus. *Wiener klin. Woch.*, **15**, 969.

Whipple, G. H. 1907. Pancreatitis and focal necrosis. *Bull. Johns Hopkins Hosp.*, **18**, 391.

Section X
THE ERYTHROCYTE

CONTENTS

Section X

PAGE

I. Physical Characters 275
1. Appearance and form 275
Terminology 276
2. Shape of erythrocyte 277
3. Effect of various factors on shape of erythrocyte 278
4. Structure 278
5. Size of erythrocyte 280
6. Number of erythrocytes 283
7. Amount of hemoglobin 286
8. Surface area and volume of erythrocyte 287
9. Suspension stability 288
II. Chemistry of Erythrocyte 289
III. Function of Erythrocyte 291
IV. Hemolysis 292
V. Origin and Development of Erythrocyte 296
1. Monophyletic theory 297
2. Polyphyletic theories 297
3. Sites of erythrogenesis 302
4. Stimulus to erythrogenesis 302
5. Ontogenesis of erythrocyte 303
VI. Fate of Erythrocyte 307
1. Duration of life 307
2. Disposal of worn-out erythrocytes 309
VII. Bibliography 310

Section X

THE ERYTHROCYTE

E. B. KRUMBHAAR

NO cell in the mammalian body has been studied so extensively as the red corpuscle of the blood. At no time has study been more vigorously or successfully prosecuted and from more varied points of view than in the past decade. A short perusal of medical bibliographies will easily demonstrate this.

The erythrocyte is a body cell unique in several particulars. Free in the blood stream, it is easily available in large numbers for many kinds of study; it preserves most of its qualities after withdrawal from the body; and its vital body function of transporting oxygen and carbon dioxide from the lungs to the tissues, and the dire consequences of its deranged function, have combined to direct attention toward it for many years. Unique is the fact that it normally functions after it has lost its nucleus, in other words, late in its life cycle. In certain of its relative permeabilities also (to anions and cations) the erythrocyte has a characteristic difference from other body cells. In different forms it is found in all vertebrates, and analogous pigment-bearing cells are found in many of the invertebrates as well. In still lower forms (worms and insects, for instance) a pigment similar to its chief constituent, hemoglobin, is found free in the circulating fluid.

The erythrocyte was first seen by Jan Swammerdam in 1658, soon after improvements in the microscope first permitted the observation of such small objects. Neither his nor the next observation by Malpighi in 1665, however, made much impression on the scientific world; so that Van Leeuwenhoek's report to the Royal Society in 1674 really initiated a study which, continued by Hewson, Hunter and others, produced fairly accurate ideas about its physical characters. Commensurate knowledge of its function, however, had to await chemical discoveries of more than a century and a half later.

I. PHYSICAL CHARACTERS

1. *Appearance and form:*

When normal fresh human blood is properly prepared in a thin layer between a glass slide and coverslip, the erythrocyte which, of course, greatly predominates, appears for the most part as a flat, pale, greenish-yellowish, circular, non-nucleated disc with a central area which is either lighter or darker than the periphery, depending on the position of the objective (in the less refractile plasma, the center is darker when the objective is slightly beyond the focal distance). An occasional cell will be found stand-

LANE LIBRARY. STANFORD UNIVERSITY

TERMINOLOGY

Terms	Employed by	Definition
Anisocyte		An erythrocyte varying from the normal in size.
Erythroblast	Pappenheim, Maximow	Progenitor of the normal nucleated red cell.
Erythroblast	Sabin	An arbitrary intermediate stage between the megaloblast and normoblast.
Erythrocyte		A normal adult red blood cell, term also used for the whole group.
Gigantoblast	Ehrlich	An extremely large nucleated erythrocyte, more than 12 to 18μ in diameter.
Hematoblast	Danchakoff	An undifferentiated cell from which the erythrocytic series is developed.
Hematoblast	Löwitt	A cell intermediate between erythroblast and erythrocyte.
Hemocytoblast	Ferrata	Earliest blood cell, capable of differentiating in various directions. Pappenheim's lymphoidocyte.
Hemohistioblast	Ferrata	Original stem cell in Ferrata's monophyletic system.
Macroblast	Naegeli	A young normoblast.
Macrocyte	Naegeli	A large adult erythrocyte.
Megaloblast	Ehrlich	A large basophilic nucleated erythrocyte with characteristic large immature nucleus (considered always pathological by Pappenheim and Ferrata), above 9μ in diameter.
Megalocyte	Ehrlich	A very large adult erythrocyte above 9μ in diameter.
Mesoblast		A cell intermediate between megaloblast and normoblast (term little used).
Metrocyte 1 and 2	Engel	Cells corresponding to Maximow's primary and secondary erythroblasts.
Microblast	Ehrlich	A small basophilic nucleated erythrocyte, especially common in hemolytic jaundice. Less than 6 μ in diameter.
Microcyte	Vanlair and Massius	A small adult erythrocyte less than 6μ in diameter.
Normoblast (secondary erythroblast.	Ehrlich	A relatively mature nucleated erythrocyte, 6 to 9 μ in diameter.
Normocyte	Ehrlich	A normal adult erythrocyte, 6 to 9μ in diameter.
Poikilocyte	Damon, 1864, Quincke	An erythrocyte of irregular shape.
Primitive erythroblast	Ferrata	See Promegaloblast—Pappenheim.
Primitive erythrocyte	Ferrata	See Megalocyte—Ehrlich.
Proerythroblast	Ferrata	A young erythroblast. Equivalent to pronormoblast.
Prohematoblast	Pappenheim	A progenitor of the hematoblast. This term was also used by Hayem to denote a platelet.
Promegaloblast	Pappenheim, Naegeli	A progenitor of the pathological megaloblast.
Pronormoblast	Naegeli	A young macroblast.
Prothemoblast	Malassez	The common ancestor of blood cells (term little used).
Schistocyte	Ehrlich	A fragmented, misshapen erythrocyte, differing from the true microcyte.

ing on end, i.e., seen in profile, in which case it will be seen that there is a certain amount of biconcavity, which accounts for this optical effect. Different effects will, of course, be produced by the different angles at which the various cells happen to present themselves. Some are normally slightly larger than others (see later), some may have a pie crust border, while some may appear concavo-convex, or have a tendency to a bell shape or sphere or other irregularities. All these modifications but the first are thought to be artefacts occasioned by changes in the surrounding plasma, although a few authorities (Weidenreich) believe that the bell form, as seen, for instance, in the mesentery under certain conditions, is normal. As examination of the moving cell in intact capillaries under conditions that from this point of view must be considered normal practically always reveals the biconcave form, these dissenting opinions carry but little weight. When thicker layers of blood are viewed, most of the cells will soon arrange themselves in the well-known "rouleaux," like piles of coins, so that the viscous raised peripheries are adherent and the concavity slightly diminished by pressure on the elastic material. These rouleaux can be separated, however, with needles, and are not associated with coagulation, as they occur in defibrinated blood. According to Jolly (1923) it is purely a question of surface tension, whereby bodies suspended in a fluid tend to approach on their largest surfaces; and he is able to reproduce the phenomenon with small discs of wood in water.

2. *Shape of the erythrocyte:*

Explanations of the biconcave shape of the erythrocyte are not entirely explanatory. On evolutionary grounds the large surface exposed for a given bulk is an obvious advantage (if spherical there would have to be nine times the number of cells of one-ninth the volume to get the same rapidity of gas diffusion). It is pointed out later that the number of cells in different species (and surface area) is in direct proportion to their metabolic needs, though inversely to the size of the cells. Hartridge (1919) also suggests that the biconcave form is one which permits slight changes in volume without greatly changing the internal stress and ingeniously suggests that it is the best shape to permit in- and out-going gases to reach and leave all parts of the corpuscle with the least variation in time—an important item in the efficient performances of the cell's function.

Ponder (1925), however, shows mathematically that this deduction, though very close, is not absolutely true and considers the similarity a lucky coincidence. He shows that by Cayley's equipotential curves the biconcave shape is not that of a solid with equipotential surfaces, but believes that it is maintained not by surface tension factors, which would

tend toward a spheroid form, but by a state of internal stress, which he has estimated at 2.5×10^{-5} ergs. Thus in saponin hemolysis which is considered as dissolving the lipoid component which maintains this stress, the cell may become spherical without change in volume.

3. *Effect of various factors on the shape of the erythrocyte:*

In hypotonic solutions or when the P_H of the plasma is changed, as when fresh blood is allowed to stand without clotting (e.g., by the escape of carbon dioxide), the biconcave shape changes into cupola or spherical forms or small beads, knobs or spikes may appear on the surface of the cell, which shrinks into the condition known as crenation. This is due (at least in part) to the escape of fluid through the semi-permeable membrane (osmosis, application of the Donnan equilibrium, etc.) and is reversible up to a certain point by shaking, centrifugation, addition of carbon dioxide and similar methods.

If immersed in water or in any salt solution in which the molecular concentration of the medium is sufficiently less than that of the cells (hypotonic), the cell volume increases (at first with diminution of diameter as a more spherical form is assumed). Even the oval cell of the camel becomes spherical with these conditions. The cell next becomes paler as the hemoglobin diffuses out into the surrounding medium until only the colorless ghost (lipo-protein) remains ("laking"). This occurs without any noticeable rupture in any part of the cell structure, which remains as a structureless disc. Laking with 1 per cent acetic acid, however, leaves a more refractile edge, which may be of significance as indicating a condensation of the cell structure. Under the action of heat (above 52°C.) the erythrocyte assumes various bizarre shapes (oval, spherical, kite-shaped, surrounded by small adherent "chaplets of pearls"). Loss of elasticity permits a cell to be broken up like a globule of mercury, and numerous small spheres with or without hemoglobin ("fragments") are found. These changes are thought to be due to coagulation of the stroma by the heat and are irreversible (Jolly).

To obtain any conception of the elasticity of the erythrocyte and of the wear and tear to which it is constantly subjected it must be seen in actual circulation, as may be easily done in the capillaries of the mesentery, or base of the finger nail. Especially when a cell gets astride the fork of a branching vessel, it receives a buffeting that distorts it greatly, and yet on release it at once assumes the normal disc-like shape. What effect, however, such an occurrence has on its subsequent existence, is an item of which we are in complete ignorance.

4. *Structure:*

The nature of the internal structure of the mammalian erythrocyte is at present receiving considerable attention, which can hardly be more than

outlined in this presentation. From one point of view (Price-Jones, Decastello and Krjukoff) it is to be considered as a small jelly-like substance of homogeneous design, holding hemoglobin and its attached substances within the minute interstices of a relatively dense stroma. At the other extreme is the concept of a vesicle with a membrane containing fluid hemoglobin, an idea that is difficult to reconcile with the hemoglobin-bearing fragments shortly to be described. From an intermediate standpoint, which seems to have the best supporting evidence, the erythrocyte is to be considered as a balloon containing its elastic stroma and functioning substance as relatively fluid colloid with a covering consisting of a condensation of the lipoid and protein stroma, which gives the effect of a delicate membrane (Ponder, 1924; Mudd, 1926, and Salén, 1920).

In favor of the first viewpoint is chiefly the observation that erythrocytes can be divided without an outpouring of any fluid contents. In disease, too, hemoglobin particles of various sizes and shapes are found, which are taken to be fragments of effete erythrocytes (Ehrlich's schistocytes). It is on such findings that Rous' (1923) explanation of the method of removal of erythrocytes from the circulation is based. The opponents of this view, however, feel that its experimental support is negatived by the fact that any such tampering kills the cell with immediate coagulation of contents, which cannot therefore be taken as examples of normal behavior. They feel, too, that the clinical observations might be explained by the gradual condensation of cytoplasm to form a new envelope about the periphery of the newly forming fragments—a view which also has some support in experimental observations.

A definite membrane ("strie bordante") undoubtedly exists in the erythrocytes of some lower animals, and Seifriz has recently shown in the erythrocyte of the hellbender a similar envelope which when torn by microdissection allows escape of the contained pigment. He says that a similar but more delicate structure is detected in mammalian erythrocytes. Michaelis, too, maintains that the contents run out visibly when the surface is scratched. A further argument in favor of a peripheral lipo-protein condensation is Jolly's observation that with certain stains (gentian and methyl violet) a narrow peripheral zone can be observed and that after treating with a lipoid solvent this zone becomes paler and granular. By studying the electric capacity of erythrocyte suspensions, Fricke (1925) determines that this zone is 3.3×10^{-7} cm. deep, which is about the length of a single molecule of lipin. Others consider it bimolecular (Gorter and Grendel, 1925) in thickness; still others, of greater and varying thickness.

Mudd's (1926) experiments with the "interfacial tension method" indicate that "the surfaces of normal erythrocytes contain in large amount, but not exclusively, non-polar, presumably lipoidal substances" which may be considered to exercise the effect of a limiting membrane. For

instance, when an oil drop pushing an aqueous solution along a slide overtakes suspended erythrocytes, they are quickly taken into the interface, there pulled into a lens shape and readily pass into the oil phase. Erythrocytes sensitized to specific sera, however, do not readily enter the oil phase but stay in the interspace for long distances and if agglutinated and anchored to the slide, various prolongations of the dragged cell ("tail phenomenon") are accentuated, or a cell may even be pinched in two. This is interpreted as evidence of a surface pellicle, which in fact can often be seen wrinkled in these preparations; that it contains a lipoid solvent, and that the sensitizing agent alters lipoid elements in this surface so as to make it more difficultly miscible with oil. Agglutinins, however, appear from this work to combine predominantly with the protein of the red cell surfaces, as Landsteiner had previously maintained.

By complicated mathematical treatment of the changes that occur in distending a spheroidal body like a balloon, possessing an elastic membrane, Ponder shows that the experimental figures obtained for the erythrocyte agree in a striking manner with the theoretical figures obtained, so that he believes that a fluid or semi-fluid interior must be assumed and that the idea of a dense sponge-like structure is not tenable.

Ultramicroscopic examination of the erythrocyte fails to reveal anything as to its structure. Neither with the dark field (Salén, 1920) nor with ultraviolet light (Grawitz and Gruneberg, 1906) was it possible to find anything but a quite homogeneous structure.

5. Size of the erythrocyte:

For many years it has been customary for textbooks to state that the human erythrocyte is about from 7μ to 7.5μ in diameter. As a matter of fact, the average size in the fresh state is probably considerably higher (8.8μ, Ponder and Millar, 1924) and the normal variation is considerably greater than 0.5μ (6μ to 9μ). No true average figure can ever be reached even for an individual, as the size of the erythrocyte is constantly varying within detectable limits under changing conditions. One of the most important of these is a change in the P_H of the plasma, in that a reduction in alkalinity increases the size of the corpuscle (Price-Jones, 1920). Corpuscles of venous blood are therefore larger than those of arterial, and any condition producing acidosis should increase their size. Price-Jones discovered a regular diurnal variation (of more than 0.5μ) that was not abolished by rest in bed. The corpuscles were smallest in the early morning and reached their maximum at bedtime. He and also Van Heukelom (1925) found that their size was increased by exercise and diminished by hyperpnea, both changes being less than 1μ. The latter found the average size of normal male corpuscles (in the fresh state, of course) to vary between 7.14μ and 8.3μ

and of females, 7.6μ and 8.5μ, and found an average variation of 0.4μ in different parts of the day. All such estimations come unpleasantly near the limit of microscopic visibility, 0.2μ, and are open to the further objection,

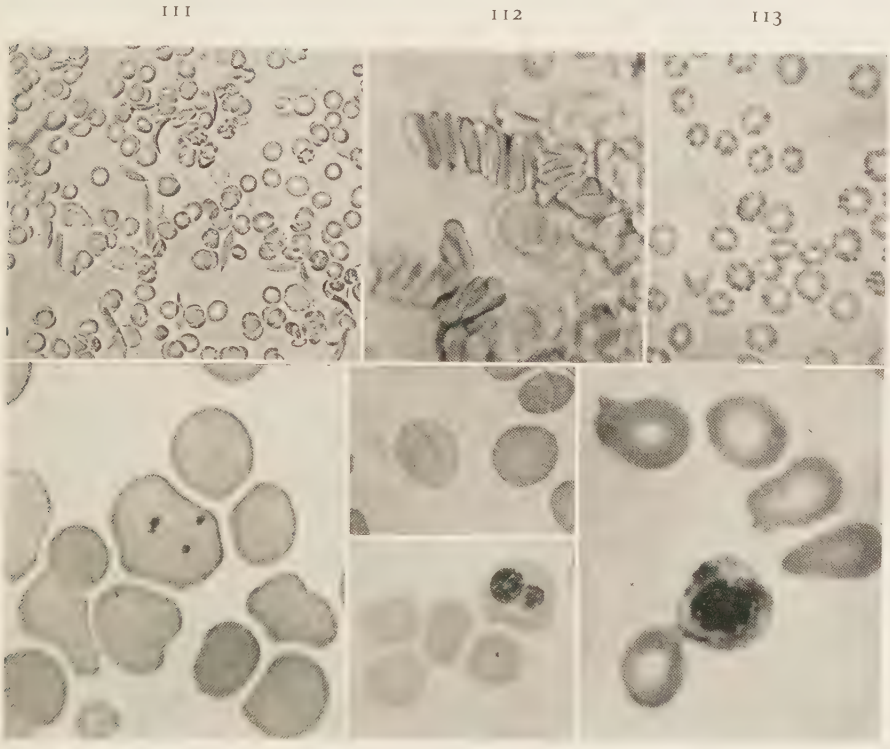

FIGS. 111–117.—111. Rouleaux in normal blood. 112. Crenation of normal blood in hypertonic solution. 113. Megaloblasts from pernicious anemia. 114. Normoblast with a typical nucleus. 115. Nuclear fragments in pernicious anemia. 116. Cabot ring forms in pernicious anemia. 117. Sickle cells in a newly made fresh preparation from a case of sickle cell anemia.

as Ponder has shown, that the first changes in shape that occur in the corpuscle are apt to be toward a more spherical form, which would tend to vitiate small differences based on measurement of diameter alone.

Changes in volume may in some cases be due to actual loss of protein. Thus Descamps (1925) found that after peptone shock and intravenous administration of hypertonic solution of glucose a diminution in volume of dog's cells occurred with loss of protein. Zunz (1925) also discovered that the erythrocytes of dogs diminished in size in anaphylactic shock, but those of guinea pigs increased, due to a corresponding change in protein content in each case.

The immature cell has long been known to be larger than the adult form. Thus for the white rat, Jolly observed that in a 16 mm. embryo it measured 9.7μ; at birth, 8.3μ; eighth day, 8μ; fifteenth day, 7.9μ; thirtieth day, 6.7μ; three months, 6.6μ; and the same has been found for the cat, goat, rabbit and man (Saragea, 1922). At birth he found an average diameter of 8.6μ; at one month, 8.1μ; adult, 7.5μ (presumably in dried stains). The rise in the aged he considers due to various physico-chemical causes.

TABLE 1

SIZE OF HUMAN CORPUSCLES AT DIFFERENT AGES (SARAGEA, 1922)

Age	Size in μ
Birth	8.6
10 days	8.3
1 month	8.1
2 months	7.7
6 months	7.5
18 months	7.1
5 years	7.2
15 years	7.7
20 years	7.8
30 years	7.6
40 years	7.5
50 years	7.5
60 years	7.8
70 years	7.8
80 years	7.7
90 years	7.7

In the various diseases that affect the blood, as one might expect, the volume changes considerably. In pernicious anemia, especially, where there is a disordered development of the erythrocyte directly from the megaloblast, the increased diameter of the cells and increased number of megalocytes becomes of diagnostic significance. Thus in 11 cases Van Heukelom (1925) found a diameter ranging from 8.8 to 10.5μ as opposed to a normal of 7.1μ to 8.5μ. It might be pointed out that for maximum rapidity of diffusion of gaseous contents this larger size is less efficient than the normal. This is shared to a lesser extent by some other anemias, and is found in myxedema and congenital cyanosis (Vaquez, 1902). In hemolytic jaundice, on the other hand, Chauffard's (1907) observation that microcytes predominate has been frequently confirmed. It has not been made clear whether this diminution in size is due to a small cell being formed in the first place or to division of cells in the circulation (Ehrlich's schistocytes). Whitcher's (1925) observation

that the microcyte of hemolytic jaundice tends to return to normal size after splenectomy, while not throwing much light on the mode of production, at least indicates that the condition is not a congenital anomaly.

Although these variations can usually be detected in dried smears as well as fresh preparations, it must be recalled that drying causes a noticeable shrinkage (about 1μ), and as Ponder showed, stained dried cells lose 1μ further in diameter. This is not recognized by Wiechmann and Schurmeyer (1925), who, however, find the same relative changes from their normal average of 7.9μ, as do the former observers. Considering the cell as a flat disc, they note that from the diameter a sufficiently accurate surface area can be got by the equation, S.A. $= 2\left(\frac{d}{2}\right)\pi^2 = d^2 \times 1.57$ (d, equalling the diameter).

The size of erythrocytes varies considerably in mammals as well as in other orders, for reasons that are not clear. As the surface area of all the erythrocytes of the body is assumed to be proportional to the metabolic needs of the animal, in mammals the size should be in inverse ratio to their number; while this holds true between hot- and cold-blooded species, it does not seem to within the mammalia. In camels the erythrocyte is an oval disc

TABLE II

SIZE OF ERYTHROCYTE IN VARIOUS SPECIES (JOLLY, 1923)

Species	Size in μ (Dried Cells)
Elephant	9.1
Man	7.5
Dog	7.3
Guinea Pig	7.0
Rabbit	6.5
Pigeon	6.1
Cow	6.1
Cat	6.0
Horse	5.7
Sheep	5.0
Goat	3.7

which circulates by turning on its long axis. Fish, reptiles, batrachians and birds have oval, nucleated erythrocytes, often attaining great size (e.g., proteus, 58μ × 34μ). They possess a resistant outer layer (Ranvier's "strie bordante"), which makes them assume bizarre shapes and wrinkles when submitted to changed conditions of surface tension.

6. *Number of erythrocytes:*

The number of red blood corpuscles in the human adult is usually placed at 4.5 millions per cubic millimeter for women and 5 millions for men. This

would place the number of cells in the average adult at approximately 4.75 millions per cubic millimeter with a total number in the body of the order of 25 trillion. Even more than in the case of the diameter of the cells, however, such factors as age, diet, habit, race, climate, geographical habitat must be recognized as playing their part in influencing departures from this average. As Gruner (1920) points out, "it is more important to realize that all these conditions produce changes in the blood than to tabulate the changes fully." The figures given above are probably low for really normal individuals. Thus Bing (1919) found the average for men under fifty was 5.5 millions (limits 4.1 to 6.1 million) and for women under fifty, 4.95 millions (limits 4.0 to 5.8 million), confirming conclusions reached by Bie and Moller (1914) with a different method. Mayers (1922) states that the average of the results of numerous investigators may be placed at 5,742,000. There is a polycythemia at birth and this increases in the first twenty-four hours, but drops in the first year to a figure below the adult average, as is shown in the following chart.

In old age, although Hansen (1919) found no significant change, Bing's studies of 22 men and 21 women over sixty, all relatively normal, showed that though variations were greater, the average was really somewhat higher (men 4.9 to 9.8, average 6.1 millions; women 4.2 to 6.4, average 5.1 millions). The great difficulty in all such studies, of course, is to include only normal subjects.

Besides the numerous possible errors in technique of counting erythrocytes,* changes from the arbitrary standard may be produced by a number of physiological variants. Thus Bing finds that there are considerably more corpuscles per cubic millimeter in the capillary blood of the abdomen than in that of the ear; that exercise and assimilation of liquid will cause a rise of several hundred thousand, although, as we shall show later, Brown (1922) has demonstrated that exercise is accompanied, as one might expect, by an increased amount of blood cell destruction. While the arterial blood has a relatively constant number, in the veins and capillaries it is somewhat higher, though less so in the main trunks. The higher content is especially marked in the veins coming from the skin, muscles and glands. In the marked increase in number that accompanies life in high altitudes, while the initial increase may be mostly explained by mobilization or redistribution, undoubtedly new cells are formed in increased numbers in response to the lessened oxygen tension.

In all such changes but the last named it is probable that it is more a question of redistribution of corpuscles rather than an actual increase in the

* We have counted sixteen possible sources of error with the method almost universally in vogue in this country, which if all were cumulative might easily produce a total error of more than 40 per cent without any one item passing a reasonable "limit of error." Limitation of space prevents the inclusion of these unpublished data.

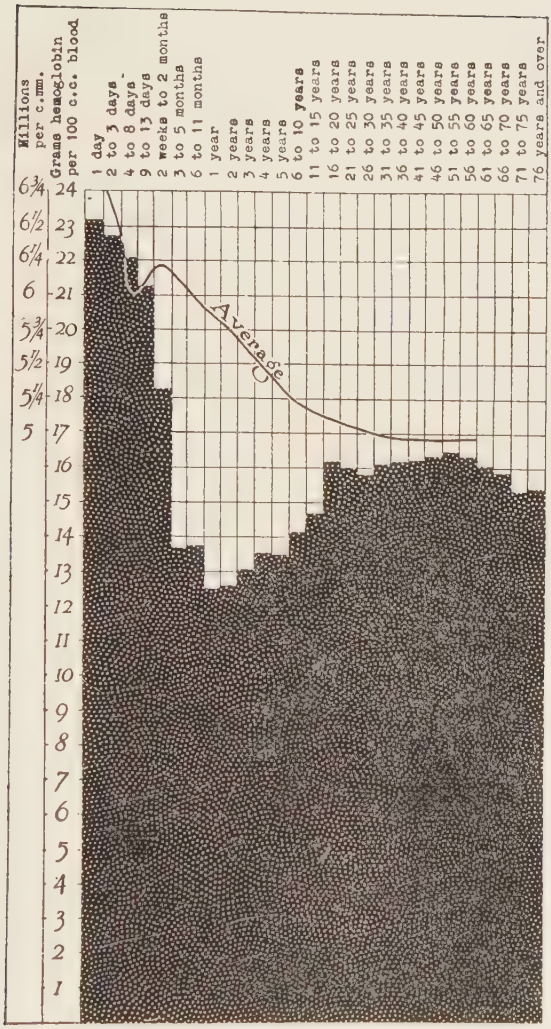

FIG. 118.—Hemoglobin and red cell values at different ages (man). The solid black plateaus indicate grams of hemoglobin per 100 c.c. of blood in persons ranging in age from one day to over 76 years. The curved line shows the average erythrocyte count at different ages to show the relationship between the number of erythrocytes and their hemoglobin content. (After Mayers.)

number of cells in the body. Lamson (1915) has demonstrated the effect of adrenaline in this regard and also pointed out that the unequal distribution of red cells through the vascular system of the body constitutes a large source of error in the prevalent methods of estimating blood volume.

7. *Amount of hemoglobin:*

From the earliest attempts of Leichtenstern (1878) to establish an average level of hemoglobin for the blood of normal individuals to the

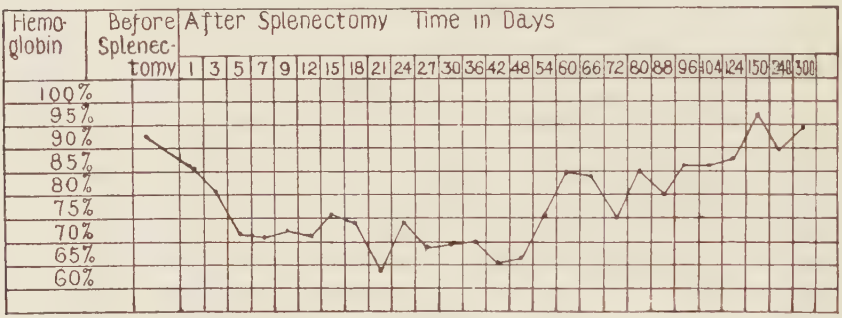

Fig. 119.—Homoglobin values after splenectomy. Average from seven dogs.

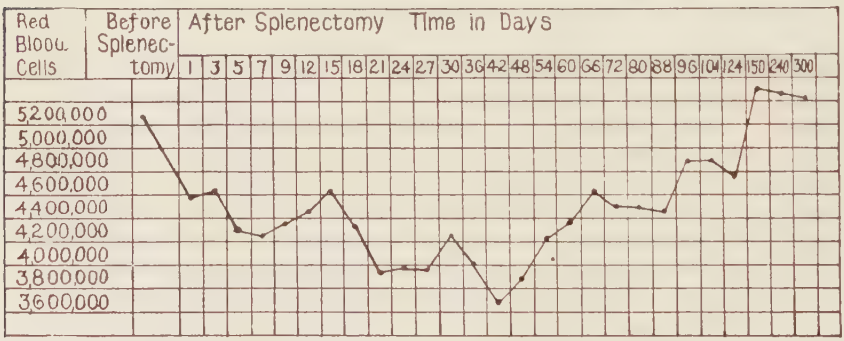

Fig. 120.—Erythrocyte values after splenectomy. Average from seven dogs.

present time, no standards have been generally accepted; and this widely used clinical test has suffered correspondingly in consequence. Leichtenstern's figures (ranging from 11 to 21 gms. per 100 c.c.) at least possessed the virtue of expression in terms of grams per 100 c.c., whereas clinical reports now almost universally are given in percentages of some usually unstated standard. In the most popular standard (Haldane's) 100 per cent is fixed at 13.8 gms. per 100 c.c., whereas the most careful recent work (Williamson, 1916) shows normal adults' blood to average over 16 gms. per 100 c.c. Like the number of corpuscles, the values are high for the first few weeks of life, then drop below the general average until a fairly constant

level is reached by the eleventh year. While the greatest care was used by Williamson in securing pure standards of hemoglobin and normal subjects in adequate numbers for study, this figure has seemed too high for general adoption by the clinician. For those who must think of hemoglobin in terms of an arbitrary percentage, Haden's (1923) average of 15.6 gms. seems most satisfactory for the male; we have found it practically possible in hospital work, however, and certainly theoretically preferable, to report all hemoglobin in grams per 100 c.c., and allow the clinician to form his own concept of the relative value, as automatically as he has always been able to do with the enumeration of red and white cells in the blood.

The extreme and important changes in the number of erythrocytes and hemoglobin values that may occur in disease and the reasons therefore are beyond the scope of this presentation. In the anemias, figures as low as a few hundred thousand cells per cubic millimeter and less than one gram of hemoglobin are found, while in polycythemias counts above thirteen million have been reported (experimentally, Lamson (1915) found a maximum of sixteen millions in a cat).

8. *Surface area and volume of the erythrocyte:*

Welcker's (1863) original figures for the surface area of the erythrocyte, 128 sq. μ (expressed in square millimeters, as the term micron was not then in use) seem still to be as good as any (123 sq. μ, Bailey, 1925). From this may be calculated an area of 640 sq. mm. per cubic millimeter of normal blood, or the enormous figure of 2816 sq. m. for all the blood cells of the body (of which 81 sq. m. pass through the lung per second). Other calculations are even higher, but of the same order: Evans (1925), 3500 sq. m.; Bailey, 4500 sq. m.

Welcker estimated the average thickness of the human erythrocyte at 1.7μ; by comparison with plaster models of the same shape as the erythrocyte, he was able to estimate the volume of a normal cell at 72 cu. μ. This compares favorably with the most recent estimations by Ponder of 110 cu. μ.

The hematocrit method of determining the ratio of blood corpuscles to plasma was first introduced by Heden in 1891, who found that the corpuscle occupied about 50 per cent of the total volume of the blood. It was put to use by Capps (1903) in connection with his "Volume Index"—an estimate of the average size of the individual's erythrocytes obtained by dividing the relative volume of the corpuscles in a hematocrit determination by their number per cubic millimeter (both expressed in percentages of the normal). For instance, if 5 millions per cubic millimeter is considered the normal number and 50 per cent the normal relative volume, blood with 2.5 millions per cubic millimeter and 25 per cent corpuscles in the hematocrit would still have a volume index of one. This determination is of clinical

importance, as Gram (1921) has shown that changes in the color index are due more to volume changes than to changes in the number of cells; wherefore both are high in pernicious anemia. Normal volume percentages have been found to vary from 40 per cent (Campbell), 42 per cent (Gram), 48 per cent (Capps), to 50 per cent (Larrabee, 1911).

"Color Index" is a term used to express the average color intensity of the corpuscles of a given blood. It is obtained by dividing the percentage of hemoglobin by the number of erythrocytes per cubic millimeter (expressed on a percentage of normal—5 millions). Thus blood with a hemoglobin of 60 per cent and a count of 2.5 millions would have a color index of 1.2. As will be seen in the former paragraph, it is also an approximate indication of the average size of the cells in question.

9. *Suspension stability (sedimentation rate):*

In 1921 Fahraeus, of Stockholm, published results of studies of the velocity of sedimentation of erythrocytes of citrated blood of pregnant women, as compared with that of men and non-pregnant women. This test, which seemed to present a valuable method for clinical diagnosis, has provoked an extraordinary number of papers, chiefly in the German literature, which already permit adequate discussion of certain features.

The sedimentation rate is said to be diminished by an increase in blood chlorides, by carbon dioxide, by thyroidectomy and with the diminished fibrinogen content following splenectomy. It is increased in fevers, pregnancy, hyperthyroidism and by alcohol and irradiation and is independent of the cholesterol content of the blood. The underlying cause for the differences in sedimentation rate is explained on two different theories, neither of which can be said to be definitely proved. Fahraeus observed that rouleaux formation and aggregation of cells increased the velocity of sedimentation. In such aggregations he found small, transparent, circular zones which he took to be autohemolyzed erythrocytes, which attracted other cells by chemotaxis, and that the number of these cells was in direct proportion to the speed of sedimentation. This is readily explained by Stokes' law that "the sedimentation velocity of the corpuscles in a suspension of globular elements in fluid is proportional to the square of their radius."

On the other hand, erythrocytes are known to carry a negative charge (Höber, 1922), and Schürer and Eimer (1921) found that the migration to the anode occurred more quickly in the blood of healthy individuals than in conditions where the sedimentation rate was increased (fevers and pregnancy). This has also been shown to occur where the plasma globulin is relatively increased at the expense of the plasma albumin, a condition in which Höber finds a lessened negative charge in the cells. In other words, with an increased proportion of plasma globulin, the negative charge of

the cells is diminished and increased speed of sedimentation results. This diminished charge also increases the viscosity which in turn should promote agglutination and speed the rate, as in Fahraeus' theory. The composition of the corpuscles themselves must also be considered. The quickly sedimenting corpuscles of the horse, for instance, retain most of their speed when tested in ox plasma (a slowly sedimenting species). Oliver and Barnard (1925) find that rabbits' cells in isotonic cane sugar, or in a low concentration of electrolytes, behave as suspended colloids, in that the stability of the suspension depends on the charge of the cells; but in high concentrations of electrolytes they behave as emulsoids, as the stability is here independent of the charge. They found that globulin also acted in this way and conclude that the surface of the erythrocyte is chiefly globulin, which affects the suspension stability by dissolving out in high electrolyte concentrations.

From the clinical aspect, the rate has been found increased in so many conditions —like fever, leucocytosis and similar conditions—that its value in diagnosis is greatly restricted. The decreased rate in asphyxia is thought to be due to the increase in size of the erythrocytes caused by the increased carbon dioxide content of the blood. Being increased in all conditions of increased protein metabolism, it cannot be used to distinguish between fevers, late pregnancy, allergy, many kidney diseases and so forth and only in repeatedly negative tests can it be used to rule out inflammations and degenerations. As an aid to prognosis, however, and especially in chronic pulmonary tuberculosis, the curve obtained from repeated tests under standard conditions seems to have a definite value.

II. CHEMISTRY OF THE ERYTHROCYTE

In Carl Schmidt's (1902) venerable analysis of normal adult male human blood—still one of the best available—the corpuscles weighed 513.02 gms. per thousand, of which water accounted for 349.69 gms., "blood casein" (i.e., lipoids, stroma, etc.?) 151.89; hematin, 7.70; inorganic constituents (excluding iron) 3.74 gms. By a modification of the Bleibtreu method, Steinbach (1922) has recently found the water content to be considerably lower (57.5 per cent) and it is almost certain that other items need similar revision. Thus Macallum (1926) considers that Schmidt's estimates for sodium and potassium are at least 10 and 40 per cent respectively in excess of modern estimates.

The chief component of the erythrocyte (eight to nine-tenths) is a solution of hemoglobin crystals—a conjugated protein of high molecular weight (in man about 16,669), with an estimated formula of $C_{758}H_{1203}N_{195}S_3FeO_{218}$. The name hemoglobin was coined by Hoppe Seyler. The elements Na, K, Mg, Ca, Cl and P are also constituents of the corpuscle. Calcium, which has been much studied recently on account of its relation to tetany and parathyroid function, exists in small or insignificant amounts in the corpuscles or may even be entirely absent. Thus Cruickshank (1923) finds an average of 9.12 mgms. in the whole blood of normal dogs, of which 1.01 mgms. are in the corpuscles.

If it is true that there is one atom of iron to each molecule of hemoglobin (0.34 per cent by weight), this would allow a molecular weight of 16,693 (Mathews, 1925). According to recent investigations, however, it seems probable that there are four atoms of iron in each molecule (Adair, 1925; Svedberg and Fahraeus, 1926). The hemoglobin mole-

cule is easily broken up into an iron-containing pigment, hematin ($C_{34}H_{34}N_4O_5Fe$ Hoppe-Seyler) (4 per cent) and a sulphur-containing protein, globin (96 per cent). These are probably simply combined as an acid and base. Hematin in turn can be obtained in a crystalline form, as hemin (hematin hydrochloride), by treatment with hydrochloric acid, and when reduced forms hemochromogen. This and hematin correspond to the terms "reduced hem" and "hem" recently introduced by Anson and Mirsky (1925). Heated with strong acid, hemochromogen forms an iron salt and hematoporphyrin (isomeric with bilirubin), a pigment found in various animal tissues, and occurring in human urine in small amounts normally, but increased in sulphonal poisoning and other pathological conditions.

Hemorlobin can readily be obtained in crystalline form, and, as was shown by Reichert and Brown (1924), each animal species has its own distinctive form of crystal; even more—crystals of related animals are so similar that the method might be used as a means of classifying relationships. Landsteiner and van der Scheer (1924), too, have found that animal precipitins resulting from injections of hemoglobin from different species permit similar gradations.

The composition of the stroma is more poorly understood. According to Abderhalden, the total lipins constitute from 0.34 to 0.77 per cent of the corpuscular weight in different mammals, of which phospholipin predominates over cholesterol, but the proportions apparently vary considerably in different species and individuals. Under the discussion of the structure of the erythrocyte, some evidence for the presence of proteins in the stroma has been discussed, but no quantitative figures appear to be available. From one kilo of red corpuscles Beumer and Burger (1923) got 22.6 gms. of dry stroma. They found that the ratio of cholesterol to phosphatides was relatively constant, and that most of the latter were sphingomyelin and cephalin, an ether soluble diamino phosphatide and a water soluble phosphatide. Lecithin was present in very small amounts and cerebrosids have also been found.

The erythrocyte, compared to some of the other cellular elements of the blood, is poorly equipped with ferments, although possibly these may be concerned with the oxygen-CO_2 exchange in some way not now understood. Glycolase exists only in the corpuscle. That it contains catalase can readily be demonstrated by the addition of cells to hydrogen peroxide with the free liberation of oxygen.

That the red corpuscles normally contain glucose in amounts equal to or slightly less than that of the plasma is an opinion held by most investigators (Tachau, 1914; Gradwohl and Blaivas, 1916; Bailey, 1919; Wishart, 1920; Bonniger, 1921; Folin and Berglund, 1922), although denied by Falta and Quittner (1919) and Brinkmann (1920), who consider that the red cells only take up sugar from the plasma after they have been damaged. More recent studies hardly leave this position tenable. In diabetes, John (1923) finds that while the corpuscular content is slightly less than that of the plasma, when washed cells are exposed to hypertonic solutions, they take up even more sugar than do normal cells.

It has been previously noted that ultramicroscopic study of the untreated erythrocyte failed to throw any light on its internal structure. If, however, preparations of stromata are treated with acetone (cholesterol solvent), saponin and alcohol (protein precipitant), Salen (1920) has found that in the dark field the fainter appearance of the cell indicates the loss of a lipoid; and the eventual formation of a ring-like structure with fine granules in the periphery indicates the albuminoid factor which Bechold and Kraus (1920) had previously found by chemical means. It is believed by Conant and Scott (1926) that much nitrogen is dissolved in hemoglobin salts by adsorption and in fact that a definite chemical equilibrium controlled by adsorption is a phenomenon of wide application in biological material.

III. FUNCTION OF THE ERYTHROCYTE

The currently accepted view of the mode of action of hemoglobin in transporting oxygen and carbon dioxide—now fairly stabilized on the work of L. J. Henderson (1924, 1925), Van Slyke (1921 to 1923), Y. Henderson and Haggard (1920), Barcroft (1924, 1925) and others—involves at least six simultaneous variables: free and combined oxygen and CO_2, the hydrogen concentration and the chloride concentration of the serum. The participation of the red corpuscle can perhaps be expressed by following one cycle of the circulation, although it must, of course, be remembered that the plasma also plays its part. At the P_H of the blood the weak acid hemoglobin is present in the corpuscle as varying amounts of sodium hemoglobinate (reduced), sodium oxyhemoglobinate and free acid. In the lung capillaries, the greater tension of oxygen from the alveoli causes its diffusion into the erythrocyte, where it enters into chemical combination with the hemoglobin, increasing the amount of the more acid oxyhemoglobin. The carbon dioxide then, which as will be seen later exists within the cells chiefly as sodium bicarbonate, loses its sodium to the hemoglobin molecule and diffuses out of the cell to be exhaled through the lungs. Sodium chloride also loses its sodium, but, the erythrocyte being peculiar in being freely permeable to anions and almost impermeable to cations,* the chloride passes into the plasma ("chloride shift," on the basis of the Donnan equilibrium). As the cell in its passage around the circulation reaches areas with more and more carbon dioxide and less and less oxygen (the difference being, of course, less marked in inactive tissues), carbon dioxide from the tissues diffuses into the plasma and the cell at relatively high tension. This is sufficient to drive off oxygen, which is at relatively high tension within the cell and the less acid hemoglobin liberates base to join with the carbon dioxide and causes a return of chlorine ions from the plasma. The CO_2 thus travels in combination with base, of which half or more is supplied by the hemoglobin change, the remainder by the buffer action of these acids. As the oxygen tension in the cell is reduced, oxyhemoglobin dissociates into oxygen and hemoglobin, which is less acid than the oxyhemoglobin (though both are weak acids). The entrance of CO_2 from the tissues (increasing acidity) promotes dissociation, thus increasing O tension and facilitating oxygen diffusion (Wilson, 1923, p. 302). Henderson and Haggard (1920), have shown that the erythrocyte is also capable of manufacturing bicarbonate when in a solution of sodium chloride, and thus aids in maintenance of neutrality.

* It is commonly stated that H and NH_4 are exceptional cations in penetrating the erythrocyte; but there is a possibility that this exception is only apparent, in that in the case of H the same results could be obtained by a permeability to OH and (as M. H. Jacobs' unpublished experiments show) there may be another way of accounting for the NH_4.

Evaluation of the various buffers of the blood can be found in the work of Doisy, Briggs, Eaton and Chambers (1922).

If the chief function of hemoglobin is to carry oxygen and carbon dioxide to and from the tissues, why is it not circulated in solution in the vascular fluid, as is its homologue in many lower forms of life, or as Barcroft (1922) recently put it, "What is the Raison d'Être of the Red Corpuscle?" He gives a twofold answer: In the first place, he found that in spite of its high molecular value, a solution of hemoglobin at the hydrogen ion concentration of the blood has an osmotic pressure of nearly 140 mm. mercury—a value so much higher than capillary blood pressure that the present system of body function would be quite impossible unless a counter substance were opposed outside the vessels. This, however, to be feasible, would have to be of low molecular weight, so as not to be too bulky, in which case new difficulties would arise through the need for keeping it in place by having smaller channels through the capillary walls. These difficulties are solved by packing the hemoglobin into corpuscles, which permits larger meshes in the capillary walls, obviates an impossibly high osmotic pressure and keeps the viscosity of the blood within desirable limits. As Barcroft also points out, it actually increases the efficiency of the hemoglobin by protecting it from sodium chloride—in which it would function with less efficiency than in phosphate - and also the slightly more acid reaction of the corpuscle is a more delicate point for the hemoglobin-oxygen reaction than is the P_H of the plasma.

That normal mature human erythrocytes are more vehicles for the processes just described than metabolizing units like the other cells of the body, is indicated by Harrop's (1919) failure to find any measurable oxygen consumption. In anemic blood, however, with the presence of nucleated forms, a distinct amount of oxygen was found to be consumed, similar to Warburg (1909) and Morawitz's (1913) earlier findings in experimental anemias and in the nucleated erythrocytes of birds. Of interest, too, is Harrop's observation that the amount of oxygen consumption varied directly with the percentage of reticulocytes in the blood.

IV. HEMOLYSIS

The hemolytic changes that occur when red blood cells are immersed in hypotonic salt solutions have already been mentioned. The accurate study of these phenomena dates chiefly from the work of Hamburger (1902), who determined the strengths of solutions of sodium chloride at which hemolysis was first observed and at which all cells are destroyed. This method is frequently employed today as a clinical laboratory test of the resistance (or fragility) of the erythrocytes, it usually being considered that hemolysis begins at from 0.44 to 0.48 per cent NaCl (minimum resistance) and is complete at from 0.34 to 0.40 per cent (maximum resistance).

Minimum resistance in the rabbit is estimated at 0.52; rat, 0.56; cow, 0.66, sheep and goat, 0.74 per cent NaCl, and is somewhat similar in birds and fish (Vallery-Radot and L'Heritier, 1919). In our own studies, both dog and monkey showed the same minimum and maximum resistances of 0.46 and 0.33 respectively. Contrary to earlier opinions that the larger the mammalian cell the weaker was the resistance to hypotonic salt solution, it now seems as if the species with the smallest cells had the least resistance. The

TABLE III

COMPARISON OF SIZE AND RESISTANCE OF WASHED ERYTHROCYTES IN VARIOUS MAMMALS (VALLERY-RADOT)

Species	Size in μ	Minimum resistance in per cent NaCl
Man	7.6	0.42–0.48
Guinea pig	7.5	0.44–0.46
Monkey	7.2	0.44
Dog	6.6	0.50–0.54
Rabbit	6.3	0.52–0.54
Horse	6.2	0.54–0.58
Rat	6.0	0.54–0.56
Cat	5.6	0.60–0.66
Goat	5.3	0.72–0.74*

* The discrepancies in the various figures quoted show how much the issue can be complicated by difference of methods and individuals.

large nucleated erythrocytes of the lower species are distinctly more resistant (0.24 to 0.30, batrachians; 0.24 to 0.38, reptiles). In hemolytic jaundice, where the test is practically pathognomonic of the condition, Chauffard's (1907) observation that the erythrocytes are more fragile have been frequently confirmed the range of hemolysis being shifted perhaps as far as 0.70 per cent (beginning) and 0.54 per cent (complete) (Pearce, Krumbhaar and Frazier, 1917). There is no question also but that there is a marked increase in resistance following splenectomy in this disease, as well as under experimental conditions. In other anemias the resistance of the erythrocytes is increased. It is thought that this is due to the increased number of young cells in the circulation, although it has never been satisfactorily proved that while there are obvious differences in resistance of the cells of a given sample, reticulocytes, for instance, are more resistant than more mature cells. Solutions at which no hemolysis occurs are known as isotonic (approximately equal molecular concentration) and though the concentration varies with different salts, the level for each remains constant. Thus, for example, equivalents of 0.60 per cent NaCl are 1.15 per cent K_2SO_4; 3.52 per cent $MgSO_4$ (Jolly); and even higher

figures for the sugars. The isotonic strength varies for different species, thus employing KNO_3 for cow's erythrocytes, a 1 per cent solution being used; birds, 0.7 per cent; fish 0.6 per cent; frog 0.3 per cent (Hamburger).

The mechanism of hemolysis by hypotonic solutions is still far from clear, as might be expected in view of our incomplete knowledge of the structure of the erythrocytes. Against the simplest view that in an attempt to equalize the osmotic pressure the cell swells till it bursts, is the fact that laking may occur without such rupture being observed and apparently intact "ghosts" remain after hemoglobin has completely passed out, although it is possible to conceive of a swelling which stretches the limiting substance sufficiently to allow passage of the large hemoglobin molecules through its pores. It is possible to produce hemolysis with hypotonic solutions of cells where swelling has been prevented by partly fixing with osmic acid or formalin; but on the other hand, such cells can no longer be considered as living normal cells. A loose chemical union of hemoglobin with stroma has been assumed, so that hemolysis would be due to rupture of this union by hydrolysis; but this does not fit the relatively slight solubility of hemoglobin nor hemolysis by trauma, alternate freezing and thawing and so on. The most generally held belief to-day is that the hemoglobin is attached to the cell by a loose union of a physicochemical nature and that interference with either factor may result in hemolysis.

Hemolysis may, of course, be produced in many other ways than by hypotonic solutions. Weak acids and bases (presumably by the action of their more completely dissociated ions); alcohols, ethers, aldehydes and acetone (presumably by their solvent action on the lipoids of the stroma); bile salts and salts of the fatty acids (e.g., sodium oleate), (which completely destroy the stroma) and glucosides (such as saponin), all readily produce hemolysis. The action of saponin is more intense on cells suspended in salt solution than in serum, which is probably due to the presence of cholesterol in the serum, as when cholesterol is added to the salt solution, this difference disappears (Ransom, 1901). May (1914) found that clinically resistance to saponin hemolysis was often qualitatively different from that of hypotonic salt solution, (e.g., normal or decreased in severe anemias, decreased in obstructive jaundice, normal in hemolytic jaundice). In various experimental conditions studied by us, however (treatment with hemolytic serum, sodium oleate, toluylenediamine, effect of splenectomy), no such qualitative differences were observable.

In spite of numerous historical accidents from the transfusion of man with the blood of foreign species, this phenomenon seems not to have been investigated experimentally until Landois in 1875 showed the widely varying effects obtained by transfusing blood from the animals of the same, closely related and far distant species. Since that time an enormous amount of work, led by Bordet, Landsteiner and v. Dungern, Ehrlich and others

(far beyond the scope of this paper), has demonstrated the serological nature of the factors involved. Suffice it here to say that not only different species possess natural hemolysins for the erythrocytes of other species (varying approximately with the closeness of the relationship), but that even within the species, differences may exist.

In man this has produced the four well-known groups of Moss (1909), characteristics that are acquired soon after birth. In Jansky's earlier (1907) but less used classification, Moss' groups 1, 2, 3, 4, correspond to Jansky's 4, 2, 3, 1.

TABLE IV

CELL GROUPS (MOSS)

	Serum			
Corpuscles	Group 1	Group 2	Group 3	Group 4
Group 1	0	+	+	+
Group 2	0	0	+	+
Group 3	0	+	0	+
Group 4	0	0	0	0

+ = Agglutination and hemolysis.

As for clinical purposes, the more important item is the effect of the recipient's serum upon the donor's cells, the possessor of Group 1 blood may be considered a universal recipient and Group 4 a universal donor.

These groups are considered by Landsteiner to be due to arrangement of four unit characteristics (A and B, Mendelian dominants and α and β recessives), so that group 1 (Jansky) has the factors $\alpha\beta$; group 2, Aβ; group 3, αB; group 4, AB). The average distribution of the four groups (Moss) is about as follows: 1, 4 per cent; 2, 40 per cent; 3, 10 per cent; 4, 46 per cent; although important variations are known to exist in different races (Ottenberg, 1925; Coca and Deibert, 1923). Thus Landsteiner found the A factor to predominate in western Europe, the B factor in the Orient and the American Indian is said not to have either. It should be recognized that untoward accidents with properly tested compatible groups indicate the possibility of important subdivisions (Guthrie and Huck, 1923, 1924), while there is some evidence that leucocytic incompatibilities may be capable of causing trouble.

Among animals, in the higher apes only have groups been identified and these are said to have the same four as does man (Landsteiner and Miller, 1925).

In addition to the natural hemolysins, animals may be stimulated to greatly increased amounts of acquired hemolysins by the repeated injections of foreign cells. In this way are not only hemolytic sera of high potency against other species obtained, but they may be developed de novo against cells of the same species, as the following chart indicates. The blood of dogs or rabbits receiving daily injections of blood from several compatible donors, increases in the number of cells and amount of hemoglobin, in spite of

practical cessation of blood formation and gradually increasing blood destruction. In a certain number, however, we have found that the plethora changes into a severe anemia, even though the daily transfusions are continued and hemolytic substances are developed which may even prove fatal to the individual.

A curious phenomenon—"reversible hemolysis"—has recently been observed (Brinkman and Szent Gyorgy, 1923), whereby suspensions of erythrocytes appropriately treated with linoleic acid may become transparent with apparent complete diffusion of the hemoglobin and yet on subsequent treatment with isotonic saline solution, the cells and the solution grossly resume their normal appearance. As it is extremely difficult to conceive that hemoglobin that has left the cell could be returned to that cell, the explanation has been offered that sufficient swelling of cells has been induced to give the solution a homogeneous "laked" appearance without actual loss of hemoglobin; so that when the

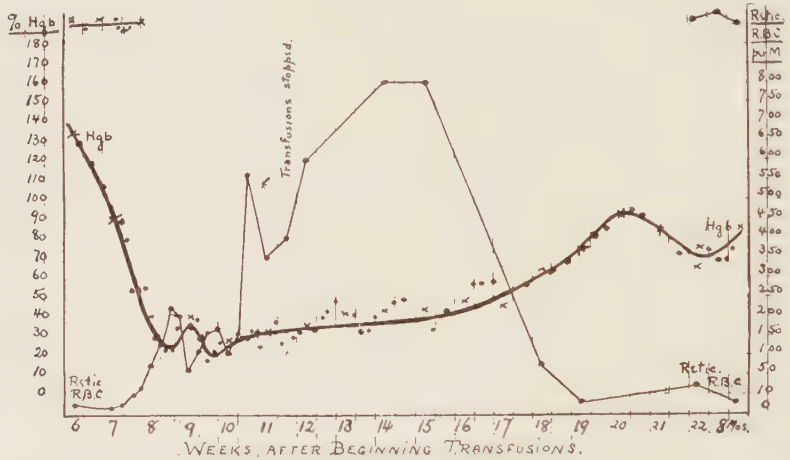

FIG. 121.—Development of anemia in plethoric dogs while receiving transfusions.

excess fluid is driven off, they and the suspension resume their normal characteristics. Brinkman, however, takes the phenomenon to indicate that the hemoglobin is not included in a vesicle but attached to the surface of the stroma. Although washed erythrocytes usually become slightly less resistant than the untreated cells (for which reason we have always used whole blood samples in our resistance experiments), Brinkman has found an increase in resistance after washing with a phosphate solution, which he thought due to the washing off of a hemolytic substance. It has recently been shown, however, that his solutions were slightly hypertonic and that the phosphate itself probably combined with the erythrocyte to make a more resistant compound (Schoep, 1925).

V. ORIGIN AND DEVELOPMENT OF THE ERYTHROCYTE

The great controversy as to the single (Pappenheim, Maximow, Ferrata) or multiple (Ehrlich, Naegeli, Schridde) origin of blood cells, which has

occupied so much of the time of a whole generation of hematologists must not and need not concern us greatly here.

1. *Monophyletic theory:*

Following Saxer's view that in mammalian embryos a basophilic mononuclear cell of mesenchymal origin, the "primary wandering cell," was the common ancestor of all blood cells, Pappenheim stated that in adult bone marrow a primary mononuclear cell of mesenchymal origin, the lymphoidocyte, was the ancestor of all blood cells, both white and red. This view, which has the support of Maximow, Ferrata, Danchakoff and in fact most hematologists to-day, is based chiefly on the facts that the further all blood cells are traced to their origin, the nearer they seem to come to an undifferentiated mononuclear cell with strongly basophilic protoplasm, and that all stages of transition between this primitive cell and the adult forms can be found. Many variants of this central idea can, of course, be found in the vast literature on the subject, but cannot be discussed here.

2. *Polyphyletic theories:*

There have been some, on the other hand, who have maintained two or more separate sources for blood cells—the polyphyleticists. Naegeli (1923), for instance, believed in a complete definitive separation of erythrocytes, lymphocytes and granulocytes even in embryo, although he allowed the persistence of undifferentiated mesenchymal tissue in the adult, which could differentiate in emergencies. He considered two immature cells—promegaloblast and pronormoblast—of which the former was only active in early stages of development or in certain pathological conditions.

Schridde (1907) described temporary primary erythroblasts formed intravascularly from endothelium, to be followed later by the basophilic erythroblast—progenitor of the adult erythrocyte—derived from endothelium but formed from extravascular clumps and the myeloblast—also formed extravascularly, and still later the lymphocyte, derived from lymphendothelium through the intermediate stage of lymphoblast.

The dual theory of origin of blood cells has, however, received its most important support from the recent experiments of Sabin, Cunningham and Doan (1922 to 1924), including actual observations of the living blastoderm of young chicks and studies on depleted and regenerating marrows of pigeons and rabbits. As they seem to place the origin and development of the erythrocyte on a firm basis, they will be considered in more detail.

Studying living chick embryos during the earliest stages of development of blood cells, Sabin was able to observe "the actual division of the endothelial cells lining the newly formed blood vessels and the subsequent development of blood islands and red blood cells from these endothelial cells," while the earliest leucocytes were observed as forming from extravascular mesenchymal cells. This view of the origin of the chick embryo red blood cell can be expressed in the accompanying diagram (after Sabin):

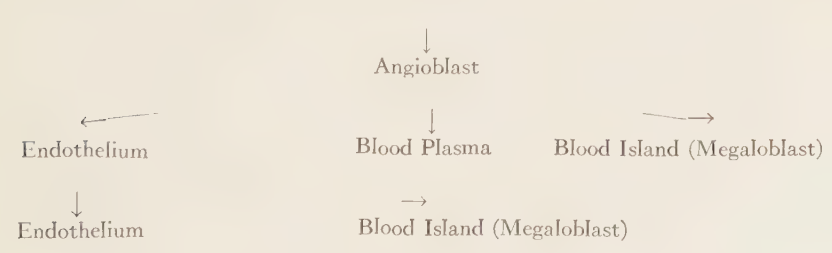

As a matter of fact, the intravascular origin of the erythrocyte in the chick embryo has received considerable support, but for the mammal, it, like the primitive white cell, has been thought to develop extravascularly, as indeed it must, if all come from the same cell.

The evidence for the intravascular development of the erythrocyte in the adult is somewhat as follows: If a pigeon be underfed for a suitable period, its blood-forming marrow becomes so depleted (yellow marrow) that, on suitable injection with dilute

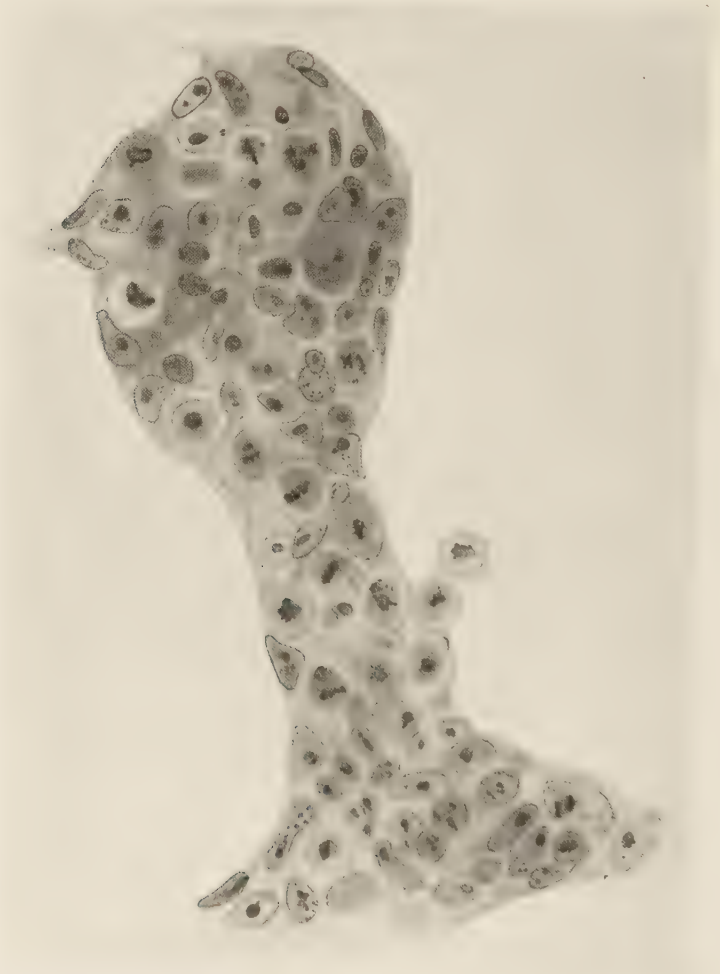

FIG. 122.—Solid angioblasts undergoing division showing rounded future blood cells and elongated future endothelial cells. Chick of eleven somites. (After Sabin.)

India ink, a new type of collapsed minute capillary (Doan's or intersinusoidal capillary) can be made out passing between the larger venous sinuses (or sinusoids). Resumption of feeding stimulates active formation of blood cells, so that by removal of bits of marrow from the test bird or by sacrificing birds at appropriate intervals, the whole process can

be passed under view. Thus the endothelial cells of Doan's capillaries are first seen to be in a stage of active proliferation, swelling the capillary with cells which gradually acquire hemoglobin in their cytoplasm. In the first few generations, with marked power of proliferation and growth, these are called megaloblasts; in the more mature stage, erythroblast; and in the semi-final stage with pycnotic nucleus, normoblast. Eventually the growth becomes so great that the distended capillary pours its more mature and less sticky elements into the sinuses and thus into the circulation.

FIG. 123.—Angioblasts, with some liquefying, others forming blood islands. A, angioblasts, in the process of liquefying; B.i., blood island; C, exocoelom; Ec., ectoderm; En, endoderm; L, lumen of vessel; Mes., mesoderm. Inner area opaca, chick of eleven somites. (After Sabin.)

To investigate erythrogenesis in the mammal—which proved unsuitable for the underfeeding experiments—the myeloid elements of the rabbit were depleted by intravenous injections of inactivated typhoid bacilli, and the bone marrow stimulated by blood withdrawal or made hypoplastic by repeated injections of blood. (We also have found that, judged both by clinical methods and post-mortem observation, the marrow of dogs can be made very hypoplastic in this way.) Thus the same mechanism of erythrogenesis was made clear for the rabbit as for the pigeon, and with the knowledge thus gained, in a few human aplastic marrows the same relationship of the special endothelium was found to maintain.

Incidentally, it became equally clear from these investigations that granulocytes (leucocytes) developed extravascularly, but succeeded in penetrating the closed vascular system by means of their ameboid motion, just as J. H. Wright demonstrated twenty years ago that pseudopods of megacaryocytes penetrated the vascular wall to be broken

FIG. 124.—Angioblasts containing hemoglobin and forming blood islands. Others have liquefied or formed endothelium. Chick of fourteen somites. (After Sabin.)

off as platelets. Such a theory, then, meets Drinker's belief in a closed circulation in the bone marrow; explains Bunting's views of red cell islands and white cell islands of development (as the bulging capillary might easily be mistaken for a Bunting island in the absence of special experimental methods), and adds another to the constantly growing list of examples of the general physiological principle of alternation of rest and activity of vascular structures (Krogh's capillaries, Richards' glomeruli, etc.).

a

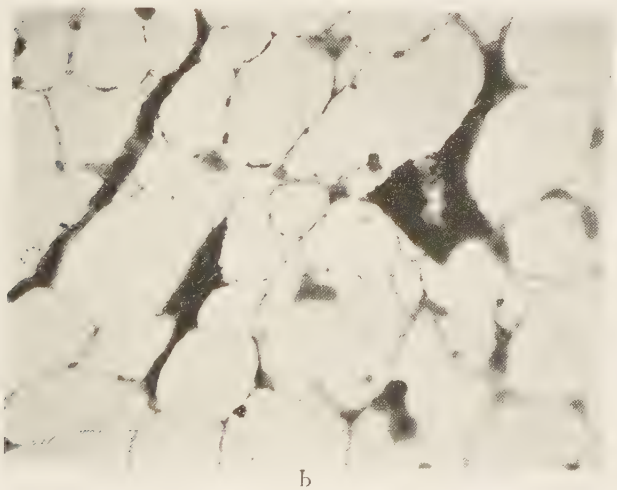

b

FIG. 125a.—Drawing of a hypoplastic bone marrow, injected with India ink, showing venous sinusoids and the inter-sinusoidal capillaries; from the radius of an adult pigeon: e.c., endothelial cells lining the capillaries; r.c., reticular cells of the marrow; n.f.c., nuclei of the fat cells; r.b.c., red blood cells; v.s., venous sinusoids; cap., inter-sinusoidal capillaries surrounding the fat cells, with the granules of carbon of the injection fluid scattered throughout the extent of their channels. These capillaries are seen to be in direct communication with the large venous sinusoids. H. and E. × 700. (After Doan.) b. Photomicrograph of the same area in the bone marrow, the detail of which is given in a. × 700. (After Doan.)

3. *Sites of erythrogenesis:*

Whatever the mechanism of erythropoiesis, the locus of its occurrence is known to vary considerably in different species and even in different stages of development. The blood islands of the yolk sac are followed in man in the third week by a similar development within the mesoderm of the embryo, with eventual fusion of the two systems. In most mammals, blood formation is then first concentrated (in the human embryo of 10 mm.) in the liver, where active formation of both white and red cells can be seen between the strands of liver cells in the first half of embryonic life. In the latter half, the spleen—a later arrival than the liver—takes on most of this activity; in turn to be replaced by the red marrow of the bones, which does not make its appearance till the second or third month of fetal life. At birth, hemopoiesis has practically or entirely stopped in the liver and spleen of man, but it is an interesting fact that at any time during life in which a diseased bone marrow (both clinical and experimental) becomes unable to supply blood cells adequately, these two organs can easily revert to their embryonic activity in forming blood cells (myeloid metaplasia). This sometimes is manifest as a diffuse picture of blood cells in various stages of immaturity and active development in the reticulum and sinuses or as definite large areas of tissue, indistinguishable microscopically from active bone marrow (Meyer and Heineke, 1907; Donhauser, 1908; and Wade, 1921). Hemopoiesis has been known to occur in numerous other sites in man, especially in the kidney pelvis after pathological new bone formation, and in lymph nodes, adrenals, sciatic nerve (Gutsell, 1017), pleura and other sites (Saleeby, 1925).

Although much remains to be learned about blood cell formation in various species, it has been amply demonstrated that great variations occur. Thus it is said that the spleen remains the chief organ of blood formation in the opossum throughout life, while in the larval frog the kidney performs this function to be replaced in the adult by the spleen. In birds, although the bone marrow is the chief site, the liver is said never entirely to lose this function; and further examples might be cited.

4. *The stimulus to erythrogenesis:*

Thus far the nature of erythropoiesis has been presented, but nothing said of the stimulus which starts the mechanism. While this phase of the problem is far from clear, it can at least be said that whatever the stimulus may be, it is efficient in coping with extraordinary demands and in maintaining accurate normal levels. Hemorrhage, for instance, is promptly balanced by the outpouring of new cells into the circulation and when there is no need for new cells, as in artificial plethora, erythropoiesis practically

PLATE I

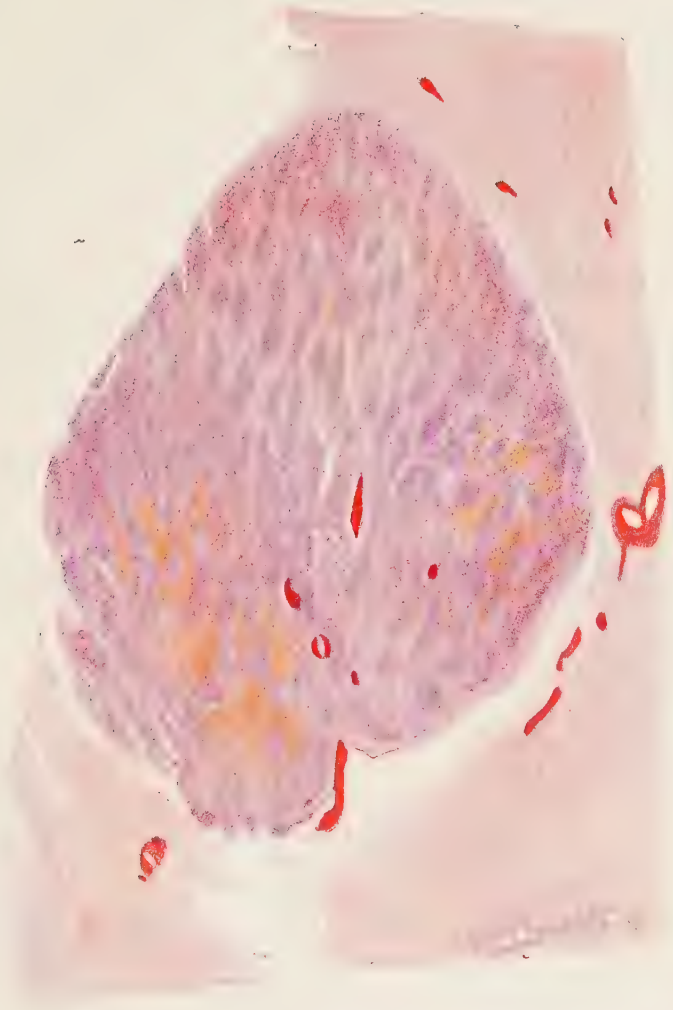

Fig. 126.—Myeloid metaplasia in the spleen.

(From J. H. Donhauser. Bull. Ayer Clin. Lab., Penn. Hosp., No. 5, Phila.)

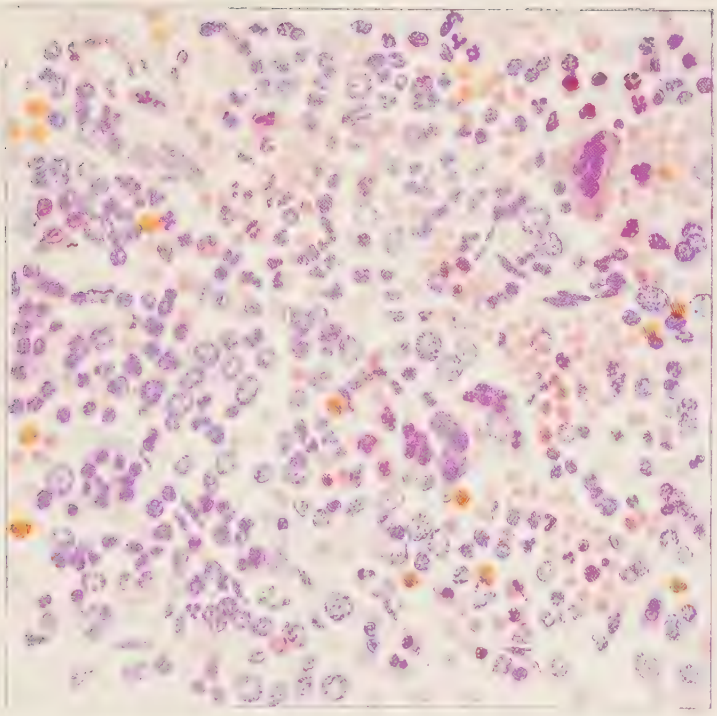

FIG. 127.—Histology or myeloid metaplasia in the spleen, showing immature erythrocytes, leucocytes and bone marrow giant cells.

(*From J. H. Donhauser. Bull. Ayer Clin. Lab., Penn. Hosp., No. 5, Phila.*)

stops, as others besides ourselves have shown (Robertson, 1917). Hemorrhage into a body cavity apparently permits quicker regeneration than when the blood is lost, and McMaster and Haessler (1921) have convincingly demonstrated experimentally that the presence in the body of hemoglobin in excess of the amount utilizable by the existing marrow is an important factor in spreading the red marrow in anemia. This, of course, is different from, but not necessarily incompatible with the view that the oxygen tension of the hemopoietic tissues is a factor in determining erythropoiesis. Thus a relative anoxemia, such as observed clinically at high altitudes or experimentally by Dallwig, Kolls and Loewenhart (1915), is followed by increased blood cell formation and it is conceivable that in plethora an unusual amount of oxygen is brought to the marrow. Miescher's (1893) conception that the bone marrow is in a constant state of relative anoxemia still awaits definite proof. It is difficult, too, to reconcile this view with the changes in blood cell formation that follow interference with related organs. Jordan and Speidel's (1924) work on the changes in frog's blood after hibernation, temperature change and hemorrhage would indicate that excess of a cellular metabolite, probably carbon dioxide, was the responsible factor.

A variety of experiments on dogs and monkeys have led us to believe that the anemia that follows removal of the normal spleen seems to be due to a loss with the spleen of a substance that has a stimulating effect on erythropoiesis, a concept strengthened by the fact that we have found that splenic extract is more potent than any other in raising the red blood cell count when the marrow is still functioning normally. This has recently been made the basis of a new therapy for certain forms of anemia (Leake, 1923 to 1925). It is difficult (though not impossible) to see how such a condition can be explained on the anoxemia basis. Then, too, in the "blood crises" of pernicious anemia, where showers of young forms appear in the blood stream with a remission in the disease picture, an increased anoxemia is difficult to visualize.

5. Ontogenesis of the erythrocyte:

The youngest representative of the red cell in its descent from the marrow endothelium is, according to Sabin, a fairly large round cell, with only a faint trace of recognizable hemoglobin in the deeply basophilic cytoplasm and a large vesicular nucleus of finely divided, sparse chromatin with perhaps one or two nucleoli. By Sabin's supravital staining method (Janus green and neutral red) large rod-shaped mitochondria are seen scattered diffusely through the cell. This and its immediate offspring, a larger cell with slightly more hemoglobin and denser chromatin and smaller mitochondria, may be taken as megaloblasts, characteristic of pernicious anemia and of extremely active erythropoiesis and seldom seen in normal

marrow. In Sabin's classification they are followed by the erythroblast,* a smaller cell, with more but smaller mitochondria, more recognizable hemoglobin in the cytoplasm and a smaller nucleus with denser network of chromatin in wheel form or concentrated in small nodes. In diseases such as pernicious anemia, where megaloblasts are prominent, some think that it is not only a question of output of immature cells due to severe demand, but that the disease has provoked a perverted type of blood formation. In the normoblast, already a decadent cell ontogenetically, the eccentric nucleus has become quite pycnotic, appearing as a solid mass of nuclear material; the cytoplasm is almost the normal erythrocyte color; and in supravital stains, the mitochondria are small and eccentric—to disappear entirely in the adult (really senile) erythrocyte (Cowdry, 1914).

Further light is thrown on the relative age of a given erythrocyte by the appearance of its reticulated substance (substantia granulo-filamentosa, Cesaris-Demel). This is a combination of threads and nodes, only brought out by vital staining (brilliant cresyl blue, neutral red, etc.), which may take the form of a heavy wreath or ball, or a flat reticulum or sometimes merely as a faint thread between two small nodes. It is unquestionably of cytoplasmic nature, as it is occasionally found well developed in cells of the peripheral blood with intact nuclei, and this is said to be not uncommon in bone marrow preparations.

While practically all erythrocytes are nucleated with basophilic protoplasm in the blood vessels of young human embryos, the proportion of non-nucleated forms steadily increases during fetal life until at birth only a few nucleated forms remain, though the proportion of basophilic staining cytoplasm is increased. The percentage of reticulocytes is greatly increased at birth, but within the first week it drops practically to normal in man, and remains at less than 1 per cent of the total throughout life. Although differ-

TABLE V

PERCENTAGE OF RETICULOCYTES IN VARIOUS ANIMALS

Species	Average, per cent	Normal range, per cent
Man	0.3	0.1–0.8
Monkey	0.3	0 –0.8
Dog	0.6	0.1–1.4
Cat	0.2	0 –0.4
Guinea pig	3.0	1.0–4.0
Rabbit	2.0	0.6–2.8
Mouse	4.0	1.0–6.0

* On account of the various connotations attached to this word and the term "megaloblast," discussions of its occurrence and behavior are of little use unless accompanied by good descriptions of its appearance.

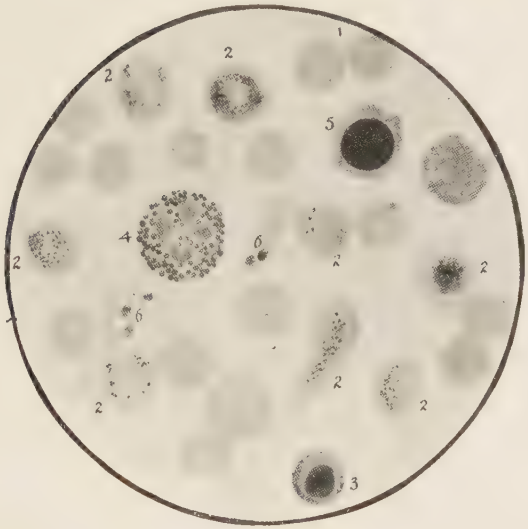

FIG. 128.—Drawing of reticulocytes vitally stained with brilliant cresyl blue. 1, normocytes; 2, various erythrocytes; 3, normoblasts with reticulum; 4, polymorphonuclear leucocytes; 5, lymphocytes; 6, blood platelets. (After Krumbhaar.)

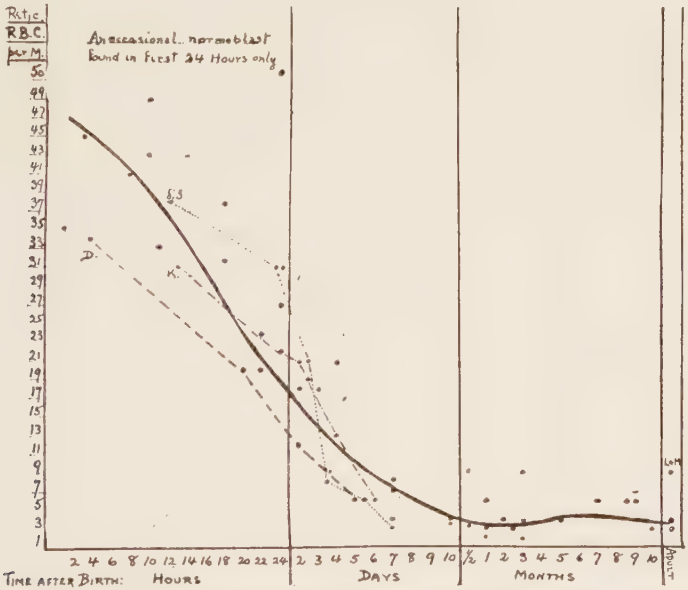

FIG. 129.—Chart of reticulocyte percentages at different ages (man). (After Krumbhaar.)

ent figures are given for normality in the few textbooks in which these cells are mentioned, the limits of 0.2 per cent to 0.8 per cent will cover the great majority of normal individuals. The normal average varies in different species: in laboratory animals, averages and variations are about as shown in Table v.

While the general rule holds that the percentage of the reticulocytes of the circulation is raised whenever new blood cells are being formed in increased numbers, it by no means follows that the percentage of reticulocytes is commensurate with the degree of anemia. Thus in the severest pernicious anemias, they usually do not rise above 12 to 15 per cent, even though nucleated forms are numerous, whereas this figure is surpassed in relatively mild cases of hemolytic jaundice, in some of which as high as 25 or 35 per cent may be found with few or no nucleated forms. This discrepancy might be explained on the basis that in hemolytic jaundice the greatly increased blood destruction makes a strong demand on the bone marrow, but that this being healthy can almost preserve equilibrium with only relatively immature cells reaching the circulation; whereas in pernicious anemia the damaged bone marrow has to let very immature cells escape without being able to maintain anything approaching a balance. The highest level ever recorded was in one of our "plethora-anemic" dogs, in which following daily injections of blood from other dogs, a plethora had been followed by a severe anemia. The high reticulocyte percentage, which in this animal's blood touched 95 per cent, might be considered as being due to the extreme demand being made on a healthy bone marrow that had been rested by the previous period of plethora.

The pycnotic nuclei of the normoblasts may assume bizarre shapes, especially in pathological conditions, before they disappear. These may be buds, rosettes, clover-leafs, double spheres or many other forms, or perhaps only a faint ring will persist. It is usually believed that the disappearance of the pycnotic nucleus is accomplished rather rapidly by some chemical transformation whereby it loses its characteristic staining quality and perhaps some fragments discharged, although others think with Howell that the whole effete nucleus is extruded. In either case, it is not uncommon to find one or more nuclear fragments in a cell in anemic conditions, particularly in a "blood crisis" (von Noorden) of pernicious anemia or after therapeutic removal of the spleen in a primary anemia (Morris, 1909). These fragments take the usual nuclear stains, vary from 1μ to the limits of visibility in size and may be found in any part of the cell. The Howell-Jolly bodies are also probably of nuclear origin, although their tinctorial qualities are atypical and they occur in much greater numbers than do the fragments just described.

The well-known Cabot's (1903) rings (more often twists or figures of eight) are also pathological products, probably the rim of the nucleus from which the chromatin has disappeared. Clinically they are only found in severe anemias, but similar pictures can occasionally be found in embryonic blood cells.

Differing from the nuclear fragments just described are the basophilic granules of the cytoplasm ("stippling"). Not only are they much more numerous than the former in a given cell and characteristically scattered about the periphery, but they may readily be found in cells containing an intact nucleus and take certain stains differently (e.g., blue with Giemsa, as compared to the red of the nuclear fragments). Surely then of cytoplasmic origin, it is still doubtful whether they are signs of youth or, as most authorities believe, of degeneration. Clinically they are characteristic of lead and other poisons, but the poison might be considered as producing either of these results, and, in fact, recent experiments with alcohol led Lehmann (1924) to believe that the basophilic granules may be manifestations of either condition.

A recent paper by Isaacs (1925) demonstrates that from 3 to 7 per cent of cells of normal human blood contain a single brilliant refractile granule, $\frac{1}{2}\mu$ in diameter, appearing black with Wright's stain. As it does not take the nuclear stain and is more refractile, it is a different structure from the Howell-Jolly bodies, though its exact status has not been defined. As this granule appeared in increased numbers even before an increase in the reticulocytes when there was even a slight increase in blood cell formation, Isaacs considers for both these reasons that it represents the final stage of ripening before the fully finished normocyte.

Polychromatophilia, a condition in which erythrocytes take diffusely some of the basophilic, as well as the acidophilic stain, is recognized as a sign of youth of the cell, although Ehrlich originally considered it a degeneration. In fact, it is believed by many hematologists that the beforementioned vitally stained reticulum is an artificial clumping of the same substance that with Romanowsky methods stains diffusely as polychromatophilia.

In addition to the several bodies just mentioned, various artefacts can be produced by standing, poor fixation, non-isotonic solutions, etc., termed "nucleoids." The Heinz bodies probably belong to this category.

VI. THE FATE OF THE ERYTHROCYTE

1. *Duration of life:*

It has already been shown that ontogenetically the erythrocyte is a senile cell when it begins its life work. How long does that life work continue

in man? The question has been thoroughly discussed by Rous (1923) in an article which still leaves little to be said. At best it can only be answered approximately, both because different methods of estimation give widely different results and because the mortality of individual cells probably varies as greatly as does that of the individuals they serve. One has only to view a live capillary under the microscope to see the trauma to which an erythrocyte is subject under normal conditions, and it requires no imagination to picture how this would be greatly increased under various physiological (exercise Broun, 1922) as well as pathological conditions.

Assuming that the amount of bilirubin excreted from the liver is proportional to the amount of blood cells destroyed, it is estimated that one-fifteenth of the erythrocytes of the body are destroyed daily, with an average life expectancy, therefore, of fifteen days. Objection has been made that this is not a fair assumption and that bilirubin excretion can be greatly influenced by such extraneous factors as the kind of diet fed to the experimental animal (Whipple and Hooper, 1916). Later experiments, however, in which the total bilirubin excretion per twenty-four hours was observed, indicate that these are variations only in the rate of evacuation and that daily bilirubin excretion follows fairly closely the amount of blood cell destruction (Rous). Whipple considers this method unreliable also because the contribution of "muscle hemoglobin" and the amount of hemoglobin conserved during pigment metabolism without being excreted as bilirubin are both unknown variables.

If, now, the survival of the erythrocyte is studied by the blood grouping method (Ashby, 1919), much higher figures are obtained. By transfusing an individual with blood cells of a different but compatible group, it is possible to determine by agglutination of successive samples with appropriate sera just how many of the foreign cells have persisted in a given sample. Thus Ashby found that from 40 to 50 per cent of the transfused cells still survived in the recipient's circulation after twenty-eight to fifty-two days and in one man some of the cells were still present after one hundred days. In Wearn's series the average duration was eighty-three days and such observations have since been repeated by other observers. Needless to say, of course, this is not studying normal conditions, so that it is possible that the strange cells may have been less susceptible to destructive influences; even though the trend is usually in the opposite direction. It seems, nevertheless, that these results must be taken as strong evidence that many erythrocytes persist considerably longer than was previously believed.

2. Disposal of worn-out erythrocytes:

There is no way of telling which cells have outlived their usefulness, ear-marked for destruction, so to speak; but we can surmise from the appearance of normal blood that useless cells are quickly removed from circulation. They need not necessarily be old cells, as is shown by Oliver's observation (quoted by Rous from a personal communication) that reticulocytes—admittedly young forms—can be found phagocyted by the splenocytes of the normal guinea pigs; reticulocytes also have been found by Rous in fragmented—presumably dying—cells. As a rule, however, the erythrocyte, barring accident, in some such time as fifteen to forty days (?) completes its life cycle and is removed from the scene.

According to Rous, the stages in which this occurs are that it breaks up into an increasing number of smaller and smaller hemoglobin-bearing fragments (Ehrlich's schistocytes), which when extremely small are taken up by the scavenger cells of the reticulo-endothelial system (spleen, Kupffer cells of the liver, bone marrow, lymph nodes, etc.). As the distribution of these cells varies greatly in different species, it follows that different organs are chiefly concerned—thus in man and dog the spleen seems to be the most important organ dealing with this function, but less so in rabbits and guinea pigs; in birds the liver is the chief agent, and so on. The transient anemia that we have found to develop in various animals after removal of the normal spleen might seem difficult to reconcile with these views; it is probable, however, that the loss of an agent of blood destruction is here more than counterbalanced by the loss of the spleen's stimulating influence on the bone marrow. Certainly in those diseases in which removal of the spleen is followed by a tremendous decrease in blood destruction, its blood destroying activities are too obvious to be denied. While Rous' theory is the favorite to-day, the fate of erythrocytes is by no means a settled question, and in any case it will be found to be considerably modified in the different species.

The intervening steps of disposition of the products of the red cell destruction are even less certain. It is believed that the hemoglobin is separated into hematin and the protein globin as a physiological process, and that the hematin is further split into bilirubin—or its isomer hematoidin—and iron, which is conserved and re-utilized in the formation of new cells. The high iron content of the spleen—especially in conditions of increased blood destruction—would indicate that these processes also take place in the reticulo-endothelial cells. That they are often modified is shown by the frequent appearance of the iron-bearing hemosiderin in the tissues.

That bilirubin is formed at such sites rather than in the liver is a fact that has been well established in the past few years. In fact, as Rich has recently pointed out, there is no evidence that bilirubin is formed in the liver. On the other hand, Whipple and Hooper's thoracic circulation experiments, and Rich's (1925) bilirubin formation from hemoglobin in vitro have con-

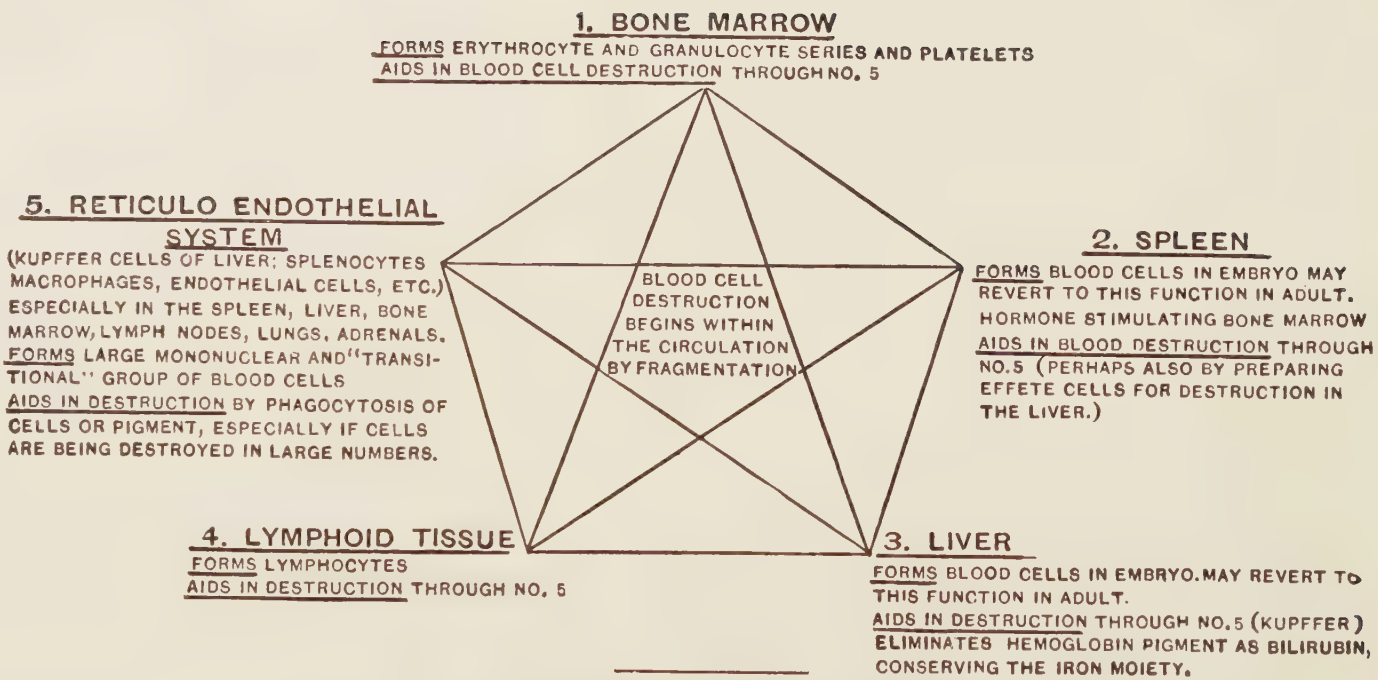
1. BONE MARROW
FORMS ERYTHROCYTE AND GRANULOCYTE SERIES AND PLATELETS
AIDS IN BLOOD CELL DESTRUCTION THROUGH NO. 5
5. RETICULO ENDOTHELIAL SYSTEM
(KUPFFER CELLS OF LIVER; SPLENOCYTES MACROPHAGES, ENDOTHELIAL CELLS, ETC.) ESPECIALLY IN THE SPLEEN, LIVER, BONE MARROW, LYMPH NODES, LUNGS, ADRENALS.
FORMS LARGE MONONUCLEAR AND "TRANSITIONAL" GROUP OF BLOOD CELLS
AIDS IN DESTRUCTION BY PHAGOCYTOSIS OF CELLS OR PIGMENT, ESPECIALLY IF CELLS ARE BEING DESTROYED IN LARGE NUMBERS.
BLOOD CELL DESTRUCTION BEGINS WITHIN THE CIRCULATION BY FRAGMENTATION
2. SPLEEN
FORMS BLOOD CELLS IN EMBRYO MAY REVERT TO THIS FUNCTION IN ADULT.
HORMONE STIMULATING BONE MARROW
AIDS IN BLOOD DESTRUCTION THROUGH NO. 5 (PERHAPS ALSO BY PREPARING EFFETE CELLS FOR DESTRUCTION IN THE LIVER.)
4. LYMPHOID TISSUE
FORMS LYMPHOCYTES
AIDS IN DESTRUCTION THROUGH NO. 5
3. LIVER
FORMS BLOOD CELLS IN EMBRYO. MAY REVERT TO THIS FUNCTION IN ADULT.
AIDS IN DESTRUCTION THROUGH NO. 5 (KUPFFER)
ELIMINATES HEMOGLOBIN PIGMENT AS BILIRUBIN, CONSERVING THE IRON MOIETY.
HEMOLYTO-POIETIC SYSTEM

FIG. 130.

clusively shown that bilirubin can be formed outside the liver—as Virchow pointed out many years ago in hematomata. Recently also Mann and his associates (1925) by delicate spectrophotometric studies have detected increased amounts of bilirubin in the blood plasma coming from the spleen. In other words, the pigment from the disintegrated erythrocyte apparently travels in the blood plasma to the liver capillaries (except that portion that is worked over by the Kupffer cells), there to pass through the liver cells, emerging into the bile capillaries as a constituent of the bile. The different types of Van der Bergh reaction (direct and indirect) indicate that the liver cells exert some further influence on the pigment, of a nature but little understood. Eventually this erythrocytic component becomes changed into urobilin by action of intestinal bacteria (McMaster and Elman, 1925) and probably is partly resorbed into the circulation, but mostly excreted in the feces.

Under pathological conditions the fragmentation process may be so exaggerated as to become easily visible (burns, mushroom poisoning, etc.) or the erythrocyte may be destroyed in various other ways. In some of the acute magnifications of experimental conditions, such as the action of hemolytic sera, numbers of whole corpuscles can be found loaded into the phagocytes of the various organs of the hemolyto-poietic system, while the pigment derivative, hemosiderin, can be found in these cells months after such an acute insult. In pernicious anemia somewhat the same picture is easy to find post mortem. Specific hemolytic sera or chemical poisons undoubtedly can destroy cells while circulating and in such large numbers that free hemoglobin floods the plasma and escapes in large amounts into the urine; the same condition is seen clinically in paroxysmal hemoglobinuria. Erythrocytes may be destroyed by hemagglutinins, as when incompatible blood is used for transfusion, or may actually be consumed by a parasite, such as the malarial organism, which enters and grows at the expense of the individual cell. Undoubtedly in some cases, such as sickle-cell anemia or hemolytic jaundice, the weakness of the cell itself is an important item in its early destruction.

Thus the phenomena of blood cell destruction, like those of blood cell formation, indicate the existence of a mechanism capable of not only preserving a most sensitive balance between blood cell formation and destruction under normal conditions, but of responding to emergencies in a variety of efficient ways.

VII. BIBLIOGRAPHY

Adair, G. S. 1925. The hemoglobin system. *J. Biol. Chem.*, **63**, 493, 503, 515, 517, 529.

Anson and Mirsky. 1925. Hemochromogen and the relation of protein to the properties of the hemoglobin molecule. *J. Physiol.*, **60**, 50, 161, 221.

Ashby, W. 1919. Determination of length of life of transfused blood corpuscles in man. *J. Exper. Med.*, **29**, 267.

Bailey, C. V. 1919. Studies on alimentary hyperglycemia and glycosuria. *Arch. Int. Med.*, **23**, 455.

Bailey, Strong and Elwyn. 1925. *Textbook of histology*. Ed. –, New York: Wm. Wood.

Barcroft, Joseph. 1921–22. The raison d'être of the red corpuscle. *Harvey Lectures*, 146.

——— 1924 and 1925. Significance of hemoglobin. *Physiol. Rev.*, **4**, 329 and **5**, 596.

—— 1925. Physiological regulation of acid-base balance of blood and some related functions. *Ibid.*, **5**, 131.

Bechold, H., and Kraus, W. 1920. Kolloid Studien über den Bau der roten Blutkörperchen und über Hamolyse. *Biochem. Zeits.*, **109**, 226.

Berzelius. 1838. *Traité de chimie* (trans. Valerius), **3**, 551.

Beumer, H., and Burger, M. 1923. Ueber die Zusammensetzung der Stromata menschlicher Erythrocyten mit besonderer Berucksichtigung der Lipoide. *Arch. f. Exp. Phar. u. Path.*, **71**, 311.

Bie and Moller. 1914. *Ugeskrift f. Laeger*, **81**, 1483.

Bing, H. I. 1919. The number of red blood corpuscles at different ages and under different conditions. *Ugeskrift f. Laeger*, **81**, 1483.

Bochner, M., and Wassing, H. 1925. Blood sedimentation (Fahraeus) in diagnosis and prognosis of disease. *J. Lab. & Clin. Med.*, **11**, 214.

Bonninger. 1920 and 1921. Ueber den Gehalt der roten Blutkorperchen im Traubenzucker. *Biochem. Zeit*, **103**, 306 and **122**, 258.

Brinkman. 1915–20. Remarques sur la question de la repartition de la dextrose entre les globules rouges et le plasma. *Arch. Internat'l. de Physiol.*, **15**, 105; and *Biochem. Zeits.*, **108**, 74.

Brinkman, R., and Szent Gyorgyi, V. 1923–24. The reversion of hemolysis. *J. Physiol.*, **58**, 204.

Broun, G. O. 1922. Blood destruction during exercise. *J. Exper. Med.*, **36**, 48.

Bunting, C. H. 1905. The etiology and pathogenesis of pernicious anemia. *Johns Hopkins Hosp. Bull.*, **16**, 222.

Cabot, R. C. 1903. Ring bodies (nuclear remnants?) in anemia blood. *J. Med. Res.*, **9**, 15.

Campbell, J. M. H. 1922. The relative volume of corpuscles and plasma. *Brit. J. Exp. Path.*, **3**, 217.

Capps, J. A. 1903. A study of volume index. *J. Med. Res.*, **10**, 367.

Chauffard, A. 1907, 1908, 1914. Pathogenie de l'ictère congénitale de l'adulte. *Semaine méd.* **27**, 25; also *Ibid.*, **28**, 49 and *Ann. de méd.*, **1**, 1.

Coca, A. F., and Deibert, O. 1923. Occurrence of blood groups among American Indians. *J. Immunol.*, **58**, 487.

Conant, J. B., and Scott, N. D. 1926. The adsorption of nitrogen by hemoglobin. *Biol. Chem.*, **67**, 107.

Cowdry, E. V. 1914. The vital staining of mitochondria with janus green and diethylsafranin in human blood cells. *Intern. Monatssch. f. Anat. u. Phys.*, **31**, 267.

Cruickshank, E. W. H. 1923. Studies in experimental tetany. *Biochem. J.*, **17**, 13.

Cunningham, R. S., Sabin, F. R., and Doan, C. A. 1924. The development of leucocytes, lymphocytes and monocytes from a specific stem-cell in adult tissues. *Contrib. to Embryol.*, No. 84. Carnegie Inst., Pub. 361, p. 227.

Dallwig, H. C., Kolls, A. C., and Loevenhart, A. S. 1915. The mechanism adapting the oxygen capacity of the blood to the requirements of the tissues. *Am. J. Physiol.*, **39**, 77.

Decastello, A., and Krjukoff, A. 1911. *Untersuchungen über die Structur der Blutzellen*. Berlin: Urban u. Schwarzenberg.

Descamps, A. 1925. Sur la mesures des variations de volume des globules rouges. *Arch. Internat. de Physiol.*, **25**, 88.

Doan, C. A. 1922. Capillaries of bone marrow. *Johns Hopkins Hosp. Bull.*, 1922, **33**, 222.

Doan, C. A., Cunningham, R. S., and Sabin, F. R. 1924. Experimental studies on the origin and maturation of avian and mammalian red blood-cells. *Contrib. to Embryol.*, No. 83. Carnegie Inst., Pub. 361, p. 163.

Doisy, E. A., Briggs, A. P., Eaton, E. P., and Chambers, W. H. 1922. Evaluation of buffers of the blood. *J. Biol. Chem.*, **54**, 305.

Donhauser, J. L. 1908. The human spleen as an hematoplastic organ, as exemplified in a case of splenomegaly with sclerosis of the bone marrow. *J. Exp. Med.*, **10**, 559.

Drinker, C. K., Drinker, K. R., and Lund, C. C. 1922. Circulation in the bone marrow. *Am. J. Physiol.*, **62**, 1, also 1916, **40**, 514.

Evans, C. L. 1925. *Recent advances in physiology.* Philadelphia: Blakiston.

Fahraeus, R. 1921, 1924. (The suspension stability of the blood.) *Acta Med. Skand.*, **55**, 1; and *Ibid.*, **60**, 12.

Falta, W., and Quittner, M. R. 1919. Ueber die Verteilung des Zuckers der Chloride und der Reststickstoffkorper auf Plasma und Körperchen. *Biochem. Zeit.*, **100**, 148.

Folin, O., and Berglund, H. 1922. Some new observations with reference to the transportation, retention and excretion of carbohydrates. *J. Biol. Chem.*, **51**, 213.

Fricke, H. 1925–26. The electric capacity of suspensions with special reference to blood. *J. Gen. Physiol.*, **9**, 137.

Gorter, E., and Grendel, E. 1925. Bimolecular layers of lipoids on chromocytes of blood. *J. Exper. Med.*, **41**, 439.

Gram, H. C. 1921. Volume des globules du sang et rapports de ce volume à l'hémoglobine et au nombre des cellules. *Compt. Rend. Soc. de Biol.*, **84**, 151.

Gradwohl, and Blaivas, A. J. 1916. The distribution of the blood sugar as regards corpuscles, plasma and whole blood in health and disease in man. *J. Lab. & Clin. Med.*, **2**, 416.

Grawitz, E., and Gruneberg. 1906. *Die Zellen des menschlichen Blutes in ultravioletten Lichte.* Thieme. Leipzic.

Gruner, D. C. 1920. Advances in knowledge about the blood cells in the past six years. *Can. Med. Ass'n. Jour.*, **10**, 624.

Guthrie, C. G., and Huck, J. G. 1923, 1924. On the existence of more than 5 isoagglutinin groups in the human blood. *Johns Hopkins Hosp. Bull.*, **34**, 37, 80, 128; **35**, 23, 81, 225.

Gutsell, R. S. 1917. An anomalous case of blood formation in the connective tissue of the sciatic nerve in man. *Anat. Record*, **13**, 409.

Haden, R. L. 1923. *Clinical laboratory methods.* St. Louis: Mosby.

Hamburger. 1902. *Osmotischer Druck und die Ionenlehre.* Wiesbaden.

Hansen, K. M. 1919. Erythrocyt ag Haemoglobintal hos gamla. *Ugeskr. f. Laeger*, **81**, 1281.

Harrop, G. A. 1919. The oxygen consumption of human erythrocytes. *Arch. Int. Med.*, **23**, 745.

Hartridge. H. 1919–20. The shape of the red blood cells. *J. Physiol.*, **53**, 81.

Hassenfratz. 1791. Memoire sur la combinaison de l'oxygène avec le carbon et l'hydrogène du sang, etc. *Annales de Chemie*, **9**, 266, 275.

Heden, S. G. 1891. Der Hamotokrit. Ein neues Apparat zur Untersuchung des Blutes. *Skand. Arch. f. Path.*, **2**, 135, 360.

Henderson, L. J., et al. 1924 and 1925. The blood as a physico-chemical system. *J. Biol. Chem.*, **46**, 411, and **59**, 155, 379, 405.

Henderson, Y., and Haggard, H. W. 1920. Hemato-respiratory function. *J. Biol. Chem.*, **45**, 189.

Hewson, W. 1770–77. Experiments on the blood with some remarks on its morbid appearances. *Philo. Trans. for 1770*, **60**, 368. On the figure and composition of the red particles of the blood; *Ibid.*, 1773, **63**, 303: *Experimental inquiries part the third, containing a description of the red particles of the blood in the human subject and in other animals, etc.* Edited by M. Falconar, London: T. Longman, 1777.

——— 1848. Works. Sydenham Soc., p. 235.

Höber, R. 1922. Theorie der Blutsenkungsgeschwindigkeit. *Med. Ges. zu Kiel*, p. 66. (Ref. *Klin. Woch.*, 1922, **1**, 2412.)

Howell, W. H. 1890. The life history of the formed elements of the blood. Especially the red corpuscles. *J. Morphol.*, **4**, 57.

Hunter, Wm. 1794. *Treatise on the blood, inflammation and gun shot wounds.* London: George Nicol. Pp. 43 and 44.

Isaacs, R. 1925. The refractive granule of the red blood corpuscle. Its behavior and significance. *Anat. Record*, **29**, 299.

Jansky, J. 1907. Hematologicke Studie u Psychotiku. *Sbornik Klinicky*, **8**, 85.

John, H. J. 1923. Distribution of sugar in whole blood, plasma and corpuscles. *Arch. Int. Med.*, **31**, 555.

Jolly, J. 1905. Sur la formation des globules rouges des mammifères. *Comp. Rend. Soc. de Biol.*, **1**, 528, 593.

——— 1923. *Traité technique d'hématologie.* Paris. P. 60.

Jordan, H. E., and Speidel, C. C. 1924. The fundamental erythrocytopoietic stimulus. *Proc. Soc. Exp. Biol. and Med.*, **21**, 399.

Krogh, A. 1918–19. Capillary circulation. *J. Physiol.*, **52**, 457.

Krumbhaar, E. B. 1922. Reticulosis-increased percentage of reticulated erythrocytes in the peripheral blood. *J. Lab. & Clin. Med.*, **8**, 11.

——— 1922. Studies on experimental plethora in dogs and rabbits. *J. Exper. Med.* **35**, 847.

Lamson, P. D. 1915. The role of the liver in acute polycythemia. *J. Pharmac. & Exper. Ther.*, **7**, 189.

Landsteiner, K., and Miller, C. P. 1925. Serological studies on the blood of primates. *Ibid.*, **42**, 841, 853, 863.

Landsteiner, K., and Van der Scheer, J. 1924. Specificity of agglutinins and precipitins. *J. Exper. Med.*, **40**, 91.

Larrabee, R. C. 1911. The volume index of the red corpuscles. *J. Med. Res.*, **24**, 15.

Leake, C. D., et al. 1923, 1924 and 1925. Erythropoietic action of red bone marrow and splenic extracts. *J. Pharmac. & Exper. Ther.*, **22**, 75, also **23**, 353 and **25**, 357.

Lehmann, H. 1924. Die Bedeutung des Vorkommen gekörnter Erythrocyten im, stromenden Blute. *Deut. Med. Woch.*, **50**, 24.

Leichtenstern, O. 1878. *Untersuchungen über den Haemoglobulingehalt des Blutes in gesunden und kranken Zuständen.* Leipzig: F. C. W. Vogel.

Liebig, J. 1842. *Die organische Chimie in ihrer Anwendung auf Physiologie und Pathologie.* Braunschweig.

MacCallum, A. B. 1926. Paleochemistry of body fluids and tissues. *Physiol. Rev.*, 6, 316.

McMaster, P. D., and Elman, R. 1925. Urobilin physiology and pathology. *J. Exp. Med.*, **41**, 503, 513, 719; and **42**, 99, 619.

McMaster, P. D., and Haessler. 1921. The factor determining the spread of red marrow during anemia. *J. Exp. Med.*, **34**, 579.

Malpighi, M. 1901. Quoted from Foster's *History of Physiology*. Cambridge. P. 23.

Mann, F. C., Sheard, C. H., Bollman, J. L., and Baldes, E. J. 1925. The extrahepatic formation of bile pigment. *Am. J. Physiol.*, **74**, 49 and 497.

Mathews, A. P. 1925. *Physiological chemistry.* Ed. 4: Wood.
May, E. 1914. *La resistance globulaire.* Thèse de Paris.
Mayers, L. H. 1922. A study of the erythrocyte curve at various ages and its relationship to the hemoglobin curve. *Arch. Int. Med.*, **30**, 479.
Meyer and Heineke. 1907. Ueber Blutbildung bei schweren Anämien und Leukämien. *Deut. Arch. f. klin. Med.*, **78**, 435.
Michaelis, L., and z. Zt. Nagoya. 1926. Permeabilität von membranen. *Naturwiss.*, 14, 33.
Miescher, F. 1893. Ueber die Beziehungen zwischen Meereshöhe und Beschaffenheit des Blutes. *Corr. f. Schweiz. Arzt.*, **23**, 809.
Milne, Edwards. 1857. *Physiologie et l'anatomie comparée de l'homme et des animaux.* Paris. T. 1.
Morawitz, P. 1913. Einige neuere Anschauungen über Blutregeneration. *Ergeb. d. Med. u. Kinderheilk.*, **11**, 277.
Morris, R. S. 1909. Nuclear particles in the erythrocytes. *Arch. Int. Med.*, **3**, 93.
Moss, W. L. 1909. Studies on isoagglutinins and isohemolysins. *Trans. Ass'n. Am. Phys.*, **24**, 419; 1917, **68**, 1905.
Mudd, S., and Mudd, E. H. B. 1926. On the surface composition of normal and sensitized mammalian blood cells. *J. Exper. Med.*, **43**, 127.
Naegeli, O. 1923. *Blutkrankheiten und Diagnostik.* Berlin.
Oliver, J., and Barnard, L. 1925. Nature of the surface of the red blood corpuscle and mechanisms of suspension stability. *Am. J. Physiol.*, **73**, 401.
Ottenberg, R. 1925. Classification of human races based on geographical distribution of blood groups. *J. Am. Med. Assn.*, **84**, 1393.
Pearce, R. M., Krumbhaar, E. B., and Frazier, C. H. 1917. *The spleen and anemia.* Lippincott.
Ponder, E. 1924. Alterations in mammalian erythrocytes during saponin hemolysis. *Quart. J. Exp. Physiol.*, **14**, 333.
——— 1924–25. On the balloon like structure of the mammalian erythrocyte. *Proc. Royal Soc.*, Ser. B., **97**, 138.
——— 1925. *Quart. Jour. Exp. Physiol.*, **15**, 235.
——— 1925. The shape of the mammalian erythrocyte and its respiratory function. *J. Gen. Physiol.*, **9**, 197.
Ponder, E., and Millar, W. G. 1924. The measurement of the diameters of erythrocytes. *Quart. Jour. Exper. Physiol.*, **14**, 67 and 319.
Price-Jones, C. 1920. Diurnal variations in size of the red blood cell. *J. Path. & Bact.*, 23, 371.
Ransom, F. 1901. Saponin und sein Gegengift. *Deut. Med. Woch.*, **27**, 194.
Reichert, E. T., and Brown, A. 1909. The crystallography of hemoglobins. *Pub. of Carnegie Inst. of Washington, No.* 116.
Rich, A. R. 1924. Formation of bile pigment from hemoglobin in tissue cultures. *Johns Hopkins Hosp. Bull.*, **35**, 415.
——— 1925. Formation of bile pigment. *Physiol. Rev.*, **5**, 182.
Richards, A. N. 1925. The nature and regulation of glomerular function. *Am. J. Med. Sci.*, **170**, 78.
Robertson, O. H. 1917. The effects of experimental plethora on blood production. *J. Exp. Med.*, **26**, 221.
Rous, P. 1923. Destruction of the red blood corpuscles in health and disease. *Physiol. Rev.*, **3**, 75.
Rud, E. G. 1922. Red corpuscles and their variations. *Acta. Med. Scand.*, **57**, 325.

Sabin, F. R. 1920. Studies on the origin of blood vessels and red blood corpuscles as seen in the living blastoderm of chicks during the second day of incubation. *Contrib. to Embryol.*, Vol. IX, No. 36. Carnegie Inst. Pub. 272, p. 213.

Saleeby, E. R. 1925. Heterotopia of the bone marrow without apparent cause. *Am. J. Path.*, 1, 69.

Salén, E. 1920. Kolloidstudien über den Bau der roten Blutkörperchen. *Biochem. Zeits.*, 90, 176.

Saragea, T. 1922. Le diamètre des hematies de l'homme aux differentes âges de la vie. *Compt. Rend. Soc. de Biol.*, 86, 312.

Schmidt, Carl. 1902. Quoted in Bunge's *Physiologic and Pathologic Chemistry*. Phila. P. 212.

Schoep, G. K. 1925. *Ueber die Bestimmung der osmotischen Resistenz roten Blutkörperchen.* Utrecht Diss.

Schridde, H. 1907. Die Entstehung der erston embryonalen Blutzellen des Menschen. *Centrlbl. f. allg. Path. u path. Anat.*, 18, 823.

——— 1923. Die blutbereitende Organe. Aschoff's *Lebrb. d. Path.*, 2, 102.

Schürer and Eimer. 1921. Uber die klinische Bedeutung der Senkungsgeschwindigkeit der roten Blutkörperchen. *Berl. klin. Wocb.*, 58, 1258.

Seifriz. 1926. Unpublished Communication.

Steinbach, R. 1922. Der Wassergehalt der menschlichen Erythrozyten und seine Bestimmung. *Zeit. f. Biol.*, 75, 305.

Svedberg and Fahraeus. 1926. *J. Am. Chem. Soc.*, 48, 436.

Tachau, H. 1914. Ueber die Verteilung des Blutzuckers auf Blut Körperchen und Blut Plasma. *Zeit. klin. Med.*, 79, 421.

Vallery-Radot, P., and L'Heritier. 1919. Parallelisme entre la résistance globulaire aux solutions chlorurées sodiques et la dimension de l'hématie. *Comp. Rend. Soc. de Biol.*, 72, 195 and 197.

Van Heukelom, A. S. 1925. Ueber die Messung roter Blutkörperchem nach den Pijperschen Methoden. *Ned. Tijd.*, 69, 2818.

Van Leeuwenhoek. 1809. More observations made by the same Leeuwenhoek. *Philosophic. Trans. Royal Society*, No. 102, p. 23. (Abridged Ed. Lond. 2, 128.)

Van Slyke, D. C., et al. 1921–23. The carbon dioxide carriers of the blood. *Physiol. Rev.*, 141; also *J. Biol. Chem.*, 56, 765.

Vaquez, M. 1897. Examen du sang des sujets myxédémateux. *Bull. et mém. d. l. Soc. méd. d. hôp. de Par.*, 33, 14, 88; and *Compt. Rend. Soc. Biol.*, 2, 10 S., 142, and 1902, 54, 925.

Wade, H. W. 1921. A preliminary report on a case of hemopoietic splenomegaly with marrow sclerosis. *Jour. Phil. Is. Med. Ass'n.*, 1, 143.

Warburg, O. 1909. Zur Biologie der roten Blutzellen. *Zeit. f. physical Chem.*, 61, 112.

Waugh, T. R. 1923. The blood sedimentation test. *Can. Med. Assn. J.*, 13, 604.

Wearn, J. T., Warren, S., and Ames, O. 1922. The length of life of transfused erythrocytes in patients with primary and secondary anemia. *Arcb. Int. Med.*, 29, 527.

Weidenreich. 1913. In Gilbert and Weinberg, *Traité du Sang.* 1, 83.

Welcker, H. 1863. Grosse, Zahl, Volum, Oberflache und Farbe der Blutkörperchen der Menschen und bei Thieren. *Zeits. f. rationel Medizin*, 20, 257; also 4, 145.

Whipple, G. H., and Hooper, C. W. 1913. Icterus. A rapid change of hemoglobin to bile pigment in the circulation outside the liver. *J. Exper. Med.*, 17, 612.

——— 1916. Bile pigment metabolism. *Am. J. Physiol.*, 40, 349, also p. 332; 42, 544.

Whitcher, B. R. 1925. Microcytosis in hemolytic icterus. *Am. J. Med. Sci.*, 170, 678.

Weichmann, E., and Schurmeyer, A. 1925. Untersuchungen uber den Durchmesser der roten Blutkörperchen. *Deut. Arcb. f. klin. Med.*, 146, 362.

Williamson, C. S. 1916. Influence of age and sex on hemoglobin. *Arch. Int. Med.*, **18**, 505.
Wilson, D. W. 1923. Neutrality regulations in the body. *Physiol. Rev.*, **3**, 295.
Wishart, M. B. 1920. The permeability of blood corpuscles to sugar. *J. Biol. Chem.*, **44**, 563.
Zeckwer, I. I., and H. Goodell. 1925. The sedimentation rate of erythrocytes. *Am. J. Med. Sci.*, **169**, 209.
Zunz, E. 1925. Le volume des globules rouges dans les états de choc. *Comp. Rend. Soc. de Biol.*, **93**, 863.

Section XI

THE LYMPHOCYTES AND PLASMA CELLS

CONTENTS

SECTION XI

PAGE

I. LYMPHOCYTES 321
1. Structure 322
2. Development in adult organism 328
3. Germ centers 330
Active phase—Resting phase—Beginning of a new active phase—Transition from active into resting condition.
4. Functional significance of germ centers 340
5. Interrelations of different forms of lymphocytes 341
6. Relations of lymphocytes to reticulum, etc. 343
7. Origin of lymphocytes in embryo 344
8. Genetic interrelationships of lymphocytes, etc 345
9. Functional properties of lymphocytes 353
II. PLASMA CELLS 353
III. BIBLIOGRAPHY 359

Section XI

THE LYMPHOCYTES AND PLASMA CELLS

ALEXANDER A. MAXIMOW

I. LYMPHOCYTES

TWO main types of cells have to be distinguished in the blood of vertebrates among the non-granulated white blood corpuscles of Ehrlich's (1891) classification. The first type is characterized by a scarce protoplasm and a relatively large nucleus—the lymphocytes. The historical development of the lymphocyte concept is well discussed in Weidenreich's review (1911). The second type has an abundant protoplasm and an excentric, oval, kidney- or horseshoe-shaped nucleus—the "large mononuclear leucocytes" and the "transitional forms of Ehrlich" which at the present time are designated as monocytes.

In the lymph of the larger lymph vessels and of the thoracic duct the majority of the cellular elements belong to the category of lymphocytes. The presence of monocytes is denied by some investigators (Lejeune, 1915; Thorne and Evans, 1922). However, as Weidenreich (1909) has shown, cells resembling monocytes do appear, at least transiently, in the lymph of the thoracic duct.

Besides the blood and lymph, the lymphocytes are to be found in the exudate of the serous cavities and in the cerebrospinal fluid. Furthermore, a part of the wandering cells of the diffuse, loose connective tissue is histologically similar to lymphocytes. Embryological and experimental investigations have shown that this similarity is, in truth, an identity. There seems to be, then, no reason for the distinguishing between "hematogenous" and "histogenous" lymphocytes. Finally, the lymphocytes are the main constituents of the lymphoid tissue and are very numerous in the red pulp of the spleen. In the myeloid tissue (bone marrow) lymphocyte-like cells are also very numerous. Whereas from the viewpoint of the unitarian theory they are true lymphocytes, the dualists look upon them as "myeloblasts" or "micromyeloblasts."

The so-called "small cells" of the thymus occupy a peculiar position. Whereas some investigators (Dustin, 1914; Schridde, 1923) believe them to be of epithelial origin, Hammar (1905, 1908, 1910) and Maximow (1909*c*, 1912*a*, *b*) have shown that they are true lymphocytes which migrate during early embryonic stages from the mesenchyme into the epithelial primordium of the thymus and undergo here an extensive multiplication in the spaces between the epithelial cells. Morphologically they are identical with lymphocytes and, besides, they react similarly in abnormal conditions, as inanition, exposure to roentgen rays, life in vitro, etc.

Among the lymphocytes, cells of different size may be distinguished—the small, the medium-sized and the large lymphocytes. These groups cannot, however, be sharply separated from each other and show close genetic relationships. The small lymphocytes are the most common variety. They are typical of the adult human blood and lymph, where they constitute the vast majority of the lymphocytes, the medium-sized elements being in a minority. The same is true for the connective tissue and the liquids of the serous cavities.

The large lymphocytes are normally found only in the blood-forming organs and especially in the lymphoid tissue. But even here they are by far outnumbered by the small and medium cells. They are believed to occur in the blood of the infant. The only basis of this statement, however, seems to be a short notice in the first edition of Ehrlich's "Anämie" (1898), which has been taken as an axiom by all succeeding investigators. Large lymphocytes have also been described in the circulating blood of the rabbit (in the lumen of the liver capillaries—Wallgren, 1909). They are very numerous in the human blood in cases of acute lymphadenosis.

1. *Structure:*

The size of the average small lymphocyte corresponds to that of an erythrocyte—approximately 7μ in man. The size of the large lymphocytes may reach 12μ and more. Sometimes giant lymphocytes can be found in normal lymphoid tissue.

The nucleus occupies nearly the whole cell body in the small lymphocytes and the protoplasm forms only a very thin layer (Figs. 131 to 133).

Among the small lymphocytes of the blood and lymph and also in the connective tissue many cells show a slightly larger amount of protoplasm which sometimes accumulates on one side of the excentrically located nucleus. They are supposed to be older forms the so-called "leucocytoid lymphocytes" of Pappenheim (1919) (Fig. 131c). In the normal circulating blood they do not approach, however, the size and the absolute and relative abundance of the protoplasm in the monocytes. Therefore, in the normal blood the distinction between the lymphocytes and monocytes is easy. In the connective tissue and under pathological conditions also in the blood - the width of the protoplasm in the older lymphocytes may increase to such a extent that the monocytes seem to be connected with them by a series of transitional forms.

In the fresh, living condition the protoplasm of the small and medium-sized lymphocytes has a glass-like, homogeneous appearance. The outlines of the nucleus are not distinctly seen; however, a one-sided indentation of the nuclear membrane usually can be noticed. In the large lymphocytes—as seen in fresh scrapings from the sectioned surface of a lymph node—the

vesicular nature of the large, clear nucleus and one or several large nucleoli can be easily determined.

In the hematological textbooks the nucleus of the small and medium-sized lymphocytes is usually described as round and sometimes provided with a slight indentation. This is inexact and due to the exclusive use of the dry smear method (Fig. 131). In well-fixed, sectioned and stained preparations the nucleus always shows on one side a deep, irregular fold of the membrane, while the protoplasm shows an excentric accumulation on the indented side of the nucleus (Fig. 136b, d).

FIG. 131.—Three lymphocytes from a Romanowsky-stained dry smear of human blood; a and b, small lymphocytes with azure granules; c, lymphocyte with larger amount of protoplasm (leucocytoid lymphocyte of Pappenheim). × 1500.

The inner structure of the nucleus of the small and medium-sized lymphocytes is characterized by the presence of large, irregular, angular, darkly staining lumps of basichromatin with narrow clear spaces between them (Figs. 131 to 136). The chromatin framework of the nucleus, therefore, stains dark with nuclear dyes –it is "trachychromatic" (Pappenheim, 1905 to 1912, 1919). The arrangement of the chromatin particles in the form of spokes of a wheel, often mentioned as a characteristic feature, is by no means common. On Romanowsky-stained dry blood smears usually no nucleolus can be seen. However, one to two nucleoli are always present and can be easily demonstrated by supravital staining with brilliant cresyl blue or on sections of well-fixed material (Zenker-Formol, Champy), especially

after eosin azure (Maximow, 1909*a*), asan (M. Heidenhain, 1915) or Kull staining (Figs. 132, 133 and 136).

On dry Romanowsky-stained smears the nucleus is dark purple, whereas the homogeneous protoplasm is slightly basophilic and stains sky blue (Fig. 131). With the usual eosin methylene blue stain the nucleus, on the contrary, is pale and the protoplasm, because of its strong basophilia, is deep blue and presents an irregular, mottled appearance.

Michaelis and Wolff (1902) have found peculiar granules in the protoplasm of lymphocytes. They can be stained only with azure on dry smears and therefore have been named "azurophilic granules" (Fig. 131a, b). Contrary to the specific granules of the granular leucocytes, they are not constant and are supposed to be the visible symptom of a peculiar secretory function or of another metabolic process.

After fixation with potassium bichromate mixtures and staining with a modified Altmann method (acid fuchsin), Schridde (1907) found in the protoplasm of the lymphocytes peculiar granules, which he thought were specific for these cells, especially in comparison with the lymphoid cells of the bone marrow, the so-called "myeloblasts" of the dualists, where they could not be found. However, they turned out to be common chondriosomes, which are present in every type of animal cell (Maximow, 1909*e*; Butterfield, Heineke and Meyer, 1909). These organoids can easily be seen in the lymphocytes after any modern method of fixation and staining, ordinarily used for the demonstration of chondriosomes (Figs. 136 to 138). Renaut and Dubreuil (1906) have described the chondriosomes as granules (mitochondria) or shorter or longer rods and threads (chondrioconts), surrounding the nucleus and sometimes closely adjacent to its surface (the so-called "périnème"). As Laguesse (1900) and Bensley (1911) have shown, thec hondriosomes can easily be stained supravitally in any cell in the fresh condition with very weak solutions of Janus green. This method has been successfully applied by Cowdry (1915) for the staining of chondriosomes in the lymphocytes of fresh human blood (Fig. 135). The chondriosomes are seen in the smallest lymphocytes as scarce, bluish-green, round granules or very short rods surrounding the nucleus. In larger specimens the rods are slightly longer, the chondriosomes more numerous and usually accumulated on one side of the nucleus, opposite its indentation and surrounding the cytocentrum. Simpson (1921), according to the old technique devised by Pappenheim (1906*a*), Nakanishi, and Rosin and Bibergeil (1904), used a mixture of neutral red and Janus green in alcoholic solution, spread on the surface of a slide and dried. In a fresh drop of blood, placed on the surface of such a stained slide, the chondriosomes in the white blood corpuscles soon show up distinctly in the form of bluish-green bodies. Simultaneously in the protoplasm of many lymphocytes, especially the larger ones, round drop-like inclusions appear, stained red with neutral red—the "segregation

132

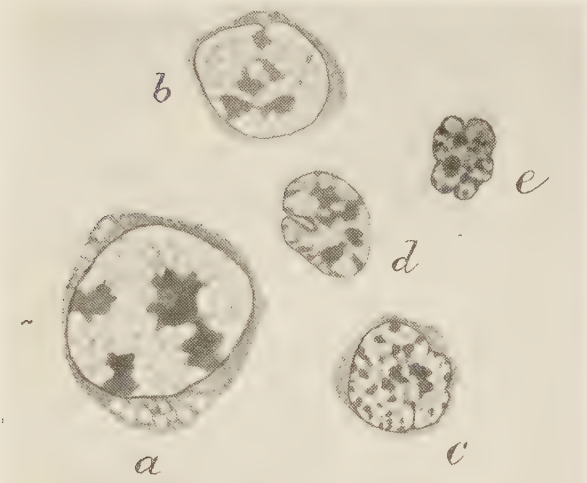

133

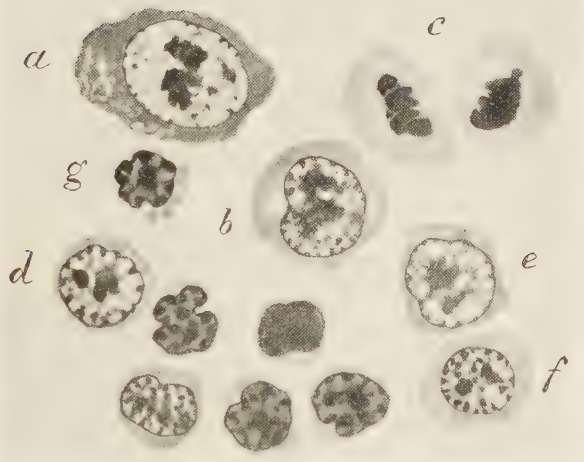

FIG. 132.—Different types of lymphocytes from a human lymph node; a, large lymphocyte, b and c, medium-sized lymphocytes; d and e, small lymphocytes. Zenker formol, hematoxylin, eosin-azure. × 1500.

FIG. 133.—Different types of lymphocytes from the lymph node of a rabbit; a, large lymphocyte with canaliculi in the protoplasm; b, large lymphocyte; c, mitosis of large lymphocyte; d, e, f, medium-sized lymphocytes. The other cells are small lymphocytes. g is a small lymphocyte with acidophilic inclusions in the protoplasm. Zenker formol, hematoxylin, eosin-azure. × 1500.

apparatus" of Evans (1915). These neutral red inclusions were seen first by Renaut and Dubreuil (1906) and Renaut (1907). Recently Sabin (1923) and her collaborators (Sabin, Doan and Cunningham, 1925) have made extensive use of the neutral red-Janus green method of Simpson for the discrimination of various cell types of the blood and for the elucidation of their relationships.

Using various aniline dyes for supravital staining of fresh blood, Hammar (1912) has also succeeded in demonstrating in the protoplasm of lymphocytes the almost regular presence of drop-like inclusions, which he believes are mostly of a lipoid nature.

On slides of material fixed with Zenker formol and stained with eosin azure the protoplasm of the small lymphocytes is often seen to contain some few red drops or granules (Fig. 133g). These inclusions, which might perhaps correspond to the azurophilic granules or to the lipoid inclusions, described by Hammar (1912), are especially conspicuous in young cultures of lymphoid tissue (Maximow, 1922).

Opposite the indentation of the nucleus in the protoplasm of the lymphocyte a typical pair of centrioles is located and may be stained with iron hematoxylin (Weidenreich, 1909, 1911) (Fig. 134). It is difficult, however, to demonstrate the cytocentrum in these cells, because of the scarcity of the protoplasm. After fixation in Champy's mixture and impregnation with 1 per cent osmic acid, according to a method devised by Kolatschev and modified by Nassonov (1923), small black bodies are seen in the neighborhood of the centrioles —the Golgi net (Fig. 138). This has been described by Cowdry (1921).

In the large lymphocytes the protoplasm forms a wider zone around the oval or kidney-shaped nucleus and is accumulated on the side opposite the excavation of the nuclear membrane. As a rule it shows a higher degree of basophilia, than in the small lymphocytes. In many cases it may contain peculiar clear canaliculi (Fig. 133a), reminding one of the trophospongia of Holmgren, or ordinary clear vacuoles. The cytocentrum, adjacent to the nucleus in the form of a clear hemispherical area, containing the centrioles, is very distinct and is surrounded by a Golgi net. The chondriosomes, granules of Schridde (1907), are more numerous than in the small and medium-sized lymphocytes and are usually accumulated on one side of the nucleus, in the neighborhood of the sphere. The vacuoles, staining supravitally with neutral red, are also present. Dry smears show a varying quantity of azurophilic granules.

The nucleus of the large lymphocyte is clear, vesicular, and stains much lighter than in the small lymphocyte, because its chromatin forms granules of varying size, which are widely separated from each other by an abundant nuclear sap (Figs. 132, 133 and 137a). In fixed preparations they sometimes seem to be arranged on threads of a loose linin network. Nucleoli, in num-

bers varying from one to three and more, are always present. They are large, irregular in size and shape, and stain dark purple with eosin azure. They usually are surrounded by a layer of blue basichromatin granules. On dry smears, stained with one of the Romanowsky stains, the nucleus of a large lymphocyte completely loses its typical aspect and, according to the textbooks of clinical hematology (Nägeli, 1923,1925), can be distinguished from the nucleus of the small lymphocyte only by its finer, more regular and paler chromatin network.

All lymphocytes are capable of ameboid motion. The large lymphocytes on fixed preparations very often show large, lobated, smoothly outlined

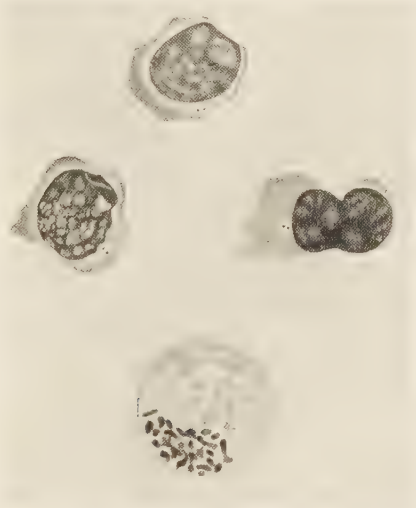

Fig. 134.—Lymphocytes from human blood, showing cytocentrum. (Weidenreich, 1909). × 750.

Fig. 135.—Lymphocyte from human blood with chondriosomes stained supravitally with Janus green. × 2600. (Cowdry, 1915.)

pseudopodia. The motility of the small lymphocytes has been denied by Ehrlich (1898). Maximow, however, showed in 1902 that under suitable conditions they display very active ameboid movements; this has been confirmed by Askanazy (1905). In cultures of lymphoid tissue the movements of the small lymphocytes can be followed with great ease. The body of the cell, together with the nucleus, stretches itself worm-like and the scanty protoplasm forms small bud-like pseudopodia (Fig. 134).

Downey and Weidenreich (1912) have observed the formation of small round particles of protoplasm on the surface of the small and medium lymphocytes in lymphoid tissue. The particles can detach themselves, become free and simulate blood platelets.

2. *Development in the adult organism:*

In the circulating blood of normal adult mammals the lymphocytes never show signs of multiplication. Their regeneration takes place in the lymphoid tissue which is located especially in the lymph nodes, but also forms the so-called peripheral lymph nodules of Schaffer (1922) in the wall of the digestive and respiratory tract and the Malpighian nodules of the spleen. In the bone marrow several authors have also described small lymphoid nodules. Furthermore, if the non-granulated stem cells of the myeloid tissue, as claimed by the unitarian hematological theory, are identical with lymphocytes this tissue should also be looked upon as a place of regenera-

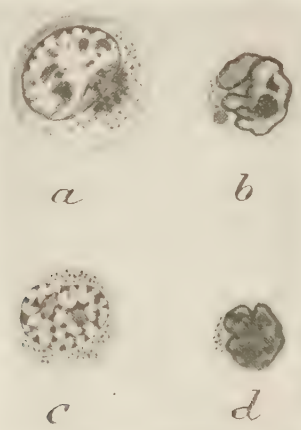

FIG. 136.—Four lymphocytes from thoracic duct of rabbit. a and b, large and small lymphocytes with Golgi net and chondriosomes; fixation Champy, osmic acid impregnation Kolatschev-Nassonov, staining Kull; c and d, medium-sized and small lymphocytes with chondriosomes. Zenker formol, Iron hematoxylin. × 1500.

tion of lymphocytes, although here the proliferation of the latter is accompanied by differentiation into other cell types.

In the lymphoid tissue a reticular stroma has to be distinguished from the free cells, located in the meshes of the framework.

The stroma consists of peculiar "reticulin" fibers and of cellular elements intimately connected with the fibers. Among these cells, according to recent investigations (Maximow, 1922, 1923), two varieties have to be distinguished.

The first are the reticular cells—large stellate or spindle-shaped elements with a more or less abundant protoplasm and an oval, pale nucleus containing little chromatin. They have a marked phagocytic capacity and are often found, even in normal conditions, containing engulfed particles, such as erythrocytes, degenerated lymphocytes. Besides, they readily store

vital dyes—acid aniline dyes of the benzidine group, such as trypan blue, and lithium carmine. They belong to the large group of histiocytes, scattered all over the body, and represented in the common connective tissue by the resting wandering cells or clasmatocytes, in the liver by the Kupffer cells, and displaying everywhere the same fundamental biological properties. The reticular histiocytes in the lymphoid tissue very often are found completely isolated and detached from the reticulin fibers. Such free histiocytes are especially active as phagocytes and usually are termed macrophages (Fig. 139e).

The other cell type has inconspicuous pale nuclei, closely adjacent to the reticulin fibers and a scant protoplasm which seems to form a syncytium, sheathing the fibers (Figs. 137d, 138r, 139d, 140b and 141e). Whereas the histiocytes probably have undergone at least a partial differentiation and have adapted themselves to the special phagocytic and nephrocytic functions, the reticular syncytium is an undifferentiated structure. Its elements keep their mesenchymal prospective potencies. They do not seem to perform special metabolic functions, they do not phagocytize and do not store vital dyes. They can, on the other hand, transform themselves into reticular cells; besides, as we shall see, they play a very important rôle in the production of lymphocytes. Transitions between the undifferentiated cells and the histiocytes can always be found.

In the meshes of the reticulum free macrophages and lymphocytes are found. The former, as has been mentioned, originate from the reticular cells and transitional forms between these two cell types, the free and the fixed histiocytes, can always be found easily. The lymphocytes, always forming the vast majority of the free cells, under normal conditions usually do not show any relation whatever to the elements of the stroma—they seem to be quite foreign to the fixed elements. As has been mentioned, the small lymphocytes (Figs. 137c and 138) always predominate, sometimes being the only type of lymphocytes present. The medium-sized lymphocytes (Fig. 137b) are scattered in various numbers among the small ones. The number of the large lymphocytes varies excessively (Fig. 137a). Very often, especially in human lymph nodes, they are completely wanting; sometimes, in active lymph nodes, they are very numerous in the dense parts of the lymphoid tissue—in the primary nodules (follicles) and in the medullary cords as well as in the sinuses. In such cases they are often found in mitotic division (Fig. 133c). The medium-sized lymphocytes also often show mitoses. The small lymphocytes, on the contrary, under normal conditions seem never to divide. They arise through the mitotic proliferation of the larger forms.

The mitoses of the large and medium-sized lymphocytes are found throughout the whole mass of the lymphoid tissue, the sinuses included. Thus the regeneration of the lymphocytes seems largely to take place

through independent mitotic proliferation of the large and medium-sized lymphocytes everywhere in the meshes of the reticulum in the lymphoid tissue. However, this is not the only manner of lymphocyte production. An important rôle is played in this respect by the so-called germ centers.

It may be added that the only type of division observed in lymphocytes is mitosis. The possibility of amitotic division, as claimed by Mar-

FIG. 137.—Part of a germ center of a rabbit's lymph node, a, large, b, medium-sized c, small lymphocytes with chondriosomes; d, cells of the reticular syncytium. Fixation Champy, staining Kull. × 1500.

chand (1913), Pappenheim (1919) and others, has never been substantiated by facts.

3. *The germ centers:*

The primary nodules (follicles) of the lymphoid tissue very often contain a round central area, staining lighter than the periphery. Flemming (1885) has shown that it contains cells with large pale nuclei and numerous mitoses; he believed these foci to be the chief, although not exclusive places

of multiplication of lymphocytes and therefore called them "germ centers." At the present time the term "secondary nodules" is often being used instead.

The conception of the germ centers as the principal foci of multiplication of lymphocytes has been generally adopted; however, the ideas of their cellular constitution as found in the textbooks are remarkably vague.

FIG. 138.—Part of a germ center of a rabbit's lymph node, with lymphocytes showing black Golgi-net and pale chondriosomes; r, cells of the reticular syncytium. Fixation Champy, osmic acid impregnation Kolatschev-Nassonov; unstained. × 1500.

In clinical hematology which, speaking generally, agrees with the dualistic doctrine, the small lymphocytes are supposed to originate in the germ centers from the division of "germ center cells" or "lymphoblasts" ("Lymphogonia" according to Benda, 1897; "large lymphocytes" of the unitarians); these peculiar cells are generally believed to be present only in

the secondary nodules; from the dualistic point of view they are specific elements and are unable to produce anything but small lymphocytes. Their morphological characteristics in most cases are not established on the basis of the study of the germ centers. On the contrary, the material used for this purpose by the clinical hematologists is pathological human blood, especially from cases of acute lymphatic leucemia. The descriptions and pictures given by the various authors sometimes are very different.

Weidenreich (1911) and Downey and Weidenreich (1912), representatives of the unitarian doctrine, have made a detailed study of the cellular composition of the germ centers. They found that the latter, even under physiological conditions, present an extraordinary variety in the general appearance and in the structure of their cells with regard to size, the relative volume of nucleus and protoplasm, the degree of basophilia, etc. The same is true for the conditions of the macrophages and the number and arrangement of the large, medium-sized and small lymphocytes. They drew the conclusion that there does not exist a special "germ center cell." The larger forms of lymphocytes, which are generally considered as the mother cells of small lymphocytes, may occasionally be present everywhere and not only in the germ centers. The same authors also describe the formation of lymphocytes from fixed reticular cells, a phenomenon which was already admitted by Flemming.

In the lymphoid tissue of embryos and new-born mammals no germ centers can be found (Baum and Hille, 1908). They reach the height of their development in the young organism. With advancing age their number decreases and in old age they disappear. But even in the adult organism they are not constant. They may disappear and arise again according to the changing physiological conditions. The lymphoid tissue in the germ centers undergoes cyclic transformations, showing different phases which in part were noticed by Flemming (1885), Benda (1896) and Downey and Weidenreich (1912). As a rule all germ centers of a lymph node, perhaps of the whole body, show similar conditions at a given time.

(*a*) ACTIVE PHASE

On the climax of its activity the microscopic picture of a germ center is very characteristic and looks quite similar in different species of mammals (Fig. 139). It is a more or less sharply outlined, lightly stained, round or oval area, sometimes of more than 1 mm. in diameter (in man). Each secondary nodule is supplied by a special small arteriole.

Contrary to the current opinion, the majority of the cells in a germ center do not correspond to the well-known type of the large lymphocytes (Fig. 139a). The tissue is formed by a compact agglomeration of more or less uniform, mostly medium-sized lymphoid elements (Fig. 139b). Sometimes they are so densely crowded together that their outlines become indistinct.

In some animals, for instance, in the cat, the pictures are especially clear and simple. The germ center contains almost exclusively medium-sized lymphocytes; due to mutual pressure they have polyhedral forms and are separated from each other by thin, clear clefts. On sections they some-

FIG. 139.—Part of an active germ center of a human lymph node. The majority of the cells are medium-sized lymphocytes (b), showing numerous mitoses (b'); a, large, c, small lymphocytes; d, nuclei of the embryonic reticular syncytium with mitoses (d'); e, macrophage. Zenker formol, hematoxylin, eosin azure. × 750.

times seem to be arranged in the form of broad, branching and anastomosing cellular cords; this appearance is due to their position in the meshes of the capillary network. Among the medium-sized cells some few small ameboid lymphocytes, with dark nuclei and transitional forms

between these two cell types, are occasionally seen. Typical large lymphocytes are also scattered singly or in small groups; they can be at once recognized by the dark blue protoplasm (after eosin azure stain) and by the large, pale, vesicular nucleus with the large nucleoli, stained purple with eosin azure. Transitional forms between them and the medium-sized lymphocytes are always present in varying numbers. Finally, a few scattered, pale, oval nuclei between the lymphocytes have to be mentioned; they belong to the reticular syncytium.

A very characteristic feature of an active germ center, after it has reached a certain size, are giant, round macrophages, of 30μ in diameter or even more; they are plainly seen under low power as clear spots and are scattered at regular distances from each other throughout the germ center. This regular distribution is due to their arrangement along the blood capillaries. Their protoplasm is extremely pale and always contains a varying quantity of phagocytized inclusions, mostly darkly staining particles of chromatin, originating from degenerated lymphocytes and described by Flemming as "stainable bodies" ("tingible Körper"). In animals vitally stained with lithium carmine, the histiocytes of the reticulum, especially in the sinuses, are storing large quantities of the dye; the elements of the reticular syncytium in the germ centers and the macrophages just mentioned, on the contrary, do not contain dye inclusions.

It seems an established fact that the macrophages of the germ centers all originate from the reticular elements and not from the lymphocytes.

The tissue of the active germ centers in man looks somewhat different (Fig. 139). Here the form and size of the medium-sized lymphocytes are not so uniform. Instead, the tissue consists of a multitude of densely crowded nuclei of slightly varying size, 6μ to 8.5μ on the average; their protoplasm is very pale and not always distinctly outlined (Fig. 139b). The membrane of the nuclei shows irregular folds and wrinkles; in the interior a varying number—mostly two or three—of small nucleoli can be distinguished. The quantity of chromatin granules also varies, probably depending on the time of the preceding or impending mitosis in the respective cell. The small ameboid lymphocytes with more or less typical dark nuclei are more numerous than in the cat; they are connected with the medium-sized cells by a series of intermediate forms (Fig. 139c).

The large lymphocytes are very numerous (Fig. 139a); however, they usually do not attain an excessive size. A series of transitional forms with nucleoli increasing in size and undergoing fragmentation clearly indicates their gradual development from the smaller cells.

The pale, oval nuclei of the reticular syncytium (Fig. 139d), as well as the typical large macrophages (Fig. 139e), arranged along the capillaries, are always clearly visible. In the center of the secondary nodule, around the

arteriole, sometimes a small area of particularly large and pale concentrically arranged reticular nuclei can be distinguished.

In every germ center of the active type a large number of mitoses can be seen. As Flemming first pointed out (1885), they are certainly much more numerous than in the other parts of the lymphoid tissue. They are found mostly in medium-sized lymphocytes (Fig. 139b'), and only a relatively small number belongs to the large cells. Besides, mitoses are very common in the nuclei of the reticular syncytium (Fig. 139d'). The large pale macrophages rarely show mitosis.

Thus, the most important rôle in the physiological cytopoiesis in the germ centers of the lymphoid tissue is played not by the large, but by the medium-sized lymphocytes. Nevertheless this does not warrant the designation of the latter as peculiar specific "germ center cells."

The large lymphocyte is not to be looked upon as the true mother cell of the small lymphocytes, as a "lymphoblast." The quantity of these cells in the germ centers is subject to great variations and they may be even completely absent. They may arise, as we shall see, directly from the undifferentiated elements of the reticular syncytium, but their most common manner of origin is the hypertrophy of a proliferating medium-sized lymphocyte. The large lymphocytes may be looked upon as a side branch of the cell lineage of the lymphocytes and seem to represent merely a temporary condition of the lymphocytoid cell type.

In the later stages of the active germ center, described below, the large lymphocytes, together with the other types, gradually recede towards the periphery of the primary nodule (follicle) and may enter the sinuses. On their way into the sinuses and later, in the lymph of the lymphatics, they may continue to divide and to produce smaller forms.

Under physiological conditions, as has been mentioned, the large lymphocytes do not enter the blood stream, probably because, before reaching the blood, they undergo division into smaller cells (Weidenreich, 1909, 1911). They seem to be unable to migrate out of the lymphoid tissue directly into the blood vessels, as do the small lymphocytes. Many of them, especially the giant forms, may degenerate in the lymphoid tissue.

The lightly staining tissue of the active growing germ center, as a rule, shows sharp outlines; beyond these limits, at the periphery of the primary nodule, the tissue stains darkly and consists almost exclusively of densely crowded, small lymphocytes, sometimes arranged in regular concentric layers with only a few pale nuclei of reticular cells between them.

The characteristic sharply outlined boundary between the light active secondary nodule and the dark periphery of the primary nodule with its concentric layers of small lymphocytes is the result of the pressure exerted by the rapidly growing germ center upon the older lymphoid tissue with its small lymphocytes.

(*b*) RESTING PHASE

During the period of complete rest in the center of the primary nodule with its dark crowded masses of uniform small lymphocytes and scarce reticular nuclei, the arteriole is seen surrounded by a small pale area. The latter consists of concentrically arranged oval nuclei of the embryonic reticular syncytium and of a small number of partly degenerated small lymphocytes. Degenerating, shrunken reticular nuclei are also of common occurrence. No mitoses are present.

This resting period sometimes may last very long. In such cases—this is very common in human material—the primary nodules are very small, contain exclusively small lymphocytes and even the small, clear perivascular area of reticular nuclei can be missing. The arteriole, however, always keeps its position. If, therefore, the germ centers are transient, fluctuating formations, the place of their possible reappearance seems nevertheless to be constant and to be connected with the end branches of small arteries.

(*c*) BEGINNING OF A NEW ACTIVE PHASE

The beginning of a new active period of a resting germ center is marked by the hypertrophy and mitotic proliferation of the embryonic reticular cells in the immediate neighborhood of the above-mentioned arteriole. A small pale area develops, which at first is not distinctly outlined and rapidly increases in size (Fig. 140). It is distinctly seen that the mitoses belong to the undifferentiated reticular syncytium (Fig. 140b). The participation of endothelium or other "cells of the blood vessel walls" ("Gefässwandzellen" of the German authors) can be excluded with certainty. The mitoses give rise to numerous cells with pale nuclei, as they were described above for the florid germ center. At first they are as yet somewhat different from the typical medium-sized lymphocytes—the nucleus is paler, less regularly outlined and the protoplasm does not show a noticeable basophilia (Fig. 140c). At any rate they are now free ameboid cells of medium size, which continue to divide and soon acquire the characteristic features of true medium-sized lymphocytes. During a long time, while the new active germ center grows, a continued transformation of proliferating reticular elements into such free cells may be observed. Among the fixed and free cells with the pale nuclei in all young germ centers a few ameboid small lymphocytes can be found; they are to be looked upon partly as small lymphocytes which remained in this place from the time of the previous active period; partly, however, they arise from the medium-sized cells with the pale nuclei, the atypical mesolymphocytes, in the manner described below, through division or through direct transformation. At the very beginning of the development of the new germ center the appearance of

large lymphocytes can also always be seen (Fig. 140d); however, their number is very small at first. As a rule, they arise through hypertrophy of the medium-sized cells, but direct development from the fixed embryonic reticular cells through rounding off and isolation also occurs (Fig. 142a). Then, gradually, along the capillaries the large, pale macrophages develop.

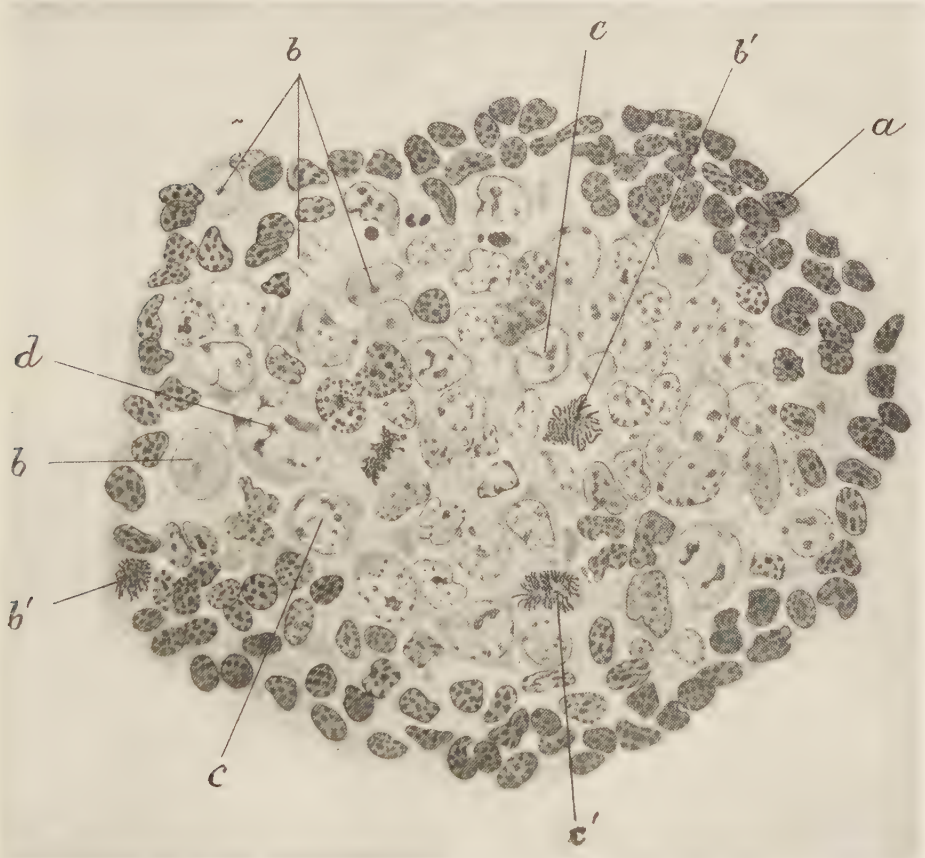

FIG. 140.—Beginning of a new period of activity in the germ center of a human lymph node; a, small lymphocytes; b, nuclei of the embryonic reticular syncytium, with mitoses (b′); c, newly formed medium-sized lymphocytes with mitoses (c′); d, newly formed large lymphocytes. Zenker formol, hematoxylin, eosin azure. × 750.

The growing clear area is surrounded by a darkly staining zone of small lymphocytes. The limit between the two, which is somewhat indistinct at first, becomes more and more prominent as the area gains in size; when the germ center reaches its full activity, it appears, as we have seen, as a sharply drawn line and is surrounded by concentric layers of small lymphocytes.

(*d*) TRANSITION FROM ACTIVE INTO RESTING CONDITION

The length of the active period remains unknown. It is possible that the changes of the blood supply of the tissue, which necessarily result from the considerable increase in size, automatically regulate the duration of the period of growth.

When the germ center has attained its maximal size, the majority of the daughter-cells, originating from the mitoses of the medium-sized cells, transform themselves into small lymphocytes. We have seen that this may be observed on a small scale at the very beginning of the period of growth; the extensive development of this phenomenon, however, is a symptom of the impending end of the active period (Fig. 141).

According to the current opinion—which, however, is not based on direct observations—the small lymphocytes with the dark nucleus are believed to originate at once from the last mitoses of the larger forms (Fig. 141b'). For a part of the cells this may be true, the more so as the true mother cells of the small lymphocytes are not the large, but the medium lymphocytes and as the differences in size and structure are not excessive. Another possibility, however, also has to be admitted and the microscopic pictures of the corresponding stages seem to fit it even better. The transformation of the larger forms, the more or less typical mesolymphocytes with the paler nucleus, into the small lymphocytes with the darker nucleus and the larger chromatin lumps may be independent of mitotic division and might be due simply to changes of the individual cells, combined with condensation and loss of water. At the end of the active period everywhere in the germ center numerous transitional forms from the mesolymphocytes to the small lymphocytes appear. The number of mitoses does not increase at the same time. The nucleus of the respective cells becomes smaller, shows irregular wrinkles on the membrane and larger chromatin granules. The large lymphocytes seem not to participate in this process and remain apparently unchanged among the masses of the newly formed small lymphocytes (Fig. 141a). They contain occasional mitoses.

During this rapid development of large quantities of small lymphocytes the volume of the secondary nodule seems to decrease. Besides, the sharp limit between the light germ center and the dark "marginal zone," i.e., the ring of small lymphocytes at the periphery of the primary nodule, disappears probably as the result of the decrease of the growth pressure. The crowds of the newly formed small lymphocytes in the germ center can no longer be sharply separated from the older generations of small lymphocytes in the marginal zone. Simultaneously the typical light appearance of the germ center area gradually becomes indistinct. These changes proceed from the periphery toward the center and thus the secondary nodule returns to its resting condition described above.

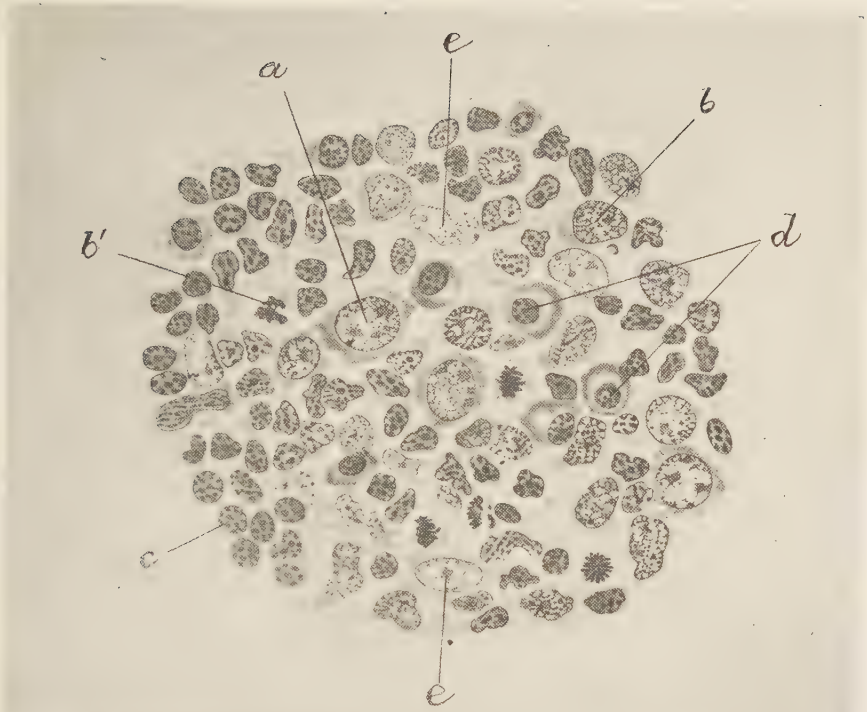

141

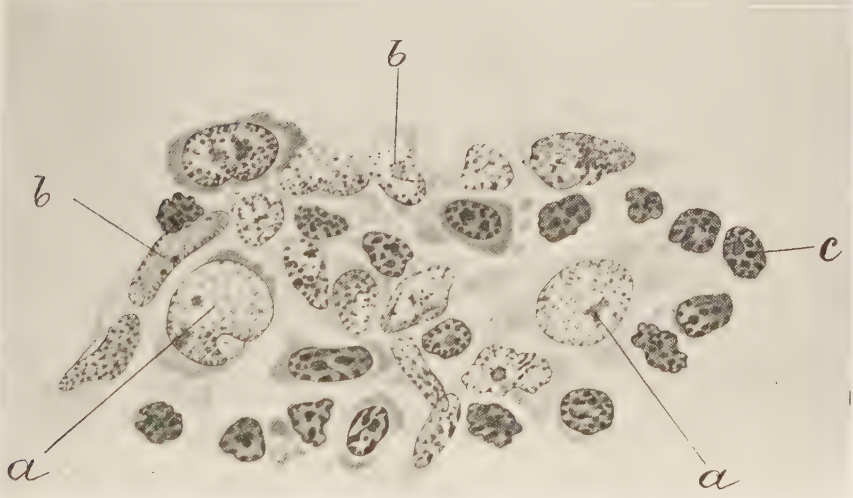

142

FIG. 141.—Part of a germ center of the human tonsil, in the stage of involution; a, large lymphocytes; b, medium-sized lymphocytes, with mitoses (b′); c, small lymphocytes; d, plasma cells; e, cells of the reticular syncytium; Zenker formol, hematoxylin, eosin azure. × 750.

FIG. 142.—Formation of large lymphocytes (a) from the embryonic reticular syncytium (b), in a small, newly formed lymph nodule in the mesentery of a rabbit, injected with phenylhydrazine and sapotoxin; c, small lymphocytes. Zenker formol, hematoxylin eosin azure. × 1000.

The newly formed lymphocytes are particularly small and possess an extremely thin layer of protoplasm. For a while they seem to lose the capacity of mitotic division. These "young" small lymphocytes were called "prolymphocytes" by Ferrata (1918). They are believed not to enter the blood circulation under normal conditions, but are found in the blood in lymphatic leucemia (lymphadenosis). The normal blood seems to contain only older small lymphocytes with a larger amount of protoplasm.

Sometimes large germ centers in a late stage of the proliferation period or in the stage of transition into the resting condition are found, in which the first traces of a new growth period have already appeared. In such cases the central arteriole is surrounded by several concentric zones of various width and of different cellular nature.

The comparison of the germ centers in their different periods of development shows that the cell transformations and the proliferation phenomena are returning and succeeding each other in cycles and expand centrifugally from the central arteriole in concentric waves.

4. *The functional significance of the germ centers:*

Flemming's (1885) conception of the germ centers as the principal foci of proliferation of lymphocytes has been recently contested by Hellmann (1921) and Heiberg (1923, 1925*a*, *b*). Several investigators have adopted their point of view (Latta, 1921; Pol, 1923; Heilmann, 1925 and others).

According to Hellmann and Heiberg the germ centers are of no importance for the regeneration of lymphocytes, which occurs everywhere in the diffuse lymphoid tissue. They are "centers of reaction to bacterial and toxic stimuli, acting upon the lymphoid tissue and are the visible expression of work performed by the tissue for this purpose. If the stimulus is slight, productive changes occur; if it is intense, the cells of the germ center will display degenerative phenomena. Among the facts on which this new theory is based may be mentioned the necrotic and inflammatory changes in the secondary nodules, occasionally observed under physiological conditions but especially common in infectious diseases, the absence of germ centers in the embryo, the sharp limit and the absence of transitional forms between the lightly staining tissue of the germ center and the darkly staining peripheral zone of small lymphocytes, etc.

It is quite probable that the lymphoid tissue in general and the germ centers in particular may take part in the defense reactions of the organism. It is also certain that the germ centers are not absolutely necessary for the regeneration of lymphocytes, as in the embryo and in the new-born infant they are not clearly developed. Flemming (1885) himself has emphasized that mitoses of lymphocytes can be very numerous outside the secondary nodules. Nevertheless it is quite evident that the sharply localized, intense mitotic proliferation of the lymphocytes and their extensive new formation from fixed cells in the active germ centers cannot be compared with the relatively low rate of proliferation in the other parts of the lymphoid tissue. This alone is sufficient for proving the importance of the germ centers for the production of lymphocytes. The sharp limit line between the light tissue of the active center and the dark marginal zone—a fact which is quoted against the cytopoietic importance of the germ centers—proves exactly the contrary. If the existence of centrifugal growth in the center is admitted, the lack of this distinct boundary line would be incomprehensible. A certain amount of degenerative and phagocytic phenomena is often present in the germ centers, even

under normal conditions; however, this need not surprise us, since, for instance in the seminiferous tubules of the normal testis, similar phenomena commonly occur on a much larger scale. The degeneration is especially pronounced in infectious diseases and in cases of local pathological conditions. An extracellular dissolution of lymphocytes in the germ centers, as emphasized by Hellmann and Heiberg, is a purely hypothetical assumption (Wätjen, 1925).

In view of the described regular cyclic growth phenomena in the germ centers their importance as the principal places of regeneration of lymphocytes, as formulated by Flemming, has to be maintained.

5. *The interrelations of the different forms of lymphocytes:*

The three described forms of lymphocytes in the lymphoid tissue are connected with each other by a series of transitional forms. This was especially emphasized by Downey and Weidenreich (1912). The number and conspicuousness of these transitional forms vary, however, with the functional changes of the tissue. In the active condition of the latter—for instance in certain phases of development of the germ centers—it may be difficult in general to discriminate between the lymphocytes of various sizes. In the resting tissue, on the contrary, the small lymphocytes with their dark nuclei seem to be independent of the larger lymphocytes with the clear, vesicular nucleus.

It is evident that between the three forms of lymphocytes the most intimate genetic relationship must exist. This is shown not only by the histogenetic facts, but also by the study of any smear of the lymphoid tissue after either moist or dry fixation. The nature of this interrelationship is explained differently by the various investigators.

According to the general opinion the medium-sized lymphocytes arise through division of the large ones and the small ones again through division of the medium-sized. Therefore, Benda (1896,1897) called the large lymphocytes "Lymphogoniae." The dualists, who believe them to produce exclusively small lymphocytes, look upon them as "Lymphoblasts" (Schridde, 1907; Nägeli, 1923,1925). The study of the germ centers has shown us, however, that this idea of the exclusive rôle of the large lymphocytes in the production of lymphocytes cannot be maintained.

The possibility of the backward transformation of the small lymphocytes into larger forms through increase in size and hypertrophy is still under discussion. It is obvious that the microscopic appearance of both processes, leaving aside the mitoses—the development of small lymphocytes from and, vice versa, their transformation into the large ones—must be identical.

The majority of the representatives of the so-called unitarian theory of hematopoiesis believe the small lymphocytes to be merely a temporary condition of the lymphocytic cell type. This necessarily implies the conclusion that they keep the same undifferentiated condition as their mother cells, the large and medium-sized lymphocytes: their potencies of develop-

ment must be unrestricted. If they do not show mitotic division, this has to be looked upon as a transitory suppression of the capability of multiplication. After a certain unknown lapse of time—provided the conditions of the outer medium are suitable—they again enlarge and transform themselves into proliferating medium-sized and large lymphocytes. This does not preclude, of course, other possibilities of transformation or differentiation.

The backward transformation of the small lymphocytes into the large forms, as well as their other developmental possibilities, need not necessarily manifest themselves in the lymphoid tissue—the place of their origin—under physiological conditions. It is quite possible that the small lymphocytes, as a rule, first have to enter the blood and to circulate there before being "activated" for the progressive development under the influence of suitable external conditions (Maximow, 1909*d*, *e*, 1923; Babkina, 1910). This idea finds support in a series of different facts—the histogenesis of the experimental extramedullary myelopoiesis, the histogenesis of inflammation, the transformation of the lymphocytes in tissue cultures, etc.

From this point of view the small lymphocytes appear not as specific and irreversibly differentiated cells, uncapable of further development, but as temporary products of a proliferation; they can transform themselves again into large lymphocytes and eventually give rise even to blood cells (Benda, 1896; Dominici, 1901*a*, *b*; Maximow, 1907, 1923; Wallgren, 1909; Pappenheim, 1905 to 1912, 1919; Weidenreich, 1909, 1911; Downey and Weidenreich, 1912; Helly, 1914; Latta, 1921; Downey, 1924 and others).

The dualists and most of the clinical hematologists (Türk, 1904 to 1912; Nägeli, 1923), on the contrary, in conformity with the original theory of Ehrlich, emphasize the specific nature of the small lymphocyte and look upon it as a highly differentiated cell incapable of progressive development and of proliferation. Ferrata (1918) also denies the possibility of their transformation into granular leucocytes and histiocytes (hemohistioblasts) as well.

This theory necessarily leads to the conclusion that the small lymphocytes, after having fulfilled their hypothetical functional activities in the very place of their origin or in the blood, are doomed for destruction. This is supposed to happen partly in the lymphoid tissue itself, viz., in the germ centers. The majority of the small lymphocytes, however, are supposed to migrate through the wall of the digestive tract and to leave the organism in this way. Bunting and Huston (1921) have calculated that during twenty-four hours more lymphocytes pass from the lymphoid tissue into the blood than the totality of the latter contains at any time. As degenerating lymphocytes seem not to be present in the circulation, their excess must be lost through their migration into the lumen of the digestive tract. This phenomenon is supposed to be connected with the function of the lymphocytes and with their destruction as well.

6. Relations of the lymphocytes to the reticulum and to the histiocytes of the lymphoid tissue:

The admission of the development of the first lymphocytes from fixed mesenchymal cells in the embryo is a logical necessity and it is easy to demonstrate this phenomenon. In the adult organism, on the contrary, the new formation of lymphocytes from fixed cells seems not to be an absolute necessity, as the lymphocytes are present everywhere and themselves possess an unlimited capability of proliferation. However, it might be expected that here, too, besides the homoplastic regeneration, a continued neoformation from fixed cells of embryonic character is also going on.

Under physiological conditions, as has been mentioned, usually no transitions can be found in the lymphoid tissue between the lymphocytes and the elements of the reticulum. This is especially manifest when vital staining is used (Goldmann, 1909,1912; Tschaschin, 1913; Kiyono, 1914). The histiocytic reticular cells store the vital dyes and phagocytize. The lymphocytes, on the contrary, remain colorless, do not phagocytize and occupy the meshes of the reticulum as seemingly foreign elements.

This problem appears not to have been investigated very thoroughly. The majority of the writers do not think much of the possibility of the development of lymphocytes from fixed cells (Kiyono, 1914). The opposite point of view is represented by Downey and Weidenreich (1912). Marchand (1913) and Jolly (1923) also admit the formation of new lymphocytes from the reticular cells of the germ centers. Maximow (1923) saw development of large basophilic lymphocytes from reticular cells in tissue cultures; in such abnormal conditions this transformation could be seen taking place even in elements which apparently had already begun their differentiation into histiocytes and contained pigment inclusions.

The cyclic tissue transformations in the germ centers, described above, show that at certain periods the development of new lymphocytes from the reticulum can easily be demonstrated. It has to be emphasized, however, that in this process the active rôle is played not by the fully differentiated histiocytes which store the vital dyes, but by the undifferentiated part of the reticulum, whose elements do not show any appreciable amount of vital staining and phagocytic activity.

When a new active germ center starts its development in the interior of the primary nodule, and the clear area appears around the arteriole, only a few partly degenerated lymphocytes of previous formation can be found between the hypertrophying pale nuclei of the syncytium. When the pale syncytial nuclei begin to divide mitotically, many of them isolate themselves from the syncytium, much in the same way as happens in the embryo. The small or large, clear, round, oval or irregularly wrinkled nucleus surrounds itself with a narrow, at first somewhat indistinctly outlined, rim of

slightly basophilic protoplasm (Fig. 10c). In its interior larger and more numerous nucleoli and coarser chromatin granules appear. In this way medium-sized or large lymphocytes arise; they continue to divide mitotically and form, as has been described above, the major part of the growing germ center. In the later stages of the active period of the germ center the proliferation seems to occur chiefly in the free cells, the medium or large lymphocytes, whereas the new formation of lymphocytes from the undifferentiated reticulum subsides and ceases completely as soon as the germ center returns to the resting condition.

Whereas in the fully developed lymph nodes the development of lymphocytes from fixed cells seems to be confined to the germ centers, it is easy to demonstrate the same process everywhere in the diffuse lymphoid tissue of young, newly formed lymph nodes in the adult organism (Fig. 142a).

Regarding the possibility of the development in the opposite direction, i.e., the transformation of lymphocytes into fixed cells, the backward transformation of the former into undifferentiated elements of the mesenchymal reticular syncytium seems improbable. On the contrary, the transformation of lymphocytes into histiocytes, as we shall see, is possible.

7. *Origin of lymphocytes in the embryo:*

For the dualistic theory of hematopoiesis, which believes that the lymphocytes are highly differentiated cells and that they, on the one hand, and the undifferentiated, nongranulated, basophilic cells of the myeloid tissue (i.e., the bone marrow), on the other hand, are different cells, with different prospective potencies, the exact determination of the place and time of the first appearance of the lymphocytes in the body of the embryo is of high importance. However, exact embryological investigations have not been published by this group of authors. They merely emphasize the appearance of typical small lymphocytes in late embryonic stages, at a time when the yolk sac, the first hematopoietic organ of the embryo, has undergone involution and the development of "myeloid" elements, granulocytes and erythrocytes in the other blood-forming organs of the embryo, the liver and the bone marrow has reached a very high degree. Schridde (1908) believes that, whereas the stem cells of the myeloid elements (the myeloblasts) arise from the walls of embryonic blood vessels, the lymphocytes develop from the endothelium of lymphatic vessels. This arbitrary statement has never been confirmed.

The study of the embryonic development of connective tissue and blood in the mammals and in the other classes of vertebrates (Maximow, 1907, 1909*b*, 1910, 1923; Dantschakoff, 1908, 1909*a*, *b*, 1916) has shown that typical small lymphocytes appear in larger quantities in the later embryonic period, in the mammalian embryo especially in the primordia of the lymph nodes. However, as has been already discussed above, no sharp distinction can be made between the larger forms of lymphocytes and their smaller forms. Besides, from the standpoint of the unitarian theory, the large lymphocytes (lymphoblasts) and the undifferentiated, basophilic stem cells of the myeloid tissue (myeloblasts) are identical—they are all to be looked upon as hemocytoblasts, as the common stem cell of all blood elements. Therefore the exact determination of the first appearance of the true small lymphocytes is impossible.

The first blood cells of the embryo—the primitive blood cells of the area vasculosa—are elements with a histological structure exactly resembling large lymphocytes. They

remain as hemocytoblasts in the vessels of the yolk sac. In the embryonic mesenchyme the same elements arise from the fixed mesenchymal cells through contraction and isolation as lymphocytoid wandering cells. The same cells again, splitting off from the mesenchyme, mark the beginning of hematopoiesis in the liver and the bone marrow and the lymphoid infiltration of the thymus primordium. Atypical specimens can be found among them wherever they appear, which are smaller, have a darker nucleus, a thin layer of protoplasm and more or less remind one of small lymphocytes. At the same time, the hemocytoblasts in the early embryonic stages show all transitions to wandering cells of the histioid or histiocytic type, with an abundant pale protoplasm and a small, irregular nucleus.

In the embryonic bone marrow, wandering cells, structurally similar to small lymphocytes, are common. They are especially numerous in the chick embryo. It is true that the typical small lymphocytes appear in large quantities only in the primordia of the lymph nodes, but even here they show all transitions to larger forms, and numerous atypical transitional forms are present.

In short, all free mesenchymal cells of the embryo, being at first equipotential, are at the same time highly polymorphous and to some extent have the structure of more or less typical small lymphocytes.

Thus the very idea of the first appearance of the lymphocytes as a specific cell type at a certain period of embryonic development is untenable. It is as futile an attempt as to try to determine at what exact period the first "myeloblast" appears in the embryo. The lymphocytes in their various forms—the large, the medium-sized and the small—are merely different structural modifications of one and the same cell type—the free wandering mesenchymal lymphocytoid cell—the hemocytoblast. They are present in the body of the vertebrate from the first stages of blood formation. The relative number and the further development of these various representatives of the lymphocytoid cell type depend on the conditions of the external medium surrounding the cells at the various places in the body. The characteristic small lymphocytes do not appear at once at a specific stage of development and at a special region of the embryonic body. They may sporadically originate in various parts of the diffuse mesenchyme or in the blood-forming organs. Their development in large quantities in the lymph node primordia of the mammals must be due to peculiar conditions prevailing in these areas, which favor the predominance of this peculiar type of mesenchymal wandering cells in preference to other types which, on the contrary, are more abundant in other places.

8. *Genetic interrelationships of the lymphocytes and the other cells of connective tissue and blood. Developmental potencies of lymphocytes:*

One of the fundamental problems of morphological hematology concerns the nature and the prospective potencies of the large lymphocytes of the lymphoid tissue on the one hand and the large, basophilic, undifferentiated cells of the myeloid tissue on the other hand. The so-called dualistic theory of hematopoiesis believes these two cell types, although structurally similar, to be quite independent from each other and to possess different prospective potencies. Whereas the large lymphocytes are supposed under all circumstances to produce only lymphocytes and therefore are called "lymphoblasts," the second cell type, the "myeloblasts," are thought to give rise exclusively to erythrocytes and granular leucocytes. Thus two separate

stem cells for the lymphoid and the myeloid elements have to be admitted. According to the unitarian theory, on the contrary, the two cell types are not only histologically similar, but have identical prospective potencies. The different results of their multiplication and differentiation in the lymphoid and myeloid tissues respectively are due to the different environment surrounding the cells. There exists only one stem cell, which may be conveniently called "hemocytoblast," a term introduced by Ferrata.

In fresh, living condition the "lymphoblasts" and the "myeloblasts" cannot be distinguished from each other. The supravital (agonal) neutral red-Janus green technique reveals in both a varying quantity of granular or rod-shaped chondriosomes (Cunningham, Sabin and Doan, 1925). After fixation and staining both cell types show the same picture. The differences between the individual cells in the lymphoid or myeloid tissue sometimes are greater than between the lymphoblasts and myeloblasts (Maximow, 1909).

The dualists (Nägeli, 1900; Schridde, 190– and others) have endeavored to find out specific structural differences; however, the number of nucleoli, the absence of the "specific granules" (chrondriosomes) in the myeloblasts, the clear perinuclear area in the lymphoblasts, etc., have all failed as decisive criteria. At the present time the dualists themselves have to admit that the large lymphoctyes and the stem cells of the myeloid elements cannot be distinguished after ordinary moist fixation and staining. Only dry smears, stained with the panoptic method of Pappenheim, are supposed to show specific structural differences, especially in the nucleus. It may be mentioned that Ellermann (1923, 1924) has recently attempted to differentiate the two types of lymphoid cells on the basis of the angle of the spindle in their mitotic figures. In the lymphoblasts it is 34° to 46°, in the myeloblasts 63° to 75°.

Besides the structural differences, the biochemical and functional character of the two cell types has been pointed out. Whereas the myeloblasts and their derivatives contain proteolytic and especially oxidizing enzymes and give the oxidase reaction, the lymphoblasts and lymphocytes react negatively (Winkler, 190–; W. Schultze, 1909; Katsunuma, 1924). However, the importance and the specificity of the oxidase reaction have been greatly minimized by the work of the latest investigators (Menten, 1919; Kwasniewski, 1924; Gräff, 1925).

Another reason for the sharp discrimination between the lymphoid and myeloid stem cells is seen by Nägeli (1923, 1925) in the different localization and arrangement of the elements of the two tissues. Although this may be true to a certain extent for the mammals, the comparative study of the blood-forming tissues in the lower vertebrates completely disavows this idea. In amphibians and fishes, speaking generally, the same cell types are present in the blood and connective tissue as in the mammals. But lymphoid

and myeloid tissue cannot be distinguished; their elements are indiscriminately mixed in the blood-forming organs, and there exists only one type of lymphocytoid basophilic cell. In the circulating blood itself all transitions can be occasionally found, from these non-granulated lymphoid cells, the lymphocytes or hemocytoblasts, to mature blood elements (Freidsohn, 1910; Werzberg, 1911; Weidenreich, 1911; Jordan and Speidel, 1923, 1924; Alder and Huber, 1923).

The different reaction of the lymphoid and myeloid elements under pathological conditions has also been considered by the dualists as a proof for the fundamental separation of the two types of lymphocytoid stem cells. A peculiar antagonism between the two tissues was believed to manifest itself. In cases of myelosis, for instance, the red pulp of the spleen undergoes myeloid metaplasia and crowds out the lymphoid follicles. Lymphadenosis, on the contrary, brings about an enlargement of the follicles and their confluence to a diffuse mass of lymphoid tissue. From the unitarian viewpoint the different reaction of one and the same stem cell to a pathological stimulus is easily explainable, if the different position of the cell in the various organs and the different external conditions of its existence be taken into consideration. Besides, many facts, which were supposed to sustain the idea of the antagonism between the myeloid and the lymphoid elements and their different reaction to abnormal factors, seem to change their aspect in the light of recent investigations.

Thus, according to Nägeli (1923, 1925), when extramedullar hematopoiesis occurs in lymph nodes, only the so-called "interfollicular tissue" is affected; whereas in the germ centers, where only true lymphocytes are supposed to be located, myelocytes never appear. Roman (1913), Citron (1915), Fineman (1922) and Logefeil (1924) have, however, observed cases of leucemia in which just the germ centers were found to be centers of myelopoiesis. Dominici as early as 1901 (*a*, *b*) succeeded in obtaining the same experimentally. Maximow (1907) has shown that when myeloid tissue develops in the rabbit's kidney after ligation of its blood vessels, the erythroblasts and myelocytes originate from the lymphocytes of the blood, stagnating in the blood capillaries. Lang (1926*a*), in an extensive study on experimental production of extramedullar myelopoiesis, has conclusively shown formation of myelocytes and erythroblasts originating from circulating hemocytoblasts which could not be distinguished from lymphocytes; furthermore, in the lymphoid tissue he found a most striking transformation of the large lymphocytes in the germ centers into special myelocytes. Bloom (1926) observed under experimental conditions in the primary nodules and germ centers of spleen and lymph nodes of the guinea pig the direct transformation of typical small lymphocytes into special "micromyelocytes." Using the method of tissue culture, Maximow (1923*b*) attempted artificially to change the external conditions for the lymphocytes

by explanting them into a medium which would as nearly as possible correspond to the medium normally surrounding the lymphoid stem cells in the myeloid tissue and might induce them to display their latent granulopoietic potencies. In fragments of lymphoid tissue, developing in vitro in a mixture of blood plasma and bone marrow extract, he observed proliferation of large lymphocytes with differentiation into special and eosinophilic myelocytes and megacaryocytes.

Taking into consideration the whole amount of facts accumulated at the present time in the hematological science, one has to draw the conclusion that the evidence is strongly in favor of the identity of the "myeloblasts" and "lymphoblasts," of the existence of one common indifferent "lymphoid" stem cell for all elements of the blood. This stem cell, the "hemocytoblast," is structurally not always absolutely uniform. In its active condition it is a large cell with a clear, vesicular nucleus and with a narrow rim of basophilic protoplasm and histologically exactly corresponds to the large lymphocyte. In the lymphoid tissue as the lymphoblast, and in the myeloid tissue as the myeloblast, the hemocytoblast may produce, through proliferation, daughter cells of a smaller size, which are convenient for transportation in the tissue liquids, keep the total amount of prospective potencies, but for a while do not display them and remain in a resting condition. They are the small lymphocytes of the lymphoid and the so-called micromyeloblasts of the myeloid tissue. Under the action of external stimuli the small lymphocyte, the temporarily inactive hemocytoblast, may develop in various directions, either hypertrophying without differentiation and returning to the condition of the large lymphocyte (hemocytoblast) or differentiating (with a partial loss of potencies) into cells of the monocytic or histiocytic type. This latter transformation is observed especially in inflammation and in the conditions prevailing during the life outside the body, in tissue cultures.

Maximow (1902, 1903, 1904, 1905, 1906, 1909*d*) has shown in his studies on experimental inflammation that the mononuclear exudate cells, found in any type of inflammation, the so-called polyblasts, arise from two sources. On the one hand the local histiocytes —the resting wandering cells, the reticular cells, the cells of Kupffer, etc.— are mobilized and transform themselves into large, ameboid, phagocytic elements. On the other hand, large quantities of lymphocytes and monocytes migrate out of the blood vessels together with the special leucocytes. They infiltrate the inflamed tissue during the first twenty-four to forty-eight hours and obviously cannot be derived from local elements, as the mitotic proliferation starts only after eighteen to nineteen hours. Besides, in the early stages the pictures of emigration out of the blood vessels are quite common (Maximow, 1902, 1903, 1905).

Whereas the emigrated special granular leucocytes soon degenerate, the lymphocytes and monocytes, on the contrary, display a great vitality.

Immediately after emigration, sometimes even in the lumen of the dilated venous capillaries, where the marginal position of leucocytes is clearly manifest, they begin to hypertrophy. The thin layer of protoplasm in the lymphocytes becomes wider, shows formation of pseudopodia and often contains vacuoles. The nucleus acquires a kidney-shaped form and occupies an excentric position. The cytocentrum becomes manifest. The small lymphocytes approach in this way first the structural type of the monocytes, and the differences between the emigrated lymphocytes and monocytes are effaced. Transformation of lymphocytes into monocytes was also observed by Bergel (1920).

In the later stages the monocytes and the lymphocytes both transform themselves into larger cells, the polyblasts. During the first two days these hematogenous polyblasts can be easily distinguished from the local mobilized histiocytes, because they are smaller. In animals vitally stained this difference is especially clear—the polyblasts of local origin from the beginning containing dye inclusions, whereas the lymphocytes and monocytes are colorless. But after three to four days the hypertrophy of the hematogenous cells reaches such a degree that they can no longer be separated from the mobilized local histiocytes; simultaneously they show a rapidly increasing accumulation of the vital dye (Tschaschin, 1913; Downey, 1917). As the migration of the lymphocytes continues much longer than the migration of the special leucocytes, small lymphocytoid polyblasts can always be found, even in chronic inflammatory lesions, among the large polyblasts. In later stages many of the newly emigrated lymphocytes transform themselves into plasma cells. The small cell infiltration in chronic inflammation, according to Schridde (1910), also has to be explained through emigration of lymphocytes.

The derivation of a part of the polyblasts in inflamed tissues from hematogenous lymphocytes and monocytes has been confirmed by a series of investigators —K. Ziegler (1904), G. Schwarz (1904), Helly (1905), Zieler (1907*a*, *b*), Verebély (1907), O. Fischer (1909), Homén (1911), v. Fieandt (1911), Wallgren (1911*b*), Tschaschin (1913*a*, *b*), Bergel (1919, 1920, 1925), Dantschakoff and Seidlein (1922), Alfejew (1925), Stilwell (1926), Lang (1926*b*) and others.

The seemingly unusual fact, that a certain group of cells, the polyblasts, have a double, histogenous and hematogenous origin, on closer scrutiny is easily explained -the histogenesis of the connective tissue and the blood in the embryo shows that the so-called resting wandering cells or histiocytes originate partly from lymphocytoid and histioid wandering cells (Alfejew, 1924).

When in later stages of inflammation scar tissue develops, the polyblasts transform themselves into resting cells and remain scattered between the fibroblasts as elements which show a striking similarity to common

histiocytes (resting wandering cells) of the normal connective tissue. If a new inflammatory process starts in the scar, these resting polyblasts mobilize anew in the same way as has been explained for the normal histiocytes. A backward development into lymphocytes or a proliferation with formation of lymphocytes or blood cells, on the contrary, never occurs.

In old scar tissue a part of the polyblasts may transform themselves into fibroblasts (Maximow, 1902). As a part of the polyblasts represents former lymphocytes and monocytes, the capability of these white blood corpuscles to undergo fibroblastic transformation under suitable conditions seems to be convincingly demonstrated. In this way the old findings of E. Ziegler (1875,1876), which for a long time were discredited, again become valid.

Whereas the development of the polyblasts from mobilized histiocytes is generally recognized, the idea of their partly hematogenous origin from emigrated lymphocytes and monocytes and of the capability of these types of leucocytes to undergo progressive development, provided suitable external conditions are secured, did not become popular. Aschoff and Kiyono (1913), Kiyono (1914), Aschoff (1924) and others draw a sharp line between the histiocytes and the monocytes on the one hand and the lymphocytes on the other hand; the discrimination is based especially upon Kiyono's experiments with the vital carmine storing. The polyblasts, being cells capable of storing carmine, belong to the histiocytes; the lymphocytes, being unable to accumulate the vital dye, are generally not supposed to be of any importance for the formation of polyblasts. Marchand (1901,1902,1913,1924c) and G. Herzog (1916) also deny the progressive development of the nongranular leucocytes and claim the capacity of producing exudate cells (polyblasts) exclusively for the "adventitial clasmatocytes" (histiocytes) and for the endothelium of the blood vessels.

The results of recent experimental investigations do not speak in favor of this extreme negative viewpoint. Kiyono himself admits in his first paper (1914) as well as in his later paper published together with Nakanoin (1919), that some few lymphocytes may, after emigration, transform themselves into carmine-storing histiocytic or polyblastic elements. This concession evidently invalidates the sharp distinction between the two cell types mentioned. Besides, Downey (1917) has conclusively shown that the capability of storing vital dyes cannot be used as the criterium for determining the origin of cells.

The experiments of Maximow (1922,1923) with tissue cultures furnish new evidence for the prospective potencies of the lymphocytes and monocytes. In cultures of lymphoid tissue the same phenomena can be observed as in inflamed lymphoid tissue (Babkina, 1910). The reticular histiocytes transform themselves into large dye-storing macrophages or polyblasts and may furnish giant cells through fusion. The lymphocytes partly give rise to

plasma cells, partly to polyblasts, which in vitro as in inflammation also join in later stages the polyblasts of local, reticular, histiocytic origin. As the lymphocytes of the lymphoid tissue are young elements which are not as yet activated by their circulation in the blood stream, their transformations are proceeding much more slowly than in the case of lymphocytes originating from the blood and migrating into the inflamed connective tissue. However, the decisive test had to be made with lymphocytes taken from the blood itself.

Awrorow and Timofejewsky (1914) were the first to cultivate non-granular leucocytes of human leucemic blood in rabbit plasma. They saw their transformation into polyblasts and even into fibroblast-like elements. Carrel and Ebeling (1922) obtained pure cultures of chicken monocytes; the latter also showed a tendency to transform themselves into fibroblast-like elements. Maximow (1925*a*, *b*) has shown that the leucocytes of the blood of the rabbit in vitro, in fragments of the buffy coat which remains on the surface of the blood after centrifuging, display similar transformations, as they do after emigration from the blood vessels in the inflamed tissue in the organism. The granulocytes, migrating from the explanted fragment into the nutritive medium, degenerate in the course of the first two days. The lymphocytes and monocytes, on the contrary, remain alive and show progressive development. The monocytes at once hypertrophy and transform themselves, after two to three days, into large, ameboid, phagocytic elements which exactly correspond to polyblasts or macrophages. Their protoplasm contains fat droplets, engulfed cell remnants and erythrocytes. The lymphocytes, whose transformations can be easily followed in the living condition, behave differently. A part of them—probably the youngest—die after one or two days. The majority, however, hypertrophy and acquire an abundant ameboid protoplasm and a kidney-shaped, clearer, excentrically located nucleus. They join the monocytes in their further transformation into polyblasts and therefore in the cultures of leucocytes of the corresponding stages all transitions can be found between the monocytes and lymphocytes. These conditions exactly duplicate the same phenomenon as observed in inflammation. After four to five days all polyblasts in the culture are considerably enlarged. They are scattered in the explanted clot and in the surrounding fibrin in smaller and larger groups and appear as large, ameboid, epithelioid cells with a very distinct cytocentrum and with fatty and other inclusions in the peripheral parts of the cell body. They contain numerous mitoses. In later stages sometimes transformation into fibroblast-like cells with spear-shaped, pointed processes can be seen. If small fragments of loose connective tissue are explanted together with the fragments of the buffy coat, the polyblasts infiltrate the tissue, and pictures exactly resembling inflammation are obtained. If tubercle bacilli are added to such cultures of leucocytes, the lymphocytes and

monocytes transform themselves into typical epithelioid cells (Maximow, 1925*b*).

Similar results with leucocytes in incubated drops of blood have been recently obtained by M. Lewis (1925). Fischer (1925) describes transformation of monocytes of the chick into large ameboid cells and further into spindle-shaped fibroblast-like elements. Timofejewsky and Benewolenskaja (1925) have confirmed the findings of Maximow concerning the epithelioid transformation of lymphocytes in cultures of blood leucocytes inoculated with tubercle bacilli. While this article was in press Bloom (1927) succeeded in demonstrating the transformation of lymphocytes of the thoracic-duct into polyblasts and fibroblasts in vitro.

The facts presented in this discussion seem to furnish a secure basis for the conclusion that the lymphocytes, appearing in different forms as large, medium and small lymphocytes, are, on the one hand, potential hemocytoblasts and under suitable conditions may produce different types of blood cells. On the other hand, they can also transform themselves into monocytic and histiocytic elements playing an important rôle in the defense reactions of the organism. Finally, they may display even fibroblastic potencies. Thus they are to be looked upon as undifferentiated mesenchymal cells which in the adult organism are scattered everywhere in the connective tissue, are accumulated in large quantities in the blood-forming organs and circulate in the blood and other body liquids. According to the external conditions encountered they either degenerate or are eliminated through the wall of the digestive tract without ever having had a chance for progressive development, or they display their various potencies and produce new cell types.

The transformation of the lymphocytes into polyblasts in inflammation and their progressive development in vitro, which has just been described, may shed light on the still obscure question of the origin and morphological nature of the monocytes. The majority of the latest authors seem to be inclined to connect them genetically with the histiocytes; the monocytes are supposed by many to be either simply mobilized histiocytes (Kiyono, 1914), or their descendants. However, the possibility of the derivation of the monocytes from the histiocytes does not exclude another possibility — as in inflamed connective tissue the polyblasts are partly of local, and partly of hematogenous, lymphocytic (and monocytic) origin, so in the blood some of the lymphocytes may transform themselves into monocytes—larger cells, with partly restricted potencies, differentiated in the direction of phagocytosis. This need not happen in the general circulation—the transformation into monocytes probably takes place in the remote sections of the circulatory system in the venous sinuses filled with stagnating blood. Therefore, in the peripheral blood, transitions between lymphocytes and monocytes are scarce or absent. From this point of view the monocyte

might be looked upon as a kind of "blood polyblast." In infections their number may greatly increase in the circulation as an expression of an increased general defense reaction.

9. *The functional properties of the lymphocytes:*

The functions of the lymphoid tissue with its lymphocytes are closely connected with the constitution, the age and the general nutritive conditions of the organism. In old age the lymphoid tissue undergoes involution. In inanition (Jolly, 1914; Jolly and Saragea, 1924) it also suffers atrophic changes which, however, are not equally distinct in all lymphoid organs. The pycnotic, disintegrating lymphocytes in this case are phagocytized by the reticular histiocytes; as soon as the animals are fed again, regeneration occurs. Lefholz (1923) has shown that food rich in calories and especially in fat increases the amount of lymphoid tissue in the body.

According to Nakahara and Murphy (1921*a*, *b*) the action of dry heat on the organism of the mouse first causes degenerative changes in the lymphoid tissue, with subsequent hyperactivity and increased production of lymphocytes.

It is well known that the lymphocytes in the lymphoid tissue (and in the thymus) are very susceptible to exposure to roentgen rays. Whereas, according to Nakahara and Murphy (1921*a*, *b*), small doses of radiant energy incite the neoformation of lymphocytes, larger doses have a destructive influence. Jolly (1923, 1924*a*) describes an extensive degeneration of lymphocytes occurring immediately after exposure of a lymph node, with resulting phagocytosis of the débris by reticular cells. These phenomena attain the height of their development six hours after exposure; they gradually subside after twelve to fifteen hours. After three to four days regeneration begins and is completed after eight days. It is doubtful, however, whether the rays act directly upon the lymphocytes (Jolly and Ferroux, 1925). After ligation of the artery supplying a lymph node, the reaction of the lymphocytes in the latter is much less distinct (Jolly, 1924*b*).

There seems to be no secure basis for the discussion of the functions of the lymphocytes. It is not known whether these cells are active in the circulating blood or in the tissue; it is usually supposed that their function is connected in some way with their quantity in the circulation.

Whereas the special granulated leucocytes are believed to possess oxidizing and proteolytic enzymes, Bergel (1919, 1920, 1921, 1925) developed the idea of the presence of a lipolytic enzyme in the lymphocytes and of the important rôle played by the latter in the general fat metabolism. In connection with this he believed the lymphocytes to play an active rôle in the defense reaction against antigens containing lipoids, especially in tuberculosis, syphilis and actinomycosis. The conclusions of Bergel did not become popular and were refuted by many investigators (Caro, 1913, 1920; Kamiya, 1924; Aschoff, 1924 and others).

It is very probable that the defense function of the lymph nodes, especially their capacity of reducing the virulence of pathogenic microorganisms, is partly due to the activity of the lymphocytes (Marchand, 1924).

According to Murphy and his collaborators Ellis, Nakahara and Sturm (1914, 1919, 1920, 1921) the lymphocytes seem to play a certain rôle in the resistance to experimental tuberculosis and to cancer in mice.

II. PLASMA CELLS

Waldeyer in 1875 described large cells in various places of the connective tissue under the name of plasma cells. Later it became manifest that into this group very different elements were placed, which had nothing in com-

mon with each other mast cells, interstitial cells of the testis, etc. In 1891 Unna applied the name "plasma cells" to peculiar connective tissue cells, which he found in the skin in cases of lupus.

The conception of the plasma cell, as formulated by Unna, was later sharply outlined by v. Marschalkó (1895). Whereas Unna seems to have included in this group, on the basis of the protoplasmic basophilia, some ill-defined cell types of polyblastic nature and probably even basophilic proliferating fibroblasts, v. Marschalkó applied the name "plasma cells" exclusively to a well-defined cell category which showed, besides protoplasmic basophilia, some other characteristic features.

At the present time the definition of the plasma cell conception, as given by v. Marschalkó, is generally accepted; sometimes for precisely designating the "true" plasma cells the definition, "cells of the v. Marschalkó type," is added.

Since the publication of the papers quoted, the question of the plasma cells has been very often the subject of thorough investigation (Krompecher, 1898; Maximow, 1902, 1906; Pappenheim, 1901, 1902, 1905 to 1912 —Atlas, pp. 63 to 79, 1906*b*; Veratti, 1905; Joannovics, 1909; Schaffer, 1910; Downey, 1911; Marchand, 1913; Dubreuil and Favre, 1914; Ferrata, 1918).

Although first discovered in abnormal, inflamed connective tissue, the plasma cells soon were demonstrated also in the healthy organism; it became obvious that they are merely more numerous under pathological conditions. In the common loose connective tissue they are extremely rare; on the contrary, they are very common in the omentum, in the interstitial tissue of various glands, for instance, the mammary or the salivary glands, and especially in the tunica propria of the intestinal mucosa and in the lymphoid tissue. They may occur also in the bone marrow and in general everywhere in the various connective tissues.

The characteristic features of the plasma cells are especially manifest after staining with basic aniline dyes polychromic methylene blue, thionin, toluidin blue, methylene azure, etc. A good method for their demonstration is the methyl-green-pyronin stain of Pappenheim (1901).

The size of the plasma cells varies (Figs. 143 and 144). All transitions can be found from cells of the size of a small lymphocyte to elements several times larger than an erythrocyte. The shape is spherical; however, in most cases the cells, adapting themselves to the spaces available in the connective tissue or, in large groups, through mutual pressure, acquire an irregular polyhedral form (Fig. 144). In small clefts of the connective tissue they are elongated; on the surface of collagenous fibers or of fat cells, on the outer surface of blood vessels they are often flattened. The outlines of the cell body are usually smooth and the corners rounded off, but in the large plasma cells of young scar tissue the surface often shows a multitude of

small pseudopodia-like outgrowths (Maximow, 1902). The plasma cells probably possess a low degree of motility. They are sometimes found migrating into the epithelium of the tonsils (Schridde, 1906). The observation in living condition sometimes reveals very slow changes of form.

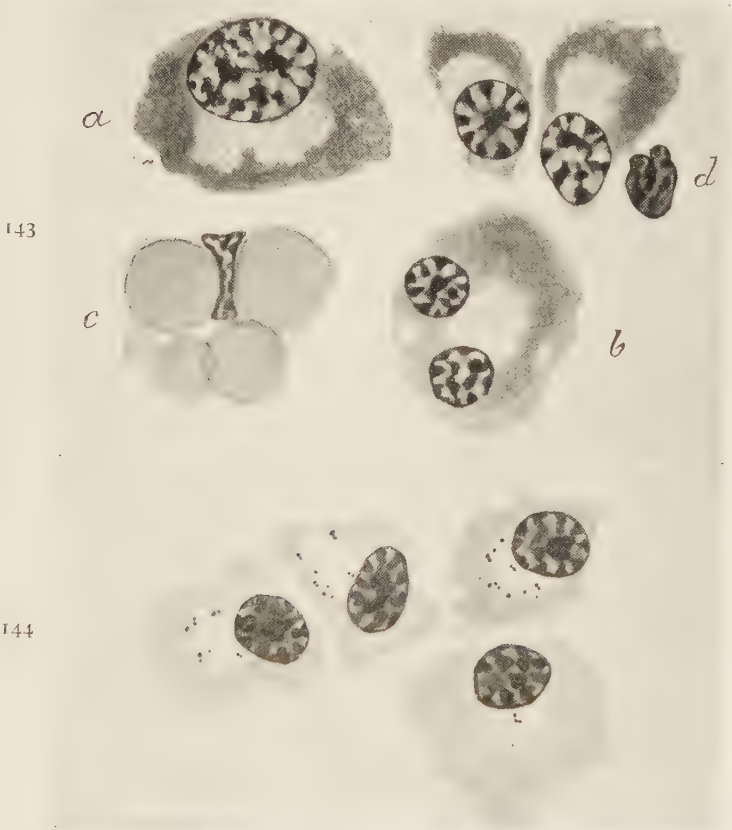

FIG. 143.—Group of plasma cells from the connective tissue surrounding the human tonsil; a, unusually large (lymphoblastic) plasma cell; b, binucleated plasma cell; c, acidophilic inclusions in degenerating plasma cell (Russell bodies); d, small lymphocyte. Zenker formol, hematoxylin, eosin azure. × 1500.

FIG. 144.—Group of plasma cells showing cytocentrum; from scar tissue surrounding a celloidin foreign body introduced into the subcutaneous tissue of a rabbit forty-two days previously. Zenker acetic, iron hematoxylin. × 1500.

The nucleus is relatively small, round or oval and occupies an excentric position (Figs. 143 and 144). It contains deeply staining, angular chromatin particles which sometimes, but by no means as a rule, appear arranged in the fashion of the spokes of a wheel ("Radkern"). Occasionally, an oxyphilic nucleolus may be present. In young plasma cells mitoses may be

found, but they are rare. In the older and larger specimens, on the contrary, amitotic constrictions of the nucleus are very common; they cause the fragmentation of the nucleus into two or several spherical parts of different size (Maximow, 1902; Weidenreich, 1909; Dubreuil and Favre, 1914).

The protoplasm of the living cell is homogeneous; after fixation and staining it often shows an indistinct granular or mottled structure; Unna believed this to be due to the infiltration of the "spongioplasm" of the cellular body with a hypothetic basophilic protein substance, the so-called "granoplasma." However, the presence of "granoplasma" cannot be considered as specific for the plasma cells alone—a similar accumulation of a "paraplasmic" basophilic substance may probably cause a more or less transient basophilia of various other connective tissue cells and even of cells of any other tissue (Marchand, 1913).

The most characteristic feature of the plasma cells is the dark basophilic stain of the protoplasm in the peripheral layers of the cell body (Figs. 143 and 144); the central part of the cell, opposite the nucleus, is occupied by a more or less sharply outlined, round, clear area. As Maximow (1902, 1906) has found and as Weidenreich (1909) and Wallgren (1911) have confirmed, this area is a peculiarly distinct attraction sphere. It contains after iron hematoxylin stain a group of centrioles, sometimes surrounded by a small, dense, darkly staining zone (Fig. 144).

The dark peripheral, usually somewhat mottled protoplasm contains no inclusions, except the occasional presence of small vacuoles which can be supravitally stained in the usual way with neutral red (Dubreuil and Favre, 1914). Appropriate methods reveal in it the presence of round, granular or short, rod-shaped chondriosomes (Wallgren, 1911; Dubreuil and Favre, 1914); these common cell organoids were mistaken by Schridde (1905*a*, *b*) for a specific kind of granule.

Regarding the origin of plasma cells, Unna (1891) and R. y Cajal (1906) believed them to arise from common fibroblasts. The same idea was advocated by L. Ehrlich (1904), partly by Joannovics (1909) and recently again by Kingsley (1924). This point of view can probably be explained by the wider limits given to the conception of the plasma cell by the authors quoted. If as "plasma cells" only elements of the v. Marschalkó type are considered, no evidence for their fibroblastic origin could possibly be detected.

At the present time it is generally admitted that the plasma cells arise from the small and medium-sized lymphocytes through individual differentiation which is not accompanied by mitosis and is caused presumably by peculiar unknown chemical stimuli. Wherever plasma cells are present, especially in the foci of "small cell infiltration" in chronic inflammation, lymphocytes and transitional forms between them and the plasma cells can be found. During the transformation the nucleus remains small, round

and stains dark, the protoplasm accumulates on one side and develops a distinct clear attraction sphere, whereas at its periphery the basophilic staining reaction increases. In cultures of lymphoid tissue (Maximow, 1922, 1923*a*) plasma cells may originate from the local lymphocytes in the course of two days; the process can be easily followed in the living condition. The same can be observed in cultures of the leptomeninges of the rabbit; here the lymphocytes accumulated in the vicinity of the arteries rapidly transform themselves into plasma cells.

Whereas the lymphocytic origin of the plasma cells is generally recognized, the opinions of the authors diverge as to the source of the respective lymphocytes. The majority believes that these lymphocytes are exclusively or at least mainly of histogeneous nature. They are supposed to originate from the resting wandering cells or the perivascular histiocytes, the so-called "adventitial clasmatocytes," but not from fibroblasts (Pappenheim, 1906*b*; Schridde, 1905*a*; Marchand, 1913; Ferrata, 1918 and others). According to other authors, however, all of the emigrated blood lymphocytes and the "histogenous" lymphocytes, previously present in the tissue, are indiscriminately able to produce plasma cells; no special proliferation of any local elements has to be made responsible for the appearance of such lymphocytes (Maximow, 1902, 1906, 1923; Weidenreich, 1911; Jolly, 1923). It is true that in the perivascular foci of plasma cells usually no evidence of emigration can be found; however, in cases of very rapidly developing purulent inflammation, emigration pictures still can be demonstrated (Maximow, 1905). On the other hand, in the same places usually no indications of an excessive proliferation of histiocytes or other elements can be found; mitoses are very rare, whereas amitosis, as already mentioned, causes fragmentation of the nuclei and occurs only in old plasma cells.

Since it has been shown that in the embryo, from the earliest stages of development, polymorphous but equipotential lymphocytoid wandering cells are present everywhere, in both the lumen of the blood vessels and in the connective tissue as well (Maximow, 1907*b*, 1909*b*, *e*, 1923; Dantschakoff, 1908, 1909, 1916; Marchand, 1913), the dispute about the hematogenous or histogenous origin of the plasma cells (Schridde, 1905*a*) has become unsubstantial. All lymphocytes are equal; hematogenous and histogenous varieties cannot be distinguished. Wherever in the connective tissue lymphocytes are present—it does not make any difference whether they came from the blood or belonged to the tissue—they may produce plasma cells, provided the external conditions are suitable.

Sometimes not only small and medium-sized lymphocytes, bu also other lymphoid elements may transform themselves into cells which are more or less similar to plasma cells of the v. Marschalkó type (Maximow, 1902; Weidenreich, 1909, 1911). This refers to the large lymphocytes (lymphoblasts) or "myeloblasts"—they may transform themselves into the so-

called "lymphoblastic plasma cells" (Schridde, 1907; Huebschmann, 1913). In monocytes the peripheral layer of protoplasm can sometimes also develop a marked basophilia (Krompecher, 1898; Weidenreich, 1909, 1911). Such "atypical" plasma cells (Maximow, 1902, pp. 147 to 148) are very common in the later stages of inflammation and are always connected by means of intermediate forms with the polyblasts and epithelioid cells which, as has been explained, also partly originate from lymphocytes and monocytes. From this point of view the plasma cells could be designated as a peculiar, specifically differentiated side branch of the cell lineage of the polyblasts.

The so-called "irritation forms" described by Türk (1904 to 1912) in pathological human blood, according to the majority of the clinical hematologists, are also to be considered as plasma cells (Nägeli, 1923). Von Juspa and Negreiros-Rinaldi (1913), however, believe them to be hemocytoblasts or "lymphoidocytes" whose differentiation has been inhibited.

Plasma cells may occur also in the lower vertebrates. Mjassojedoff (1926) finds them, in conformity with the older data of Solucha (1908), very numerous in the subcutaneous connective tissue and in the serous membranes of the chick. Downey (1911) gives a detailed description of the plasma cells in the amphibians and fishes. Here the "atypical" forms, i.e., transitions between the v. Marschalkó type and the common polyblasts or macrophages, seem to be especially numerous.

Very few authors admit the possibility of a progressive development of plasma cells into permanent connective tissue elements (Unna, R. y Cajal). Generally they are looked upon as cells which rapidly appear and disappear in the tissue. This explains why their quantity shows extraordinary variations, not only under pathological conditions, but also in seemingly normal organs as, for instance, in the omentum or in the tunica propria of the intestine. In the embryo no plasma cells can be found. They gradually appear in the extra-embryonic life. Their ultimate fate seems always to be degeneration. Cells with unmistakable signs of senile degeneration can easily be found at any place where the plasma cells are numerous (Maximow, 1902; Dubreuil and Favre, 1914). The types of degeneration are different. The involution often starts with the fragmentation of the nucleus, as described above. Later the nucleus undergoes pycnosis or chromatolysis. The protoplasm loses its basophilia and becomes vacuolated. Such degenerating plasma cells are often phagocytized by local, mobilized, resting wandering cells (histiocytes).

Very often in the foci of plasma cells a peculiar type of degeneration can be found; it manifests itself through the appearance of acidophilic inclusions of undetermined chemical character (Dubreuil and Favre, 1914). At first in the basophilic protoplasm coarse, homogeneous, spherical or crystalline bodies appear, which are intensely stained with eosin. The round inclu-

sions are sometimes very similar to the granules of the eosinophilic leucocytes. Simultaneously the cell rounds off, loses the basophilic staining reaction and the nucleus shows constrictions. Later very large, round or polyhedral, homogeneous, acidophilic bodies are seen to distend the cell body; the protoplasm is reduced to thin partitions between them and the angular or flattened nucleus is pushed to the periphery (Fig. 143c). Finally the cytoplasm disintegrates and the inclusions come to lie freely in the tissue. They are known in pathological anatomy as the Russell bodies (Russell, 1890).

Several authors (Krompecher, 1898; Schridde, 1905*a*; Downey, 1911; Dubreuil and Favre, 1914) have described plasma cells with metachromatically staining granules in the basophilic protoplasm—so-called "plasmamastcells."

Regarding the function of the plasma cells, only vague hypotheses can be suggested. Many investigators believe them to be secretory elements. Others (Huebschmann, 1913) look upon them as elements adapted to formation of defensive substances. According to Schaffer (1910) they are supposed to absorb and then dispose of various products of tissue metabolism. This explains their abundance in the connective tissue stroma of carcinomas, where the presence of large quantities of products of cell degeneration has to be admitted.

III. BIBLIOGRAPHY

Alder, A., and Huber, E. 1923. Untersuchungen über Blutzellen und Zellbildung bei Amphibien und Reptilien. *Fol. baematol.*, Archiv, **29**, 1.

Alfejew, S. 1924. Die embryonale Histogenese der Zellformen des lockeren Bindegewebes der Säugetiere. *Ibid.*, **30**, 111.

——— 1925. On the cell types of the connective tissue in the frog. *Publications of the Institute of scientific biology at the University of Perm*, **4**, 29 (Russian).

Aschoff, L. 1924. Das reticulo-endotheliale System. *Ergeb. d. inneren Med. u. Kinderheilk.*, **26**, 1.

Aschoff, L., and Kiyono, K. 1913. Zur Frage der grossen Mononukleären. *Fol. baematol.*, Archiv, **15**, 383.

Askanazy, M. 1905. Ueber amöboide Beweglichkeit der Lymphozyten. *Centralbl. f. allg. Path. u. path. Anat.*, **16**, 897.

Awrorow, P., and Timofejewsky, A. 1914. Kultivierungsversuche von leukämischem Blute. *Virchow Archiv*, **216**, 184.

Babkina, H. 1910. *Changes in the tissue of the blood forming organs in aseptic inflammation.* Thesis, St. Petersburg (Russian). Reviewed in *Fol. baematol.*, Zentralorg., 1911, **11**, 202.

Baum and Hille. 1908. Die Keimzentren in den Lymphknoten von Rind, Schwein, Pferd und Hund und ihre Abhängigkeit vom Lebensalter der Tiere. *Anat. Anz.*, **32**, 561.

Benda, C. 1896. Ueber den Bau der blutbildenden Organe und die Regeneration der Blutelemente beim Menschen. Verhandl. d. physiol. Gesellsch. zu Berlin. *Arch. f. An. u. Phys.*, phys. Abt., 1896, 347.

Benda, C. 1897. Anatomische Mitteilungen über akute Leukämie. *Verh. d. 15. Kongr. f. inn. Medicin*, 371.

Bensley, R. 1911. Studies on the pancreas of the guinea pig. *Am. J. Anat.*, **12**, 297.

Bergel, S. 1919. Beiträge zur Biologie der Lymphozyten. *Berl. klin. Woch.*, 915.

——— 1920. Beiträge zur Biologie der Lymphozyten. *Zeitschr. f. exp. Pathol. u. Therapie*, **21**, 216.

— 1921. *Die Lymphozytose.* Berlin: J. Springer.

— 1925. Weiteres zur lipoidspaltenden Funktion der Lymphozyten. *Beitr. z. path. Anat. u. z. allg. Path.*, **73**, 404.

Bloom, W. 1926. Hemopoietic potency of the small lymphocyte. *Fol. haematol.*, Archiv., in press.

——— 1927. *Proc. Soc. Exp. Biol. a. Med.*, **24**, 567.

Bunting, C., and Huston, J. 1921. Fate of the lymphocyte. *J. Exper. Med.*, **33**, 593.

Butterfield, E., Heineke, A., and Meyer, E. 1909. Ueber das Vorkommen der Altmann'schen Granulationen in den weissen Blutzellen. Technische Bemerkungen unter Mitarbeit von W. H. Meriam. *Fol. haematol.*, **8**, 325.

Cajal, R. y. 1906. Quelques antécédents historiques ignorés sur les plasmazellen. *Anat. Anz.*, **29**, 666.

Caro, L, 1913. Fettspaltende Fermente im menschlichen Blutserum, ihre Abhängigkeit von krankhaften, namentlich kachektischen Zuständen, ihre Unabhängigkeit von der histologischen Zusammensetzung des Blutes. *Ztschr. f. klin. Med.*, **78**, 286.

——— 1920. Zur Frage der Herkunft und Bedeutung von fettspaltenden Fermenten des menschlichen Blutes. *Ibid.*, **89**, 49.

Carrel, A., and Ebeling, H. 1922. Pure cultures of large mononuclear leucocytes. *J. Exper. Med.*, **36**, 365.

Citron, J. 1915. Ueber zwei bemerkenswerte Fälle von (akuter) Leukämie. *Fol. haematol.*, Archiv, **20**, 1.

Cowdry, E. V. 1915. The vital staining of mitochondria with janus green and diethylsafranin in human blood cells. *Internat. Monatschr. f. Anat. u. Phys.*, **31**, 267.

— 1921. The reticular material of developing blood cells. *J. Exper. Med.*, **33**, 1.

Cunningham, R., Sabin, F., and Doan, C. 1925. The development of leucocytes, lymphocytes and monocytes from a specific stem-cell in adult tissues. *Carnegie Inst. of Wash., Contributions to Embryology*, No. 84, **16**, 227.

Dantschakoff, W. 1908. Untersuchungen über die Entwicklung des Blutes und Bindegewebes bei den Vögeln. 1. Die erste Entstehung der Blutzellen beim Hühnerembryo und der Dottersack als blutbildendes Organ. *Anatomische Hefte*, **37**, 471.

——— 1909*a*. Untersuchungen über die Entwicklung von Blut und Bindegewebe bei Vögeln. Das lockere Bindegewebe des Hühnchens im fetalen Leben. *Arch. f. mikr. Anat.*, **73**, 117.

——— 1909*b*. Ueber die Entwicklung des Knochenmarks bei den Vögeln und über dessen Veränderungen bei Blutentziehungen und Ernährungsstörungen. *Ibid.*, **74**, 855.

— 1916*a*. The wandering cells in the loose connective tissue of the bird and their origin. *Anat. Record*, **10**, 483.

——— 1916*b*. Ueber die Entwicklung des Blutes in den Blutbildungsorganen (area vasculosa, Dottersackanhänge, Knochenmark, Thymus, Milz und lockeres Bindegewebe) bei Tropidonotus natrix. *Arch. f. mikr. Anat.*, **87**, 497.

Dantschakoff, W., and Seidlein, S. 1922. Digestive activity of mesenchyme and its derivatives. *Biol. Bull.*, **43**, 97.

Dominici, H. 1901*a*. Sur l'histologie de la rate á l' état normal et pathologique. *Arch. d. méd. expér. et d'anat. path.*, **13** (Ser. 1), 1.

Dominici, H. 1901*b*. Sur le plan de structure du système hématopoiétique des mammifères. *Ibid.*, **13** (Ser. 1), 473.

Downey, H. 1911. The origin and structure of the plasma cells of normal vertebrates, especially of the cold blooded vertebrates, and the eosinophils of the lung of Amblystoma. *Fol. haematol.*, 1 Teil, Archiv, **11**, 275.

——— 1917. "Histiocytes" and "macrophages" and their relations to the cells of normal blood in animals stained intra vitam with acid colloidal dyes. *Anat. Record*, **11**, 350.

——— 1924. The occurrence and significance of the "Myeloblast" under normal and pathological conditions. *Arch. Int. Med.*, **33**, 301.

Downey, H., and Weidenreich, F. 1912. Ueber die Bildung der Lymphozyten in Lymphdrüsen und Milz. IX. Fortsetzung der "Studien über das Blut und die blutbildenden und -zerstörenden Organe." *Arch. f. mikr. Anat.*, **80**, 306.

Dubreuil, G., and Favre, M. 1914. Cellules plasmatiques, plasmazellen à granulations spécifiques, cellules à corps de Russell (cytologie et formes évolutives). *Arch. d'Anat. micr.*, **17**, 302.

Dustin, A. 1914. Nouvelles contributions à l'étude du thymus des reptiles. *Arch. de zool. expér.*, **54**, 1.

Ehrlich, L. 1904. Der Ursprung der Plasmazellen. *Virch. Archiv*, **175**, 198.

Ehrlich, P. 1891. *Farbenanalytische Untersuchungen zur Histologie und Klinik des Blutes.* Berlin: Hirschwald.

Ehrlich, P., and Lazarus, A. 1898. *Die Anämie.* Spezielle Pathologie und Therapie von H. Nothnagel. 1 Auflage, 8. Wien: A. Hölder.

Ellermann, V. 1923. Messung der Mitosenwinkel als Methode zur Unterscheidung verschiedener "lymphoider" Zellformen. *Fol. haematol.*, Archiv, **28**, 207.

——— 1924. Zwei Fälle von akuter Leukämie. *Ibid.*, **30**, 1.

Evans, H. M. 1915. The macrophages of mammals. *Am. J. Physiol.*, **37**, 243.

Ferrata, A. 1918. *Le emopatie.* Milano: Società Editrice Libraria.

v. Fieandt, H. 1911. Beiträge zur Kenntnis der Pathogenese und Histologie der experimentellen Meningeal- und Gehirntuberkulose beim Hunde. *Arb. a. d. path. Inst. d. Univ. Helsingfors*, Ser. 1, **3**, 235.

Fineman, S. 1922. A study of microlymphoidocytic leukemia with the report of a case. *Arch. Int. Med.*, **29**, 168.

Fischer, A. 1925. Sur la transformation, in vitro, des gros leucocytes mononucléaires en fibroblastes. *C. rend. soc. biol.*, **92**, 109.

Fischer, O. 1909. Ueber die Herkunft der Lymphozyten in den ersten Stadien der Entzündung. Experimentelle Studie. *Beitr. z. path. Anat. u. z. allg. Path.*, **45**, 400.

Flemming, W. 1885. Studien über Regeneration der Gewebe. 1. Die Zellvermehrung in den Lymphdrüsen und verwandten Organen und ihr Einfluss auf deren Bau. *Arch. f. mikr. Anat.*, **24**, 50, 338.

Freidsohn, A. 1910. Zur Morphologie des Amphibienblutes. Zugleich ein Beitrag zu der Lehre von der Differenzierung der Lymphozyten. *Ibid.*, **75**, 435.

Goldmann, E. 1909. Die äussere und innere Sekretion des gesunden und kranken Organismus im Lichte der "vitalen Färbung." Teil 1. *Beiträge z. klin. Chir.*, **64**, 192.

——— 1912. Neue Untersuchungen über die äussere und innere Sekretion des gesunden und kranken Organismus im Lichte der "vitalen Färbung." *Ibid.*, **78**, 1.

Gräff, S. 1925. Der kolorimetrische Nachweis von Zelloxydase unter optimalen Bedingungen. *Centralbl. f. allg. Path. u. path. Anat.*, **35**, 481.

Hammar, J. 1905. Zur Histogenese und Involution der Thymusdrüse. *Anat. Anz.*, **27**, 23, 41.

——— 1908. Zur Kenntnis der Teleostierthymus. *Arch. f. mikr. Anat.*, **73**, 1.

Hammar, J. 1910. Fünfzig Jahre Thymusforschung. *Ergebn. d. Anat. u. Entwicklungsgesch.*, **19**, 1.

—— —— 1912. Lipoidbildung in den weissen Blutkörperchen, nebst einigen Beobachtungen über Vitalfärbung des Zellkernes. *Kungl. Svenska Vetenskapsakademiens Handlingar*, **49**.

Heiberg, K. 1923. Das Aussehen und die Funktion der Keimzentren des adenoiden Gewebes. *Virch. Archiv*, **240**, 301.

——— 1925*a*. Die Lymphozytenproduktion und die Leistungsmittelpunkte mit Phagozyten im adenoiden Gewebe, nebst Bemerkungen über die Verhältnisse in der Thymus. *Anat. Anz.*, **59**, 238.

——— 1925*b*. Die pathologische Anatomie der Tonsillen bei Endocarditis chronica und Febris rheumatica. *Virch. Archiv*, **257**, 1.

Heidenhain, M. 1915. Ueber die Mallorysche Bindegewebsfärbung mit Karmin und Azokarmin als Vorfarben. *Zeitschrift f. wiss. Mikrosk.*, **32**, 361.

Heilmann, P. 1925. Ueber Veränderungen des lymphatischen Gewebes im Wurmfortsatz und im Allgemeinen. *Virch. Archiv*, **258**, 52.

Hellmann, T. 1921. Studien über das lymphoide Gewebe. Die Bedeutung der Sekundärfollikel. *Beitr. z. path. Anat. u. z. allg. Path.*, **68**, 333.

Helly, K. 1905. Zur Morphologie der Exsudatzellen und zur Spezifität der weissen Blutkörperchen. *Ibid.*, **37**, 171.

——— 1914. Lympho- und Leukozytosen. *Ergebn. d. allg. Path. u. path. Anat.*, **17**, 1 Abt., 1913, 1.

Herzog, G. 1916. Experimentelle Untersuchungen über die Einheilung von Fremdkörpern. *Beitr. z. path. Anat. u. z. allg. Path.*, **61**, 377.

Homén, E. 1911. Studien über experimentelle Tuberkulose in den peripheren Nerven und dem Bindegewebe bei gesunden und bei den alkoholisierten Tieren. *Arb. a. d. path. Inst. d. Univ. Helsingfors*, Ser. 1, **3**, 91.

Huebschmann, P. 1913. Das Verhalten der Plasmazellen in der Milz bei infektiösen Prozessen. *Verhandl. d. Deutsch. path. Gesellsch.*, 16 Tag., Marburg, 110.

Joannovics, G. 1909. Ueber Plasmazellen. *Zentralbl. f. allg. Path. u. path. Anat.*, **20**, 1011.

Jolly, J. 1914. Modifications des ganglions lymphatiques à la suite du jeûne. *Compt. rend. soc. biol.*, **66**, 146.

——— 1923. *Traité technique d'hématologie*. Paris: A. Maloine et fils.

——— 1924*a*. Sensibilité comparée des différents organes lymphoïdes aux rayons X. *Compt. rend. soc. biol.*, **91**, 354.

——— 1924*b*. Action des rayons X sur les cellules. Diminution de la réaction d'un organe sensible par la ligature des artères afférentes. *Ibid.*, **91**, 532.

Jolly, J., and Ferroux, R. 1925. L'action nocive des rayons X sur les tissus vivants est-elle une action directe ou une action indirecte? *Ibid.*, **92**, 67.

Jolly, J., and Saragea, Th. 1924. Sur les modifications histologiques de l'appendice du Lapin au cours du jeûne. *Ibid.*, **90**, 618.

Jordan, H., and Speidel, C. 1923. Studies on lymphocytes. I. Effect of splenectomy; experimental hemorrhage and a hemolytic toxin in the frog. *Am. J. Anat.*, **32**, 155.

——— 1924. Studies on lymphocytes. III. Granulocytopoiesis in the salamander, with special reference to the monophyletic theory of blood origin. *Am. J. Anat.*, **33**, 485.

v. Juspa and Negreiros Rinaldi. 1913. Ueber die morphologische Bedeutung der Türkschen Zellen und deren Verhältnisse zu den Plasmazellen. *Fol. haem.*, Arch., **16**, 237.

Kamiya, H. 1924. Zur Frage der Spezifität der zelligen Bauchhöhlenexsudate. *Beitr. z. path. Anat. u. z. allg. Path.*, **72**, 761.

Katsunuma, S. 1924. *Intrazelluläre Oxydation und Indophenolblausynthese.* Jena: G. Fischer.

Kingsley, D. 1924. Regressive structures and the lymphocyte. The plasma cell; its origin and development. A study of the mammalian nictitating membrane. *Anat. Record,* **29,** 1.

Kiyono, K. 1914. *Die vitale Karminspeicherung.* Jena: G. Fischer.

Kiyono, K., and Nakanoin, T. 1919. Weitere Untersuchungen über die histiozytären Zellen. *Acta scholae med. Univ. Imp. in Kioto,* **3,** *55.*

Krompecher, E. 1898. Beiträge zur Lehre von den Plasmazellen. *Beiträge zur patb. Anat. u. z. allg. Patb.,* **24,** 163.

Kwasniewski. 1924. Ein Beitrag zur Klinik und Histogenese der akuten Myeloblastenleukämie. *Deutscb. Arch. f. klin. Med.,* **145,** 83.

Laguesse, E. 1900. Sur les paranuclei et le mécanisme probable de l'élaboration dans la cellule pancréatique de la salamandre. *13ème Congrès International de Médecine, Hist. et Embr., Paris,* 1.

Lang, F. 1926*a*. Experimentelle Untersuchungen über die Histogenese der extramedullären Myelopoese. *Zeitschr. f. mikr. anat. Forsch.,* **4,** 417.

——— 1926*b*. Rôle of endothelium in the production of polyblasts (mononuclear wandering cells) in inflammation. *Archives of Path. and Lab. Med.,* **1,** 41.

Latta, J. 1921. The histogenesis of dense lymphatic tissue of the intestine (Lepus): a contribution to the knowledge of the development of lymphatic tissue and blood-cell formation. *Am. J. Anat.,* **20,** 159.

Lefholz, R. 1923. The effects of diets varying in caloric value and in relative amounts of fat, sugar, and protein upon the growth of lymphoid tissue in kittens. *Ibid.,* **32,** 1.

Lejeune, E. 1915. Die Zellen im Ductus lymphaticus beim Menschen und einigen Säugern, unter spezieller Berücksichtigung der "grossen Mononukleären." *Fol. haematol.,* Archiv, **19,** 371.

Lewis, M. 1925. The formation of macrophages, epithelioid cells and giant cells from leucocytes in incubated blood. *Am. J. Path.,* **1,** 91.

Logefeil, R. 1924. A study of mixed leukemia with the report of a case. *Arch. Int. Med.,* **33,** 659.

Marchand, F. 1901. Der Prozess der Wundheilung. *Deutsche Chir.,* herausgeg. von v. Bergmann und v. Bruns, Lief. 16, Stuttgart.

—— 1902. Ueber Klasmatozyten, Mastzellen und Phagozyten des Netzes. *Verh. d. Deutsch. path. Ges.,* 4 Tag., 124.

—— 1913. Ueber die Herkunft der Lymphozyten und ihre Schicksale bei der Entzündung. *Ibid.,* 16 Tag., Marburg, 5.

——— 1924. Die örtlichen reaktiven Vorgänge (Lehre von der Entzündung). *Handbuch d. allg. Pathologie,* herausg. v. L. Krehl und F. Marchand, **4,** Abt. 1, 78. Leipzig: S. Hirzel.

v. Marschalkó, Th. 1895. Ueber die sog. Plasmazellen, ein Beitrag zur Kenntnis der Herkunft der entzündlichen Infiltrationszellen. *Arch. f. Dermatol. u. Syphilis,* **30.**

Maximow, A. 1902. Experimentelle Untersuchungen über entzündliche Neubildung von Bindegewebe. *Beiträge z. path. Anat. u. z. allg. Pathol.* Supplementheft **5,** 1.

——— 1903. Weiteres über Entstehung, Struktur und Veränderungen des Narbengewebes. *Ibid.,* **34,** 153.

——— 1904. Ueber entzündliche Bindegewebsneubildung bei der weissen Ratte und die dabei auftretenden Veränderungen der Mastzellen und Fettzellen. *Ibid.,* **35,** 93.

——— 1905. Beiträge zur Histologie der eitrigen Entzündung. *Ibid.,* **38,** 301.

——— 1906. Ueber entzündliche Bindegewebsbildung beim Axolotl. *Ibid.,* **39,** 333.

——— 1907*a*. Experimentelle Untersuchungen zur postfötalen Histogenese des myeloiden Gewebes. *Ibid.,* **41,** 122.

Maximow, A. 1907*b*. Ueber die Entwicklung der Blut- und Bindegewebszellen beim Säugetierembryo. *Fol. haematol.*, **4**, 611.

—— 1909*a*. Ueber zweckmässige Methoden für zytologische und histogenetische Untersuchungen. *Zeitschr. f. wiss. Mikrosk.*, **26**.

—— 1909*b*. Untersuchungen über Blut und Bindegewebe. I. Die frühesten Entwicklungsstadien der Blut- und Bindegewebszellen beim Säugetierembryo, bis zum Anfang der Blutbildung in der Leber. *Arch. f. mikr. Anat.*, **73**, 444.

—— 1909*c*. Untersuchungen über Blut und Bindegewebe. II. Ueber die Histogenese der Thymus bei Säugetieren. *Ibid.*, **74**, 525.

—— 1909*d*. Die Histogenese der Entzündung (Mit Berücksichtigung der gewebsbildenden hämatogenen Zellen). *Verh. d. 16 Internat. Med. Congresses zu Budapest*, Sect. 4 b, 41.

—— 1909*e*. Der Lymphozyt als gemeinsame Stammzelle der verschiedenen Blutelemente in der embryonalen Entwicklung und im postfötalen Leben der Säugetiere. *Fol. haematol.*, **8**, 125.

—— 1910. Untersuchungen über Blut und Bindegewebe. III. Die embryonale Histogenese des Knochenmarks der Säugetiere. *Arch. f. mikr. Anat.*, **76**, 1.

—— 1912*a*. Untersuchungen über Blut und Bindegewebe. IV. Ueber die Histogenese der Thymus bei Amphibien. *Ibid.*, **79**, 560.

—— 1912*b*. Untersuchungen über Blut und Bindegewebe. V. Ueber die embryonale Entwicklung der Thymus bei Selachiern. *Ibid.*, **80**, 39.

—— 1922. Untersuchungen über Blut und Bindegewebe. VII. Ueber "in vitro" Kulturen von lymphoidem Gewebe des erwachsenen Säugetierorganismus. *Ibid.*, **96**, 494.

—— 1923*a*. Untersuchungen über Blut und Bindegewebe. VIII. Die zytologischen Eigenschaften der Fibroblasten, Retikulumzellen und Lymphozyten des lymphoiden Gewebes ausserhalb des Organismus, ihre genetischen Wechselbeziehungen und prospektiven Entwicklungspotenzen. *Ibid.*, **97**, 283.

1923*b*. Untersuchungen über Blut und Bindegewebe. IX. Ueber die experimentelle Erzeugung von myeloiden Zellen in Kulturen des lymphoiden Gewebes. *Ibid.*, **97**, 314.

—— 1923*c*. Untersuchungen über Blut und Bindegewebe. X. Ueber die Blutbildung bei den Selachiern im erwachsenen und embryonalen Zustande. *Ibid.*, **97**, 623.

—— 1925*a*. Ueber die Entwicklungsfähigkeiten der Blutleukozyten und des Blutgefässendothels bei Entzündung und in Gewebskulturen. *Klin. Wochenschr.*, **4**, 1486.

1925*b*. Rôle of the nongranular blood leukocytes in the formation of the tubercle. *J. Infect. Dis.*, **37**, 418.

Menten, M. 1919. A study of the oxidase reaction with α-Naphthol and Paraphenylendiamine. *J. Med. Res.*, **40**, 433.

Michaelis, L., and Wolff, A. 1902. Ueber Granula in Lymphozyten. *Virch. Archiv*, 167, 151.

Mjassojedoff, S. 1926. Die Zellformen des Bindegewebes und des Blutes und die Blutbildung beim erwachsenen Huhn. *Fol. haematol.*, Archiv, **32**, 263.

Murphy, J., and Ellis, A. 1914. Experiments on the rôle of lymphoid tissue in the resistance to experimental tuberculosis in mice. *J. Exper. Med.*, **14**.

Murphy, J., and Nakahara, W. 1920. The lymphocytes in natural and induced resistance to transplanted cancer. V. Histological study of the lymphoid tissue of mice with induced immunity to transplanted cancer. *Ibid.*, **31**.

Murphy, J., Nakahara, W., and Sturm, E. 1921. Studies on lymphoid activity. V. Relation between the time and extent of lymphoid stimulation induced by physical agents and the degree of resistance to cancer in mice. *Ibid.*, **33**.

Murphy, J., and Sturm, E. 1919. The lymphocytes in natural and induced resistance to transplanted cancer. IV. Effect of dry heat on resistance to transplanted cancer in mice. *Ibid.*, **29**.

Nägeli, O. 1900. Ueber rotes Knochenmark und Myeloblasten. *Deut. med. Wochenschr.*, **26**, 287.

——— 1923. *Blutkrankheiten und Blutdiagnostik.* Ed. 4, Berlin; Julius Springer.

——— 1925. Allgemeine Embryologie, Morphologie und Biologie der Blutzellen und der blutbildenden Organe. *Handb. d. Krankh. d. Blutes u. d. blutbild. Organe*, herausg. von A. Schittenhelm, **1**. Berlin; J. Springer.

Nakahara, W., and Murphy, J. 1921*a*. The lymphocytes in natural and induced resistance to transplanted cancer. VI. Histological comparison of naturally immune and susceptible mice. *J. Exper. Med.*, **33**.

——— 1921*b*. On the nature of the so-called germ center in lymphoid tissue. *Anat. Record*, **22**, 107.

Nassonov, D. 1923. Das Golgische Binnennetz und seine Beziehungen zu der Sekretion. Untersuchungen über einige Amphibiendrüsen. *Arch. f. mikr. Anat.*, **97**, 136.

Pappenheim, A. 1901. Wie verhalten sich die Unna's chen Plasmazellen zu Lymphozyten. *Virch. Archiv*, **166**, 425.

——— 1902. Weitere kritische Ausführungen zum gegenwärtigen Stand der Plasmazellenfrage. *Ibid.*, **169**, 372.

——— 1906*a*. Einige Bemerkungen über Methoden und Ergebnisse der sog. Vitalfärbung an den Erythrozyten. *Fol. haematol.*, **4**, Suppl., 46.

——— 1906*b*. Unsere derzeitigen Anschauungen über Natur, Herkunft und Abstammung der Plasmazellen und über die Entwicklung der Plasmazellfrage. *Ibid.*, **4**, Suppl. 206.

——— 1905–1912. *Atlas der menschlichen Blutzellen.* Jena: G. Fischer.

——— 1919. Morphologische Hämatologie. *Fol. haematol.*, Archiv, **24**, 1.

Pol, R. 1923. Zur Funktionsfrage der lymphadenoiden Organe, insbesondere der Tonsillen. *Verhandl. d. Deutsch. path. Gesellsch.*, 19 Tag., Göttingen, 286.

Renaut, J. 1907. Les cellules connectives rhagiocrines. *Archives d'Anat. micr.*, **9**, 495.

Renaut, J., and Dubreuil, G. 1906. Sur les cellules rhagiocrines libres du liquide des diverses séreuses. *C. rend. soc. biol.*, **60**, 34.

Roman, B. 1913. Zur Kenntnis der myeloischen Chloroleukämie. *Beitr. z. path. Anat. u. z. allg. Path.*, **55**, 61.

Rosin, H., and Bibergeil, E. 1904. Ueber vitale Blutfärbung und deren Ergebnisse bei Erythrozyten und Blutplättchen. *Zeitschr. f. klin. Medizin*, **54**, 197.

Russell. 1890. Address on a characteristic organism of cancer. *Brit. Med. J.*, 1356.

Sabin, F. 1923. Studies of living human blood cells. *Bull. Johns Hopkins Hosp.*, **34**, 277.

Sabin, F., Doan, C., and Cunningham, R. 1925. Discrimination of two types of phagocytic cells in the connective tissues by the supravital technique. *Carnegie Inst. of Wash. Contributions to Embryology*, No. 82, 125.

Schaffer, J. 1910. *Die Plasmazellen.* 8 Heft der "Sammlung anatomischer und physiologischer Vorträge und Aufsätze," herausg. von Gaupp u. Nagel. Jena: G. Fischer.

——— 1922. *Lehrbuch der Histologie und Histogenese.* Ed. 2, Leipzig: Engelmann.

Schridde, H. 1905*a*. Beiträge zur Lehre von den Zellkörnelungen. Die Körnelungen der Plasmazellen. *Anat. Hefte*, **28**, 691.

——— 1905*b*. Weitere Untersuchungen über die Körnelungen der Plasmazellen. *Zentralbl. f. allg. Path. u. path. Anat.*, **16**, 433.

——— 1906. Ueber die Wanderungsfähigkeit der Plasmazellen. *Verhandl. d. deut. path. Gesellsch.*, 10 Tag., Stuttgart, 110.

Schridde, H. 1907. Myeloblasten, Lymphoblasten und lymphoblastische Plasmazellen. *Beiträge zur path. Anat. u. z. allg. Path.*, **41**, 223.

— — 1908. Ueber Regeneration des Blutes unter normalen und krankhaften Verhältnissen. *Berl. klin. Woch.*, **45**, 1864.

——— 1910. *Studien und Fragen zur Entzündungslehre.* Jena: G. Fischer.

— 1923. Die Zellen der Thymusrinde. *Centralbl. f. allg. Path. u. path. Anat.*, **33**, 284.

Schultze, W. 1909. Die Oxydasereaktion an Gewebsschnitten und ihre Bedeutung für die Pathologie. *Beitr. z. path. Anat. u. z. allg. Path.*, **45**, 127.

Schwarz, G. 1904. Ueber die Herkunft der einkernigen Exsudatzellen bei Entzündungen. *Wien. klin. Wochenschr.*, **17**, 1173.

Simpson, M. 1921. I. Vital staining of human blood with special reference to the separation of the monocytes. II. The experimental production of circulating endothelial macrophages and the relation of these cells to the monocytes. *Univ. of California Publications in Anatomy*, **1**, 1.

Solucha, N. 1908. *Ueber die Zellformen des Bindegewebes der Vögel in normalem Zustande und bei Entzündung.* Inaug. Diss. St. Petersburg (Russian); reviewed in *Fol. haematol.*, 1909, **8**, 230.

Stilwell, F. 1926. On the phagocytic capacity of the blood vessel endothelium of the frog's tongue and its presumed transformation into wandering cells. *Ibid.*, Archiv, **33**, 81.

Thorne, G., and Evans, H. 1922. Absence of monocytes in thoracic duct lymph. *Anat. Record*, **23**, 42.

Timofejewsky, A., and Benewolenskaja, S. 1925. Explantationsversuche von weissen Blutkörperchen mit Tuberkelbazillen. *Arch. f. exp. Zellf.*, besonders Gewebezüchtung (Explantation), **2**, 31.

Tschaschin, S. 1913*a*. Ueber die "ruhenden Wanderzellen" und ihre Beziehungen zu den anderen Zellformen des Bindegewebes und zu den Lymphozyten. *Fol. bäm.*, Arch., **17**, 317.

——— 1913*b*. Ueber die Herkunft und Enstehungsweise der lymphozytoiden (leukozytoiden) Zellen, der "Polyblasten," bei der Entzündung. *Ibid.*, **16**, 247.

Türk, W. 1904–1912. *Vorlesungen über klinische Hämatologie.* **1** and **2**. Wien.

Unna, P. 1891. Ueber Plasmazellen, insbesondere beim Lupus. *Monatshefte f. prakt. Dermatologie*, **12**, 296.

Veratti. 1905. *Ricerche sulla origine delle plasmazellen.* Tesi di libera docenza. Pavia.

v. Verebély, T. 1907. Di Granulation des menschlichen Fettgewebes. *Beiträge z. klin. Chir.*, 54, 320.

Waldeyer, W. 1875. Ueber Bindegewebszellen. *Arch. f. mikr. Anat.*, **11**, 176.

Wallgren, A. 1909. Zur Kenntnis der lymphoiden Zellen des Kaninchenblutes. *Fol. haematol.*, 8, 307.

——— 1911*a*. Zur Kenntnis der Plasmastruktur der Plasmazelle. *Beitr. z. path. Anat. u. z. allg. Path.*, **51**, 227.

— 1911*b*. Beitrag zur Kenntnis der Pathogenese und Histologie der experimentellen Lebertuberkulose. *Arb. a. d. path. Inst. d. Univ. Helsingfors*, Ser. 1, **3**, 139.

Wätjen. 1925. Zur Keimzentrumsfrage. *Verh. d. deut. path. Ges.*, **20**, 366.

Weidenreich, F. 1909. Zur Morphologie und morphologischen Stellung der ungranulierten Leukozyten—Lymphozyten—des Blutes und der Lymphe. *Arch. f. mikr. Anat.*, **73**, 793.

——— 1911. *Die Leukozyten und verwandte Zellformen.* Wiesbaden: J. F. Bergmann (Ergebn. d. Anat. u. Entwicklungsgesch., **19**).

Werzberg, A. 1911. Studien zur vergleichenden Hämozytologie einiger poikilothermer Vertebraten. *Fol. haematol.*, **11**, 17.

Winkler, F. 1907. Der Nachweis von Oxydase in den Leukozyten mittels der Dimethyl-paraphenylendiamin-Alphanaphtol-Reaktion. *Fol. Haematol.*, 4, 323.

Ziegler, E. 1875. *Untersuchungen über die Herkunft der Tuberkel-Elemente.* Würzburg: Staudingee.

——— 1876. *Ueber die pathologische Gewebs- und Gefässneubildung. Ibid.*

Ziegler, K. 1904. Histologisehe Untersuchungen über das Oedem der Haut und des Unterhautzellgewebes. *Beiträge z. path. Anat. u. z. allg. Path.*, **36**, 434.

——— 1907*a*. Ueber die bei der aseptischen Entzündung des Bindegewebes auftretenden Zellformen. *Arch. f. Dermat. u. Syph.*, **85**, 323.

——— 1907*b*. Ueber Exsudatzellen bei der akuten aseptischen Entzündung des Bindegewebes. *Zentralbl. f. allg. Path. u. path. Anat.*, **18**, 289.

Section XII
THE MYELOBLAST

CONTENTS

Section XII

PAGE

I. Cytology: Normal and Pathological 371
1. Definition 371
2. Synonyms 371
3. Structure 372
4. Biological Characters 380
II. Myeloblast in Leucemias 381
III. Occurrence in Normal Adult 385
IV. Position of Myeloblast in Hematological System 388
V. Conclusions 390
VI. Bibliography 391

Section XII

THE MYELOBLAST*

HAL DOWNEY

I. CYTOLOGY: NORMAL AND PATHOLOGICAL

1. *Definition:*

THE myeloblast of Naegeli (Figs. 1 to 5, 33, 34) is the undifferentiated, non-granulăr, lymphoid "stem-cell" of the red bone marrow which functions as the indifferent, polyvalent parent cell of all of the "myeloid" elements.

The myeloid cells include the specific parenchymal cells of the marrow which enter the blood stream after passing through a series of maturation stages, and the bone marrow giant cells, the so-called megacaryocytes, which give off bits of their cytoplasm to the blood as blood platelets. The red blood corpuscles, the three types of granular leucocytes, the megacaryocytes, and, according to Naegeli and some others, the monocytes or large mononuclears of Ehrlich are all included among the myeloid elements, and they are all derived from the myeloblast.

The myeloblast is described as "lymphoid," because its cytoplasm is basophilic and contains no specific granules, but it is not a lymphocyte and in structure it is quite different from lymphocytes of normal blood or lymphatic tissue. It is most easily recognized when it occurs in the blood, as in cases of myelogenous leucemia, along with normal lymphocytes. In dry smears of blood from such cases stained with Wright's stain, it is evident that the myeloblasts are not lymphocytes and that they are cells which do not occur in normal blood. When the hematopoietic organs of the adult normal organism are prepared by the same technique, myeloblasts are found only in the red bone marrow, and for this reason they are generally regarded as specific marrow elements which are never found outside the marrow under normal conditions.

2. *Synonyms:*

The following are some of the terms which have been applied to the non-granular marrow cells. Most of them are not exact synonyms for Naegeli's myeloblast, because the authors were working with inadequate technique and so could not recognize the specific structure of this cell, or their conceptions of its genetic relationships were different. Most recent authors who recognize this cell have adopted Naegeli's terminology. This includes many who recognize relationships between myeloblasts and lymphocytes under certain conditions.

The *cellules medullaires* of Cornil (1887) included the granular as well as the non-granular leucocytes of the marrow. The question of relationships between them and

* Figures in this section will be found on plates following bibliography.

lymphocytes was not discussed. Troje's (1892) *juvenile form* (Jugendform) of the *marrow cells* had a narrow cell body and finely reticulated nucleus, and differed from blood lymphocytes. The *marrow cells* of H. F. Müller (1891) were also regarded as specific marrow cells and they were described as having a nucleus with very fine structure.

The *large lymphocytes* of Engel (1897) are related to myelocytes, and the *lymphocytes* of Hirschfeld (1898) differ from those of the blood by their larger size. Ehrlich's (1898) *large lymphocyte* is found in the marrow, but is a genuine lymphocyte. Myelocytes are the youngest cells of the granulocyte series. The *non-granular marrow cells* of Schur and Löwy (1900) were also identical with lymphocytes, but Rubinstein's *lymphoid mother cell* had specific structure and there were no genetic relationships between it and lymphocytes.

The *indifferent lymphoid cells* of Michaelis and Wolff, and Wolff (1902) produce myeloid cells in the marrow, but may also produce lymphocytes. They are also the germ center cells which produce normally only lymphocytes.

Pappenheim's "*Grosslymphozyt*" of the marrow was distinguished from the "*grosser Lymphozyt*" of the lymphatic tissue. The term "*Grosslymphozyt*" was later changed to "*Lymphoidozyt*." Morphologically it is identical with the myeloblast of Naegeli, but is an indifferent stem cell which can produce lymphocytes under pathological conditions and in the embryo.

Türk (1903) was uncertain whether his *lymphoid marrow cells* were the result of de-differentiation of granulocytes or whether they were genuine myeloblasts in the sense of Naegeli.

Browning (1905) recognized *undifferentiated leucoblasts* especially in the marrow of the fetus. Schleip's (1908) *large mononuclear basophilic cell* has myeloblastic structure but may differentiate into all other types of blood cells, including lymphocytes.

The *hemocytoblast* of Maximow and Danchakoff, and the *lymphoid hemoblast* of Jordan and Latta are polyvalent large lymphocytes. A cell of myeloblastic structure is not recognized. The *hemocytoblast* of Ferrata is identical with Naegeli's myeloblast, but it may produce lymphocytes when in lymphoblastic function and it occurs in normal lymphatic tissue as well as in the marrow.

The *indifferent lymphoid germinal cell* of Jolly (1923) is abundant in the marrow and also occurs to some extent in lymph nodes, but the latter is not absolutely identical with the marrow cell, because it does not attain all of its characters while in the lymphatic tissue.

This list of terms is by no means complete, but it includes those which have been commonly used. A longer list will be found in Gruner (1914), "The Biology of the Blood Cells," page 353, under the heading "Lymphoidocyte."

3. *Structure:*

Like most cells, the myeloblasts are subject to considerable variation in their structure, and certain features have been described by some authors which are not regarded as specific by others. But in spite of these difficulties the cells are readily identified by the dry smear method unless extreme alteration has resulted from pathological conditions. In sections and moist smears the identification is usually very difficult, which probably explains the fact that the extreme unitarians are unable to distinguish between these cells and lymphocytes. The descriptions of myeloblasts are, therefore, usually based on the dry smear method with staining according to Wright, Pappenheim's May-Giemsa combination, etc.

Schridde (1907*a*) attempted to distinguish the cells in sections and claimed this to be the most reliable method, but a careful check of his figures and descriptions by the writer and others has shown that he was following preconceived notions rather than actual facts. All others who have worked with this problem emphasize the fact that the finest cytological details, especially of the nucleus, which are necessary for the identification of these cells cannot be brought out in sections or moist smears. The writer has given special attention to the technical requirements in an investigation of the myeloblast problem just completed (Downey, 1926). It was found that in pathological material in which there might be a large number of myeloblasts in the lymphatic organs, it is sometimes possible to distinguish them from mature lymphocytes by the section method, but that when the myeloblasts are scattered here and there among lymphocytes it is impossible to distinguish them from the latter. Any problem involving the myeloblast and its relations to other blood cells must, therefore, be controlled by the dry smear method. For this reason the description given here will be based entirely on this technique. The papers by Schridde (1907*a*) and the writer (1926) may be referred to for descriptions and figures of the myeloblasts in sections.

Myeloblasts as they appear in the blood in cases of myelogenous leucemia are shown in Figure 5, taken from Pappenheim's splendid atlas on the cells of leucemic myelosis, and Figures 33 and 34 from a case observed by the writer. Figures 1 and 2 are myeloblasts from dry smears of human marrow, and Figures 3 and 4 from the marrow of newly born rabbits.

The photographs of the original colored plates do not reproduce the delicacy of coloring and structure of these cells. Beautiful colored illustrations will be found in Pappenheim's two atlases (1905–12 and 1914); in Ferrata, "Le Emopatie," Vol 1, Plate 14, Figures 1 to 15; Plate 18, Figure 1 (normal human marrow, dry smear); Plate 19 (smear of normal guinea pig marrow); in Naegeli's book (1923), Plates 10, 11, 24 and 25.

The figures of myeloblasts from the marrow are of special importance, because the usual illustrations and descriptions of these cells are based on leucemic blood. Comparison of the figures referred to above will show that the myeloblasts of the normal marrow are identical with those of the leucemic blood when the latter have not been distorted by the pathological process.

The cells under discussion are the myeloblasts of Naegeli (1900), the lymphoidocytes of Pappenheim and hemocytoblasts of Ferrata, different names for the same type of cell, but they are not necessarily the hemocytoblasts of Maximow and Danchakoff, or the lymphoid hemoblasts of Jordan, Latta, et al., because these authors fail to distinguish between the myeloblast of Naegeli and lymphocytes.

The extreme unitarians deny the existence of a lymphoid cell having the structure of the myeloblast, while the neo-unitarians recognize it, but not

as a specific myeloid cell. These topics will be discussed later, but for the present, reference to my Figures 36 and 37 from dry smears of rabbit lymph node and Figures 25 and 26 from human blood will show that myeloblasts are not identical with the larger lymphocytes of normal blood and lymphatic tissue.

Myeloblasts are usually rounded in outline, but may be somewhat irregular in shape. The majority of them are of about the same size as the largest lymphocytes of normal blood, but they may be as small as the smallest lymphocytes and the largest ones may equal the large mononuclears. There is some variation in structural detail, but it does not depend on the size of the cells, and the differences are not as great as those of different types of lymphocytes.

The structure of the nucleus as seen in dry smears is of the most specific and constant character. Its membrane is of smooth, even outline and exceedingly thin. Frequently it is difficult to detect a nuclear membrane, especially in sections. There is little or no condensation of the chromatin at the inner surface of the membrane, as is usually the case in lymphocytes. The chromatin shows even, diffuse distribution throughout the nucleus with no aggregation into larger masses, but with some condensation about the nucleoli.

Two types of nuclear pattern can be recognized. In the one (Figs. 5 and 34) the minute chromatin granules are so arranged that they form an exceedingly delicate, narrow-meshed network with rounded spaces occupied by the lighter and slightly acidophilic parachromatin (oxychromatin of some authors). If attention is focused on the parachromatin it will appear in the form of rounded granules embedded in a continuous mass of basichromatin. This appearance can be emphasized by slight variation in the method of staining. There is sharp separation of chromatin and parachromatin and no gradual merging of the one into the other, as is the case with lymphocytes (Lenaz).

The other type of nuclear pattern is illustrated in Figure 2 from human marrow and Figure 33 from leucemic human blood. In this type of myeloblast the chromatin is in the form of somewhat coarser granules which are distributed rather uniformly through the nucleus with slight condensation about the nucleoli. In these cells the chromatin does not form a network as it does in the nuclei of the other type (Figs. 18, 34 and 35). The same sharp separation of chromatin and parachromatin is also noted in the cells of the second type. Both types of cells occur in the same marrow and in leucemic blood from the same case. Whether the one type is less differentiated than the other is difficult to say, but in favor of this view is the fact that during the differentiation of these cells into other types of blood cells the nuclear chromatin condenses in the form of a coarse network of heavy strands, which indicates that the cells with the stippled nuclei are the younger ones. Figures 27 to 32, illustrating the differentiation of a cell of the myeloblastic

type (Fig. 27) to a lymphocyte, show the gradual formation of such a coarse network. A similar change in nuclear pattern is noted during the differentiation of the granulocytes from the myeloblast (Figs. 5 to 14).

Usually the nucleus appears rather pale and vesicular owing to the relatively large amount of parachromatin, but in pathological cases the quantity of chromatin may be greatly increased, so that the nucleus appears quite dark. This is particularly true of the smaller micromyeloblasts or microlymphoidocytes of Pappenheim, and such cells are often difficult to distinguish from small lymphocytes. But if overstaining is avoided it will be seen that the distribution of the chromatin is the same as that of normal myeloblasts, while the lymphocytes of corresponding size will show coarser strands and heavy masses of chromatin.

The term "pachychromatic" is used by Pappenheim to describe the coarse structure of the lymphocyte nucleus, and the delicate, net-like or stippled structure of the myeloblast nucleus is described as "leptochromatic." A nucleus which has little chromatin and is, therefore, of light color is "amblychromatic," and a dark nucleus with much chromatin is "trachychromatic" (Pappenheim, 1910a). The myeloblast nucleus is always leptochromatic and may be either trachychromatic or amblychromatic. The larger lymphocytes are pachychromatic and somewhat amblychromatic, but the smaller ones are both pachychromatic and trachychromatic.

The number and character of the nuclei are often claimed as a distinguishing feature of the myeloblast, especially by Naegeli, who sees from two to four round, pale nucleoli in myeloblasts and from one to two irregular and more deeply staining nucleoli in young lymphocytes, and none at all in the mature lymphocytes of normal blood as seen in dry smears. Schridde (1907), who is otherwise an ardent supporter of the myeloblast theory, finds as many as six nucleoli in lymphoblasts, but in sections stained with methyl green pyronin they differ in both color and structure from those of the myeloblasts.

Butterfield (1908) finds as many as five nucleoli in lymphocytes of germ centers and concludes that their number depends on the biological condition of the cell and not on its origin. Naegeli (1923) agrees that they may be numerous in germ center cells but not in lymphocytes of the blood, which proves that the immature germ center cells do not reach the blood. Pappenheim (1907,1910) could find nothing characteristic in the number of nucleoli, and in sections of marrow he found myeloblasts with both one to two and three to four nucleoli. Klein (1910) agrees that myeloblasts usually have more nucleoli, but finds that the reverse is often the case.

In sections one usually sees nucleoli in both myeloblasts and lymphocytes and those of the lymphocytes are generally larger and more irregular in shape. In dry smears nucleoli are not seen in mature lymphocytes unless they have been crushed in making the smear. Myeloblasts usually contain

several and they are generally round and not very deeply stained (Figs. 1, 2 and 3). There are exceptions, however, for one frequently encounters myeloblasts without nucleoli, and when present they are often irregular in shape (Figs. 33 and 34).

While the number and character of the nucleoli are of some importance in distinguishing between myeloblasts, mature lymphocytes and monocytes (the latter have none), they are of no significance whatever when one tries to distinguish myeloblasts from immature lymphocytes as seen in the lymphatic leucemias. This will be evident from Figures 28 to 31 and 35, which are immature lymphocytes from cases of subacute and chronic lymphatic leucemia. These cells have from two to five nucleoli which are rounded and otherwise identical with the common type seen in myeloblasts. In such cases it is, therefore, impossible to use the nucleoli as a diagnostic feature.

Nucleoli disappear during the early stages of differentiation of myeloblasts. In the red cell series this occurs very early, but in a series of developing granulocytes they may be carried over into the leucoblast and promyelocyte stages. In diagnostic work it is, therefore, very important to give special attention to the nucleoli, because their presence is an indication of immaturity of the cells, but they usually do not tell us whether the cell has originated in the marrow or lymphatic tissue.

The nucleus of the myeloblast is usually relatively large, but wide-bodied "leucocytoid" forms (Pappenheim) do occur, especially in pathological cases. In the leucemias the nucleus may show a sharp, deep indentation which is usually interpreted as indicating beginning amitosis. The division may never be completed in many cases, but complete division of the nucleus by amitosis was demonstrated by Sabin, Austrian, Cunningham and Doan (1924) in the living cells.

The nucleus may also have several wide but deep and irregular indentations which result in extensive lobulation. Myeloblasts of this type are called "Rieder cells" and they occur most frequently in acute and subacute myelogenous leucemia and are probably to be regarded as pathological forms. They are often difficult to distinguish from atypical monocytes and some of the monocyte leucemias which have been described have probably been cases with numerous Rieder cells rather than monocytes (Alder, Naegeli). Lymphocytes having the same type of nuclear lobulation are referred to as "Rieder lymphocytes." They should not be confused with the genuine Rieder cells which have an inner nuclear pattern identical with that of the myeloblast. Cells having the typical lobulation of the Rieder cell are shown by Ferrata (1918), Plate 16, Figures 1, 3, 5 and 10. Ferrata shows these cells as typical Rieder cells, but Alder claims that they are monocytes. The inner structure of the nuclei and the fine azure granulation of the cytoplasm is in favor of Alder's interpretation.

These cells were first described by Rieder (1893) in acute leucemia. He stated that they show signs of caryolysis and are characterized by deep, irregular indentations which may lead to the breaking up of the nucleus into four or five coarse, irregular fragments. Naegeli describes similar cells as pathological lymphocytes. Pappenheim (1905) believes them to be normal involution or degeneration forms and designates them as "age" forms ("Altersformen"). Weidenreich (1911) does not agree with this interpretation and believes that such cells are still capable of division; they represent normal variations or are the expression of functional activity.

Myeloblasts of this type are rarely seen in normal marrow or in the ordinary type of chronic myelogenous leucemia. The fact that they are more abundant in the acute forms of leucemia seems to indicate that they are the expression of a peculiar function or pathological alteration.

Cytoplasmic characters that have been described as specific for the myeloblasts as distinguished from lymphocytes are: more rounded outline of the myeloblasts, cytoplasm reticular, spongy or foamy in contrast with the more homogeneous structure of lymphocyte cytoplasm, characteristic form and diffuse distribution of the mitochondria differing from the plump rods and granules of the perinuclear zone of the lymphocytes (Schridde-Altmann granules) and lack of distinct perinuclear zone or "Hof" in the myeloblasts (Naegeli, 1923).

Every one of these characters has been disputed, and illustrations presented here will prove that at least some of them are variable and not at all specific.

That myeloblasts are not always round but may be quite irregular in outline is shown by Figures 3 and 34. This is true of the cells in both sections and smears.

The structure of the cytoplasm is extremely variable in different myeloblasts and lymphocytes of various types, and there seems to be no constant feature which will always distinguish the myeloblast from the lymphocyte. A distinct perinuclear zone is seen in some myeloblasts (Figs. 3 and 34) but not in others (Figs. 1, 2 and 33), and this feature is found to be just as variable in the lymphocytes. The degree of basophilia of the "spongioplasm" is also extremely variable in both types of cells and both may develop into extremely basophilic plasma cells.

The plasma cell which is derived from the myeloblast may retain the nuclear pattern of the latter and such a cell is known to pathologists as the "Türk irritation cell." Frequently its chromatin becomes aggregated into coarser masses, and then it is difficult to tell whether the plasma cell has been derived from a large lymphocyte or a myeloblast. Some authors include these cells with the Türk irritation forms. Good figures of both types are to be found in Ferrata (1918), Plate 16, Figures 26 to 35. His cells 26, 27, 28 and 33 still have the myeloblast nucleus, but the nuclei of the

other cells are pachychromatic. Plasma cells derived from lymphocytes are shown on the same plate, Figures 16 to 25. Their nuclei are relatively smaller, more eccentric and more pachychromatic in structure.

Schridde and Naegeli have made much of the supposed specificity of the mitochondria of myeloblasts. Schridde (1907, 1913) described plump, rod-like granules which with his special fuchsin method appear in a light perinuclear zone or "Hof," usually on one side, of the lymphoblasts. These granules are described as differing both morphologically and functionally from those of the myeloblasts. They are not so numerous, they never form filaments or chains and they are complete functioning structures of a mature cell; while the plastosomes of the myeloblasts are unripe antecedents of cell granules and constituents of an unripe cell. These granules were soon recognized as the same granules that Altmann had previously described, and so they are now generally known as the Schridde-Altmann granules and they are considered to be identical with mitochondria.

Schridde's view of the specific nature of these granules and of their importance for the myeloblast theory was accepted by Naegeli, and by Morawitz and Rehn and others, but was disputed by Maximow (1909), Butterfield (1908), Butterfield, Heineke and Meyer, and Klein (1910, 1914), Türk, Wallgren, and recently by Sabin, Austrian, Cunningham and Doan. Butterfield, Heineke and Meyer made this question the object of a special study, using the lymphocytes of normal blood, and cases of lymphocytosis and lymphatic leucemia, and myeloblasts from a case of acute myelogenous leucemia in which the blood contained all intermediate stages between myeloblasts and myelocytes, and normal marrow. They conclude that myeloblasts contain perinuclear fuchsinophile granules which cannot be distinguished from those of lymphocytes. Their excellent plate shows no difference in size, distribution or character of the granules.

In spite of this opposition Naegeli (1923) still believes that these granules are of some value in distinguishing between lymphoblasts and myeloblasts. He now admits that they occur in both types of cells of smears, but he does not find them in the myeloblasts of sections. In the smears those of the myeloblasts are in the form of short threads or commas, while those of the lymphoblasts are short rods located in the perinuclear area.

The supravital method introduced by Cowdry (1914), now being used by Sabin, Cunningham, Austrian and Doan, is claimed to be specific for mitochondria, and these authors are classifying the blood cells according to the character and arrangement of the mitochondria and neutral red granules. Although they claim specific differences and lack of direct relations between myeloblasts and lymphoblasts, they find little difference in their mitochondria. They find that the myeloblast is characterized by the presence of diffuse rounded and rod-shaped mitochondria, while clumping of the mitochondria is one of the characteristics of lymphocytes. The

lymphoblasts, on the other hand, vary from those having diffuse mitochondria to those which have them concentrated about the nucleus but show no clumping. The authors also disagree with the view of Schridde and Naegeli regarding the characteristic shape of the mitochondria in the two types of cells, but admit that this may be due to the fact that they are studying living cells.

Like the other types of lymphoid cells myeloblasts may develop azure ganulation, and when present it is more or less specific in character, differing from that of the lymphocytes and monocytes. The granules are darker, more abundant and usually larger than those of the lymphocytes. In leucemic blood they are often much coarser and more irregular in shape than those of the normal marrow. The two cells from human marrow shown here (Figs. 1 and 2) give their characteristic appearance under normal conditions. Pappenheim's atlas (1914) gives a series of these cells from leucemic blood on Plate XIIIB, Figures 35 to 52. In human marrow most of the myeloblasts seem to have this type of granulation, but in rabbit and guinea pig marrow such cells are not very numerous. Cases of myelogenous leucemia are variable in respect to the azure granulation present. In some cases nearly every myeloblast and leucoblast will have the granulation, but in other cases cells containing it are very rare. When present it is a great aid to diagnosis, particularly if only poorly stained or preserved smears are available.

There is considerable difference of opinion regarding the significance of this granulation. On account of its inconstant occurrence most authors do not regard it as a specific type of granulation equivalent to the eosinophile or neutrophile granulation but as an indication of a temporary functional condition or internal secretion of the cell. Because it is more abundant and frequent in the leucoblasts, Pappenheim (1911, Atlas, Supplement-Band) and Ferrata (1918) believe that it indicates that the cell is in a myeloplastic condition and is about to differentiate. According to Ferrata the myeloblasts with coarse azure granules will differentiate into eosinophile leucocytes and those with fine granules into neutrophiles, although there is no direct transformation of azure granules to the specific granules of the leucocytes.

That there is no transformation of these granules is indicated by the fact that they may be carried over into the promyelocyte and myelocyte stages when it is seen that there is no direct transition from azure granules to those of the neutrophile or eosinophile type.

Against the view that the presence of these granules indicates beginning differentiation is the fact that in many cases of chronic myelogenous leucemia the differentiation of myeloblasts to leucocytes may take place without the azure granules. This proves at least that the differentiation of the specific granules can proceed in a normal way without the presence of the azure granules. This is decidedly against Naegeli's view that the azure

granules represent immature neutrophile granules, and it does not favor Hynek's theory that they represent crystallization points on the surface of which is condensed the specific protoplasmic product of the special (neutrophile) granulation.

In the acute leucemias the myeloblasts and immature lymphocytes may develop a different type of azure granulation from that which has just been discussed. This form was first described by Auer in 1906. These so-called "Auer bodies" occur as large granules, globules or pellets of azure substance, or as one or two very slender rods located in cytoplasmic vacuoles. The larger rounded masses frequently show evidence of having been partly or completely dissolved, leaving cytoplasmic vacuoles, or vacuoles completely or partially lined with the azurophilic substance.

Auer states that these bodies can be stained with Ehrlich's triacid mixture, which proves that they are not identical with the azurophile granulation commonly seen in myeloblasts and lymphocytes. Downey and McKinlay saw the Auer rods in an occasional somewhat immature lymphocyte of a case of benign lymphocytosis, but usually they are seen only in the acute leucemias and for this reason they may be an aid to diagnosis. They are not normal constituents of the cell, and their presence indicates pathological alteration of a very immature cell which may be either myeloblast or unripe lymphocyte.

4. *Biological characters:*

It has been shown that many of the cytological characters which have been described as specific for the myeloblast are variable or inconstant and are often found in unripe lymphocytes as well as in myeloblasts. This is realized by many dualists some of whom admit that it is impossible to distinguish between the stem cells of the myeloid and lymphatic series on morphological grounds alone. For the neo-unitarians this means a common stem cell for the two systems, but the dualists believe that embryological, histological and biological features justify separation of the two stem cells even though the morphological characters should prove to be unreliable.

Embryology is supposed to prove the separate and independent origin of lymphatic and myeloid tissue, and histology, especially the histopathology of the leucemias, the continued independence and "antagonism" of the one for the other. These conclusions are not justified when one takes all of the known facts into consideration, but discussion of them is outside the field of cytology and so they cannot be argued here. Naegeli's book (1923) gives an extensive presentation of these topics from the polyphyletic standpoint, and Downey's preliminary account (1924) gives a brief discussion from the other side.

Among the biological reactions which are supposed to characterize myeloid tissue and the myeloblast are: presence of proteolytic ferment,

and positive oxydase and peroxydase reactions. The Winkler-Schultze oxydase reaction is especially favored by those who believe that the myeloid cells, including the myeloblasts, elaborate specific ferments, although it is generally admitted that myeloblasts may lose the ability to synthesize indophenol blue granules from solutions of α-naphthol and dimethylparaphenylendiamine. For technique and literature of the oxydase and peroxydase reactions see Naegeli (1923), pages 82 to 85.

According to the generally accepted opinion positive reaction always proves the myeloid nature of a cell. However, the reactions are often negative in cells which are of undoubted myeloid origin, so that negative reaction does not necessarily mean that the cells under consideration are lymphocytes. Menten concludes that the reaction is an adsorption phenomenon dependent on properties of intracellular surfaces. It is not specific for myeloid cells, for lymphocytes give a well-marked reaction, although it is stronger in eosinophile and neutrophile leucocytes. Many tissues give the reaction, so it is by no means specific for blood cells.

Citron concludes that positive reaction proves myeloid cell nature existing at the time, but does not tell us anything regarding the origin of the cells, as from previously negatively reacting lymphocytes. Richter arrives at similar conclusions regarding the peroxydase reaction.

Gräff has recently worked with the Winkler oxydase reaction, using a more refined technique than has generally been employed. He finds that the reaction is affected by the alkaline or acid nature of the tissue. Negative reaction is due to the fact that the optimal conditions for the formation of the color granules have not been fulfilled. When these are met, lymphocytes of the follicles of human and animal lymph nodes and spleen give a very positive although weak reaction, from which he concludes that the blood cells cannot be separated either diagnostically or genetically on the basis of their oxydase content. The differences are only quantitative and not qualitative.

II. THE MYELOBLAST IN THE LEUCEMIAS

The dualistic and polyphyletic theories are based in large measure on the conditions in the leucemias. In the typical chronic forms of this disease there is marked reaction of either the myeloid or lymphatic tissues, but not of both in the same case. The blood picture reflects the primary changes in the blood-forming organs and is explained by the fact that in the myelogenous form there are hyperplasia of the marrow and replacement of much of the lymphatic tissue by myeloid tissue, especially the granulocytic part of it, while in the lymphatic form the condition is reversed, with the result that there is substitution of lymphatic for myeloid tissue in the marrow and hyperplasia of the lymphatic apparatus.

Some of the lymphoid cells which appear in the blood in chronic myelogenous cases are evidently the precursors of the granulocytes and one can find all of the necessary intermediate stages between them and mature granular leucocytes, as shown in Figures 5 to 14, and occasionally their development into red cells can also be traced in the blood. A few normal lymphocytes are also present, and by comparing them with the lymphoid precursors of the granulocytes one can prove that the two cell types are not identical. The undifferentiated, non-granular precursors of the leucocytes are the myeloblasts of Naegeli, and they are identical with the corresponding cells of normal marrow. They are, therefore, constituents of the normal marrow which pass into the blood under certain pathological conditions, and it is not necessary to assume that there has been metaplasia or de-differentiation of the leucocytes in order to explain their presence in the blood.

This type of cell does not occur in the ordinary case of chronic lymphatic leucemia, where the dominant cell of the blood is the mature lymphocyte. Usually the blood of these cases will also contain a few lymphocytes with more diffuse distribution of the chromatin and these are evidently the younger cells, although they are far removed from the myeloblast.

The extreme unitarian view does not meet this situation, nor does it account for the fact that myeloblasts occur in normal marrow and not in normal lymphatic tissue (dry smears!). Although many of the features which have been described as specific for the myeloblast have been shown to be variable characters which may also occur in lymphocytes, the fact remains that there is a myeloid cell with leptochromatic nucleus which does not exist in lymphatic tissue of the normal adult. Under normal conditions this cell does not seem to have any relations to lymphocytes unless it should be proved that it is also the mother cell for the few lymphocytes which normally occur in the marrow.

The question of whether this type of cell may ever differentiate into lymphocytes under any circumstances has been one of the dominant problems of morphological hematology for many years. Closely linked to this problem are others of equal importance, such as the regeneration of lymphocytes and the nature and identity of their stem cells, and the possibility of direct metaplasia of lymphocytes to myeloid tissue. Here we are especially interested in the possibility of relationships between cells of the myeloblastic type and lymphocytes. The other two problems mentioned will be discussed by Maximow.

The leucemias have always been regarded as especially favorable material for the study of all of these questions. The immature, undifferentiated lymphocytes of cases of acute and subacute lymphatic leucemias are of special interest. Usually these cells have definite lymphocyte characters, although their nuclei may be slightly leptochromatic and possess

nucleoli. But occasionally there is a case in which the de-differentiation of the lymphocytes has gone so far that some of the cells cannot be distinguished from myeloblasts. These same cases may also have mature lymphocytes in the blood along with intermediate stages between them and the myeloblastic type of cell. Very rarely a chronic case will present a similar phenomenon.

A cell from such a case is presented in Figure 35, and a corresponding cell from chronic myelogenous leucemia in Figure 34. The latter would be a genuine myeloblast according to the dualists, but cell 35 from lymphatic leucemia would be a lymphoblast. In many respects cell 35 conforms more to the description of the myeloblast than does cell 34. The character of the nuclear membrane and the inner nuclear structure is practically identical in the two cells. The pale, round nucleoli of 35 are more in accord with the usual description of these structures for the myeloblast than are the more distinct and irregular nucleoli of cell 34. Both cells have a light area at one side of the nucleus, but in cell 35 this area also has a very delicate spongioplasmic network which is supposed to be characteristic for myeloblast cytoplasm.

If it were not for the intermediate stages between cells like the one of Figure 35 and the riper lymphocytes (Figs. 25 and 26) it would be quite impossible to diagnose the case as either lymphatic or myelogenous from the blood alone. Such immature and undifferentiated cells as the one shown in Figure 35 are rare in chronic lymphatic leucemia but are rather common in acute lymphatic leucemia. Two acute cases of this type have come under the writer's observation and several others are to be found in the literature.

A series of cells from one of these cases is shown in Figures 18 to 26. The myeloblastic characters of cells 18, 19 and 20 are evident from the figures. Cell 20 with its five round, pale nucleoli is of special interest. The net-like arrangement of the chromatin in cells 18 and 19 is also of importance. The gradual transformation of cells of this type to the riper lymphocytes is illustrated in the figures.

Cells from another acute lymphatic case, drawn with slightly reduced magnification, are shown in Figures 27 to 32. This is the case published by Fineman from the writer's laboratory. It was classified as a "microlymphoidocytic" leucemia because the cells were small and many of them were of the myeloblastic type. Cells like those of Figures 27 and 28 are of myeloblastic structure, but the direction of differentiation was lymphatic, as illustrated in Figures 29 to 32.

In this case the total leucocyte counts were extremely variable from day to day. During the days of high counts there were more immature (Figs. 29 to 31) and myeloblastic forms (Figs. 27 and 28) present than during the periods of low counts. A lymph node removed at biopsy during the height of the proliferative activity showed that many of the "myeloblasts" were

produced in the germ centers and follicles. There was also some evidence to indicate that many of them were derived from the reticulum. These details are presented here in order to prove that cells of the myeloblastic type containing four and five nucleoli (Figs. 28 to 30) may be related to lymphocytes and that they are not necessarily derived from the marrow. In many respects this case was similar to the one reported by Citron.

The three cases just discussed demonstrate the difficulty of distinguishing between genuine myeloblasts from the marrow and cells having similar structure, but derived from lymphatic tissue and differentiating into lymphocytes. The literature shows that others have had the same difficulty, among them dualists like Türk, Gütig, Herz and Butterfield, Heineke and Meyer. Other important cases bearing on this question are those published by Krjukow, Lydtin, Du Toit, Chosrojeff and the earlier ones of Hirschfeld and Pappenheim.

The conclusion from these cases is, first, that in both types of acute leucemia and in chronic myelogenous leucemia a cell form appears in the blood and tissues, which is termed a myeloblast if the affection involves primarily the myeloid tissue and a lymphoblast if the disease is centered in the lymphatic tissue; and second, that the organic changes are by no means always as specific and definite as they are usually described, so that the histological study often fails to reveal the true nature of the leucemia, a fact which is difficult to explain from the dualistic standpoint. Sternberg, as early as 1905, called attention to these atypical organic changes and pointed out the difficulty of classifying some cases according to dualistic principles. His views have received support from the subsequent publication of numerous atypical cases, like those discussed above, and from the experimental work of Dominici, Hertz, Werzberg, Maximow and others.

Cases of so-called "mixed leucemia," of which there are a number on record, are of still greater importance in this question. Such a case was reported from the writer's laboratory by Dr. Logefeil. The diagnosis was first made from the blood smear and was based on the fact that it was possible to trace both lymphocytes and myelocytes to the myeloblast through numerous intermediate stages. Subsequent study of the organs confirmed the diagnosis and also gave evidence for the development of eosinophile myelocytes from small lymphocytes. The organ changes indicated simultaneous hypertrophy of both systems, and, what is more important, there was not the complete segregation of the two systems that has been reported in some other cases.

It is evident from the above discussion of the leucemias that they do not justify the strict dualistic concept if all of the facts are taken into consideration. In the ordinary chronic lymphatic and myelogenous cases there are independent reaction and complete segregation of the two tissues, but in many acute cases and in mixed leucemia the two systems converge to a com-

mon stem cell which is morphologically identical with the myeloblast of normal marrow. The exact diagnosis can be established only after the direction of differentiation has been determined. This monophyletic relationship based on a common stem cell of myeloblastic structure has, however, only limited application, because the myeloblast does not serve as a common stem cell in the chronic leucemias or in the normal adult.

III. OCCURRENCE IN THE NORMAL ADULT

Grawitz, Neumann, Ferrata, Di Guglielmo and Du Toit differ from the neo-unitarians in assuming that a lymphoidocyte of myeloblast structure serves as a common stem cell for both the lymphatic and myeloid systems in normal as well as pathological conditions. Their lymphoblast is identical with the myeloblast and it occurs in the lymphatic tissue of the normal adult. Pappenheim and Hirschfeld (1908) and Pappenheim and Ferrata (1910) could not find such a cell in the normal lymphatic tissue, but they believed that the lymphocytes of the embryo are derived from it. Danchakoff and Jolly derived the first lymphocytes of the embryonic spleen from large hemocytoblasts or "primitive spleen cells," probably identical with the lymphoidocyte of Pappenheim, but Sabin (1904), Maximow (1910), Türk (1912), Naegeli, and Thiel and Downey (spleen) found that the first lymphocytes of the embryonic lymphatic tissue are small lymphocytes with dark nuclei; they are derived directly from the mesenchyme without the intervention of a large, primitive lymphoid cell.

The writer found the section method to be of little value in the investigation of this problem (1924, 1926) and so made a careful search through the lymphatic tissue with the dry smear method. Cells resembling myeloblasts were not found, except in lymph nodes of guinea pigs and in the nodes of newly born rabbits. Two such cells from the newly born rabbit are shown in Figures 16 and 17. If they are compared with the myeloblasts from the marrow of a newly born rabbit (Figs. 3 and 4) it will be seen that their essential structures are practically identical with those of the latter; their nuclei are just as leptochromatic, their membranes just as thin and the nucleoli of Figure 17 are like those that are described as characteristic for the myeloblasts. If one did not know the source of the material, all of these cells would probably be diagnosed as marrow cells. Mature lymphocytes from a node of adult rabbit are shown in Figures 36 and 37. The difference in nuclear pattern is at once apparent. The thick chromatin strands and the heavy nuclear membrane are the characteristic features of the older cells. The immature forms (Figs. 16 and 17) do not occur in the nodes of the adult animals, but they do occur in the marrow as stem cells of the myeloid elements.

The most immature lymphocyte found in lymphatic tissue of a normal human adult is shown in Figure 15. It has several round nucleoli, but the

nucleus is pachychromatic and has thick chromatin strands which give this nucleus a very different appearance from that of the human myeloblast (Fig. 2) from the marrow.

The guinea pig is exceptional in that the nodes of the adult animal contain some very immature lymphocytes which are much like myeloblasts in structure. A cell of this kind is shown in Figure 38. It is practically identical with many myeloblasts of human marrow and leucemic blood, but its chromatin strands are a little coarser and the cytoplasm denser than is the case in the myeloblasts of the guinea pig marrow. Intermediate stages between cells of this type and more mature forms, like Figures 40 and 41, and the oldest cells, like Figures 36 and 37 (rabbit), prove that in the guinea pig the regeneration of lymphocytes is heteroplastic from a stem cell which resembles the myeloblast in many respects but is not identical with it. In rabbit and man the regeneration is largely homoplastic and so does not require the presence of an immature stem cell.

The reticulum serves as a reserve mother tissue for lymphocytes, the latter being differentiated from free cells isolated from the reticular network. This process is especially evident in the guinea pig (Downey and Weidenreich), which probably accounts for the presence of the numerous immature lymphocytes in this animal. This is difficult to prove in dry smears, but in sections it is seen that cells which are intermediate between those of the reticulum and lymphocytes have nuclei which resemble sections of myeloblast nuclei. In other animals and in man the lymphoidocyte stage is probably passed over so rapidly that it cannot be recognized. The guinea pig, then, does furnish some evidence in favor of the complete identity of the stem cells of the lymphatic and myeloid tissues (Dominici, Jolly, Maximow, Ferrata, Du Toit, Neumann).

The presence of cells of the myeloblastic type which are identical with true myeloblasts of the marrow in the nodes of newly born rabbits is in favor of the view of Pappenheim and Ferrata that the lymphocytes are derived from lymphoidocytes (myeloblasts) of the embryo. Against this view is the fact that numerous observers have claimed that the first lymphocytes of the embryo are the smaller lymphocytes with dark nuclei. They are derived from the mesenchyme of the developing nodes but do not seem to pass through the lymphoidocyte stage during the process of differentiation. It is possible that this stage is passed over very rapidly in the embryo and is delayed somewhat in the new-born.

The lymphoidocyte which appears in acute lymphatic leucemia and in mixed leucemia as a stem cell of the lymphocytes, and showing definite relations to the lymphatic tissue, is a cell which does not exist in the normal human and rabbit lymphatic tissue. The complete explanation of its occurrence and relationship to lymphocytes cannot be given at the present time. There is little hyperplasia of lymphatic tissue in some cases of acute

lymphatic leucemia, and in these cases one might assume de-differentiation of the lymphocytes to the primitive myeloblastic type. In other cases (Fineman, Ewald) there is evidence favoring the view that many of these cells are derived from the reticulum. In sections of nodes of these cases one has the advantage of being able to compare the cells in the vessels with those in the lymphatic tissue in the same section. One can note very little difference between the nuclei of the reticular cells and those of the myeloblasts in the vessels and tissue. Failure to differentiate is one of the characteristic features of the blood cells in acute leucemia, and one might assume that the cells which are cut off from the reticulum fail to acquire specific nuclear characters and so appear in the blood as myeloblasts. The result is that in acute lymphatic leucemia the blood is inhabited by lymphatic cells which do not exist in the normal lymphatic tissue, while in myelogenous leucemia similar cells which are normal constituents of the marrow are carried into the blood.

The fact that lymphoidocytes (myeloblasts) do not occur in normal lymphatic tissue proves that these cells are not essential for the development of lymphocytes. The myeloid elements usually require the presence of the myeloblast as a stem cell, but numerous observations of the direct metaplasia of lymphocytes to granulocytes and red cells (Dominici, Maximow, Weidenreich, Pappenheim, Jordan, Lang, Bloom) prove that myeloid tissue may also develop without the myeloblast. To a limited extent this occurs normally in the thymus, hemolymph nodes and mucosa of the digestive tract (Weidenreich, Weill). It has been observed frequently under experimental conditions which may even lead to myeloid metaplasia of the germ centers of the lymph follicles (Dominici, Roman, Lang, Bloom).

The conditions under which lymphocytes may differentiate to higher types of cells are discussed by Maximow on page 341. We may conclude that lymphocytes do not have an inherited inner disposition to differentiate, but they may do so when they are subjected to certain external influences. The myeloblast, on the other hand, is a more primitive type of cell and is predestined to differentiate, but may fail to do so under pathological conditions which inhibit this natural tendency, or the abnormal conditions may cause it to produce lymphocytes instead of myeloid elements. The final products of the normal differentiation of the myeloblast may also be derived from other sources, e.g., lymphocytes and free histiocytes of the connective tissue (Ferrata's hemohistiocytes).

It is evident from this brief discussion that the relationship of the blood cells to one another and to the myeloblast is variable under different conditions. In the normal adult it is quite different from what it is in certain pathological and experimental conditions and in the embryo. This complicates the myeloblast problem, and so a brief discussion of the position of the myeloblast in the hematological system may not be out of place.

IV. POSITION OF THE MYELOBLAST IN THE HEMATOLOGICAL SYSTEM

Naegeli (1923, p. 169) states that in recent years the myeloblast problem has undoubtedly become the most important one in hematology, because the decision of the fundamental question of the occurrence of two different leucocyte systems—lymphatic and myeloic—with morphologically different stem cells depends on the existence or non-existence of the myeloblast.

Recent investigations, however, seem to indicate that the myeloblast does not have the fundamental significance ascribed to it by Naegeli and that it does not necessarily enter into the question of the polyphyletic or monophyletic origin of blood cells. Ferrata recognizes the existence of the myeloblast as a morphological type, but believes that his hemohistiocyte (reticular cell, clasmatocyte, etc.) may differentiate into a granulocyte without passing through the myeloblast stage. Because he derives all types of blood cells, including lymphocytes, from the hemohistiocyte or hemohistioblast his hemocytoblast, morphologically identical with Naegeli's myeloblast, is no longer *the* polyvalent stem cell.

Pappenheim's last writings (1917, 1919) indicate a strong leaning towards a similar view and to some extent a reversal of former opinion regarding the position of the myeloblast (the lymphoidocyte of his terminology). He still believed the lymphoidocyte to be both myelopotent and lymphopotent, but in the normal adult it is to be found only in the marrow and, therefore, represents normally the first stage of differentiation in the myeloid series corresponding to the lymphoblast in the lymphocyte series. The real stem cell is now the histiocyte of Aschoff, the reticulo-endothelial cell, or the clasmatocyte (Ferrata's later hemohistiocyte). He still believed in the relationship between lymphoidocytes and lymphocytes in acute lymphatic leucemia and referred to Du Toit's work as the strongest evidence so far presented in favor of such a view. But for normal adult conditions he was in practical agreement with Naegeli's dualism as it applies to the independence of the lymphatic and myeloid series in their relations to the myeloblast.

Recently Cunningham, Sabin and Doan have studied the origin and differentiation of the myeloblast by means of the supravital technique of Sabin (1923). They claim that the myeloblast is partially differentiated along myeloid lines, giving rise to granulocytes only. It and the lymphocytes and monocytes are derived from a free "primitive blood cell" which in turn comes from the reticulum of the blood-forming organs. Red cells are derived from the endothelium of marrow capillaries. They recognize no relationships between lymphocytes or their immature forms, the lymphoblasts and myeloblasts, except through the primitive blood cells which can be recognized by the supravital technique, but cannot be distinguished from myeloblasts when seen in dry smears.

This genealogy of the blood cells is more polyphyletic than Naegeli's scheme, but both are monophyletic to the extent that they recognize the existence of a primitive connective tissue cell which can differentiate into all types of blood cells except erythrocytes. This is Naegeli's indifferent primitive mesenchyme cell which he believes exists in all of the blood-forming organs and the loose connective tissue, especially in the neighborhood of the blood vessels. In both of these schemes the myeloblast is an essential intermediary in the differentiation of granulocytes and it is already differentiated to the extent that it can no longer give rise to lymphocytes.

This was also Pappenheim's latest theory for the normal adult, but for pathological and experimental conditions he believed that the differentiation of the myeloblast could be diverted to the lymphocyte side of the "Stammbaum."

According to Ferrata the myeloblast and myelocyte stage is often skipped (in leucemia) and there is direct differentiation of the primitive connective tissue cell (hemohistioblast) to the other types of blood cells. The position of the myeloblast (his hemocytoblast) becomes rather uncertain. It is on a higher differential level than the hemohistioblast, but may nevertheless develop into lymphocytes as well as granulocytes.

Klein (1914) and Brinkmann (1924) described "Myelogonia" which are much like the cells which Ferrata later named "hemohistiocytes." Klein finds these cells to be abundant in both myelogenous and lymphatic leucemias and especially in those of the myeloblastic type. They are also to be found in normal blood in small numbers. These cells are regarded as the mother cells of all the myeloid cells, including the megacaryocytes and reds, and Klein believes that he can identify them in smears and sections of marrow and other hematopoietic organs. They are more primitive than the myeloblast and show transitional stages to the latter.

Cells more primitive than the myeloblast were also described by Ewald (1923) in a case of acute leucemia which he classifies as one of "acute reticulo-endotheliosis." These cells show some resemblance to myeloblasts, but are regarded as being more primitive cells which are derived from the reticulum of the spleen and marrow and the stellate cells of the liver sinusoids. The author believes that in this case the entire reticulo-endothelium is irritated so that it produces new cells, while in the usual type of acute leucemia more highly differentiated cells, the myeloblasts or lymphoblasts, are affected. Dieckmann and Lindbom also derived myeloblasts from the reticulo-endothelium lining the splenic sinuses, while Kahle thought that he could trace their origin from the capillary endothelium in an angiosarcoma of the liver.

Further discussion along this line is not desired, but enough has been said to indicate that the conclusion to be drawn from these and some other

recent writings is, that the authors' ideas regarding the origin and relationship of blood cells are no longer determined by the question of the existence or non-existence of the myeloblast. With few exceptions the existence of such a cell type is now generally recognized, but it has been fitted into both the monophyletic and polyphyletic schemes and, according to Dominici, Ferrata and many others, lymphocytes or hemohistioblasts may differentiate directly into granulocytes without passing through the myeloblast stage.

Although the question of the origin and relationship of blood cells does not depend entirely on the myeloblast, the myeloblast problem is still of theoretical interest and of very great practical importance in the diagnosis of blood diseases.

Recent work on the myeloblast justifies the following conclusions regarding its position and significance:

V. CONCLUSIONS

In the normal adult rabbit and human organism the myeloblast occurs only in the bone marrow where it functions as a stem cell for the heteroplastically developing myeloid elements.

A cell which is morphologically identical with the myeloblast also serves as a stem cell for lymphocytes in the lymph nodes of newly born rabbits, and in many cases of acute and rare cases of chronic lymphatic leucemia, where regeneration of lymphocytes is also heteroplastic. In mixed leucemia it is a stem cell for both lymphocytes and granulocytes.

The lymphoidocyte or myeloblast probably originates from the reticulum. Lymphocytes may also differentiate from the free cells of the reticulum without passing through the lymphoidocyte stage, but normally their regeneration is largely homoplastic by division of their own kind.

Myeloblasts may result from the process of de-differentiation of granulocytes and lymphocytes in cases of hypoplastic acute leucemia.

Myelocytes and fully differentiated granular leucocytes are derived from all types of lymphocytes during myeloid metaplasia resulting from experimental and pathological conditions. This is usually direct metaplasia which does not require de-differentiation to the myeloblast. Occasionally this process occurs under normal conditions.

The lymphocyte is a polyvalent cell with the capacity to differentiate in various directions, depending largely on external conditions. The myeloblast has greater capacity for differentiation, but is a more primitive cell phylogenetically and so is concerned normally with the differentiation of several types of cells, while the lymphocyte of the normal organism usually fails to differentiate into higher types of cells.

The dualistic concept is true only in so far as it concerns the myeloblast and myeloid tissue in the normal adult, but it does not account for the

numerous instances of direct relationship between myeloblasts and lymphocytes, and between the latter and granulocytes under pathological and experimental conditions. The monophyletic theory in its neo-unitarian modification, as advocated by Pappenheim, accounts for most conditions, but must be expanded to include the myeloid metaplasia of genuine lymphocytes.

VI. BIBLIOGRAPHY

Alder, A. 1923. Ueber abnorme Zellformen und ihre Häufigkeit bei akuter Myelose. *Folia Haematol.*, Archiv, **29**, 1.

Auer, J. 1906. Some hitherto undescribed structures found in the large lymphocytes of a case of acute leukemia. *Amer. Jour. Med. Sci.*, **131**, 1002.

Betances, L. M. 1918. *La granulation azurophile.* Paris: Le François.

Bloom, W. 1926. The hemopoietic potency of the small lymphocyte. *Folia Haematol.*, Archiv, in press.

Brinkmann, E. 1924. Ueber "Stammzellenleukämie." *Folia Haematol.*, Archiv, **31**, 51.

Browning, C. H. 1905. Observations on the development of the granular leucocytes in the human fetus. *J. of Path. and Bact.*, **10**, 145.

Butterfield, E. E. 1908. Ueber die ungranulierten Vorstufen der Myelocyten und ihre Bildung in Milz, Leber und Lymphdrüsen. *Deutsch. Arch. f. klin. Med.*, **92**, 336.

Butterfield, E. E., Heineke, A., and Meyer, E. 1909. Ueber das Vorkommen der Altmannschen Granulationen in den weissen Blutzellen. *Folia Haematol.*, **8**, 325.

Chosrojeff, G. P. 1915. Myelosis aleucaemica acuta micromyeloblastica. *Folia Haematol.*, Archiv, **20**, 33.

Citron, J. 1915. Ueber zwei bemerkenswerte Fälle von (akuter) Leukämie. *Folia Haematol.*, Archiv, **20**, 1.

Cornil, V. 1887. Sur la multiplication des cellules de la moelle des os par division indirecte dans l'inflammation. *Arch. de Physiol. Norm. et Pathol.*, 3 Ser., **10**, 46.

Cowdry, E. V. 1914. The vital staining of mitochondria with janus green and diethylsafranin in human blood cells. *Intern. Monastschr. f. Anat. u. Physiol.*, **31**, 267.

Cunningham, R. S., Sabin, F. R., and Doan, C. A. 1925. The development of leukocytes, lymphocytes and monocytes from a specific stem-cell in adult tissues. *Contrib. to Embryol., No. 84, Carnegie Inst. of Washington*, publication 361, Vol. 16, 227.

Danchakoff, V. 1916*a*. Equivalence of different hematopoietic Anlages. (By method of stimulation of their stem cells.) *Am. J. Anat.*, **20**, 255.

—— 1916*b*. Origin of the blood cells. Development of the hematopoietic organs and regeneration of the blood cells from the standpoint of the monophyletic school. *Anat. Record*, **10**, 397.

Dieckmann, H. 1922. Histologische und experimentelle Untersuchungen über extramedulläre Blutbildung. *Virchow's Archiv*, **239**, 451.

Di Guglielmo, G. 1916. *La leucemia acuta.* Napoli: N. Jovene, E. C.

Döhrer and Pappenheim. 1913. Ein weiterer Fall von akuter Mikrolymphoidozytenleukämie. *Folie Haematol.*, Archiv, **16**, 145.

v. Domarus, A. 1908. Ueber die Blutbildung in Milz und Leber bei experimentellen Anämien. *Arch. f. exper. Path. u. Pharmakol.*, **58**, 319.

Dominici, H. 1902. Polynucléaires et macrophages. *Arch. de Méd. Expér. et d'Anat. Pathol.*, **14**, 1.

—— 1909. De l'origine lymphatique ou amyéloide des polynucléaires ou leucocytes granuleux à noyau polymorphe. *Folia Haematol.*, **8**, 97.

Dominici, H. 1921. Études sur le tissu conjonctif et les organes hématopoiétiques des mammifères. *Arch. d'Anat. Microscop.*, **17**, 3, 83 and 247.

Downey, H. 1924. The occurrence and significance of the "myeloblast" under normal and pathologic conditions. *Arch. Int. Med.*, **33**, 301.

——— 1926. The myeloblast—its occurrence under normal and pathologic conditions, and its relations to lymphocytes and other blood cells. *Folio Haematol.*, Archiv, in press.

Downey, H., and McKinlay, C. A. 1923. Acute lymphadenosis compared with acute lymphatic leukemia. *Arch. Int. Med.*, **32**, 82.

Downey, H., and Weidenreich, F. 1912. Ueber die Bildung der Lymphocyten in Lymphdrüsen und Milz. *Arch. f. mikr. Anat. u. Entwgsch.*, **80**, Abt. 1, 306.

Du Toit, P. J. 1916. Beitrag zur Morphologie des normalen und des leukämischen Rinderblutes. *Folia Haematol.*, Archiv, **21**, 1.

Ehrlich, P., and Lazarus, A. 1898. Die Anämie. 1. Abt.: Normale und Pathologische Histologie des Blutes. *Nothnagel's spez. Pathologie u. Therapie*, VIII.

Engel, C. S. 1897. Hämatologischer Beitrag zur Prognose der Diphtherie. *Deutsch. med. Wochenschr.*, **23**, 118, 137.

Leukamien. *Folia Haematol.*, Archiv, **10**, 459.

Ewald, O. 1923. Die leukämische Reticuloendotheliose. *Deutsch. Arch. f. klin. Med.*, **142**, 222.

Fabian, Naegli and Schatiloff. 1907. Beiträge zur Kenntnis der Leukämie. *Virchow's Archiv*, **190**, 436.

Ferrata, A. 1910. Einige neue Feststellungen über die Vorstufen der Granulozyten. *Folia Haematol.*, Archiv, **9**, 549.

—— 1918. *Le emopatie*. Vol. 1, Parte Generale; Vol. 2, Parte Speciale (1923). Milano: Societa Editrice Libraria.

Fineman, S. 1922. A study of microlymphoidocytic leukemia. *Arch. Int. Med.*, **29**, 168.

Fischer, H. 1909. *Myeloische Metaplasie und fötale Blutbildung und deren Histogenese*. Berlin: J. Springer.

Fraenkel, A. 1895. Ueber acute Leukämie. *Deutsch. med. Wochenschr.*, **21**, 639.

Gordon, A. K. 1919. The lymphoidocyte and its clinical significance. *The Lancet*, **197**, No. 5003, 108.

Gräff, S. 1925. Der kolorimetrische Nachweis von Zelloxydase unter optimalen Bedingungen. *Centralbl. f. allgem. Path. u. path. Anat.*, **35**, 481.

Grawitz, E. 1911. *Klinische Pathologie des Blutes*. Leipzig: G. Thieme.

Gruner, O. C. 1914. *The biology of the blood-cells*. New York: Wm. Wood.

Gütig, K. 1907. Ein Beitrag zur Morphologie des Schweineblutes. *Arch. f. mikr. Anat. u. Entwsgsch.*, **70**, 629.

Helly, K. 1910a. Anämische Degeneration und Erythrogonien. *Beitr. z. path. Anat. u. z. allgem. Pathol.* (Ziegler), **49**, 15.

1910b. Kritik der sogennanten Myeloblasten. *Verh. d. deutsch. path. Gesellsch.*, **14**, 198.

Hertz, R. 1910. Zur Frage der experimentellen myeloischen Milz-Metaplasie. *Zeitschr. f. klin. Med.*, **71**, 435.

Herz, A. 1911. *Die akute Leukämie*. Leipzig: Franz Deuticke.

Herzog, G. 1915. Experimentelle Untersuchungen über die Einheilung von Fremdkörpern. *Beitr. z. path. Anat. u. z. allgem. Pathol.* (Ziegler), **61**, 325.

Hirschfeld, H. 1898. Zur Kenntnis der Histogenese der granulierten Knochenmarkzellen. *Virchow's Archiv*, **153**, 335.

- - — 1902. Ueber myeloide Umwandlung der Milz und der Lymphdrüsen. *Berliner klin. Wochenschr.*, **39**, 701.

Hirschfeld, H. 1907. Ueber akute Leukämie. *Folia Haematol.*, **4**, 202.
——— 1908. Ueber die unitarische und die dualistische Auffassung über die Histopathologie der Leukämien. *Ibid.*, **6**, 382.
Horwitz, K. 1904. Ueber die Histologie des embryonalen Knochenmarks. *Wiener med. Wochenschr.*, **54**, Nos. 31–35.
Hynek, K. 1912. Zur Monozytenfrage. *Folia Haematol.*, Archiv, **13**, 345.
Isaac, S., and Cobliner, S. 1910. Ueber mikrolymphozytäre Typen akuter myeloischer Leukämien. *Folia Haematol., Archiv*, **10**, 459.
Jolly, J. 1923. *Traité technique d'hématologie.* Paris: A. Maloine et Fils.
Jordan, H. E., and Speidel, C. C. 1923. The fate of the mammalian lymphocyte. *Anat. Record*, **26**, 223.
Kahle, H. 1919. Ueber ein Hämogonien und Leukozyten erzeugendes Angiosarkom in zirrhotischer Leber. *Virchow's Archiv*, 226.
Klein, S. 1910. Ueber die grossen einkernigen Leukozyten des Leukämieblutes. *Folia Haematol.*, Archiv, **10**, 475.
——— 1914. *Die Myelogonie als Stammzelle der Knockenmarkszellen im Blute und in den blutbildenden Organen und ihre Bedeutung unter normalen und pathologischen Verhältnissen.* Berlin: J. Springer.
Kleinenberger, C. 1909. Akuter Übergang einer chronischen myeloiden Leukämie in eine (akute) Myeloblastenleukämie. *Deutsch. med. Wochenschr.*, **35**, 2161.
Krjukow, A. 1913. Ueber einen Fall von akuter Mikrolymphoidozytenleukämie. *Folia Haematol.*, Archiv, **15**, 328.
Lambin, P. 1924. Sur les rapports des cellules réticulaires et des cellules lymphoides du parenchyme myéloide. *C. R. de l'Assoc. des Anatomists*, **19**, 190.
—— 1924. Contribution à l'étude des cellules de Ferrata dans la leucémie granulocytique. *Ibid.*, **19**, 177.
Lang, F. J. 1926. Experimentelle Untersuchungen über die Histogenese der extramedullären Myelopoese. *Zeitschr. f. Mikr.-Anat. Forschung*, **4**, 417.
Latta, J. S. 1921. The histogenesis of dense lymphatic tissue of the intestine (Lepus). A contribution to the knowledge of the development of lymphatic tissue and blood-cell formation. *Am. J. Anat.*, **29**, 159.
Lazarus, A., and Naegeli, O. 1913. *Die Anaemie* (Ehrlich and Lazarus), 1. Abteil., 1. Teil: Die normale und pathologische Histologie des Blutes (Lazarus and Naegeli), Ed. 2 (H. Nothnagel, spezielle Pathologie und Therapie, Bd. VIII). Wien und Leipzig: A. Hölder, 1909 (Volume completed in 1913).
Lenaz, L. 1921. Megaloblasten und Plasmazellen. *Folia Haematol.*, Archiv, **26**, 151.
Lindbom. 1919. Akute Leukämie. *Svensk. Läkaresällsk.* Handl. 45. (Abstract in *Deutsch. med. Wochenschr.*, **46**, 52.)
Lubliner, R. 1918. Ein Fall von atypischer chronischer myeloischer Leukämie mit zahlreichen Hauteruptionen und Übergang in Mikromyeloblastenleukämie. *Folia Haematol.*, Archiv, **22**, 15.
Lydtin, H. 1913. Ein Fall von Mikromyeloblastenleukamie. *Folia Haematol.*, Archiv, **15**, 316.
Marchand, F. 1913. Ueber die Herkunft der Lymphozyten und ihre Schicksale bei der Entzündung. *Verh. d. Deutschen Path. Gesellsch.*, **16**, 5.
—— 1916. Beitrag zur Pathologie und pathologischen Anatomie des Bronchialasthma. *Beitr. z. path. Anat. u. z. allgem. Pathol.* (Ziegler), **61**, 251.
Maximow, A. 1907. Experimentelle Untersuchungen zur postfötalen Histogenese des myeloiden Gewebes. *Beitr. z. path. Anat. u. z. Allgem. Pathol.* (Ziegler), **41**, 122.
——— 1909. Der Lymphozyt als gemeinsame Stammzelle der verschiedenen Blutelemente in der embryonalen Entwicklung und im postfetalen Leben der Säugetiere. *Folia Haematol.*, **8**, 125.

Maximow, A. 1910. Untersuchungen über Blut and Bindegewebe. III. Die Embryonale Histogenese des Knockenmarks der Säugetiere. *Arch. f. mikr. Anat.*, **76**, 1.

—— 1923. Ueber die experimentelle Erzeugung von myeloiden Zellen in Kulturen des lymphoiden Gewebes. *Ibid.*, **97**, 314.

—— 1924*a*. Relation of blood cells to connective tissue and endothelium. *Physiological Reviews*, **4**, No. 4, 533.

—— 1924*b*. Tuberculosis of mammalian tissue in vitro. *J. Infect. Dis.*, **34**, 549.

Mayer, Edmund and Furuta. 1924. Zur Frage der Lymphknötchen im menschlichen Knockenmark. *Virchow's Archiv*, **253**, 574.

Menten, M. L. 1919. A study of the oxydase reaction with alpha-naphthol and paraphenylendiamine. *J. Med. Research*, **40**, 433.

Meyer, E. 1908. Weitere Untersuchungen über extrauterine Blutbildung. *Münch. med. Wochenschr.*, **22**, 1161.

Meyer, E., and Heineke. 1907. Ueber Blutbildung bei schweren Anämien und Leukämien. *Deutsch. Arch. f. klin. Med.*, **88**, 435.

Michaelis, L., and Wolff, A. 1901. Die Lymphozyten. *Deutsch. med. Wochenschr.*, **27**, 651.

Mollier, S. 1909. Die Blutbildung in der embryonalen Leber des Menschen und der Säugetiere. *Arch. f. mikr. Anat.*, **74**, 474.

Morawitz, P., and Rehn, E. 1907. Ueber einige Wechselbeziehungen der Gewebe in den blutbildenden Organen. *Deutsch. Arch. f. klin. Med.*, **92**, 109.

Müller, H. F. 1891. Zur Leukämie-Frage. Zugleich ein Beitrag zur Kenntnis der Zellen und der Zellteilungen des Knochenmarks. *Deutsch. Arch. f. klin. Med.*, **48**, 47.

——— 1894. Die Morphologie des leukämischen Blutes und ihre Beziehungen zur Lehre von der Leukämie. Zusammenfassendes Referat. *Centralbl. f. allgem. Path. u. path. Anat.*, **5**, 553.

Naegeli, O. 1900. Ueber rotes Knochenmark und Myeloblasten. *Deutsch. med. Wochenschr.*, **26**, 287.

——— 1913. *Leukämie und Pseudoleukämie*. Nothnagel's Spezielle Pathologie und Therapie, **8**. Wien und Leipzig: A. Hölder.

——— 1923. *Blutkrankheiten und Blutdiagnostik*. Ed. 4, Berlin: J. Springer.

Neumann, E. 1912. Hämatologische Studien. 3. Leukocyten und Leukämie. *Virchow's Archiv*, **207**, 379.

Pappenheim, A. 1899. Vergleichende Untersuchungen über die elementare Zusammensetzung des roten Knochenmarks einiger Säugetiere. *Virchow's Archiv*, **157**, 19.

——— 1900. Von den gegenseitigen Beziehungen der verschiedenen farblosen Blutzellen zu einander. *Ibid.*, **159**, 40.

——— 1905–12. *Atlas der menschlichen Blutzellen* (1905–9). Supplement-Band (1911–12). Jena: G. Fischer.

——— 1907*a*. Zwei Fälle akuter grosslymphozytärer Leukämie. *Folia Haematol.*, 4, Supplementheft 3, 301.

——— 1907*b*. Ueber die Stellung der akuten grosszellig lymphozytären Leukämie im nosologischen System der Leukämien und die Bedeutung der grossen Lymphozyten Ehrlich's an und für sich und für die Pathologie dieser Erkrankung. *Ibid.*, **4**, 1.

——— 1908. Ueber die grosse mononucleäre ungekörnte Zelle unter den Leucocyten. *Ibid.*, **6**, 217.

——— 1909. Zur vorstehender Mitteilung Dominici's. *Ibid.*, **8**, 107.

——— 1910*a*. Bemerkungen über artliche Unterschiede und die gegenseitigen Beziehungen zwischen den verschiedenen Zellformen des Blutes. *Ibid.*, **9**, 321.

——— 1910*b*. Neue zytomorphologische Studien an Blutzellen mit farbenanalytische Methoden III. *Ibid.*, **9**, 572.

——— 1910*c*. Ueber die Azurkörnung in den lymphoiden Blutzellen. *Ibid.*, **9**, 553.

Pappenheim, A. 1914. *Die Zellen der leukämischen Myelose.* Text and Atlas. Jena: G. Fischer.

——— 1917. Ueber die Wandlung des Lymphoidozytenbegriffs und der Blutstammzellen. *Folia Haematol.*, Archiv, **21**, 207.

——— 1919. *Morphologische Hämatologie,* Bd. I. u. II. Leipzig: W. Klinkhardt.

Pappenheim, A., and Ferrata, A. 1910. Ueber die verschiedenen Zellformen des normalen und pathologischen Blutes mit spezieller Berücksichtigung der grossen Mononukleären des Normalblutes und ihrer Beziehung zu Lymphozyten und myeloischen Lymphoidzellen. (Am. Meerschweinchen demonstriert). *Folia Haematol.*, Archiv, **10**, 78.

Pappenheim, A., and Hirschfeld, H. 1908. Ueber akute myeloide und lymphadenoide mikrolymphozytäre Leukämie an der Hand von zwei verschiedenen Fällen. *Folia Haematol.*, Archiv, **5**, 347.

Richter, M. N. 1925. Leukemia. The relative values of cell morphology and the peroxydase reaction as diagnostic aids. *Arch. Inter. Med.*, **36**, 13.

Rieder, H. 1893. *Atlas der klinischen Mikroskopie des Blutes.* Leipzig.

Roman, B. 1913. Zur Kenntnis der myeloischen Chloroleukämie. *Beitr. z. path. Anat. u. z. allgem. Pathol.* (Ziegler), **55**, 61.

Rubinstein, H. 1901. Ueber die Veränderungen des Knochenmarks bei Leukocytose. *Zeitschr. f. klin. Med.*, **42**, 161.

Sabin, F. 1904. The development of the lymphatic nodes in the pig and their relation to the lymph hearts. *Am. J. Anat.*, **4**, 355.

——— 1923. Studies of living human blood cells. *Johns Hop. Hosp. Bull.*, **34**, 277.

Sabin, Austrian, Cunningham, Doan. 1924. Studies on the maturation of myeloblasts into myelocytes and on amitotic cell division in the peripheral blood in subacute myeloblastic leukemia. *J. Exper. Med.*, **40**, 845.

Schleip, K. 1908. *Hematological atlas.* New York: Rebman & Co.

Schridde, H. 1907*a*. Myeloblasten, Lymphoblasten und lymphoblastische Plasmazellen. *Beitr. z. path. Anat. u. z. allgem. Pathol.* (Ziegler), **41**, 223.

——— 1907*b*. Weitere Beobachtungen über die lymphozytären Zellen des Menschen. *Folia Haematol.*, 4, Supplementheft **3**, 285.

——— 1913. Die blutbereitenden Organe. Ch. III, Vol. 2, L. Aschoff, *Pathologische Anatomie,* Ed. 2, Jena: G. Fischer.

Schridde, H., and Naegeli, O. 1921. *Die hämatologische Technik.* Jena: G. Fischer.

Schur, H., and Löwy, H. 1900. Ueber das Verhalten des Knochenmarks in Krankheiten und seine Beziehung zur Blutbildung. *Zeitschr. f. klin. Med.*, **40**, 412.

Siegmund, H. 1923. Reizkörpertherapie und aktives mesenchymatisches Gewebe. *Münch. med. Wochenschr.*, **70**, 5.

Sternberg, C. 1905. Primärerkrankungen des lymphatischen und hämatopoetischen Apparates; normale und pathologische Morphologie des Blutes. *Ergeb. der allgem. Pathol. u. path. Anat.* (Lubarsch-Ostertag), **9**, (II), 360.

Thiel, G. A., and Downey, H. 1921. The development of the mammalian spleen, with special reference to its hematopoietic activity. *Am. J. Anat.*, **28**, 279.

Troje. 1892. Ueber Leukämie und Pseudoleukämie. *Berliner klin. Wochenschr.*, **29**, 285.

Türk, W. 1903. Ein System der Lymphomatosen. *Wiener klin. Wochenschr.*, **70**, No. 39, 1073.

——— 1906. Ueber die Beziehungen zwischen myeloidem und lymphoidem Gewebe im Verlaufe der Leukämien. *Verh. des Kong. f. innere Med.*, **23**, 585.

——— 1912. *Vorlesungen über klinische Haematologie.* II, Teil, I. Hälfte. Wien u. Leipzig: W. Braumüller.

Wallgren, A. 1909. Zur Kenntnis der lymphoiden Zellen des Kaninchenblutes. *Folia Haematol.*, **8**, 307.

Walz, K. 1901. Leukämie. Zusammenfassendes Referat über die neuere Literatur. *Centralbl. f. allgem. Pathol. u. path. Anat.*, **12**, 967.

Weidenreich, F. 1909. Zur Morphologie und morphologische Stellung der ungranulierten Leukocyten—Lymphocyten—des Blutes und der Lymphe. *Arch. f. mikr. Anat.*, **73**, 793.

——— 1910. Die Morphologie der Blutzellen und ihre Beziehungen zu einander. *Anat. Record*, **4**, 317.

——— 1911. *Die Leukocyten und verwandte Zellformen.* Wiesbaden: J. F. Bergmann.

——— 1912. Die Thymus des erwachsenen Menschen als Bildungsstätte ungranulierter und granulierter Leukocyten. *Münch. Med. Wochenschr.*, **59**, No. 48, 2601.

Weill, P. 1919*a*. Ueber die Bildung von granulierten Leukocyten im Karzinomgewebe. *Virchow's Archiv*, **226**, 212.

——— 1919*b*. Ueber die leukocytären Elemente der Darmschleimhaut der Säugetiere. *Arch. f. mikr. Anat.*, **93**, 1.

——— 1919*c*. Ueber das regelmässige Vorkommen von Myelocyten in der Milz des erwachsenen Menschen. *Ibid.*, **93**, 82.

Werzberg, A. 1911. Neue experimentelle Beiträge zur Frage der myeloiden Metaplasie. *Virchow's Archiv*, **204**, 272.

Wolff, A. 1902. Ueber die Bedeutung der Lymphoidzelle bei der normalen Blutbildung und bei der Leukämie. *Zeitschr. f. klin. Med.*, **45**, 385.

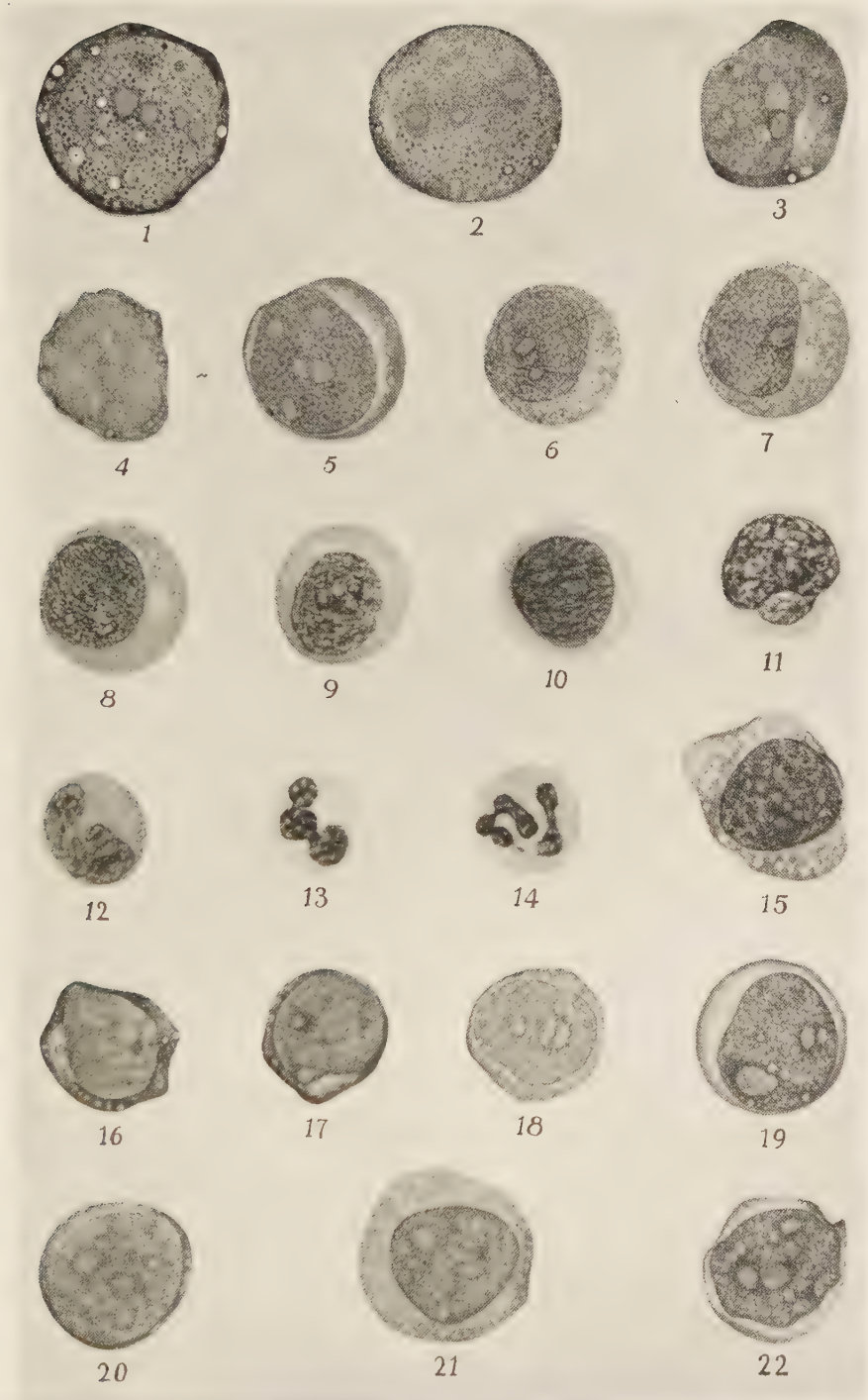

PLATE I, Figures 1–22.—The myeloblast. See following page for detailed description.

PLATES I and II*

FIGS. 1 and 2.—Myeloblasts from human marrow. FIGS. 3 and 4.—Myeloblasts from marrow of newly-born rabbit. FIGS. 5 to 14.—Various stages of differentiation of the myeloblast to the mature neutrophile leucocyte from blood of case of myelogenous leucemia. (After Pappenheim, 1914.) FIG. 5.—Myeloblast. FIGS. 6 to 8.—Leucoblasts. FIG. 9.—Promyelocyte. FIGS. 10 and 11.—Myelocytes. FIG. 12.—Metamyelocyte. FIG. 13.—Young neutrophile leucocyte. FIG. 14.—The fully differentiated mature cell. FIG. 15.—Somewhat immature lymphocyte with five nucleoli, human spleen. FIGS. 16 and 17.—Very immature lymphocytes, identical with myeloblasts from marrow (see Figs. 3 and 4), from lymph node of newly-born rabbit. FIGS. 18 to 26.—Lymphocytes from blood of case of acute lymphatic leucemia to show differentiation of mature lymphocytes from a primitive cell with nucleoli, which is identical with the myeloblast. Figures 18 and 20 are the most immature cells of the series and they cannot be distinguished from myeloblasts. Progressive differentiation to the more mature forms is illustrated in Figures 21, 19, 22 to 26. FIGS. 27 to 32.—Lymphocytes from another case of acute lymphatic leucemia (Fineman). Figure 27 has the structure of a small myeloblast. The other cells of the series are arranged in order according to the degree of their maturity. From two to five nucleoli were noted in most of the immature cells of this case. FIGS. 33 and 34.—Myeloblasts from case of myelogenous leucemia. FIG. 35.—Immature lymphocyte from chronic lymphatic leucemia. The inner structure of its nucleus is identical with that of the genuine myeloblast of Figure 34. FIGS. 36 and 37.–Mature lymphocyte from dry smear of lymph node of adult rabbit. FIGS. 38 and 39.—Very immature lymphocytes from dry smear of lymph node of adult guinea pig. Their nuclear pattern is similar to that of the myeloblast, but is somewhat coarser. FIGS. 40 and 41.—More mature lymphocytes from same smear of guinea pig lymph node. The mature cells resemble those of the rabbit (Figs. 36, 37).

All of the figures are based on dry smears. Figures 5 to 14 are from Pappenheim's atlas (1914), the others are photographs of the author's original colored drawings (Artists: Carol Young Alwin, Miss Parker) from preparations stained with Wright's blood stain or Pappenheim's May-Giemsa combination.

*Consecutive figures 145 to 185

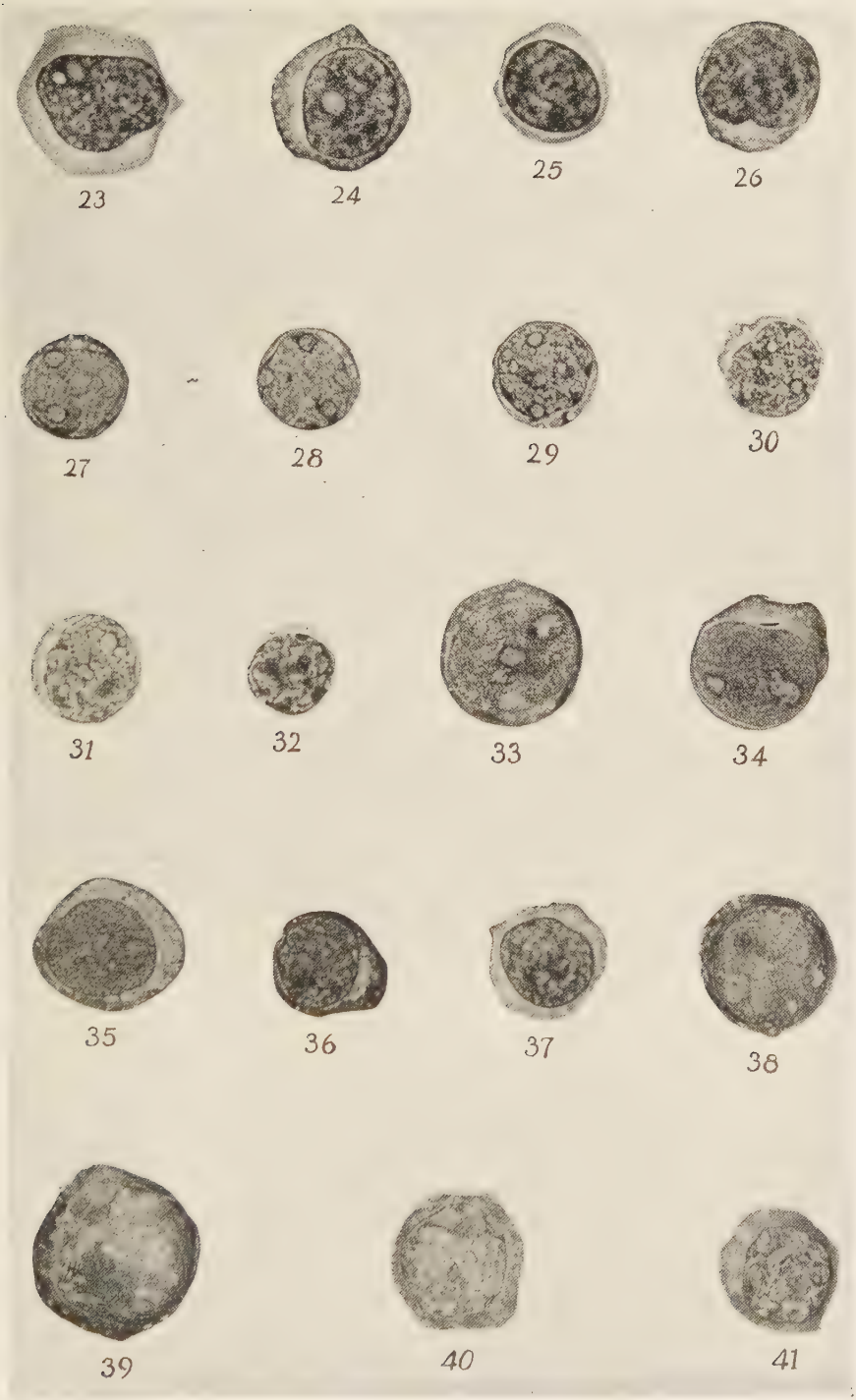

PLATE II, Figures 23–41.—The myeloblast.

Section XIII

THE GRANULAR LEUCOCYTES

CONTENTS

Section XIII

PAGE

I. Polymorphonuclear Neutrophilic Leucocyte 403
1. Number and distribution 403
2. Size 404
3. Nucleus 404
4. Cytoplasm 406
5. Motility 408
6. Origin 409
7. Function 410
8. Fate 411
II. Eosinophilic Leucocyte 411
III. Basophilic Leucocyte 415
IV. Blood Platelets 417
1. Character 417
2. Distribution and number 418
3. Origin 420
4. Function 421
V. Megalocaryocyte 421
VI. Bibliography 423

Section XIII

THE GRANULAR LEUCOCYTES

C. H. BUNTING

I. THE POLYMORPHONUCLEAR NEUTROPHILIC LEUCOCYTE

THE polymorphonuclear neutrophilic leucocyte belongs to a limited group of body units which may be called "end cells." An end cell may be defined as a cell incapable of further differentiation or of multiplication. This characteristic of the neutrophilic leucocyte, in addition to its striking morphology, its active motility and its importance in pathological processes, renders it a cell of great interest.

In the century which followed Hewson's discovery of the colorless corpuscles, the advance in our knowledge of the circulating leucocytes was by slow accretion. Wharton Jones, in 1846, described finely and coarsely granular leucocytes in the blood, adopting the term "granule cell" from Vogel, who had used it to designate a form of cell found in inflammatory exudates. In 1865, Max Schultze, in a study of blood by means of the warm stage, had clearly differentiated the actively ameboid, finely granular leucocyte with two or more nuclear masses, from the coarsely granular cell, and from the lymphoid elements and mononuclears. It remained, however, for Ehrlich, following his introduction of the fixed and stained blood film in 1879, to separate the leucocytes into the classes we recognize today. It required almost a generation more to eradicate the error indicated by Ehrlich's term "Transitional" for the monocyte with lobed nucleus and to bring hematologists to the conception, now a matter of common acceptance, that the neutrophilic leucocyte neither arises from nor develops into any other type of white cell found in the circulating blood of the normal individual.

1. *Number and distribution:*

The neutrophilic or "species" or "special" leucocyte forms approximately 65 per cent of the leucocytes found in each cubic millimeter of circulating blood in a healthy man, or practically 5000 per cubic millimeter in the average total count of 7500. This may be asserted only on the assumption that there is a uniform distribution of leucocytes in all parts of the vascular tree and that the blood from the cutaneous and subcutaneous vessels commonly used for clinical counts therefore gives an accurate sample of the whole. It seems reasonable to assume this to be true in ordinary circumstances, as the total count of white cells and differential proportion remain fairly constant when the blood is taken at a fixed time on successive days. In spite of this relative constancy, there is a diurnal variation in number and proportion of leucocytes that is striking. There is a morning minimum and late afternoon maximum in total numbers. Unpublished counts by Ethel Thewlis carried out on four individuals throughout the twenty-four hours showed the minimum (4000 and 5000 cells) in two at 4 A.M. and in the

other two at 9 A.M. Between these minima and the afternoon maxima there was approximately a difference of 5000 cells in each case without great variation in the differential proportions. Sabin and her co-workers have published curves showing a similar diurnal variation, but with serrations imposed upon it, indicating an hourly rhythm with maximum and minimum counts approximately one-half hour apart and frequently differing from each other by over 2000 cells. It is important that the possibility of such normal variations be considered in interpreting experimental results and clinical findings.

Except for their presence in the bone marrow, neutrophile leucocytes appear to be confined to the blood stream in the normal man or animal. They are not found in the tissues generally or in the stroma of the organs, as are lymphocytes.

2. *Size:*

To one who is accustomed to study blood cells in stained films, it is a surprise to find that when the cells are allowed to "round up" in a fairly thick fresh blood preparation, the neutrophiles measure but a scant 10μ in diameter. The range of variation in diameter given by Schultze and commonly accepted is from 9 to 12μ. When coagulated in tissues or blood stream by a fixing fluid such as Zenker's fluid, the cells vary from 6.5 to 8μ in diameter, unless they have imbibed serum as in an inflammatory exudate.

3. *The nucleus:*

That which distinguishes the neutrophile morphologically from all other body cells is the character of its nucleus. While early considered to be a polynuclear cell it was soon shown, by the application of more refined staining technique, to have a single but irregularly lobed nucleus. While in some cells the lobes may be connected by relatively broad bridges, one may in other cells find them united by but a strand or thread of chromatin of extreme tenuity. So great is the variability in shape of the nuclei of the neutrophiles, that no single description is adequate. The normal blood contains chiefly cells with from three to five lobes to the nucleus, which may be curved into a horseshoe shape, or coiled into an S-shape, or overlying each other. There seems to be no definite nuclear membrane, but rather a peripheral basket-work of intensely basophilic chromatin strands connected with internal irregular masses and strands of similar material. These are separated by an achromatic or, more properly, "oxyphilic" chromatin material which may be stained by appropriate methods, so as to give a picture of the nucleus which is the negative of that obtained with the ordinary dyes. In the nucleus of younger cells the basophilic chromatin is more loosely woven than in the nuclei of older cells, where the strands are more compact and even more basophilic.

There is not entire agreement as to whether or not there be a nucleolus in the polymorphic nucleus. Naegeli (1923) is unable to stain one by any method. Brugsch and Schilling (1908) describe nucleoli in young leucocytes stained by the Giemsa stain. The author, using an iron hematoxylin stain on blood films, has stained spherical solid masses within the nuclei of young cells, that can be interpreted only as nucleoli. In the more compact older nuclei they are not distinguishable.

Knoll (1910) has emphasized the occurrence, on the nuclei, of certain prolongations of nuclear material into the protoplasm of the cell. These he describes as consisting chiefly of oxychromatin and as ending in a plasmasome which anchors the nucleus to the cell reticulum so that in motion the cell body and nucleus move as one. Further, the nucleus cannot be displaced within the cell by micro-dissection methods. Although one may not be inclined to accept Knoll's interpretation, it must be granted that the processes described may be seen upon the nuclei of many neutrophiles. They may be slender and of uniform diameter or they may be polypoid in shape. As Knoll has found them in fresh unstained human blood, they cannot be artefacts, yet they are not found on the nuclei of a sufficiently high proportion of a series of cells to establish for them the position of a necessary or constant nuclear organ. At the present time one should not be dogmatic in regard to them.

An extensive controversial literature has been written concerning the attempt of Arneth (1914) to establish a definite formula for the normal human blood on the basis of the number of lobes or parts to the nucleus of the neutrophilic cell and to interpret deviations from this formula in diseased conditions as of value in prognosis. This interpretaton is based on the assumption that as the neutrophilic leucocyte increases in age, its nucleus shows an increase in number of lobes, and apparently on a further assumption from the physiological standpoint that a young leucocyte is a more able defense agent than an older one. For the first assumption to be valid it would be necessary to prove that every leucocyte must pass successively through all intermediate stages from the single nucleus to the five-lobed state, and at the same rate of transition as every other leucocyte. Neither of these postulates has been proved to be a fact. On the contrary leucocytes with basophilic protoplasm, loosely woven nuclei and even with basophilic granules among the neutrophilic granules, and thus obviously young cells, may show as many lobes to the nucleus as cells evidently senile. The use of the classification for prognostic purposes in disease is complicated by the wide latitude of individual variation in deciding how slender the connection between nuclear parts must be to constitute them separate lobes. At the present time the author is not inclined to assign to the Arneth classification the importance claimed for it by its proponent.

Excessive lobation of the nucleus of the neutrophilic cell is found in some pathological states, especially in progressive pernicious anemia and at times in bone tumors (myeloma). One may find in these conditions seven, eight or even nine small lobes to the nucleus of the leucocyte, without evidence that the nuclear material exceeds that of a normal cell. The interpretation of this finding is not apparent.

4. *Cytoplasm:*

In the freely moving, living leucocyte examined on the warm stage, the protoplasm is seen to consist of a hyaline exoplasm which forms the advancing pseudopodium and into which there flows an endoplasm containing many fine, slightly refractile granules. There is evident no sharp line of demarcation between the two protoplasmic zones; yet it is to be noted that while the granules in the inner zone dance and shift their relative positions while the cell is in motion, individual granules do not escape into the hyaline zone any distance beyond their fellows. The granular endoplasm seems to flow into the pseudopodium en masse. This would seem to indicate a separation or difference in quality between the two layers. While there is no Brownian motion of the granules in the cell at rest, their shifting of position in the moving cell would suggest that the endoplasm is in a fluid state.

Aside from the granules in the protoplasm one may note in the living cell one or more vacuoles of varying size (Schultze). These vacuoles will "segregate" such a dye as neutral red, if it is used as a vital stain, and may show a neutral or an acid reaction with the dye. The vacuoles may be quite minute or may equal the nucleus in size, and Sabin considers their presence an indication of the functional phagocytic activity of the cell.

A centrosome with a surrounding halo or centrosphere may be stained in some neutrophilic leucocytes by the use of the iron hematoxylin stain. The centrosome may consist of a single intensely staining particle or of two granules. Schilling (1908) has studied the centrosphere in the living cell by use of dark field illumination, and finds what may also be brought out in stained cells—that it bears no definite relation to the nucleus but rather holds a central position in the cell protoplasm, which it maintains during the ameboid movements of the cell. It thus shifts its position in relation to the nucleus which appears to be dragged along in the outer part of the granuloplasm of the cell during locomotion. Schilling regards the centrosphere as the organ in which cell movement originates, and points out that it is lacking in certain non-motile, dead leucocytes found in the blood stream. The author has been unable to stain centrosomes in even a high proportion of all leucocytes in a given blood film. It hardly seems probable that this is always a result of accident in making the film whereby the centrosome comes to lie above or below the nucleus so as to be obscured, or of accidents of staining technique, as immediately adjacent cells may differ

as to the presence or absence of the body. It seems more probable that there is a gradual deterioration of the structure, as shown by Jordan for the neutrophile of the frog, with eventual disappearance. The centrosome stains much more intensely in young human neutrophiles than in older cells. Whether this loss of centrosome and centrosphere is connected with a loss of motility of the cell, as suggested by Schilling, or with loss of the power of reproduction must remain a question for the present. In topographical association with the centrosome is found a structure, which is but little known, called the Golgi apparatus (Cowdry, 1921).

The presence of mitochondria in the living neutrophilic leucocytes of man was first demonstrated by Cowdry (1914). They may be stained by Janus green or by diethylsafranin. They are larger than the specific granules and exist in the form of granules and rods but not as filaments. Sabin and her co-workers (1924) believe that, in the transformation of the myelocyte into the leucocyte, there is a gradual reduction in number of mitochondria as the specific granules increase in number, so that by the time the leucocyte becomes non-motile no mitochondrial substance is present. This raises the interesting and at present unsolved question as to whether the specific granulation may be a product of mitochondrial differentiation. In numerous cases of myelocytic (splenomyelogenous) leucemia the author has noted in the more primitive myelocytes, in blood films stained by Wright's stain, rod-like bodies taking the same stain as the granules. These rods generally showed an intensification of stain at intervals, with intervening, palely staining segments, suggesting strongly that the material of which they were composed was being segregated into granules. It is to be noted also that in broken leucocytes in a blood film, the specific granules appear in many cases to be associated in linear groups of two or three elements.

The specific granules of the special leucocyte were named E. (epsilon) or neutrophilic granules by Ehrlich, because, in his triple stain mixture, they stained with the resulting neutral dye and not with either the acid or basic dye present. In the various methylene blue-eosin mixtures, which have almost entirely superseded the Ehrlich stain, they react with the neutral dye by staining a purplish or lilac tint. The staining of the granules varies much in tone, however, depending apparently upon the age of the cell. In the young leucocyte, as in the myelocyte, the granules tend to react much more with the basic dye and take a deep bluish-purple stain, while in the old cells the granules stain more with the eosin component of the mixture and may be distinguishable at times from the true eosinophile granules only by size and refractility. At times this "ripening" process in the granules does not appear to take place uniformly, so that scattered basophilic granules may be seen among the neutral-staining majority. The granules may also be stained in the living cell by many of the so-called vital dyes,

among which neutral red has been most extensively used by those studying living cells, as it is apparently less toxic than many others. The granules are minute and appear practically uniform in size and quite evenly distributed throughout the endoplasm, except where the centrosphere is placed. They were considered by Ehrlich to be the specific secretion of the cell.

The neutrophilic leucocytes, in common with other cells of marrow origin, give a sharp oxydase reaction with a-naphthol and dimethyl-paraphenylendiamine, and it appears to be the specific granules which are stained by the resulting indophenol blue. They also give a peroxydase reaction with benzidine.

If a blood film is made and plunged immediately into an atmosphere of iodine the neutrophilic leucocytes show a definite iodophilia. The body of the cell shows the presence of numerous granules or masses of considerable size stained a dark brown by the iodine. These masses are scattered generally throughout the cell protoplasm. The iodine test was first applied by Ehrlich to air-dry films of blood, and in this state there was a diffuse browning of the neutrophiles' protoplasm in normal blood, but a reaction like that described for the living leucocyte, in certain pathological bloods, particularly in cases of suppurative infectious processes with neutrophilic leucocytosis. This granular, iodophilic reaction was first regarded as a degenerative process, and the stained material was considered to be glycogen. As the reaction occurs in normal living cells, it cannot be considered a degeneration. There has been considerable discussion as to the nature of the substance. It does not show the easy solubility of glycogen in water. Czerny and Zollikofer, because of staining reactions, considered the granules to be not glycogen but a precursor of amyloid. Neukirch, more recently, after checking the iodine-staining with Best's carmine stain for glycogen with special fixation, came to the conclusion that the material is either glycogen in loose combination within the cell or an allied insoluble form of carbohydrate. There the matter appears to rest.

Fat droplets appear in leucocytes in inflammatory exudates. Under the same septic conditions, leucocytes in the blood stream may show fat in the protoplasm. This is probably to be interpreted as the result of the action of toxins upon the circulating cells and not the re-entrance into the blood stream of leucocytes, injured in the inflammatory field.

Neusser's "perinuclear granules," sometimes obtained with the Ehrlich triple stain, have been dropped from consideration, as they have been shown to be artefacts due to the use of impure dyes. They do not appear in methylene blue-eosin preparations.

5. Motility:

The neutrophile is the most actively motile of all the circulatory leucocytes. On the warm stage, the projected pseudopodia are usually of a blunt,

rounded or tongue shape and consist primarily of hyaline ectoplasm, into which the endoplasm with its dancing granules seems to flow. In this movement the nucleus of the cell appears to be dragged along passively. The rate of locomotion of the neutrophile has been measured by McCutcheon (1923), who finds it to be 34.1μ per minute at 37°c. This figure exceeds that of Jolly (15.5μ) and that obtained by Comendon (25.2μ at 35°c.). Within certain limits, McCutcheon finds that with an increase of 10° in temperature the speed of progression is practically doubled.

Under some conditions, the neutrophile may put out filamentous pseudopodia, and may even put out such a number of these as to assume a "prickle-cell" appearance. These processes, which may be withdrawn, do not lead to locomotion, and are considered by Sabin to be a reaction to an unfavorable environment.

In its motion through blood vessel walls and into the tissues the leucocyte often becomes drawn out into an elongated, slender, almost thread-like cylinder. Its nucleus, however, does not seem to be as ductile as that of the lymphocyte, since in fixed tissues its lobes can still be detected. The emigration of the cell is said to occur under positive chemotaxis. The chemotactic substances are apparently many, but among the most powerful may be mentioned some undetermined substance which is possibly an alkaline albuminate present in necrotic cells and tissues. Its mode of action on the leucocyte is a problem for the physical chemist or the colloid chemist.

6. *Origin:*

It seems useless at this time to enter into the extensive literature concerning the origin of the neutrophilic leucocyte under normal conditions, as it is no longer a vexed question. There seems to be unanimous agreement that in the healthy state, the neutrophile arises within the bone marrow by a differentiation of neutrophilic myelocytes. During this process of differentiation, a non-motile cell becomes a motile cell, a spherical nucleus becomes a lobed nucleus, specific protoplasmic granules increase and mitochondria decrease, as emphasized by Sabin and her co-workers. The neutrophilic myelocytes can be separated into at least two general groups: a large primitive cell with vesicular nucleus and relatively few granules; and a somewhat smaller cell with more intensely staining nucleus and with an increased number of specific granules in the protoplasm. These lie in the intervascular spaces of the marrow. They appear to be massed in groups or leucogenic centers, and so arranged that the maturing cells come to lie at the periphery of the group and thus adjacent to the thin-walled venous sinuses (Bunting). The leucocytes enter the blood stream through their own active motion, but under what chemical or mechanical stimulus is not known. For the maintenance of a constant number of circulating cells, it would appear that a sufficient amount of leucogenic marrow is developed

so that the necessary number of cells may be supplied by mitosis in pre-existing neutrophilic myelocytes. Only when there is an excessive or pathological demand is this met by the formation of new centers by differentiation of the indifferent stem cell or myeloblast into granular myelocytes. The new tissue thus produced replaces the adipose tissue of the marrow.

Under various pathological conditions, foci of extramedullary leucocyte formation may be found. These may be of no physiological importance but only of scientific interest, as in those cases in which typical red marrow is found in the marrow cavities of metaplastic bone formation in the arteries or in other organs of the body. Similar marrow masses have been found in experimental bone production in the kidney of the rabbit after ligation of the renal vessels, as described by Maximow. We have been able to confirm this finding. These foci are probably best explained as the result of differentiation of primitive hematoblastic cells (the indifferent lymphoid cells of Maximow), under the influence of the bone environment. In leucemias, one may find not only multiplication of myelocytes filtered out of the blood stream in various organs, but also myeloid transformation of lymphoid structures, under the influence of the same stimulus which causes the excessive marrow proliferation.

7. Function:

At the present time, no essential function in the normal physiological existence of an individual can be assigned to the neutrophilic leucocyte, unless that of aiding defense against invading pathogenic organisms can be called physiological. It appears to be the cell in the first line of attack against invading living organisms of every type, whether they be of the group of the so-called pyogenic bacteria or the undetermined viruses of our acute exanthemata. Their method of attack is that of phagocytosis and intracelluar destruction of the organisms if they be successful in the combat. The neutrophiles are apparently not phagocytic while circulating in the blood stream but only after emigration from it or after being anchored within it, as in thrombus formation. The cell is also not equally effective against all types of organisms. For example, Medlar has recently shown it cannot deal successfully with the tubercle bacillus but quickly succumbs, contributing the main mass of the caseous material in a tubercle. Here the macrophage of Metchnikoff is the efficient agent, and even against the pyogenic cocci this latter cell appears in some cases to be more efficient than the leucocyte. The neutrophile cannot be a factor in antitoxic or bactericidal immunity, for since it is an end cell it has no progeny to which it can pass on an increased ability to destroy invading organisms.

A further function of the cell in pathological processes is that due to its possession of a proteolytic enzyme which was found by Opie to be most active in an alkaline medium. This is of importance in the digestion of nec-

rotic cells and tissues without the blood stream and also in the disappearance by autolysis of acute inflammatory exudates, as in lobar pneumonia, when the biological contest is over.

8. *Fate:*

Under normal conditions the neutrophile appears to pass its existence within the blood stream after it has entered it from the marrow. How long this existence is, is at present undetermined. In the making of a blood film one finds that there are fragile leucocytes which are easily broken. Schilling (1908) has called attention to the occurrence of non-motile granular leucocytes in the fresh blood when studied by dark field illumination. Sabin has emphasized their occurrence and their imperviousness to vital dyes. Sabin, Cunningham, Doan and Kindwall have followed in their counts the curve of these non-motile, dying leucocytes throughout the day and find that while at times they may be so few as to escape observation, yet there are periods in which they occur in definite showers. There may be two or three such showers fairly evenly spaced in the period of study (9 A.M. to 5 P.M.) and at the peak of these the non-motile cells may form from 25 to 36 per cent of the total number of leucocytes or from one-third to one-half of the total neutrophiles. Such curves would indicate the death of a considerable proportion of the neutrophile leucocytes during each twenty-four hours and their replacement by new living cells, and further indicate that the life of the neutrophile within the blood is measured by days and even almost by hours. The dead cells and fragments of them which remain unautolyzed would appear to be filtered out by the great blood filters, the spleen and liver, through the agency of their macrophages.

II. THE EOSINOPHILIC LEUCOCYTE

The coarsely granular, oxyphilic, acidophilic or eosinophilic leucocyte forms only from 2 to 4 per cent of the leucocytes in the circulating blood. This cell is practically of the same size as the neutrophile, varying between 10 and 12μ when "rounded up" in fresh blood films.

The nucleus of the eosinophile is a much simpler body than that of the neutrophile. It consists usually of two lobes connected by a slender bridge which is at times of almost filamentous tenuity. It may show three lobes, and in pathological bloods (pernicious anemia) in which the neutrophile shows excessive lobation, the eosinophile may exhibit a similar condition with many of the cells having nuclei with four and five lobes. The nucleus, however, does not become drawn out with the appearance of a thin twisted skein of material like that which occurs in the neutrophile. The lobes are plump and rounded.

With ordinary stains the nucleus of the eosinophile is also much less basophilic than is that of the neutrophile. A nucleolus is not brought out by ordinary staining, but may be seen by appropriate methods. While the nucleus is distinctive, it does not suggest as great deviation from the nuclei of other body cells as does that of the neutrophile.

The cell body shows a division into a hyaline ectoplasm and granular endoplasm when the cell is seen in the living moving state. It shows no vacuoles or "segregation apparatus," even when treated with vital dyes.

The most striking feature within the cell protoplasm is the presence of the large refractile granules of practically uniform diameter which crowd the cell body. The avidity of these granules for acid dyes makes the cell a brilliant object in stained blood films. The granules in the living cell also react more intensely with neutral red than do the neutrophile granules. The granules of the eosinophile of the horse, as studied by Petry (1908), are insoluble in fat solvents; they resist digestion by trypsin, and by autolytic enzymes; they are not soluble in dilute alkalies, but are soluble in concentrated alkalies and acids. Acetic acid dissolves them only upon heating. They do not give a xanthoproteic reaction. The granules in the horse were found by Petry to contain a high percentage of iron, confirming Barker's observation on the eosinophiles of human blood. Petry's conclusion is that the material of the granules is not identical with any of the typical cell proteids. The granules give the usual oxydase and peroxydase reactions.

While one seldom finds granules in the eosinophile of human blood that are not definitely acidophilic, Downey has shown that, in the guinea pig, the granules of the eosinophilic myelocytes are at first basophilic, and in the process of maturation of the cell these granules are transformed directly into the acidophilic granules of the mature leucocyte.

Aside from the characteristic and specific granules, Cowdry (1914) has succeeded with Janus green in staining a few granular and rod-like mitochondria in some eosinophiles. In others he was unable to find mitochondrial substance. Simpson (1921) finds them fewer and less easily observed in the eosinophile when compared to the neutrophile. These findings apparently coincide with Sabin's observations (1924) upon the disappearance of mitochondria in the maturation of the neutrophile cell.

In the fresh blood preparation on the warm stage, the eosinophilic cell shows definite ameboid motion. Rounded, blunt pseudopodia, consisting of hyaloplasm, are projected, and into these the dancing coarse granules seem to flow. Its locomotion appears somewhat less active and less direct than that of the neutrophile. Sabin, however, notes that she has observed them to move just as fast, but their motility is not as prolonged on the warm stage, seldom lasting over one-half hour.

The origin of the eosinophilic leucocyte and the nature of its contained granules have been subjects concerning which an extensive literature has

appeared during the past forty years. It seems unnecessary to discuss an early belief that the eosinophilic granules are a transformation of neutrophilic granules, for this view has been generally discarded. The eosinophiles, like the neutrophiles and the basophiles, are a distinct cell race with distinctive cell characters, aside from the specific granules. This was the original view of Ehrlich, who regarded the eosinophilic granules as an endogenous specific product of cell metabolism. In view of all the evidence there seems no reason for not accepting this view. In the opinion of the author the eosinophiles of the blood and those found in the tissues in pathological reactions are derived from the eosinophilic myelocytes of the bone marrow. These myelocytes may be produced either by mitotic division in parent eosinophilic myelocytes, or by the differentiation of granules in myeloblasts under proper stimulus.

The chief opponent of the Ehrlich view has been Weidenreich (1908, 1910) who maintains that the granules in the eosinophiles of all mammals are derived exogenously from hemoglobin. According to his view, either red blood cells, or their fragments, or hemoglobin are taken up by lymphocytes in lymphoid tissue or in the tissues generally, and these cells become eosinophiles through an appropriate change in the character of their nuclei. This view is apparently based upon a primary false assumption that all eosin-staining granules in cells are of the same nature. There seems to be also a confusion of a definite pathological process with the development of a normal race of cells. The author has observed in lymph nodes, through which lymph from areas of hemorrhage was draining, certain changes in plasma cells, which may be at the bottom of this view of Weidenreich's. All steps of the process were noted, from the absorption of a material, apparently hemoglobin, which gave to the protoplasm of the cell a diffuse, brilliant purple color in hematoxylin and eosin stains, through a stage in which this material was apparently condensed into brilliantly eosin-staining granules, to a stage in which these granules became swollen into large myelin-like droplets exceeding the nucleus in size. Throughout these changes, the nuclei remained of the plasma cell type. This is the only change in character the author has ever noted in plasma cells in chronic inflammatory tissue, where it is not infrequently seen. Its interpretation is not clear. When true eosinophiles are present in the same tissues, a possible relationship between them and the granular stage of this process in the plasma cells might easily be assumed.

The very unusual reactions of the eosinophilic granules as noted, and also their development from granules which primarily are basophilic in reaction both speak for an endogenous formation. The relation found experimentally by Opie and others between local eosinophilia, blood eosinophilia and increased development of marrow eosinophilic tissue, is evidence both of an independent race of cells, and of marrow rather than local origin

for them. In their reaction, when there is tissue demand for them, the eosinophiles follow the same curve as do the neutrophiles under similar conditions. When demand exceeds supply, there is a diminution in the number of circulating eosinophiles. With compensation by increase of tissue in the marrow, the number of cells in the circulation increases and with the usual reaction in excess, goes on to a definite eosinophilia.

The function of the eosinophilic leucocyte is still somewhat uncertain. It is not ordinarily a phagocytic cell for bacteria or cell products. At times, however, bacteria may be stained in them. Foster notes that the eosinophiles of the guinea pig are phagocytic for diphtheria bacilli. The pathological conditions under which a blood eosinophilia and a tissue invasion occur are rather varied and are not easily interpreted from the standpoint of function. Aside from the increase in such hyperplastic conditions of the marrow as myelocytic leucemia and polycythaemia vera, irritations and inflammations of the skin of almost any grade or type, and the presence of animal parasites, particularly of the verminous group, appear productive of the sharpest reaction on the part of the cell. They are increased in bronchial asthma. In many acute infectious diseases, after an early diminution in number, they show an increase in convalescence. The author has been convinced from pathological studies that the products of destruction of lymphocytes are specifically chemotactic for eosinophiles, accounting for their accumulation in the lymph nodes in Hodgkin's disease and in the periphery of cancerous growths. This may be but a single example of the general type of reaction emphasized by Schlecht as a result of experimental work. His conclusion is that eosinophilia is the expression of a reaction of the body against toxic products resulting from the injection of foreign proteins and also from the decomposition of native proteins. Injection of proteins, and of peptones, but not of amino acids, will give the reaction. Animals in the hypersensitive state, which survive anaphylactic shock, will show an eosinophilia. The eosinophilia of bronchial asthma is to be interpreted as of this group of reactions. How the eosinophiles react under these conditions is undetermined. Even when the cell shows such toxic injury as to lead to nuclear fragmentation, the granules appear unchanged. Eosinophiles in the peripheral sinuses of bronchial lymph nodes in a case of bronchial asthma appear entirely unchanged from those in the blood stream except possibly for slight imbibition of serum by some cells. The granules are evidently not liberated from the cells in pathological reactions until the cell undergoes autolysis.

As the result of his chemical study Petry (1908) is of the opinion that the eosinophile is concerned in the metabolism of iron in the body. While there are many breaks in our knowledge concerning the manner in which the physiological decomposition of hemoglobin in the body is accomplished, the pigment part of the molecule excreted and the iron conserved for future

use in reconstruction of hemoglobin, there is at present not sufficient evidence to connect the eosinophile directly with the process.

Eosinophiles appear to leave the blood stream in supposedly healthy individuals in greater numbers than do the neutrophiles. At least, they appear to be of normal occurrence in the gastrointestinal mucosa where there is no demonstrable pathological lesion. Schlecht's observations might suggest that here they were playing a detoxifying rôle against toxic substances absorbed from the lumen.

Within the blood stream Sabin, Cunningham, Doan and Kindwall (1925) report an hourly rhythm of the cells comparable to that of the neutrophiles but of much less magnitude. An occasional non-motile cell with coarse granules may be observed but not in such showers as they describe for the neutrophiles. Further observations as to these phenomena are needed.

The function or functions of the cell and its exact life history must be left as matters of some uncertainty at the present time.

III. THE BASOPHILIC LEUCOCYTE

The basophilic leucocyte, or hematogenous mast cell or mast leucocyte forms from but 0.4 to 0.6 per cent of the circulating leucocytes in man. One might consider this almost an accidental invasion of the blood stream by the cell were it not for the fact that even so small a percentage means that approximately 200,000,000 such cells are constantly present in the whole circulation. The average basophile is smaller than the neutrophilic leucocyte, since its diameter is from 8 to 10μ. An occasional cell may exceed these measurements.

The nucleus of the basophile is more centrally placed than in the neutrophile or eosinophile and seems to constitute a larger proportion of the cell mass. It is polymorphous in shape, but much more irregularly lobed than in the neutrophilic cell. The lobes are not commonly spread apart but folded in upon each other so that, in the stained cell, where the rather pale nucleus is obscured to some extent by the intensely staining specific granules, the nucleus may appear to be spherical. In myelocytic leucemia, in which more basophiles are found in the circulation than in any other condition and thus can be best studied, cells with three plump lobes to the nucleus appear to be most common. One is not certain, of course, in this condition that he is not dealing with a pathological cell. The nuclear chromatin is not strongly basophilic, and the nucleus takes a pale strain in the methylene blue-eosin mixtures commonly used for blood films. Nucleoli may be made out by appropriate stains.

The most distinctive feature of the cell protoplasm is the presence in it of many relatively large, slightly refractile granules. In the cells vitally

stained by neutral red, Sabin notes that the granules take the stain more intensely than do those of either the neutrophile or eosinophile. She also describes them as spherical, varying in size and intermediate in diameter between the neutrophilic and eosinophilic granules. In the fixed blood film stained by methylene blue-eosin mixtures, the metachromatic, deep purplish-blue granules show a variation in size, and the larger ones appear to exceed the size of the granules of the eosinophile. This may be but the result of a difference in consistence which allows them to be more spread out in the making of the film. The tendency of some granules to be oval and not round may be explained in the same way. With the Ehrlich triple stain one obtains a negative picture of the granules, the cell appearing as if the seat of many minute vacuoles. In the methylene blue-eosin mixtures the stain is intense, as stated. The granules give an oxydase reaction. They are easily soluble in water and thus do not appear in tissues fixed in aqueous solutions of the coagulants commonly used. This accounts in part for our very slight knowledge as to the part played by the cell in pathological processes.

Centrosomes have been stained in the basophiles by Naegeli, and by Weidenreich. On account of technical difficulties, Cowdry (1914) was unable to determine the presence or absence of mitochondrial substance in the cell. Sabin makes no note on the subject. Simpson (1921) finds relatively few mitchondria in the basophiles of the rabbit's blood.

Ehrlich considered the basophiles as cells of a distinct group of granular cells in which the granules were a characteristic product of cell secretion or metabolism, and considered them to be of marrow origin. This is the view also of Naegeli, Maximow, Downey, Ringoen, Michels, Sabin, and others, including the author, who have given the subject earnest consideration. The cells may arise by mitosis of basophilic myelocytes or by differentiation of myeloblasts into basophilic myelocytes. The name "mast leucocyte" was given to the cell because the hematogenous cell was supposed to be identical with the mast cell of the tissues. There is, however, no identity between the two, and there appears in general a reciprocal relation in the vertebrate series of animals between the number of tissue and blood mast cells. Those animals with a large number of tissue mast cells have few in the circulating blood, and the contrary is also true.

An attack upon the independent nature of the blood basophile in man was made by Pappenheim (1904, 1908), followed by Weidenreich (1908, 1910). In their opinion the cells represent not a true cell race but are merely lymphoid elements in a state of degeneration, the specific granules being but mucoid degenerative products. The view is untenable. A cell which is present not only in the blood of the vertebrate series but also in invertebrates can hardly be an accident of the circulation. A cell which is produced in proportionate numbers with neutrophiles and eosinophiles in such hyper-

plasias as those in chronic marrow leucemia and in polycythaemia vera must stand on the same footing as the other two cells. Also Sabin has shown that in vitally stained films the cell is alive and shows active ameboid motion. As negative evidence, one does not find such a type of degeneration in lymphoid cells in pathological processes.

There is at present no satisfactory knowledge as to the function of the cell. Aside from the increase of the basophiles in the blood in myelocytic leucemia and polycythemia, the author has found them increased in early Hodgkin's disease, chronic inflammation of the accessory nasal sinuses and in smallpox and chickenpox. They are found in smears from the lymph nodes of patients with Hodgkin's disease, and with eosinophiles, neutrophiles and other blood cells they are present in smallpox pustules. Schlecht (1912) has found that experimentally they react with the eosinophiles in injections of foreign proteins into the tissues of animals, but somewhat less regularly. In the pathological conditions just mentioned there is also an excessive eosinophile reaction—therefore, if the latter cell has a detoxifying function as claimed by Petry and by Pröscher, the basophile may share in the same process.

IV. THE BLOOD PLATELETS

The blood platelets, blood plaques, thrombocytes, elementary corpuscles of Zimmerman, "haematoblasts" of Hayem (1878), "third corpuscle" of Osler were observed by many investigators during the early part of the last century.

These workers, however, generally failed to realize the significance of their observations. Zimmerman refers to observations by Gerber, Arnold, Donné, Andral and Simon. Zimmerman himself, in 1860, considered them to be elementary bodies or corpuscles from which the red blood cells were developed. In 1865 Max Schultze described certain granular masses in the blood, and in 1874 Osler resolved these into distinct, small corpuscular elements which he found existed as such and not in mass form in the blood vessels of the new-born rat. In 1878 Hayem investigated them in the blood of man and animals, and named them "haematoblasts," as his view, like that of Zimmerman, was that they developed into red blood cells. In 1882 Bizzozero in an exhaustive study found the platelets pre-formed in the blood vessels of living animals, demonstrated their adhesive quality, by which they stick to foreign bodies in the circulation and to injured vessel walls, becoming the primary elements in the thrombi, and showed that they played an important part in the coagulation of the blood. Not until 1906, in Wright's publication concerning the origin of the platelets, is there a further striking contribution to our knowledge of these structures.

1. *Character:*

The blood platelets appear as small round or oval disk-like bodies, commonly about half the diameter of a red blood cell, that is to say, from 2 to 4μ in diameter. Unstained in fresh blood or in a conserving fluid they appear

as slightly refractile, shadowy or grayish bodies. Deetjen notes that they have a greenish, more refractile center, which he considers a nucleus. In a fresh blood preparation they cohere when in contact with each other and rapidly disintegrate, forming granular masses.

When stained in blood film by Giemsa or Wright stain, the platelet has a peripheral, pale blue, sharply contoured hyaloplasm, with an irregular central clump of azure granules. There is no definite arrangement of these granules and no surrounding membrane suggesting a nuclear membrane. Deetjen's conception of the platelet as a true nucleated cell has not been widely accepted. The granules stain with neutral red in "vital" preparations. The platelet shows also, when stained by Janus green, the presence of mitochondrial rods and granules, as demonstrated by Cowdry, Sabin and others. When a blood film is exposed to an iodine vapor immediately after it is made and before it is dry, relatively large, spherical, dark mahogany-colored masses appear on or in many of the platelets. It is difficult to determine the exact relationship of the mass to the platelet body. Naegeli considers it an extracellular reaction. The exact nature of the substance has not been determined, but it appears probable that it is glycogen or a related substance.

Deetjen (1901) has shown that on a film of agar-agar containing acid potassium phosphate the blood platelets project pseudopodial processes which may be rounded, but are more commonly slender and pointed. These pseudopodia may be projected and withdrawn, giving rapid changes of shape to the platelet. He also claims that by the means of these processes the platelet is capable of actual ameboid locomotion. While the extension of pseudopodia under these conditions has been abundantly confirmed, Deetjen's conclusion of true locomotion has not been readily accepted. Emerson was unable to confirm it.

2. *Distribution and number:*

Blood platelets appear to be confined to the blood stream. Jordan (1918) was unable to find them in the lymph of the thoracic duct in animals. Their number was determined by Hayem as lying between 200,000 and 300,000 per cubic millimeter in the normal individual. This is the approximate range accepted for health as the result of the work of many subsequent investigators both by indirect methods of counting and by the direct method with a variety of fluids. Exact counts are difficult owing to the small size of the platelets, their tendency to cohere and adhere, and to their rapid disintegration in shed blood. Constancy or variability in this normal number in an individual has not been sufficiently investigated. Hayem found a definite increase in number after meals.

Under pathological conditions there is great variation in the number of circulating platelets, and one may also find abnormal forms. In pernicious

anemia and in hemorrhagic purpura there is a marked diminution in the number of the platelets, at times even to a point of fewer than 10,000 per cubic millimeter or almost to the vanishing point. In chlorosis, most secondary anemias, chronic diseases, such as tuberculosis, Hodgkin's disease, and myelocytic leucemia, they are commonly increased. The author has found over 1,000,000 per cubic millimeter in Hodgkin's disease. Buckman and Hallisey (1921) report 1,316,000 in myelogenous leucemia. The abnormal forms are varied. One may find large, oval platelets with the long diameter exceeding that of a red blood cell, or slender, elongated masses of normal platelet diameter but at times of 50μ length, or even irregular, large

FIG. 186.—Photomicrograph of the pseudopodium of a megalocaryocyte in a human blood film (about 1500 diameters).

masses several times the area of a red cell. All these show the same staining reaction as the normal platelet but usually without the clumping of the azurophile granules seen in that body. The author has seen these abnormal platelets most commonly in Hodgkin's disease, but they may occur under other conditions.

Attention has been called by the author to the finding that pseudo-platelets or platelet-like bodies may be pinched off from pseudopodia projected from the bodies of large lymphoid cells in such diseases as influenza where there is a reduction in the number of circulating true platelets. Smith (L. W.) has noted them also from the same type of cell in a case of acute leucemia in an infant. They may be observed in other condi-

tions, and are distinguished with difficulty from true platelets. The azurophilic granules of the lymphoid cells are coarser than those of the platelet and do not form such definite clumps in the false platelet forms.

3. *Origin:*

The origin and the nature of the platelets have been subjects for much discussion and speculation since their discovery. They have been regarded as the formative elements from which red cells arose (hematoblasts), as independent cellular elements or blood corpuscles, as fragments of red cells, as extruded nuclei of red cells, as fragments of leucocytes and as protein precipitate. In 1906, Wright showed conclusively, it appears to the author, by means of a special staining method, that the platelets were constricted portions from pseudopodial processes, thrown out by the megalocaryocytic giant cells of the bone marrow. These pseudopodia are projected into the venous sinuses of the marrow and here the clumping of granules and segmentation into platelets take place. Unsegmented pseudopodia and protoplasmic masses from the giant cells may be shed into the blood stream, accounting for the abnormal forms of platelets described as occurring in the peripheral blood.

These observations of Wright's have been confirmed by many investigators and in a variety of ways. Many have succeeded, by using Wright's stain and other methods (Downey), in confirming the apparent identity of the granules in megalocaryocyte and in platelet. Some have failed. Petri, the most recent objector to the theory, is not only unable to use the stain successfully but is also unable to find any connection between platelet production and megalocaryocytic activity, as claimed by Bunting, in experimental anemias in the rabbit due to hemorrhage and saponin toxemia. The demonstration of mitochondria in platelets is clear evidence that they are protoplasmic fragments. Stahl, Horstmann and Hilsnitz (1925) have found in megalocaryocytes iodophilic masses identical in size and shape with those stained in peripheral platelets, and unlike the masses in other blood cells. Unsegmented pseudopodia and protoplasmic masses of megalocaryocyte type in the blood stream offer further evidence. In stained blood films from cases of myelocytic leucemia, Minot (1922) has observed megalocaryocytes in the segmenting condition, and Sabin in vital films from the blood in the same disease, has seen segmentation take place in the giant cells. These findings seem conclusive when taken with the relationship between the number of platelets and megalocaryocytes in the marrow in certain pathological conditions. In pernicious anemia there is a great scarcity of giant cells in the marrow and a great deficiency of platelets in the circulation. The same finding occurs in acute marrow (myeloblastic) leucemia. In chronic myelocytic leucemia the reverse occurs, many giant cells, many platelets. A similar condition is found in the recovery from a

secondary anemia. Wright has also emphasized that blood platelets do not appear in the embryo until after megalocaryocytes are seen. There seems no real reason to the author for not accepting Wright's theory as a fact.

4. *Function:*

Unless the platelet be the source of prothrombin in the normal plasma, the platelets would seem to function only in pathological conditions. As emphasized by Bizzozero (1882) one function depends upon the cohesive and adhesive quality of the strucures as a result of which they stick to foreign bodies in the circulation, and to rough spots and wounds in the walls of blood vessels and thus become the foundation element in thrombus formation. This is a matter of general acceptance among pathologists at the present time. Thrombosis is not common in diseases in which circulating platelets are few. A great reduction in platelets is apparently the important factor in the prolonged "bleeding time" seen in purpura haemorrhagica, as platelets are lacking to form protective thrombi in the injuries of the vessels.

A second function of the platelets as observed by Bizzozero is concerned with the clotting of the blood. Morphologically, in a blood clot, the strands of fibrin radiate from granular clumps of disintegrating platelets. According to Howell's theory (1924) there is required, before the blood can clot, a neutralization or inhibition of the antiprothrombin (heparin) of the plasma. This may be supplied by disintegrating tissue cells or leucocytes, but is ordinarily furnished by the platelets which disintegrate so much more rapidly than the other cellular elements of the blood. This substance is cephalin, or a substance allied to it. In such a pathological condition as hemophilia, where a much delayed coagulation of the blood occurs with practically a normal platelet count, one must postulate a pathological quality in the platelets. In the opinion of Howell (personal communication) in hemophilia the changed quality leads to a slowness of disintegration and therefore to a delay in liberation of the activating or neutralizing substance.

V. THE MEGALOCARYOCYTE

The megalocaryocyte is a cell that may attain a diameter of 40μ in fixed tissues. It has abundant granular protoplasm and an irregularly lobed ring or doughnut-shaped nucleus. This is composed apparently of a multitude of vesicular nuclei, with definite nucleoli, joined to each other. The giant cells are ordinarily widely scattered throughout the marrow and do not occur in compact masses so as to form a tissue or even centers. This would seem an argument in favor of the development of each giant cell by differentiation and growth of mononuclear cells or myeloblasts. To support this view, there are found many small megalocaryocytes in the

marrow with nuclei of much less complexity than in the large mature cells. One may even find them with but two lobes. Mitotic figures may be found in large megalocaryocytes. In the rabbit they are multipolar and suggest in this feature mitoses in giant cells of malignant tumors. The cells do not appear to divide with these mitoses and the conclusion is suggested that the process leads to an increased complexity of the nucleus—as in the tumor giant cells.

The granules of the protoplasm vary somewhat in distribution in cells of different ages or of different stages of activity. The granules become, in development of the cell, quite evenly distributed throughout the protoplasm except for a narrow peripheral rim. With the beginning of platelet formation the granules become grouped or clumped in small masses. A pseudopodium may be observed, however, with a central, evenly spaced stream of granules. Downey (1913) is convinced by his observations that the granules are of nuclear rather than protoplasmic origin and that they change their staining characteristics while within the protoplasm. Evidence of platelet activity of the marrow is gained not alone from the number of the giant cells but from their character. With marked activity the giant cells lose the major part of their protoplasm and become reduced to a deeply staining, pycnotic nucleus with but a scant rim of protoplasm. Whether these cells are able to regenerate new protoplasm or whether they disintegrate is not clear. The character of the nucleus would suggest that they were in a degenerative state.

In addition to specific granules the megalocaryocytes contain abundant mitochondria. According to Jordan (1921) they may be either of the bacillary organular type, the latter predominating in the older cells and a skein-like Golgi apparatus, located near the centrosomes, has also been demonstrated by Jordan. This structure fragments and disappears in the older giant cells.

Wright has shown that the megalocaryocyte is ameboid. The cell does not remain fixed in the bone marrow but leaves it under a variety of circumstances. Apparently in every case of high leucocytosis giant cells get into the circulation. Ordinarily they do not get into the peripheral blood stream as their size is such that they become lodged in the lung capillaries. Their occurrence in the lung capillaries in fatal cases of pneumonia is a matter of common observation. Their number is even greater in the lungs of fatal cases of Hodgkin's disease, where there has been a protracted leucocytosis. In chronic myelogenous (myelocytic) leucemia, Minot has observed them in the peripheral blood in 35 of 45 cases. Their number may be very great, even as high as 8 per cent of counts between 50,000 and 150,000 white cells. In leucemia there appears to be a plethora which results in dilatation of the capillary beds in such organs as liver and lung and thus the latter's capillaries permit of easy passage of the giant cells.

VI. BIBLIOGRAPHY

Arneth. 1914. Die neutrophilen Leukocyten bei Infektions Krankheiten. *Deutsch. Med. Woch.*, **30**, 54.

Barker, L. F. 1894. On the presence of iron in the granules of the eosinophilic leukocyte. *Johns Hopkins Hospital Bull.*, **5**, 93.

Bizzozero. 1882. Ueber ein neuen Formbestandtheil des Blutes und den Rolle bei der Thrombose und der Blutgerinnung. *Virchow's Archiv*, **90**, 261.

Brugsch and Schilling. 1908. Die Kernform der lebenden neutrophilen Leukocyten beim Menschen. *Folia Haemat.*, **6**, 327.

Buckman and Hallisey. 1921. Studies in the property of blood platelets. *J. Am. Med. Ass.*, **76**, 427.

Bunting, C. H. 1906. Experimental anaemias in the rabbit. *J. Exper. Med.*, **8**, 625.

——— 1906. The formation of true bone with cellular (red) marrow in a sclerotic aorta. *Ibid.*, **8**, 365.

——— 1909. Blood platelet and megalokaryocyte reactions in the rabbit. *Ibid.*, **11**, 541.

——— 1911. Blood platelets and megalokaryocytes in Hodgkin's Disease. *Johns Hopkins Hospital Bull.*, **22**, 114.

——— 1920. Vicarious blood-platelet formation. *Ibid.*, **31**, 439.

——— 1922. The leukocytes. *Physiol. Rev.*, **2**, 505.

Bunting, C. H., and Thewlis, Ethel. 1926. Leukocytic reactions in smallpox, chickenpox, scarlet fever, measles and mumps. *Arch. of Path.*, **1**, 189.

Cowdry, E. V. 1914. The vital staining of mitochondria with janus green and diethylsafranin in human blood cells. *Internat. Monatsschr. f. Anat. u. Physiol.*, **31**, 267.

——— 1921. The reticular material of developing blood cells. *J. Exper. M.*, **33**, 1.

Deetjen. 1901. Untersuchungen ueber die Blutplättchen. *Virchow's Archiv*, 239.

Downey, Hal. 1913. The origin of blood platelets. *Folia Haemat.*, **15**, 25.

——— 1915. The origin and development of eosinophilic leukocytes and of haematogenous mast cells in the bone-marrow of the adult guinea pig. *Ibid.*, **19**, 148.

Emerson. 1908. *Clinical diagnosis*. Ed. 2, Philadelphia.

Foster. 1908. A study of the eosinophile cells as occurring in the haematopoietic organs as occurring in diphtheria and tuberculosis. *J. Med. Research*, **19**, 83.

Hayem. 1878. Recherches sur l'évolution des haematies dans le sang de l'homme et des vertèbres. *Arch. de Physiol.*, **5**, 692.

Howell, W. H. 1924. *A text book of physiology*. Ed. 9, Philadelphia.

Jones, T. Wharton. 1846. The blood corpuscle considered in its different phases of development in the animal series. *Philosophical Transactions*, 63.

Jordan, H. E. 1918. The histology of lymph with special reference to platelets. *Anat. Record*, **15**, 37.

——— 1919. The histology of the blood and the red bone marrow of the leopard frog. *Am. Journ. Anat.*, **25**, 437.

——— 1921. Mitochondria and Golgi apparatus of the giant-cells of the bone marrow. *Am. Journ. Anat.*, **29**, 117.

Knoll. 1910. Ein Beitrag zur Morphologie u. Physiologie der polymorphen Leukocyten. *Zeitschr. f. wiss. Zool.*, **95**, 121.

McCutcheon. 1923. Studies on the locomotion of leukocytes. *Am. J. Physiol.*, **64**, 180.

Maximow, A. 1907. Experimentelle Untersuchungen zur post foetal Histogenesis des myeloid Gewebes. *Zeigler's Beitrage*, **41**, 122.

——— 1913. Ueber Blutmastzellen. *Arch. f. Mikr. Anat.*, **73**, 247.

Michels. 1923. The mast cell in the lower vertebrates. *La Cellule*, **33**, 339.

Minot, G. R. 1922. Megacaryocytes in the peripheral circulation. *J. Exper. Med.*, 36, 1.

Naegeli. 1923. *Blutkrankheiten und Blut Diagnostik.* Ed. 4, Berlin.

Neukirch. 1910. Ueber die jodophile Substanz der Leukocyten u.s.w. *Zeitschr. f. Klin. Med.*, **70**, 251.

Opie, E. L. 1904*a*. An experimental study of the relation of cells with eosinophile granulation to infection with an animal parasite (Trichina spiralis). *Am. J. Med. Sci.*, **127**, 477.

— — 1904*b*. The relation of cells with eosinophile granulation to bacterial infection. *Ibid.*, **126**, 988.

——— 1906. The enzymes in phagocytic cells of inflammatory exudates. *J. Exper. Med.*, **8**, 410.

Pappenheim. 1904. Zusatz zu der Mittheilung von Pröscher ueber experimentelle Leukocytosen. *Folia Haemat.*, **1**, 686.

——— 1908. Ueber Mastzellen. *Ibid.*, **5**, 156.

Petri. 1925. Investigations concerning the origin of the blood platelets. *Acta Path. et Microbiol. Scandinavica*, **2**, 23, 9+, 2++.

Petry. 1908. Zur Chemie der zell granula. *Weiner Klin. Woch.*, 1360. *Muench. Med. Woch.*, 1912, **59**, 1892.

Ringoen. 1921. The origin of the eosinophilic leucocytes of mammals. *Folia Haemat.*, **27**, 10.

——— 1923. The mast leucocytes in the adult guinea pig under experimental conditions. *Am. J. Anat.*, **31**, 319.

Sabin, F. R. 1923. Studies of living human blood cells. *Johns Hopkins Hospital Bull.*, **34**, 277.

Sabin, F. R., Austrian, Cunningham and Doan. 1924. Studies on the maturation of myeloblasts into myelocytes and on amitotic cell division in the peripheral blood in subacute myeloblastic leucemia. *J. Exper. Med.*, **40**, 845.

Sabin, F. R., Cunningham, R. S., Doan and Kindwall. 1925. The normal rhythm of the white blood cells. *Johns Hopkins Hospital Bull.*, **37**, 14.

Schilling. 1908. Lebende weisse Blutkörperchen im Dunkelfeld. *Folia Haemat.*, 6, 429.

Schlecht. 1912. Ueber experimentelle Eosinophilie. *Arch. f. Exper. Path. u. Pharm.*, 108, 405.

Schultze, Max. 1865. Ein heizbares Objecttisch u. seine Verwendung bei Untersuchungen des Blutes. *Arch. f. Mikr. Anat.*, **1**, 1.

Simpson. 1921. Vital staining of human blood with special reference to the separation of the monocytes. *Univ. of California Publications in Anatomy*, **1**, 1.

Smith. 1921. A case of acute leukaemia in an infant. *Am. J. Dis. of Children*, **21**, 163.

Stahl, Horstmann and Hilsnitz. 1925. Untersuchungen mittels der vitale Jodfixation am Stromenden Blute und am Knochenmark. *Virchow's Archiv*, **257**, 392.

Weidenreich. 1908. Zur Kentniss der Zellen mit basophilen Granulationen im Blut und Bindegewebe. *Folia Haemat.*, **5**, 135.

——— 1910. Die Morphologie der Blutzellen und ihre Beziehungen zur einander. *Anat. Record*, **4**, 317.

Wright, J. H. 1906. Die Entstehung der Blutplättchen. *Virchow's Archiv*, **184**, 55. *Boston Med. & Surg. J.*, **154**, 643.

——— 1910. The histogenesis of the blood plates. *J. Morph.*, **21**.

Section XIV

THE MACROPHAGES OR HISTIOCYTES

CONTENTS

Section XIV

PAGE

I. Introduction 427
II. Histiocytes of Common Connective Tissue. 429
III. Histiocytes of Omentum 436
IV. Histiocytes of Lymphoid Tissue. 442
V. Histiocytes of Myeloid Tissue. 450
VI. Histiocytes of Red Pulp of Spleen. 451
VII. Histiocytes of Liver Sinusoids 452
VIII. Differences between Histiocytes in Various Organs of Body . . 455
IX. Free Histiocytes of Blood. 455
X. Monocytes in Their Relation to Histiocytes 458
XI. Embryonic Development of Histiocytes and Monocytes 463
XII. Genetic Relationships between Histiocytes and Other Elements of Connective Tissue and Blood and Their Prospective Potencies . . 470
XIII. Histiocytes in Lower Vertebrates 474
XIV. Functional Properties of Histiocytes 474
XV. Bibliography 476

Section XIV

THE MACROPHAGES OR HISTIOCYTES

ALEXANDER A. MAXIMOW

1. INTRODUCTION

METSCHNIKOFF discovered (1892, 1901, 1905) peculiar large fixed and motile cells in the connective tissue of the Metazoa, which, together with the blood leucocytes, play an important rôle in the defense reactions of the organism, especially in inflammation. They phagocytize certain pathogenic microorganisms, dead cell remnants, etc., and are supposed to secrete various soluble substances, as, for instance, enzymes. Whereas the common special granular leucocytes (the neutrophiles) were called microphages by Metschnikoff, the phagocytic cells of the connective tissue received from him the name of "macrophages."

Ranvier was the first to give a histological description of the macrophages in the omentum of mammals (1890,1900); he designated them "clasmatocytes." Marchand identified them with his "adventitial cells," which he also studied in the omentum (1898, 1902). Maximow (1902, 1906*b*) found them to be a regular constituent of ubiquitous diffuse, irregularly arranged connective tissue in the mammals. He gave a detailed histological description and termed them "resting wandering cells."

Previous to the investigations just mentioned, the cells in question usually were not distinguished from the fibroblasts, because the common nuclear dyes do not clearly demonstrate their characteristic features. They have been confused with mast cells by some authors, as was the case with Ranvier in his study of these cells in the urodele amphibians. The modern vital and supravital staining methods and perfect fixation methods make the identification of these cells very easy.

The experimental work of Goldmann (1909, 1911, 1912, 1913), Tschaschin (1913) and Kiyono (1914), who used the new method of vital staining of the organism, brought about an extension of the conception of the resting wandering cells.

Goldmann used for his investigations pyrrhol blue and isamin blue—acid aniline dyes. When their colloidal solutions are introduced intravenously, intraperitoneally or subcutaneously into the animal body, an elective accumulation of dye particles is observed not only in the resting wandering cells of the common diffuse connective tissue, but also in other elements distributed all over the body. According to the quantity of the respective cells in the various tissues, the latter show at autopsy, in sufficiently stained animals, a lighter or darker color. Exclusive of the renal

tissue, the color of which is mostly due to the accumulation of the dye in the epithelium, the most intense coloration is always shown by the spleen, the liver, the lymph nodes and the bone marrow.

In all these tissues the ability of certain cells to store colloidal dyes appears combined with their tendency to become mobilized, to transform themselves into free ameboid cells, giant cells, epithelioid cells, etc., and to phagocytize.

Goldmann was the first to express the idea that the resting wandering cells of the loose connective tissue belong to a great cell group distributed all over the body in various organs. He believed that these resting wandering cells appear in various forms and play an important rôle in the general metabolism. Tschaschin (1913) and Kiyono (1914) developed this line of thought further. The former used colloidal silver—collargol—in addition to isamin and pyrrhol blue to secure vital staining. The latter worked with lithium carmine, the properties of which as a vital stain were pointed out by Ribbert in 1904. Kiyono (1914) proposed for the elements storing vital dyes the term "histiocytes."

While studying the metabolism of cholesterol, Landau and McNee (1914) also came to the conclusion that there is in the organism a peculiar "reticulo-endothelial metabolic apparatus," intimately connected with this function. As it became known later, this cell apparatus is a part of the cell system which becomes manifest in vitally stained animals.

From the investigations just mentioned, and many others which followed them closely, originated the theory of the "reticulo-endothelium" or the system of the "histiocytes." It has already an extensive bibliography and has been discussed in several critical reviews (R. H. Jaffé, 1922; Aschoff, 1924, 1925; Oberling, 1924; Boerner-Patzelt, 1925; Schittenhelm, 1925; Sacks, 1926, and others).

The term "reticulo-endothelium" is not suitable, as the true endothelium of the common blood vessels is quite different from the histiocytes and also from the so-called reticular cells. The term "histiocytes" means merely "tissue cells" and has been chosen by Kiyono apparently because this author was convinced that these elements are genetically sharply separated from the blood leucocytes and especially from the lymphocytes. This hypothesis proved to be wrong, as Kiyono and Nakanoin (1919) themselves admitted later. In the meantime, however, the term "histiocytes" became generally accepted.

The decision as to whether or not a connective tissue cell belongs to the system of histiocytes is usually taken at the present time on the basis of the positive behavior of the cell towards vital staining with colloidal dyes. The supravital reaction to neutral red is also a reliable criterion (Maximow, 1906*b*; Sabin, Doan and Cunningham, 1925). The other general properties of the histiocytes, such as their behavior in inflamma-

tion, or their changes in certain diseases, supposed to affect electively the histiocytic apparatus—morbus Gaucher, lipoidemia of diabetes (Schultze, 1912), aleucemic reticulosis (Letterer, 1924), lipoidhistiocytosis (Bloom, 1925), kala azar (Meleney, 1925)—are not as easy to test. The changes described in these diseases are also probably not uniformly developed in the various groups of histiocytes; this, however, is also partly true for the storing of dyes.

The following cell types, which react positively to vital dyes, are included in the system of histiocytes: the resting wandering cells (clasmatocytes, adventitial cells) of the common loose or dense, regularly or irregularly arranged connective tissue and the serous membranes; the reticular cells of the lymphoid and myeloid tissue and the red pulp of the spleen; the squamous cells lining the lymph sinuses in the lymph nodes and the venous sinuses in the bone marrow and the spleen; the cells of v. Kupffer in the liver capillaries, and some of the cells in the walls of the venous capillaries in the adrenal and the hypophysis.

Some investigators, as Lubarsch (1921), are inclined to include in the group of histiocytes other cellular elements, on the basis of their tendency to store dyes, fats and endogenous pigments. This refers to the reticular cells of the thymus, to the perivascular spindle cells of the interstitial tissue of the testis, to some perivascular cells in the adrenal and kidney, to the reticulum of the pancreas, to certain cells in the posterior lobe of the hypophysis, etc. Even the interstitial cells of the ovary are supposed by some authors to be histiocytes (Benthin, 1923). As the cells just enumerated include not only elements of mesodermal, but also of entodermal (thymic) and ectodermal (glial) origin, the outlines of the conception of the histiocytes in the case of such an extension are liable to become vague. The storing and intraplasmatic transformation of the substances mentioned above, at least as a temporary or pathological phenomenon, seem not to be the exclusive prerogative of the histiocytes.

In their various locations the histiocytes show more or less typical structural differences. In addition, their microscopic appearance is strongly influenced by their functional condition. In general, the histiocytes can be found in a resting or in an active state. The first status usually coincides with their fixed position, while the active histiocytes in most cases show a more or less distinct hypertrophy and rounding up and may even become completely isolated from their neighbors and appear as free ameboid cells. In their active condition the histiocytes store larger quantities of vital dyes than in the resting.

II. THE HISTIOCYTES OF THE COMMON CONNECTIVE TISSUE

In the common loose, irregularly arranged connective tissue of the mammals the histiocytes are found, in part, in an active, ameboid condition; in part, in a quiescent, fixed condition.

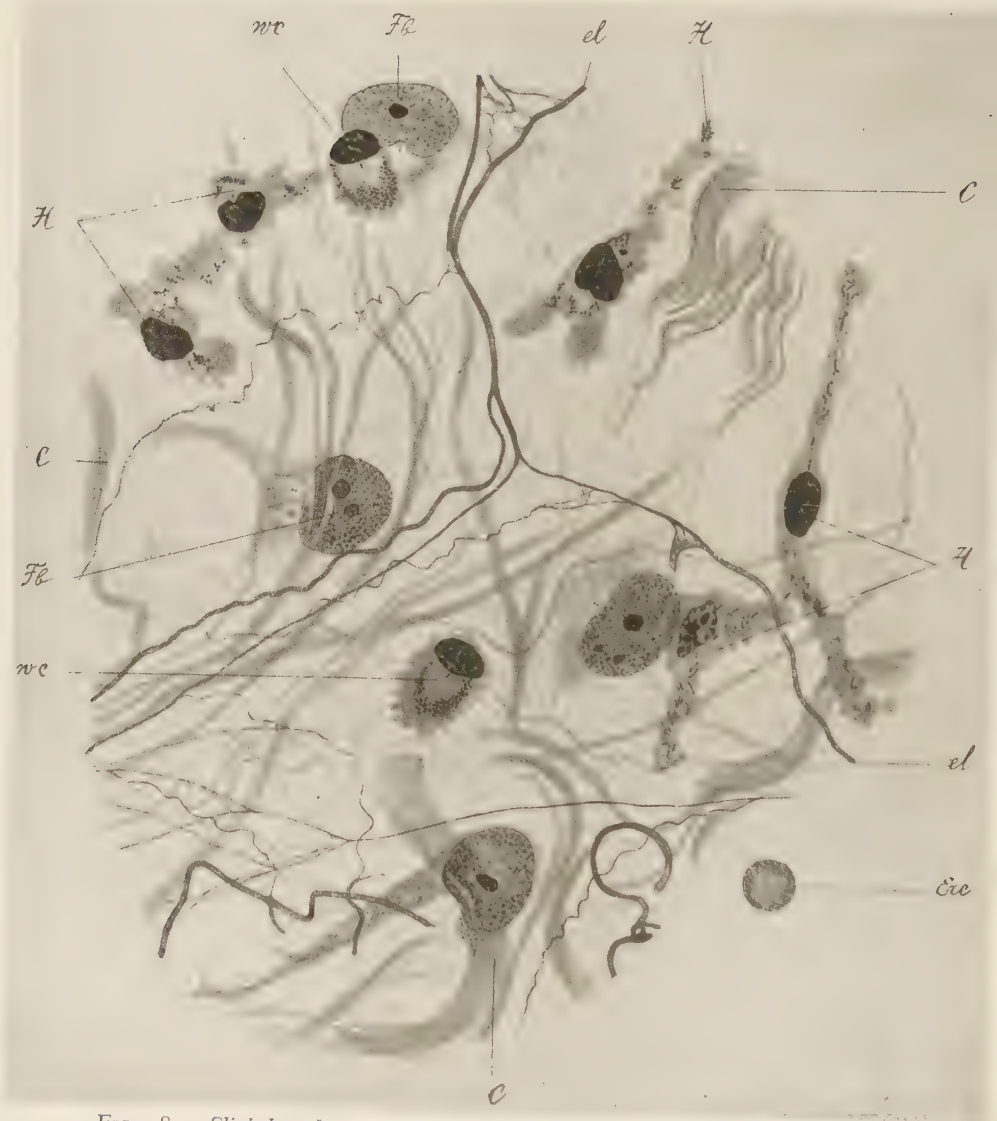

FIG. 187.—Slightly edematous loose subcutaneous tissue from thigh of man. c, collagenous fibers; el, elastic fibers; Fb, fibroblasts; we, ameboid wandering cells (macrophages); H, resting wandering cells (histiocytes, clasmatocytes); Erc, human erythrocyte from the same slide, drawn for comparison of size. Zenker formol fixation; iron-hematoxylin. Zeiss apochr. hom. imm. 2 mm, comp. oc. 8.

The cells of the first type constitute the larger forms of the so-called "round wandering cells" of the connective tissue and seem to have been seen here for the first time by v. Recklinghausen (1863). Whereas the small forms histologically correspond to the lymphocytes and monocytes of the blood, the larger ones have an average diameter of 10μ to 15μ and possess an excentrically located kidney-shaped nucleus and an abundant, pale, slightly basophilic or even acidophilic protoplasm, containing a cytocentrum and numerous granular and short rod-shaped chondriosomes (Fig. 187, wc). When stained supravitally with neutral red, the cells contain

FIG. 188.—Subcutaneous tissue of cat, supravital staining with neutral red; Fbl, fibroblasts; RWz, resting wandering cells (histiocytes, clasmatocytes); Mz, mast cells; c, collagenous fibers, El, elastic fibers. Zeiss apochr. hom. imm. 2 mm., comp. oc. 8. (After Maximow, 1906*b*.)

a varying amount of small and large red vacuoles, arranged around the cytocentrum more or less distinctly in the form of a rosette. In animals stained intravitally with trypan blue or carmine they may accumulate granular dye inclusions.

The fixed histiocytes, described as resting wandering cells by Maximow (1902, 1906*b*), are found in the various parts of the body in varying quantities. Counts have never been made; in most cases they seem to be

about equal to the number of fibroblasts. In the places of the loose connective tissue poor in vessels and cells they are less numerous but of larger size; they are more numerous but smaller in places richly supplied with blood vessels, especially in the fat tissue. They are scattered singly or in small groups of two or three. Contrary to the opinion of some authors (Dominici, 1920–21; W. and M. v. Möllendorff, 1926) they, as a rule, at least under normal conditions in mammals, seem to be quite independent cellular units and do not form syncytia. Observation in living condition (in tissue cultures), with supravital staining (neutral red) and in suitably fixed and stained slides shows them to be always independent of the fibroblasts.

The resting wandering cells are polymorphous (Fig. 18⁻H, Fig. 188RWZ). All transitions can be found among them from squamous, round or angular bodies, which in profile assume a short, spindle-shaped form, to irregularly outstretched cells with very long, sometimes branched processes. In some species (rat, mouse, hedgehog) the forms of the first kind prevail, while in other species (rabbit, cat, dog, man) the second type is more common. The nucleus is always smaller and darker than that of the fibroblasts. It has an irregular, round, oval or kidney-shaped form and a coarser, wrinkled membrane. In the interior of the nucleus, on fixed slides, coarser and more irregular chromatin particles and an inconspicuous nucleolus can be seen. The protoplasm shows in the living condition a higher refractive index and sharper outlines than in the fibroblasts. After fixation it appears to be darker and may show a granular or reticular structure. It stains heavier than the protoplasm of the fibroblasts and its outlines are more distinct and sometimes markedly ragged. It contains, especially in the neighborhood of the attraction sphere, chondriosomes in the form of short rods (chondrioconts) and round granules (mitochondria). As the visible expression of an active metabolism, it usually displays a varying amount of more or less solid granular inclusions of different size (especially in the rabbit) and of vacuoles; these sometimes contain a small solid granule. Very commonly, droplets of neutral fat or lipoids are found. Next to the nucleus, provided the cell occupies a favorable position in the slide, the protoplasm always displays a well developed cytocentrum. It consists of a typical pair of centrioles, which are sometimes surrounded by a clear area. A Golgi net is also present.

When stained supravitally with neutral red—an injection of a few drops of a weak solution of this dye in physiological saline into the tissue of a freshly killed animal is sufficient—the resting wandering cells become very prominent, because their granular and vacuolar inclusions rapidly adsorb the dye (Maximow, 1906*b*; Renaut, 190⁻; Evans and Scott, 1921; Sabin, Doan and Cunningham, 1925). This is a typical case of the action of a basic dye (v. Möllendorff, 1918, 1920) (Fig. 188RWZ).

The most characteristic phenomenon for the cells under consideration is their elective intravital staining with acid aniline dyes—pyrrhol blue, isamin blue, trypan blue, etc. (Bouffard, 1906; Goldmann, 1909, 1912; Tschaschin, 1913; Evans, 1915; Evans and Schulemann, 1915; Evans and Scott, 1921) and with lithium carmine (Ribbert, 1904; Kiyono, 1914). After repeated injections of sufficient quantities of these colloidal dyes into an animal—subcutaneously, intraperitoneally or intravenously—the resting wandering cells everywhere in the diffuse connective tissue accumulate stained particles. At first some few minute, round, homogenous and relatively pale droplets appear in the protoplasm around the nucleus. Later the cell body gradually becomes more and more crowded with an increasing quantity of colored granules which extend to the ends of its processes. The size of the granules also increases and soon irregular, angular lumps of varying sizes develop. These inclusions may attain considerable dimensions and sometimes contain dark, granular dye precipitates. The connective tissue may even macroscopically show a distinct color. As the fibroblasts store only quite insignificant amounts of dye, this method offers a good opportunity for distinguishing the resting wandering cells in living condition.

The intravital storage of dyes is probably not regulated by chemical interactions; it seems to be a purely physical phenomenon (Schulemann, 1917; v. Möllendorff, 1920; Evans and Scott, 1921). Whereas basic dyes, as neutral red, will stain passive, non-living inclusions in any kind of cell, the nature of the intracellular accumulation of the acid aniline dyes and lithium carmine seems to be quite different. Ultramicroscopic dye particles of the colloidal solution are supposed to enter the cytoplasm of certain cell types, in our case of the resting wandering cells, in an invisible way; they are precipitated in the cell body where they are continuously joined by new particles of the same kind. As soon as the dye accumulations reach a sufficient size, they become visible under the microscope. Finally, the increased concentration of the dye in such inclusions may result in the formation of solid, granular precipitates and sometimes even of crystals.

The distribution of the acid dyes in the body and their storage in the resting wandering cells is regulated particularly by the solubility of the dyes, by the manner and the speed of their introduction into the body, by the doses used, etc. The highest degrees of vital staining of the resting wandering cells can be observed in cases, where a very coarsely dispersed colloidal dye is introduced directly into the loose connective tissue, such as occurs in subcutaneous injection. Under such circumstances these cells may even be induced to accumulate colloidal silver (collargol) (Tschaschin, 1913).

If fine particulate matter, as India ink, carmine powder, cinnabar etc., finds its way into the connective tissue and comes in contact with the resting wandering cells, it is at once taken up by their protoplasm. Thus,

the capacity for storing substances in colloidal solutions is associated with the tendency to phagocytize microscopic particles. If the stimulation in such cases does not exceed a certain degree of intensity, the cells may remain in their quiescent, fixed condition. They can be looked upon as "fixed phagocytes" in the sense of Metschnikoff (1905).

Apart from transitional forms between the resting wandering cells and the large, ameboid active histiocytes, the connective tissue contains a variable quantity of elements, which have to be looked upon as transitional forms between the histiocytes and the small lymphocytoid and monocytoid ameboid wandering cells on the one hand and between the histiocytes and the fibroblasts on the other hand (Ranvier, 1890, 1900; Maximow, 1902, 1906*b*; Weidenreich, 1911; Benninghoff, 1923; W. and M. v. Möllendorff, 1926).

The transitional forms of the first type in vitally stained animals show a marked tendency to gradually store the dye, which parallels the increase in size of the cell body. This series extends to the large, active histiocytes or macrophages and can be continued farther to the typical quiescent resting wandering cells. In this case the round cell body flattens and its ameboid movements subside. Instead of the pseudopodia, fixed outgrowths of various length with sharply outlined, sometimes ragged contours, appear. The cytoplasm accumulates the inclusions described above.

In the transition forms between the fibroblasts and histiocytes the nucleus is fairly large and has a more or less regular oval shape; its chromatin is distributed in fine dust like granules and conspicuous nucleoli are present. The cell body becomes thin and transparent and the sharp contours become indistinct.

It is difficult to interpret definitively the nature of the transitional forms described. They may be the expression of a real transformation of ameboid wandering cells into resting wandering cells and further into fibroblasts — of a process continually going on in the adult normal organism. They may also be considered as merely the expression of an interruption of the ontogenetic differentiation at a certain stage or perhaps of a transient functional condition. On the basis of the latest experimental data a real transformation might very well be considered as possible. However, it certainly cannot proceed in so simple a manner and on so large a scale, as was admitted by many authors of the French school, who described everywhere in the connective tissue a continuous neoformation of clasmatocytes and fibroblasts from lymphocytes (Renaut, 1907; Dubreuil, 1913; Dominici, 1920 21). The absence of degenerating fibroblasts in the normal connective tissue constitutes in itself a serious objection to the admission of a constant neoformation of fibroblasts from wandering cells.

The presence of transitional forms between fibroblasts and resting wandering cells in the normal connective tissue may suggest another possi-

bility—the development of histiocytes from mesenchymal cells. The presence of such undifferentiated elements with unrestricted mesenchymal potencies of development in the connective tissue of adult animals has been recently advocated by Maximow (1926). These elements are arranged especially along the small blood vessels and cannot always be well distinguished from the fibroblasts. W. and M. v. Möllendorff (1926) consider all fibroblasts of the loose connective tissue as undifferentiated embryonic elements, arranged in the form of a syncytial network. They also deny the individuality of the resting wandering cells and believe them to be merely parts of the fibroblastic network, which, under the influence of a stimulus or injury, temporarily separate themselves from the syncytium.

The term "resting wandering cells" was given by Maximow (1906*b*) to the histiocytes of the common loose connective tissue to emphasize one of their most important qualities, their close relationship to the ameboid wandering cells, which had been already noticed by Ranvier. This does not mean that they are all lymphocytes which have migrated from the blood vessels as is often wrongly represented in the literature. That this relationship exists is now plentifully confirmed by histogenetic and experimental investigations. Maximow (1907) and Alfejew (1924) have shown that in the embryo the resting wandering cells develop in part from the so-called primary wandering cells of the mesenchyme, through cessation of the ameboid movement and transformation into quiescent forms; in part they arise directly from fixed mesenchymal cells. During the entire life new histiocytes of the same kind can develop from active lymphocytoid or monocytoid, hematogenous or histogenous wandering elements. Some of the transitional forms in the normal connective tissue, mentioned above, have to be accounted for in this way. The fully developed resting wandering cells keep for ever in a latent condition their ability to move. Under the influence of sufficiently strong stimuli, for instance in inflammation, they become mobilized and transform themselves into ameboid, phagocytic, dye-storing, active wandering elements, the so-called polyblasts (Maximow, 1902, 1903, 1904, 1905, 1909*b*; Weidenreich, 1911).

The name "clasmatocyte," given by Ranvier, was due to a peculiar phenomenon, which Ranvier thought he observed in the cells under consideration after fixation with osmic acid and staining with methyl violet. On the surface of the darkly stained protoplasm small bud-like particles were seen to arise. They were pinched off, became free and dissolved in the tissue liquid providing, in the opinion of Ranvier, some nutritive material to the other elements. This so-called "clasmatosis" cannot, however, be observed in the living condition, for instance, in tissue cultures. It is probably merely an artefact due to peculiar technique. For this reason the word "clasmatocyte" cannot be considered as suitable.

Renaut (1907) believed the vacuolar and granular neutral red inclusions to be the expression of a secretory function and designated the histiocytes of the common connective tissue as "rhagiocrine cells." The secretory nature of the inclusions has not been

conclusively demonstrated. Besides, the supravital neutral red staining is not absolutely typical for the histiocytes; it is well known that basic aniline dyes will stain any inclusion in any kind of cell (v. Möllendorff, 1918, 1920).

The name "adventitial cells," given by Marchand (1898, 1902, 1913), would be suitable if it could be shown that the resting wandering cells are arranged exclusively around the blood vessels. This is by no means the case, however. Very often in the common connective tissue and especially in the omentum the capillaries and the small veins and arteries are surrounded by elongated spindle-shaped histiocytes. But in addition similar cells are seen scattered everywhere in the tissue. In the omentum they are very numerous in the areas devoid of vessels and in most cases certainly could not have originated from the neighborhood of blood vessels (Fig. 189). The perivascular arrangement is merely one of the many possible locations and should not influence the terminology.

Metschnikoff (1905) created, as has been mentioned, the expression macrophage for the large phagocytic cells which are found in different places of the body and play an important rôle in the defense reactions. From the morphological standpoint, however, his conception of the macrophages was rather vague, as he did not sharply separate them from the leucocytes. In consideration of the phagocytic potencies of these cells Dominici (1902), Evans (1915), Evans and Scott (1921) and others have adopted the terminology of Metschnikoff for the resting wandering cells of the connective tissue.

As has been already pointed out in the introduction, the resting wandering cells of the common irregularly arranged connective tissue belong to a vast cell system distributed all over the body and termed at the present time by the majority of investigators as the system of histiocytes (reticulo-endothelium). The resting wandering cells are the histiocytes of the common loose connective tissue.

III. THE HISTIOCYTES OF THE OMENTUM

The tissue of the serous membranes is a peculiar variety of the common loose irregularly arranged connective tissue. Its most important part is the omentum, which contains a very great variety of cells and is especially well provided with histiocytes. It has therefore always been a favorite object for the study of these cells (Ranvier, 1890, 1900; Marchand, 1898, 1902, and others).

The resting wandering cells, the clasmatocytes, or histiocytes of the omentum, are flat, angular, or fusiform elements, which sometimes, especially in the rabbit, are markedly stretched out and provided with long, branched filiform processes (Fig. 189H). Their inner structure corresponds to the description given above for the same cells in the common loose connective tissue. Supravital staining with neutral red shows a varying number of clear vacuoles and of red inclusions assembled in small groups around the nucleus and scattered in the processes (Fig. 190a). In intravitally stained animals the protoplasm also contains granular dye inclusions.

In the so-called milky spots and along the larger blood vessels the histiocytes constitute the majority of the elements of the tissue; their accumula-

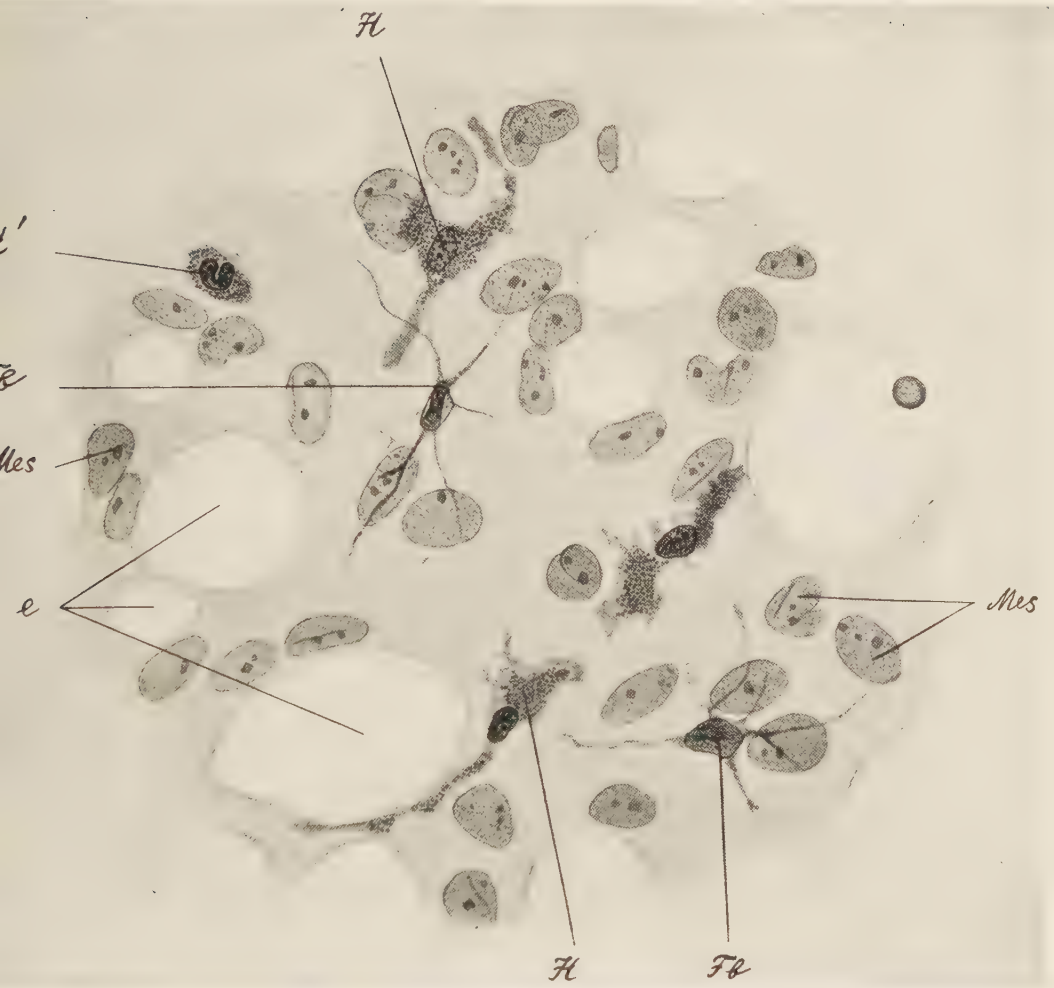

FIG. 189.—Whole mount of stretched omentum of a rabbit repeatedly injected intravenously with lithium carmine; perforated area, not containing vessels. Mes, nuclei of mesothelium; e, holes in the membrane; Fb, fibroblasts; H, resting wandering cell (histiocyte, clasmatocyte); H′, ameboid wandering cell (histiocyte, macrophage). On the right side an erythrocyte from the same slide. Sublimate formol fixation; hematoxylin. Zeiss, apochr. hom. imm. 2 mm, comp. oc. 4.

tions cause the opaque aspect of the membrane in these places. A large part of them is always found here in a contracted, round, active and ameboid condition—as phagocytic macrophages or physiological polyblasts of spherical or irregularly angular shape and of various sizes (Fig. 191H′).

The excentrically located nucleus, usually of kidney-shape or horseshoe-form, has a wrinkled membrane. It contains irregularly scattered chromatin particles and small nucleoli. The cytocentrum is very prominent. The protoplasm stores large quantities of colloidal dyes. After supravital neu-

Fig. 190.—a, resting wandering cell (histiocyte, clasmatocyte) from omentum of normal rabbit; supravital staining with neutral red; red inclusions grey, unstained vacuoles clear, fat droplets ringshaped; b, similar cell from same omentum, supravital staining with Janus green; protoplasm contains greenish-blue chondriosomes (black) and clear vacuoles. Leitz hom. imm. 1/12, Zeiss, oc. 6.

tral red staining a large rosette of red granules or vacuoles surrounds the cytocentrum. Most of these are very fine. At the periphery of the rosette, however, the neutral red inclusions may attain a large size (Fig. 192a–f). The supravital staining with Janus green reveals a multitude of small granular and rod-shaped chondriosomes, scattered through the cell body. In combination with neutral red the Janus green usually does not stain the chondriosomes, (Fig. 190b).

The resting and active mobilized histiocytes are always connected with each other by numerous transitional forms (Fig. 189H′). This fact may be

explained through continuous mobilization of new resting wandering cells which balances those lost by migration into the abdominal cavity. On the other hand the possibility is not excluded, that active macrophages may settle down again and transform themselves into resting histiocytes. Besides, the histiocytes of the omentum always show mitotic figures and, in addition, heteroplastic neoformation of histiocytes from undifferentiated mesenchymal elements, especially along the small blood vessels, has to be admitted. Another source of the histiocytes in the omentum is the pro-

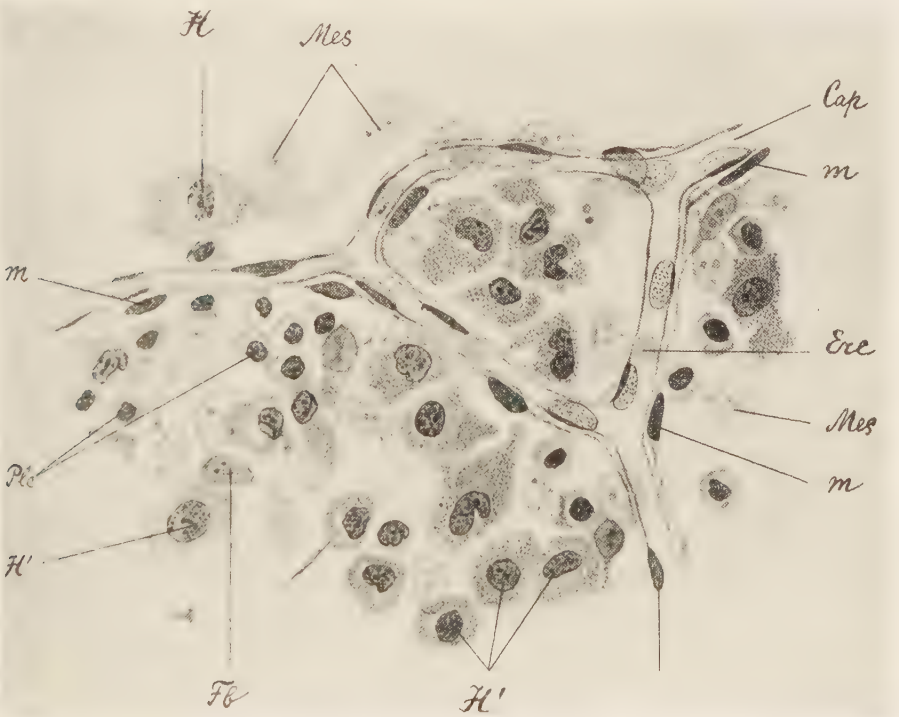

FIG. 191.—Same slide as in Figure 189. Edge of a milky spot with vessels. Cap, blood capillaries; m, undifferentiated perivascular cells (pericytes); Erc, erythrocytes; Plc, plasma cells; other abbreviations, technique and magnification as in Figure 189.

gressive transformation of local or hematogenous lymphocytes and monocytes into polyblastic macrophages.

The large quantity of ameboid histiocytes which are quite similar to the polyblasts as found in inflammation, gives the normal omentum, microscopically, the appearance of inflamed tissue. In addition, the quantity and the condition of the histiocytes in the omentum even in normal individuals are subject to marked fluctuations. These structural changes can be looked upon as the expression of reactions to transient physiological alterations of

LANE LIBRARY, STANFORD UNIVERSITY

the chemical constitution of the internal medium of the body and of resorptive processes, of a so-called "physiological inflammation" in the sense of Rössle (1923).

Under various pathological and experimental conditions the omentum and especially its histiocytes are known to play an important rôle in the defense reaction against local injuries (Seifert, 1921; Vogt, 1923; Portis, 1924, and others). In cases of inflammatory irritations of the peritoneum the reactive phenomena develop with the greatest speed and manifest themselves with the greatest intensity in the omentum. If particulate matter of any kind, including bacteria, enters the peritoneal cavity, it is taken up

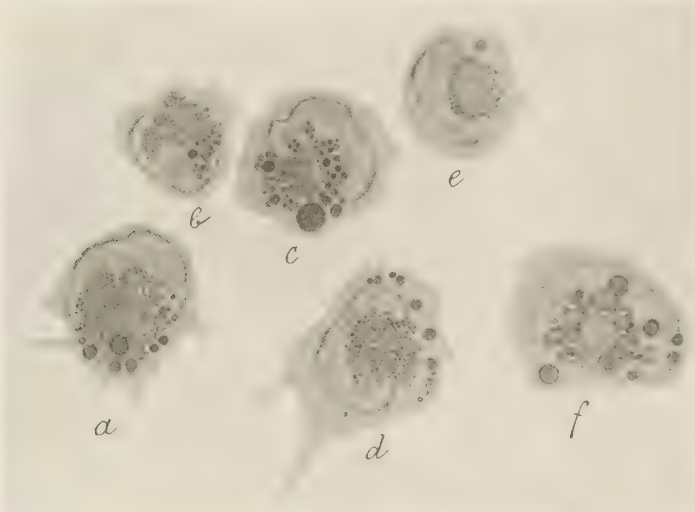

FIG. 192.—a-f, mobilized, round, ameboid wandering cells (histiocytes, clasmatocytes) from milky spot of omentum of normal rabbit; e, monocytoid cell; supravital staining with neutral red; red inclusions gray. Leitz hom. imm. 1/12, Zeiss comp. oc. 6.

and disposed of by the histiocytes of the omentum. These elements seem also to take an active part in the elaboration of antibodies.

The mobilized histiocytes (macrophages) of the omentum pass in large numbers into the peritoneal exudate. Their migration through the mesothelium can be easily observed. In inflammatory reactions their number in the exudate increases enormously and transitions are also found from lymphocytes and monocytes (of local and hematogenic origin) to large free macrophages.

As the free round histiocytes of the normal or inflammatory peritoneal exudate correspond in every respect to the "mononuclear" exudate cells, found in inflamed areas of the common loose connective tissue, they have been called "exudate polyblasts" (Wjereszinski, 1924, 1925). They are

large, spherical phagocytic cells, with an excentrically located, kidney-shaped, sometimes constricted or irregularly wrinkled nucleus which often shows mitotic division (Fig. 193Exp). Sometimes two or more nuclei are present in the larger cells (Exp'). The protoplasm contains a distinct cytocentrum and numerous chondriosomes and forms at the free surface a dense ectoplasm, sending out membrane-like pseudopodia. In vitally stained animals most of the free exudate polyblasts contain a varying number of dye granules arranged around the sphere. If vital dyes are injected intraperitoneally, the dye accumulation here naturally reaches the highest degree.~

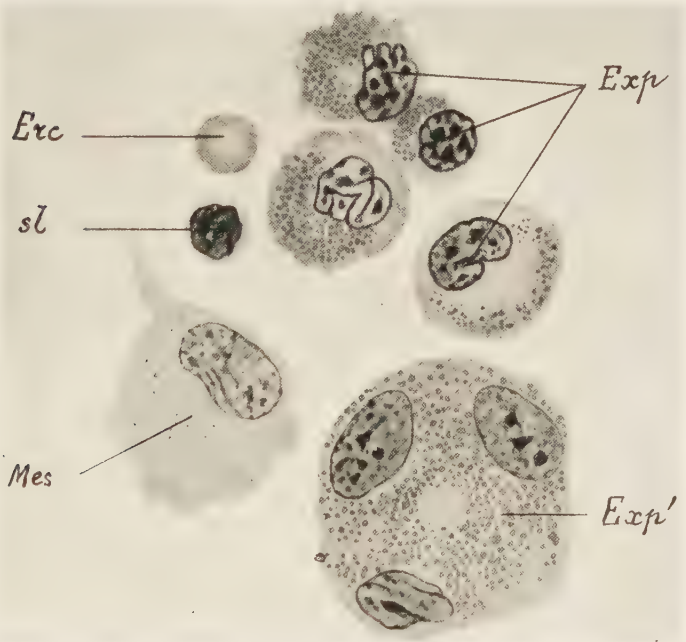

Fig. 193.—Cells from the peritoneal exudate of a rabbit which was repeatedly injected intravenously with lithium carmine. Mes, detached mesothelial cell; sl, small lymphocyte; Erc, erythrocyte; Exp, carmine storing exudate polyblasts (macrophages); Exp', large macrophage with three nuclei and cytocentrum. Moist smear, Sublimate formol fixation; hematoxylin. Zeiss apochr. hom. imm. 2 mm, comp. oc. 8.

When stained supravitally with neutral red the exudate polyblasts display a varying quantity of red vacuoles, which, as is usual in active free histiocytes, in most cases surround the cytocentrum in the form of a rosette. In the largest cells the rosette may be obscured by a great accumulation of stained, large, drop-like inclusions.

An attempt has been made to classify the exudate polyblasts on the basis of their reaction to neutral red in fresh condition. Sabin, Doan and

Cunningham (1924) distinguish the so-called monocytoid type with a fine granular rosette from a histiocytic or clasmatocytic type with large scattered inclusions. McJunkin (1925*a*), using the same method, finds three types of cells. However, the different types of exudate polyblasts are connected with each other by intimate transitional forms and cannot be sharply separated. The conclusions as to their different origin (blood vessel endothelium, lymphatic endothelium etc., McJunkin) seem not to be sufficiently warranted.

IV. THE HISTIOCYTES OF THE LYMPHOID TISSUE

In the lymphoid tissue, as for instance in the lymph nodes, the histiocytes are massed in large quantities. They have been known here for a long time as "reticular cells," attached to the fibers of the reticular stroma of the tissue.

In their resting condition the reticular cells are characterized by an oval, sometimes flattened, wrinkled, pale nucleus which contains but little chromatin and an angular nucleolus and which is surrounded by a scant, pale, homogenous protoplasm (Fig. 194, Fig. 195m); usually no distinct inclusions are seen in the latter. The cell bodies are not only adjacent to the fibers of the reticulum, but they surround them completely, so that the fibers, in fact, are located within the protoplasm (Thomé, 1903; Orsós, 1926). As M. Heidenhain (1911) has pointed out, the fibers usually occupy a peripheral position in the protoplasm and sometimes are seen to line its surface. The processes of the reticular cells often extend into thin protoplasmic membranes which occlude the meshes of the fibrous reticulum much in the fashion of a veil stretched on a frame. In the sinuses, on the surface of the primary nodules, in the neighborhood of vessels, the fibers are thick and the protoplasm so scant, that it is almost invisible and the fibers seem naked. In other places, especially in the germ centers, the protoplasm, on the contrary, predominates and the reticulum is for the most part cellular in nature (v. Schumacher, 1897, 1899; v. Ebner, 1902; Thomé, 1903; Weidenreich, 1905, and others). This arrangement, however, is subject to changes and in the sinuses large cells with abundant protoplasm can arise in the shortest period of time from the small, inconspicuous nucleated cell bodies adjacent to the fibers.

Although Ranvier (1889) succeeded in demonstrating with the aid of silver nitrate black-stained cell limits in the reticulum of the lymph nodes, it is generally admitted at the present time, that the reticular cells just described are connected with each other in the form of a sponge-like, reticular syncytium penetrated by a branched fibrous framework (Fig. 194). This syncytial nature is by no means permanent or unchangeable. Under physiological and even more under pathological conditions free cells break

loose from the syncytium, especially in the sinuses (Fig. 195H′, Fig. 196). The same phenomenon can be easily observed in living condition, in tissue cultures of lymph nodes (Maximow, 1916, 1922, 1923*a*, Fig. 197).

On the one hand in the normal lymphoid tissue degenerating and disintegrating reticular cells sometimes can be found. On the other hand a varying, usually large quantity of them presents signs of functional activity.

FIG. 194.—Stroma of lymphoid tissue from lymph node of cat. The net forming fibers sheathed by a protoplasmic syncytium with nuclei. The lymphocytes in the meshes are not shown. (After M. Heidenhain, 1911.)

They are far more conspicuous than the resting elements and to them apply most of the descriptions of the "reticular cells," given in the literature.

The active condition finds its visible expression in a pronounced swelling and enlargement of both nucleus and protoplasm. The lymphocytes occupying the meshes of the stroma are pushed aside and instead of a compressed, pale nucleus, an irregularly outlined, lightly staining cell body with a large

FIG. 195.—Medullary sinus of mesenteric lymph node of rabbit repeatedly injected intravenously with lithium carmine; m, undifferentiated, resting elements of the cellular reticular syncytium; H, histiocytes (reticular cells) storing carmine in granular form; some of the granules, brown in the original slide, are waste pigment; w, squamous histiocytes, lining the wall of the sinus; H′, large free histiocyte (macrophage), phagocytizing erythrocytes (Erc); slc, small lymphocytes; llc, large lymphocytes; llc′, mitosis of large lymphocyte. Zenker formol fixa-

vesicular nucleus, appears. While still keeping its adherence to the fibers and perhaps the syncytial connection with its neighbors, the cell bulges into the free spaces of the reticulum. This is especially prominent in the sinuses (Fig. 195H).

As the ultimate result of this transformation the hypertrophying cells withdraw their fixed processes and definitively isolate themselves from the reticulum; they are now seen in its meshes as large, free, phagocytic elements, as ameboid macrophages (Fig. 195H', Fig. 196). The protoplasm sends out membrane-like hyalin pseudopodia (Fig. 197), the kidney-shaped, excentrically located, pale, vesicular nucleus has a distinctly wrinkled membrane and an enlarged nucleolus. By their abundant, pale, sometimes acidophilic protoplasm, the positive reaction to supravital neutral red staining, and the small amount of chromatin in the nucleus, the free histiocytes of the macrophage type are always easily distinguishable from the large lymphocytes.

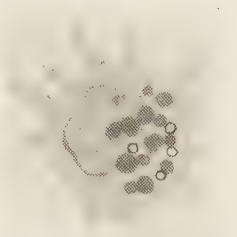

FIG. 196.—Free ameboid histiocyte (macrophage) from the sinus of mesenteric lymph node of a normal rabbit; supravital neutral red staining; red inclusions gray; fat droplets ringshaped. Zeiss hom. imm. 1/12, comp. oc. 6.

Parallel with the described hypertrophy, the protoplasm of the active histiocytes begins to accumulate various inclusions, as vacuoles or granules of waste pigment (lipofuscin); the latter is especially common in the reticular cells of the medullary sinuses in the mesenteric lymph nodes.

Supravital staining with neutral red produces in the histiocytes of the lymphoid tissue the same effect as in the resting and mobilized histiocytes of the omentum.

The vital staining of the active histiocytes is merely one of the manifestations of their capacity of storing colloidal substances. It can be brought about through repeated subcutaneous, intraperitoneal or, better still, intravenous injections of the dyes already mentioned above—isamin blue, trypan blue, lithium carmine. Carmine is especially favorable, because it remains in the tissue even after the treatment with such a histological reagent as potassium bichromate, whereas the benzidine dyes disappear. On the other hand the carmine seems to have a toxic influence upon the organism and causes especially the lymphoid reticulum to produce an unusually large quantity of hypertrophic fixed or free macrophages.

The active reticular cells and especially the free macrophages store vital dyes slower than the same cells in the spleen and bone marrow. But finally they can accumulate the dyes in even larger quantities than the resting wandering cells of the common loose connective tissue or the "clasmatocytes" of the omentum. All transitions from the smallest microscopically

visible granules, to large, round or irregular lumps can be seen in the protoplasm (Fig. 195H). The dye inclusions are often found together with granules of waste pigment and the larger lumps may appear partly brown and partly red or blue respectively. Simultaneously the protoplasm of a particular histiocyte may contain vacuoles, fat droplets and various phagocytized particles, as erythrocytes or—in cases of combined intravenous vital dye and India ink injections—particles of carbon. The larger the amount of

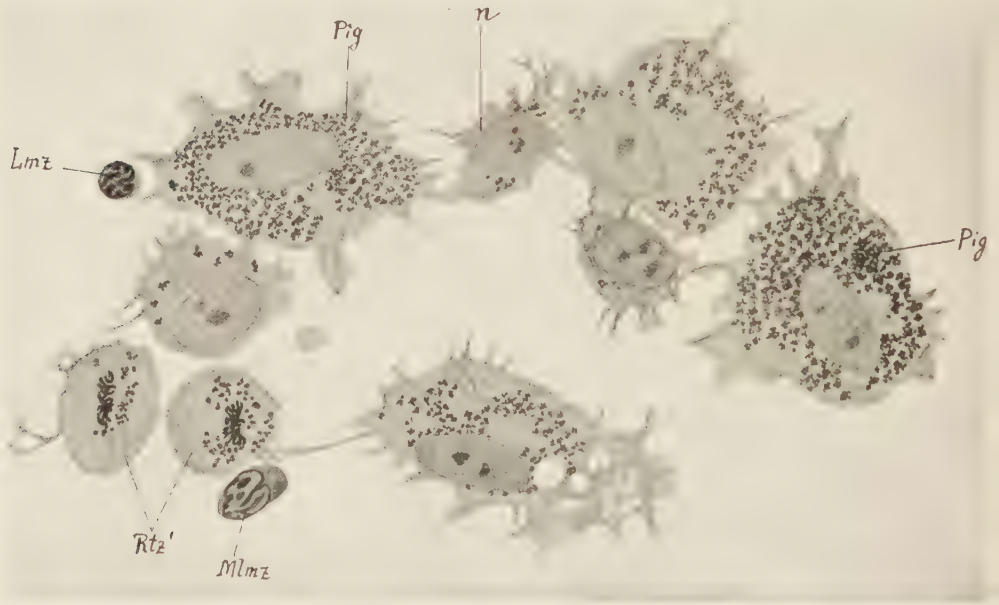

FIG. 197.—Tissue culture of lymph node of rabbit (5 days). Large free ameboid histiocytes (reticular cells) floating in the liquid on the surface of the explant; through mitotic division (Rtz') the cells temporarily acquire a smaller size (n); Pig, waste pigment inclusions; Lmz, small lymphocyte; Mlmz, medium sized lymphocyte. Zenker formol fixation; eosin-azure. Zeiss apochr. hom. imm. 2 mm, comp. oc. 8. (After Maximow, 1923.)

stored carmine, the larger the size of the cell; the greatest quantities of carmine are always found in the giant macrophages in the sinuses.

Regarding the distribution of the storing cells in the lymphoid tissue they are always most numerous in the large medullary sinuses of the lymph nodes. In some cases practically all the cells of the reticular stroma are found in the condition of maximal storage and for the most part as free macrophages. Among the fixed carmine-loaded cells the squamous elements

lining the surface of the medullary cords are especially conspicuous. In the diffuse lymphoid tissue of the cortex the reticular cells usually contain a smaller amount of carmine. However, occasionally here, too, very large, epithelioid, polyhedral cells crowded with carmine granules can be found singly or in small groups.

It is important, that even in cases with maximal intravital staining an attentive examination will always reveal numerous small, pale, seemingly unchanged reticular elements with but few or no dye granules (Fig. 195m). It is especially remarkable that the reticular cells and even the large phagocytic macrophages in the germ centers as a rule remain free of dye inclusions.

The fixed reticular cells in the active histiocytic condition and especially the free macrophages engulf any kind of particulate matter as soon as it comes in contact with their protoplasm. Degenerating and dead cells such as lymphocytes, reticular cells or special leucocytes, and particularly erythrocytes, are of quite common occurrence in the sinuses even under physiological conditions (Fig. 195h'). They are all phagocytized and undergo intracellular digestion (v. Schumacher, 1897, 1899; Thomé, 1898). In some pathological conditions this may occur on a very large scale. The same cell may contain various phagocytized inclusions which in most cases accumulate at the periphery of the cytocentrum. It is difficult to decide whether this phenomenon is active phagocytosis, i.e. whether the free macrophages are guided in their wanderings by chemotactic influences. At any rate the surface of their protoplasm seems to have a peculiar stickiness for the particles suspended in the lymph and seems to produce an agglutinating effect upon them. In cases of erythrophagocytosis the surface of the macrophages is covered by an uninterrupted layer of erythrocytes. Similarly, in the vessels of the yolk sac, the "endothelial phagocytes"—the first histiocytes of the embryo—display the same peculiarities (Fig. 203h).

In the sinuses of the lymph nodes, even under apparently normal conditions, all available reticular cells may occasionally be found in a highly hypertrophic condition. They need not be isolated in such cases in the form of free macrophages, but may keep their usual relations to the fibers of the reticulum and their irregular polyhedral shape. In such cases only small clefts remain between them for the lymph flow. Such sinuses filled with pale hypertrophied "epithelioid" reticular cells are very prominent between the darkly staining follicles and medullary cords and have been designated by v. Schumacher (1897) as "intermediate tissue."

It is well known, that the irregular walls of the sinuses in the lymph nodes are lined with squamous cells, the outlines of which can be made visible by the use of silver nitrate (Ranvier, 1889). The presence of these cells induced Ribbert (1889) to distinguish among the reticular elements

two kinds of cells, the "reticular cells" proper and the "endothelial cells." The flat cells lining the walls of the sinuses have been repeatedly described as "endothelium" by various authors (Thomé, 1898; Ribbert, 1907; Mallory, 1914, and others). This is certainly correct in so far as the sinuses develop from endothelium-lined lymphatics (Kling, 1904) and in so far as they remain forever in direct connection with the afferent and efferent lymphatics of the lymph nodes. In this case, however, the reticular cells adhering to the reticulin fibers in the lumen of the sinuses should also be looked upon as "endothelial cells," as they are known to arise through proliferation of the elements lining the walls of the embryonic lymphatics.

Now the endothelium of the common blood and lymph vessels is a well defined and seemingly highly differentiated cell type which under physiological, and pathological conditions as well, acts quite differently from the histiocytes. It is true, that the common endothelium is able to ingest particulate matter from the blood, as for instance carbon particles (McJunkin, 1919; Foot, 1919, 1920*a*, *b*, 1921*a*, *b*, 1922, 1923, 1925; Stilwell, 1926; Lang, 1926*c*). However, it does not store any of the colloidal vital dyes (Tschaschin, 1913; Kiyono, 1914) and is unable to transform into wandering phagocytic polyblastic elements (Maximow, 1902, 1903, 1904, 1905, 1906*a*, 1924*a*, *b*; Downey, 1922; Lang, 1926*a*, *c*); it does display, however, a decided tendency to change into common fibroblasts. This difference in the behavior of the endothelium and the histiocytes is especially manifest in tissue cultures (Maximow, 1916, 1922, 1923*a*, 1925*a*).

The squamous cells of the sinus walls, as Downey (1915) emphasizes, show intimate anatomical relations to the reticular cells of the diffuse lymphoid tissue in the lymph nodes. In fact, they can be looked upon as flattened reticular cells (Fig. 195,w). Their functional properties are also identical with those of the reticular cells; they behave in every respect like true histiocytes and the eventual differences are merely of a quantitative nature. They store vital dyes, phagocytize, furnish free macrophages and epithelioid cells. If under certain pathological conditions, as for instance in Gaucher's disease (Mandlebaum and Downey, 1916), they seem not to take part in the formation of the large specific elements, this can be easily explained by postulating the absence of the stimulating factor from the lymph. Furthermore, if the "endothelium" of the sinuses in vitally stained animals seems to contain more dye inclusions, than the "true" reticular cells of the "parenchyma" in the primary nodules or in the medullary cords, this again could be explained by the greater accessibility of the first-named cells to the dye circulating in the lymph. In tissue cultures the "endothelium" of the sinuses shows exactly the same behavior as the "true" reticular cells of the diffuse lymphoid tissue—it also transforms itself into large ameboid, phagocytic macrophages or polyblasts (Maximow, 1922, 1923*a*).

The sharp differences between the cells of the sinus walls and the elements known in morphology as endothelium cannot be disregarded. The former are common histiocytes and if they have to be differentiated from the reticular histiocytes of the lymphoid tissue outside the sinuses they might very well be designated with Siegmund (1923*b*) as "littoral" cells.

If the current idea of the development of the sinuses from lymph vessels is correct, we shall have to suppose that the endothelium of the lymph vessels at the time of their transformation into sinuses is still in an embryonic, undifferentiated condition. It can therefore differentiate in the histiocytic direction.

However, the recent investigations of Downey (1922) on the histogenesis of the lymphatic sinuses may lead us to another, simpler conception. Downey has found that the sinuses do not develop from preformed embryonic lymphatics, but arise as independent, blind cavities in the mesenchyme of the lymph node primordium. Accordingly, these irregular, cleft-like cavities from their very beginning are devoid of true endothelium but are lined instead with flattened mesenchymal elements. The cavities later fuse with the afferent and efferent lymph vessels. The cells lining them in these early stages naturally can easily differentiate in the histiocytic direction.

We have seen that the cellular elements of the lymphoid reticulum can be found in different functional conditions and offer a different histological picture.

We know, that in the lymphoid and myeloid tissues there must be present fixed undifferentiated mesenchymal elements with unrestricted potencies of development. This is especially clearly manifested in active germ centers, where new lymphocytes develop from the reticular syncytium (Downey and Weidenreich, 1912; Maximow, 1927*b*) and in tissue cultures, where, as Maximow (1923*a*) has shown, it is easy to observe the splitting off of free lymphocytoid and histiocytoid cells from the cellular reticulum.

The histological analysis of the processes just mentioned shows beyond doubt, that the small, inconspicuous reticular cells, with the small, oval, pale nuclei and scanty protoplasm, and which do not store vital dyes even in heavily stained animals, are the source of the new formation of histiocytes and lymphocytes. They are, then, to be looked upon as embryonic, undifferentiated cells. They are especially numerous in the germ centers.

The enlarged reticular cells with abundant protoplasm, which act as phagocytes, contain inclusions and store vital dyes, are active elements. They behave in various circumstances in the same way as do the resting wandering cells in the common loose connective tissue or in the omentum. They are the histiocytes proper of the lymphoid tissue and we have seen

that under the influence of physiological or pathological stimuli, they may round off and isolate themselves as free macrophages or polyblasts (inflammatory macrophages).

As the active elements of the lymphoid reticulum, the true histiocytes, are much more conspicuous than their resting, embryonic, undifferentiated fellow cells, it is easy to understand why the descriptions found in the literature, as a rule, apply only to the first category of elements. These storing, phagocytic, partly isolated histiocytes, on the one hand and the small, pale embryonic reserve elements on the other hand, have to be carefully distinguished from each other. Whereas the latter keep their mesenchymal potencies unrestricted, the active histiocytes, originating from them, have probably lost a part of their potencies and are to be looked upon as cells which have advanced a little farther in differentiation. The relations between these two cell types are similar to the relations between the fully developed, phagocytic resting or active wandering cells (histiocytes) of the common connective tissue or the omentum on one hand, and the perivascular mesenchymal cells of the same tissue on the other hand (Maximow, 1927*b*). The relative quantities of the resting and active reticular elements vary according to the functional conditions of the lymphoid tissue.

The free histiocytes (macrophages) can probably turn back into fixed histiocytes. Many are carried away with the lymph or degenerate in loco. The undifferentiated, embryonic reticular cells take care of the production of new histiocytes. They proliferate mitotically and transform themselves, according to the needs of the organism, into histiocytes. A development of the phagocytic histiocytes, especially the free macrophages, into the primitive, undifferentiated condition is hardly possible, as the potencies of the true histiocytes, as has been pointed out, are to a certain extent irreversibly restricted.

Fibroblasts, as a rule, cannot be detected in the reticulum of the lymphoid tissue. However, it has been shown, that in inflammation (Babkina, 1910) and in tissue cultures (Maximow, 1922, 1923*a*) large quantities of typical fibroblasts develop from the reticular stroma. The presence of undifferentiated, mesenchymal elements in the reticular syncytium, as described above, provides an adequate explanation for this phenomenon. The histiocytes themselves certainly are also able to transform into fibroblasts (Fig. 207).

V. THE HISTIOCYTES OF THE MYELOID TISSUE (BONE MARROW)

In the bone marrow the fixed part of the tissue is represented by a reticulum of essentially the same character as in the lymphoid tissue. Its "reticular" cells have the same appearance and the same relations to the fibers. In vitally stained animals or after intravenous injection of fine particulate matter, as India ink, many of them—the true histiocytes—store the foreign substances. This occurs here with much greater facility than in the lymphoid tissue. This functional difference of the histiocytes in the two blood forming tissues is easily explained by the peculiar character of the walls of the venous sinusoids in the bone marrow and by the easier access the foreign substances, especially particulate matter, have to the cells in this tissue.

As in the lymphoid tissue, a part of the reticular cells in the bone marrow also remains unstained with vital dyes. They are to be looked upon as

embryonic undifferentiated mesenchymal elements, whereas the storing and phagocytic cells, the fully developed, true histiocytes, have their potencies of development restricted to a certain extent.

In the myeloid tissue also, a varying number of the histiocytes is found in a hypertrophied condition, sometimes as free isolated macrophages, which have the same structure, as in the lymph nodes and are often seen phagocytizing nuclear debris or erythrocytes and containing pigment.

As the lymph sinuses are lined with flattened histiocytes, so the large venous sinusoids of the myeloid tissue also have a wall, consisting not of common endothelium, but of flattened histiocytes, which cannot be separated from the reticular histiocytes of the tissue and which show the same functions in an especially high degree—storing of colloidal dyes, phagocytosis of particulate matter, transformation into free macrophages, etc. They also are intimately connected with the fibers of the reticulum supporting the wall of the vessel. They are "littoral cells" of the histiocytic system in the same sense as the "endothelium" of the lymph sinuses and as the cells of v. Kupffer in the liver.

In pathological conditions, according to Masugi (1927) only in the agonal period, the littoral and tissue histiocytes of the bone marrow may both give rise to a large quantity of free macrophages. They enter the sinusoids, partly through active migration through the walls of the latter, and are carried into the capillaries of the lung.

In inflammation and in tissue cultures the mobilization may affect all available histiocytes without exception.

VI. THE HISTIOCYTES OF THE RED PULP OF THE SPLEEN

The reticulum of the red splenic pulp has a similar structure as the reticulum of the lymph nodes and the bone marrow and among its cells the same two types, the resting embryonic elements and the active, storing and phagocytizing histiocytes, can be distinguished. Many histiocytes are found isolated, as free macrophages. They display a high degree of phagocytic activity. Under physiological conditions the phagocytosis is directed primarily against the worn-out erythrocytes. If fine particulate matter of any kind, carmine powder, India ink, bacteria, etc., enters the general blood circulation, these particles are also at once engulfed in large quantities not only by the histiocytes of the liver and bone marrow, but also by the corresponding elements of the splenic red pulp.

The walls of the venous sinusoids in the red pulp consist of peculiarly differentiated histiocytes (Weidenreich, 1901, Mollier, 1911), supported by a regularly arranged network of reticulin fibers. These "littoral" cells (Siegmund, 1923*a*, *b*) cannot be sharply separated from the histiocytic syncytium of the pulp.

VII. THE HISTIOCYTES OF THE LIVER SINUSOIDS—THE STELLATE CELLS OF V. KUPFFER

In 1876 v. Kupffer discovered and later described in detail (1899) peculiar cellular elements in the wall of the intralobular capillaries in the mammalian liver, which since are known as the "stellate cells of v. Kupffer." The wall of the intralobular capillaries, as has been shown by v. Kupffer and confirmed by all subsequent investigators, is a syncytial membrane, which is thickened in places by the stellate cells. In profile they are spindle-shaped, in surface view they display many interlacing processes. They bulge more or less into the capillary lumen and are in direct contact with the circulating blood. As v. Kupffer has shown, the cells under consideration readily phagocytize erythrocytes, especially after transfusion of blood, and digest them into pigment. In the same way they also engulf any particulate foreign matter, which happens to get into the blood, for instance India ink particles. These fundamental statements of v. Kupffer have been confirmed and further developed by many subsequent experimenters. Oppenheimer (1908), Nathan (1908), Goldmann (1909, 1911), Tschaschin (1913), Kiyono (1914), Evans, Bowman and Winternitz (1914), Migay and Petroff (1923) and others, worked on animals, injected intravitally with collargol, saccharated iron oxide, isamin blue, trypan blue, lithium carmine etc.; they found that the v. Kupffer cells store these colloidal substances in the form of granular inclusions in the same way as the histiocytes in other organs. They react to supravital staining with neutral red in the same manner as the resting wandering cells of the connective tissue. In various conditions of local or general irritation, especially in aseptic, purulent or specific (tuberculous) inflammation of the liver, they hypertrophy, proliferate mitotically and become free histiocytes or macrophages. They can transform themselves into epithelioid cells and, through fusion of the latter, into giant cells. In cirrhosis they are the source of fibroblast and collagen formation (Nathan, 1908). Their phagocytic tendencies towards particulate matter in the blood—degenerating erythrocytes or leucocytes and especially bacteria—have been confirmed by numerous observations. They react in this case in the same way as the squamous histiocytic elements lining the blood sinusoids in spleen and bone marrow. They also may contain varying quantities of neutral fat (Schilling, 1909).

Zimmermann (1923) discriminates in the wall of the liver capillaries three types of cells: the endothelium proper; branched pericytes between the endothelium and the liver cells; and peculiar endocytes, provided with processes and located at the inner surface of the endothelial tube or even in the lumen of the vessel. He believes that only the endocytes correspond to the true cells of v. Kupffer.

It is easy to demonstrate in the liver of any vitally stained or carbon injected animal that the cellular elements of the capillary wall are not

FIG. 198.—Liver of rabbit, injected intravenously with Higgin's India Ink. Lc, liver cells; Erc, erythrocytes in the lumen of the sinusoids; elc, eosinophilic leucocyte; a, cells caption of the capillary wall in resting condition; d, stellate cell of v. Kupffer; b and c, transitions from a to d. Zenker formol fixation; hematoxylin eosin azure. Zeiss hom. imm. $\frac{1}{12}$, comp. oc. 8.

all identical (Fig. 198). One part of the cells—these are the true cells of v. Kupffer—have a large, clear nucleus, a large amount of stored inclusions and bulge far into the lumen (d). According to Pfuhl (1926) they usually occupy either the crests in the angles of division of capillaries (phagocytic position) or they are located in the outpocketings of the wall (digestive position). The rest of the elements of the capillary wall are small and inconspicuous, possess a somewhat darker nucleus and no or very few inclusions (a). However, these variations do not entitle us to discriminate them into different categories of cells. High doses of colloidal foreign substances increase the quantity of active v. Kupffer cells. This is brought about mainly through an increased transformation of the non-storing cells into active elements (b, c), and only to a small extent through mitosis of the latter. Sometimes practically all elements in the capillaries seem to have assumed the properties of v. Kupffer cells or even to have been transformed into isolated, free macrophages (Fig. 199). Thus, the structural differences of the elements of the capillary wall in the liver seem to be merely the visible expression of their changing functional conditions (Schilling, 1909; Pfuhl, 1926). This makes the capillary wall in the liver very similar to the lymphoid and myeloid reticulum. The similarity is increased by the intimate relations existing between the elements of the liver capillary walls and the networks of reticulin fibers, forming the support of the liver lobule. Furthermore, in inflammation, the cells of v. Kupffer react in the same way as the reticular cells in the lymph nodes and in tissue culture they transform themselves into similar mobilized, ameboid polyblasts (Maximow, 1923*a*, 1925*a*). It must be pointed out, that, contrary to the findings of McJunkin (1926), the mobilized v. Kupffer cells in inflammation or in vitro react to supravital neutral red staining in exactly the same way as any other histiocytic macrophages. A large accumulation of small and large red vacuoles, which assume the character of a typical rosette, is seen at the side of the nucleus (Fig. 199).

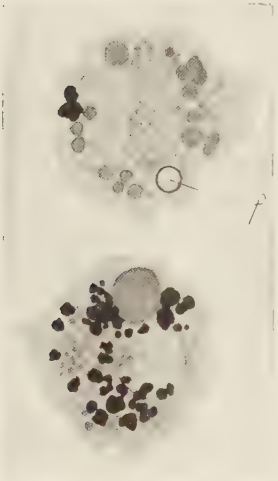

Fig. 199.—Two free histiocytes (macrophages) from the capillaries of the liver of a rabbit, injected intravenously with Higgin's India ink. Supravital neutral red staining; neutral red inclusions gray, engulfed carbon particles black. f, fat droplet. Leitz hom.imm. $^1/_{12}$, Zeiss comp. oc. 6.

It is not quite clear whether the liver capillary wall contains undifferentiated mesenchymal elements comparable to those described above in the lymphoid and myeloid tissue. Whereas Siegmund (1923*a*), Paschkis (1926*a*, *b*) and others, ascribe to the wall of these vessels not only histio-

cytic, but also hemopoetic potencies, Lang's (1926*b*) experiments with extramedullary myelopoesis have shown in the liver capillaries only colonization of hemocytoblasts, and no in loco development of blood elements from the fixed or detached cells of the wall.

VIII. THE DIFFERENCES BETWEEN THE HISTIOCYTES IN THE VARIOUS ORGANS OF THE BODY

As has been already pointed out, the histiocytes in the various regions of the body display certain structural differences.

In the diffūse loose connective tissue they are single, isolated cells; in the blood forming organs, in the spleen, in the liver they, at least in part, are fused together and form syncytia. Even in the connective tissue they may display minor differences according to the location, as for instance in the subcutaneous tissue on the one hand and in the omentum on the other hand. In the common connective tissue they do not show a close relation to fibers. In the blood forming organs and in the spleen they form a part of the fibrous reticulum.

A peculiar position is occupied by the histiocytes which line the blood and lymph channels in lymph nodes, bone marrow, spleen and liver—the so-called "littoral" cells of Siegmund (1923*b*, 1925) (Fig. 195w). These elements are quite different from the true endothelium of the common blood vessels and should not be called "endothelium." Their prospective potencies are not identical and they behave differently in inflammation, in tissue cultures, etc.

Whereas in the blood forming tissues the histiocytes are intimately connected with the undifferentiated embryonic syncytium and split off from the latter according to the needs (Fig. 195), they are isolated independent cells in the common loose connective tissue (Fig. 187).

A peculiar position has to be attributed, according to Lang (1925, 1926*a*), to the histiocytes in the lung. They are massed in large quantities in the partitions between the alveoli, where their major part displays undoubted embryonic properties. Under physiological conditions a varying quantity of them is found in activity on the inner surface of the alveolar wall in form of the so-called "nucleated alveolar epithelial cells." Many transform themselves in large, ameboid phagocytic and storing elements, which are known in pathology as "alveolar phagocytes," "dust cells," so-called "Herzfehlerzellen," etc.

IX. THE FREE HISTIOCYTES OF THE BLOOD

Under the action of sufficiently intense physiological and, especially, pathological stimuli the histiocytes in the various tissues of the body may isolate themselves and become free macrophages.

Aschoff (1913), Aschoff and Kiyono (1913), Tschaschin (1913), Kiyono (1914), Simpson (1921, 1922) and others, have shown, that in animals

sufficiently stained with vital dyes or repeatedly injected intravenously with various colloidal substances or suspensions, free histiocytes may enter the blood stream. They seem to originate especially in the spleen, liver and bone marrow and to pass with the venous blood into the right heart and into the lung capillaries, where they for the most part remain obstructing the lumen. Later these embolized histiocytes are believed to disintegrate (Aschoff, 1926) or to become incorporated into the wall of the lung veins

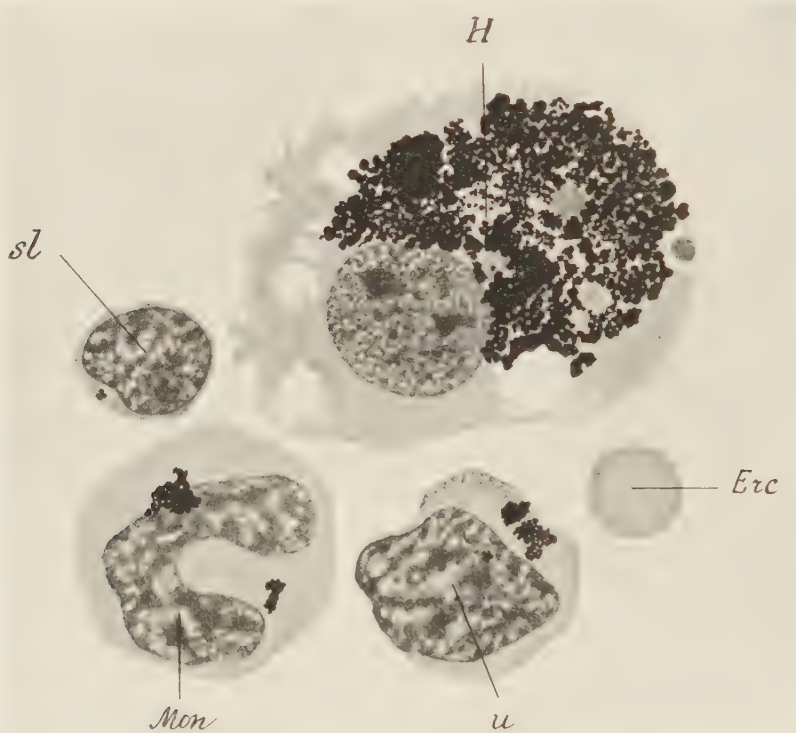

FIG. 200.—Dry smear of blood from right heart ventricle of a rabbit which repeatedly received intravenous injections of saccharated iron oxide and Higgin's India ink. H, free histiocyte (macrophage); Mon, monocyte; sl, small lymphocyte; u, transitional form between sl and Mon; Erc, erythrocyte. Stained with May Grünwald and Giemsa. Zeiss apochr. hom. imm. 2 mm, comp. oc. 12.

(Siegmund, 1926). Very few of these cells seem to pass through the lung capillaries into the general circulation.

According to Simpson (1922) the free histiocytes appear in the blood of the right ventricle in showers. Masugi (1927) explains this phenomenon merely as the result of aspiration of an inflammatory exudate from the pericardium into the syringe after repeated heart puncture.

In the living frog the blood histiocytes were observed in the circulation by Wentzlaff (1924). M. Lewis (1925*b*) has shown, however, that the respective cells are not histiocytes, but non-granular blood leucocytes, which have hypertrophied to large intravascular polyblasts or macrophages.

Macrophages in the peripheral blood were described in different infectious diseases in man (malaria, recurrent fever, endocarditis lenta, etc.)

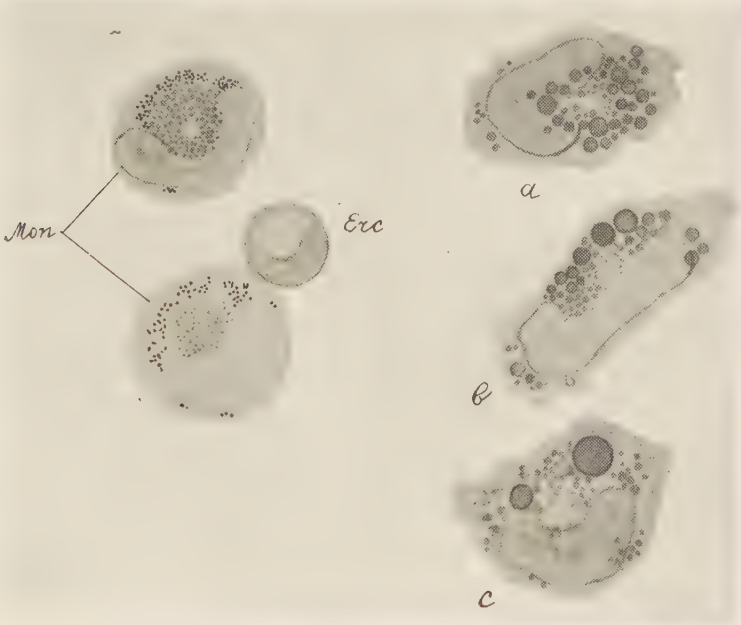

FIG. 201.—Cells from blood of a rabbit, injected with Bacillus monocytogenes, supravitally stained with neutral red and Janus green. Mon, monocytes, with rosette of fine neutral red vacuoles in the indentation of the nucleus (gray) and with peripherally arranged chondriosomes stained with Janus green (black). Erc, erythrocyte; a-c, free histiocytes (macrophages) with inclusions stained with neutral red (gray); chondriosomes not visible. Leitz hom. imm. 1/12, Zeiss oc. 6.

(Schilling, 1919; Kaznelson, 1919; Bittorf, 1920; Hess, 1922; Seyderhelm, 1923; Kartaschowa, 1925, and others). Sabin and Doan (1926) believe them to be constituents of the normal blood picture in man and other mammals.

The blood histiocytes are large spherical cells (15μ–30μ), exceeding in diameter not only the special leucocytes, but even the largest monocytes (Fig. 200H, Fig. 201a–c). The oval or kidney-shaped nucleus is excentrically located. Cells with two nuclei may occur, as well as cells with mitoses (Kiyono, 1914; Schilling, 1919). In dry smears the nucleus consists of a

delicate network and resembles the nucleus in the histiocytes as we find them in the lymphoid or myeloid tissue. The protoplasm stains faintly and may contain vacuoles, fat droplets and a various amount of stored substances. Supravital neutral-red staining reveals in the excavation of the nucleus, around the sphere, a large rosette of fine and coarse red vacuoles. Janus green stains granular and short rod-shaped chondriosomes scattered between the vacuoles and around the nucleus.

In cases with a pronounced histiocytosis in the blood of the right ventricle, sections of the liver, bone marrow and spleen often show clearly the process of separation of tissue histiocytes and their passing into the blood stream. In human material from cases of infectious diseases similar observations can be made (Schilling, 1919). Histiocytes in the parenchyma and littoral cells as well transform themselves into free macrophages. The cells can sometimes be found migrating through the walls of venous capillaries and accumulating in the lumen of the latter in large numbers.

It has to be pointed out, however, that in the opinion of Masugi (1927) the appearance of free histiocytes in the blood is merely an agonal phenomenon.

The discrimination between several categories of free histiocytes on the basis of their reaction to supravital neutral red staining, mentioned above for the histiocytes of the peritoneal cavity, has been extended by McJunkin (1925*a*, *b*, 1926) to the macrophages of the blood. He believes the cells with a finely granular red rosette to originate from "lymphatic endothelium," while the cells with a few or no red inclusions ("hyaline cells") are derivatives of blood vessel endothelium. This hypothesis is not substantiated by facts. The neutral red test shows that the histiocytes all over the body react in a similar way. The differences seem to depend on the functional condition and the stage of development of the cell and cannot afford a basis for morphological classification. The resting histiocytes usually contain diffusely scattered neutral red inclusions of various size. The active cells tend more to the accumulation of the latter in the form of a rosette at the periphery of the cytocentrum. The relations between the blood histiocytes and the monocytes are discussed in the following paragraph. In addition, it may be mentioned, that the so-called "hemohistioblasts" of the blood of the Italian author (Ferrata, 1918, 1921) which have been described as a new cell type, are doubtlessly for the most part nothing more than blood histiocytes.

X. THE MONOCYTES IN THEIR RELATION TO HISTIOCYTES

The problem of the histiocytes cannot be separated from the problem of the monocytes. These non-granular leucocytes have been described by Ehrlich as "large mononuclear leucocytes" and "transitional forms."

The monocytes are cells of 12μ–15μ. Contrary to the lymphocytes they have an abundant, slightly basophilic protoplasm accumulated on one side of the oval, kidney-shaped or constricted nucleus (Fig. 200 and 201 Mon). The Romanowsky stain gives the protoplasm a greyish-blue color and sometimes reveals peculiar fine azurophile granules. The cytocentrum

is well developed. When stained supravitally with neutral red and Janus green, the monocytes contain around the sphere a typical rosette of salmon-colored fine granules, while the rosette is surrounded by numerous bluish-green chondriosomes (Simpson, 1921, 1922; Sabin, 1923). This, however, cannot be considered as an absolutely specific feature of these cells. The free histiocytes (macrophages) may also display a similar rosette (Fig. 192, 198 and 201a–c) and in the lymphocytes a rosette may develop with astounding rapidity under the influence of inflammatory stimuli or in vitro (Maximow, 1927*a*; Bloom, 1927).

The origin and morphological position of the monocytes are still subject to discussion.

The "dualists" among the hematologists advocate their origin from the myeloid tissue of the bone marrow. Cunningham, Sabin and Doan (1925) believe them to originate from peculiar "monoblasts," for the most part in the spleen, to a lesser extent in the bone marrow. The monoblasts in their turn are supposed to develop from a more primitive stem cell which splits off from the reticulum. The "unitarians" (Weidenreich, 1911 and others), on the contrary, always had the tendency to place the monocytes in close connection with the lymphocytes and to deny the possibility of a sharp distinction between these two cell types.

A very popular idea at the present time is the origin of the monocytes from "endothelium." Mallory (1898, 1914) was the first to express this point of view; he termed the monocytes "endothelial leucocytes." His "endothelium," however, was in reality the layer of histiocytes, lining the sinuses in the lymph nodes, the capillaries in the liver, etc. Other writers, on the contrary, believe in monocyte production by the endothelium of common blood vessels and this assumption seems to have become a matter of fact in the modern clinical literature.

Cases of doubtless formation of free round cells by squamous elements, lining blood channels, are well known; they have been mentioned above, when the transformation of fixed histiocytes into free macrophages in the lymph sinuses and in the venous sinuses of the bone marrow were discussed. Another example is the cell clusters originating from the proliferating endothelium in the ventral wall of the abdominal aorta in young mammalian embryos (Maximow, 1907, 1909*a*). Nothing of this kind has ever been found up to the present time to support the presumed endothelial origin of the monocytes.

McJunkin (1919) used intravenous injections of India ink for proving the endothelial origin of the monocytes. He found mitoses in carbon containing endothelial cells and nearby, in the lumen of the vessels, free carbon containing elements. It is obvious that this fact cannot be considered as a proof for the endothelial origin of monocytes. He did not demonstrate the transformation of dividing endothelial cells into white blood corpuscles.

Foot (1919, 1920*a*, *b*, 1925), who used McJunkin's India ink technique, reiterates the affirmations of McJunkin but does not give persuasive descriptions or pictures to support his idea.

Lang (1926*c*) and Stilwell (1926), working with animals, injected intravenously with India ink, were unable to confirm the endothelial origin of monocytes. The monocytes, as well as the endothelial cells, could be easily identified in all cases, but no relations whatsoever between them could be detected. Maximow (1902, 1925*a*) has shown that in inflammation and in tissue culture the endothelium of common blood vessels proliferates and gives origin to fibroblasts, but never produces wandering cells. The same occurs in the organization of thrombi.

Aschoff and Kiyono (1913) and Kiyono (1914), on the basis of experiments with intravital carmine staining, expressed the idea that the monocytes are free histiocytes and thus identified these two cell types. They did not discriminate between the large storing blood histiocytes and the monocytes which in the average are much smaller and for the most part do not store. Despite this obvious contradiction, the idea of the identity or at least the close genetic relationship of the histiocytes and monocytes and of the independence of the latter from the lymphoid and myeloid tissue spread rapidly and has been accepted without criticism by many subsequent investigators (Schilling, 1919; Weicksel, 1920; Weill, 1920; Holler, 1923; Wollenberg, 1925; Shiomi, 1925; Schittenhelm and Erhardt, 1925; Paschkis, 1926*a* and others). From this view has developed, at the present time, the so-called "trialistic" theory, which claims for the monocytes a third, independent position, equal to the lymphoid and myeloid cell system.

The latest contributor to the problem, Masugi (1927), a student of Aschoff, makes a clear distinction between monocytes and histiocytes. By injecting intravenously different colloidal substances in rabbits he obtained, as had many experimenters before him, an increase in the number of monocytes in the blood. This increase was independent of and not parallel to the numbers of the other blood cells. Simultaneously the quantity of histiocytes in all the organs also increased. These facts, confirming similar findings of many previous investigators, lead this author to the conclusion that the monocytes and the free histiocytes originate from the same source, the ubiquitous reticulo-endothelium (i.e. the fixed resting histiocytes). The monocytes can gradually acquire the character of histiocytes. They, as well as the histiocytes, have no relation whatever to lymphocytes or to myeloid leucocytes. Masugi does not give a direct demonstration of the development of the monocytes from histiocytes. He, as well as many other writers, has reached this conclusion only by analogy.

The typical monocytes are quite different from histiocytes and the latter could not possibly transform directly into smaller cells through an individual change, such as shrinkage or some similar process. The develop-

ment of histiocytes into monocytes could possibly consist only in mitotic proliferation of the former with the production of a new generation of smaller and different cells. It might furthermore be possible that the monocytes arise not only from the differentiated phagocytizing histiocytes, but directly through proliferation and rounding up of the undifferentiated mesenchymal elements of the cellular reticulum in the blood forming organs and in the spleen. Maximow (1923*a*) and Shiomi (1925) have observed a similar process in cultures of lymphoid tissue. Large, carmine-storing and pigment-containing histiocytes (Fig. 197) gave rise through intense mitotic proliferation to numerous smaller ameboid cells, which were similar to monocytes (Fig. 202r). In the body, however, the only case where a similar phenomenon was doubtlessly observed by many investigators, seems to be the formation of monocytoid cells from large mobilized histiocytes in the milky spots of the omentum (Fig. 192e).

It is true that in cases of monocytosis and histiocytosis in the blood many transitional forms can be found connecting the two cell types. But as mitoses are not numerous, the natural explanation is that the monocytes gradually hypertrophy and undergo individual transformation into histiocytic macrophages—a phenomenon, easily observed in every case of acute inflammation (Maximow, 1902) and in tissue cultures of the buffy coat of the blood (Awrorow and Timofejewsky, 1914; Carrel and Ebeling, 1922; Maximow, 1925*a*; M. Lewis, 1925*a*; A. Fischer, 1925).

The sum of the facts available leads to the conclusion, that the monocytes, although doubtlessly closely related to the histiocytes, nevertheless do not all originate from the latter. It is more probable, that they originate from the lymphocytes, through hypertrophy in the same way as this occurs with amazing rapidity in inflammation, when polyblasts or inflammatory macrophages develop from lymphocytes which have migrated from the blood vessels (Maximow, 1902) and in tissue cultures of the buffy coat of the blood (Maximow, 1927*a*) and of the lymph (Bloom, 1927).

Regarding the localization of the production of monocytes in the body, it must be pointed out, that their development in the blood forming tissues —with the exception perhaps of the red pulp of the spleen—has never been demonstrated. In the normal lymphoid tissue-free histiocytes (macrophages) are always present, but no monocytes. In the myeloid tissue only some few exceptional monocytes can be found (Hynek, 1912; Pappenheim, 1919). Smears naturally do not permit of conclusions concerning the localization of cells in the tissue. Masugi (1927) also found the monocytes evenly distributed throughout the circulatory system and in approximately identical numbers in punctures from such organs as spleen, liver, bone marrow and lymph nodes.

Therefore, it may be assumed, that the majority of monocytes arise from the lymphocytes (or hemocytoblasts, which are the same from the

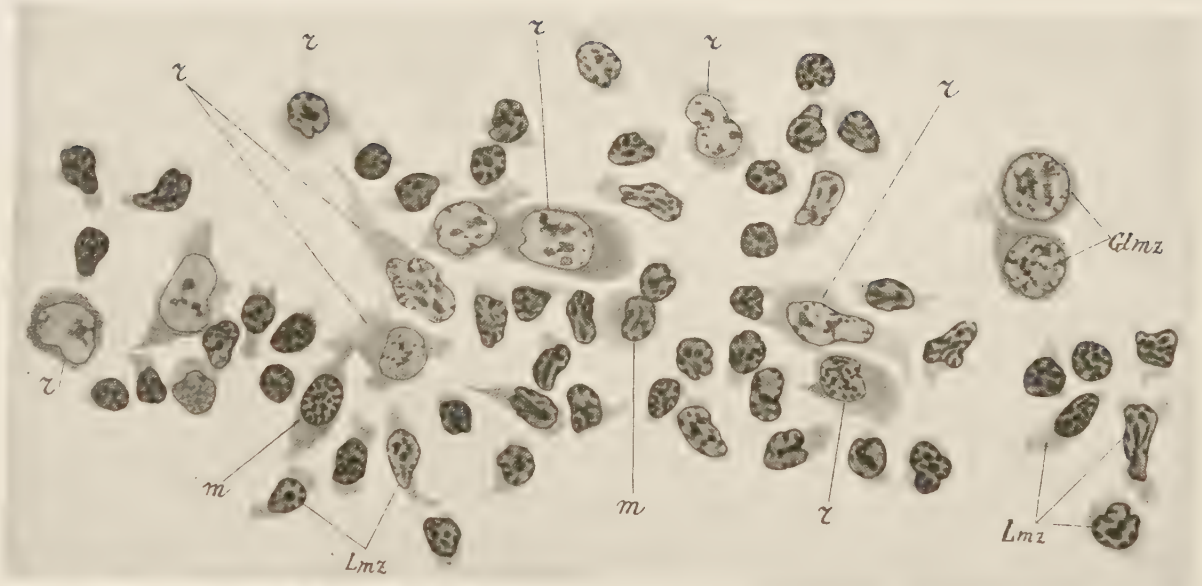

FIG. 202.—Tissue culture of lymph node of rabbit (6 days). Cells floating in the liquid, covering the explant; Glmz, large lymphocytes; lmz, small lymphocytes; m and r, cells of polyblastic type, partly originating through mitosis of reticular cells (histiocytes), partly through hypertrophy of small lymphocytes; the latter have monocytoid character (m). Zenker formol fixation; eosin azure. Zeiss apochr. hom. imm. 2 mm, comp. oc. 8. (After Maximow, 1923.)

unitarian point of view) not in the tissues, but in the lumen of the blood vessels. This need not occur in the general circulation. It is probable that it occurs predominantly in certain areas of the circulatory system; in the venous capillaries of the bone marrow, the spleen and the liver, where the blood flows sluggishly; in the red pulp of the spleen, which resembles a sponge soaked with slowly filtering blood; and eventually the lymph sinuses; here probably only under pathological conditions. As the transformation of lymphocytes into monocytes is confined only to certain sections of the vascular system it is quite natural that in blood smears taken from peripheral capillaries under physiological conditions both cell types seem to be sharply separated. However, in cases of monocytosis transitions between lymphocytes and monocytes in the blood are fairly numerous (Fig. 200u). The origin of the monocytes from ubiquitous lymphocytes explains why after splenectomy or the partial elimination of a blood forming organ the monocyte count in the blood need not be affected.

Thus, the monocytes have to be looked upon as "physiological polyblasts of the blood."

These considerations give also a simple explanation for the excessive and seemingly extremely rapid cell multiplication in certain sections of the vascular system (for instance in the lungs) in the allergic reaction (Oeller, 1923, 1925; Töppich, 1925, 1926; Siegmund, 1925 and others). The possibility of an enormous proliferation of "endothelium" or "cells of the wall of the blood vessels" (Gefässwandzellen) in the course of a few minutes, as described by these authors, especially through amitosis (v. Möllendorff, 1927), is quite improbable. On the contary, rapid changes in the distribution of circulating blood cells, especially the lymphocytes and monocytes in the vascular bed, and rapid polyblastic transformation of the intravascular lymphocytes, have to account for these phenomena. That the lymphocytes can change into monocytoid and histiocytoid elements in the course of an amazingly short lapse of time has been shown recently by Maximow (1927a) and Bloom (1927).

The monocytes are neither a lymphoid, nor a myeloid cell, nor do they represent a peculiar specific cell type as claimed by the "trialistic" theory. They for the most part are peculiar stages of development of the ubiquitous lymphoid cells. Their development is not confined to a certain tissue or organ, but may occur anywhere in blood or lymph channels, in places where the blood stream is slow and necessary chemical stimuli are available.

The monocytes must play an important rôle in the general defense reaction. On the other hand, they are incapable of hematopoetic activity and their prospective potencies of development seem to be restricted to the same extent as those of the histiocytes.

XI. THE EMBRYONIC DEVELOPMENT OF HISTIOCYTES AND MONOCYTES

The first elements of histiocytic type to appear in the embryo (rabbit 11 days) are peculiar ameboid free cells, originating from the undifferentiated endothelium of the blood vessels of the area vasculosa and scattered singly between the hemocytoblasts, primitive and secondary erythroblasts

and erythrocytes (Maximow, 1907, 1909*a*; Kiyono and Nakanoin, 1919; Sabin, 1921) (Fig. 203H). They are highly phagocytic, possess a pale, vacuolated protoplasm and a kidney-shaped, excentrically located nucleus. Endothelial cells are seen to bulge into the lumen and finally to become free. Kiyono and Nakanoin succeeded in staining these cells by injecting vital dyes into the chick embryo.

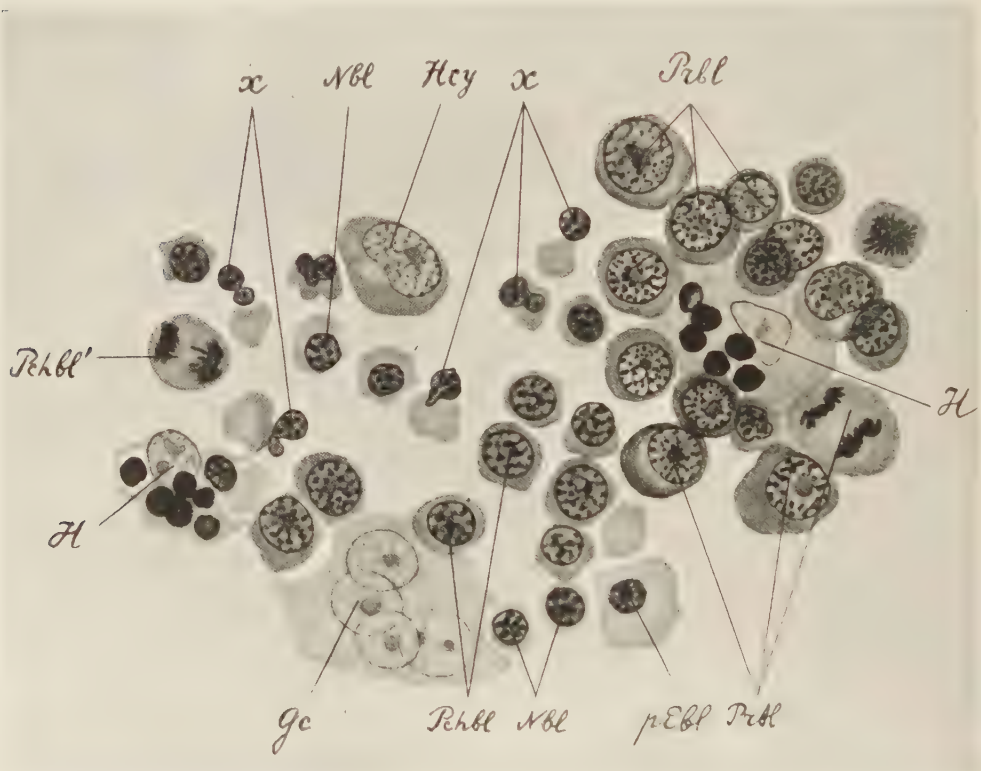

FIG. 203.—Cells from the lumen of a yolk sac vessel of a cat embryo of 10 mm. H, endothelial phagocytes (histiocytes, macrophages) with engulfed erythrocytes and their nuclei; Gc, multinucleated giant cell; Hcy, hemocytoblast; pEbl, primitive erythroblasts; Prbl, procrythroblasts; Pchbl, polychromatic erythroblasts; Pchbl', same cells in mitosis; Nbl, normoblasts; x, normoblasts extruding nuclei. Whole mount of yolk sac wall. Zenker-formol fixation. Hematoxylin-eosin-azure. Zeiss apochr. hom. imm. 2 mm, comp. oc. 8.

Similar cells arise in the early stages, before the beginning of hematopoesis in the liver, everywhere in the diffuse mesenchyme through contraction and isolation of fixed mesenchymal cells (Fig. 204hwc). Maximow (1907, 1909*a*) described them as "histioid" wandering cells. They are comparable to the free macrophages of the adult connective tissue.

At first these free histiocytes in the blood and in the mesenchyme remain undifferentiated and keep their full mesenchymal potencies. Accordingly they cannot as yet be sharply separated from the hemocytoblasts or the "lymphocytoid wandering cells" of the mesenchyme and mutual transformation between these elements is possible. The best proof of the undifferentiated condition of the histiocytes at this time is the fact that

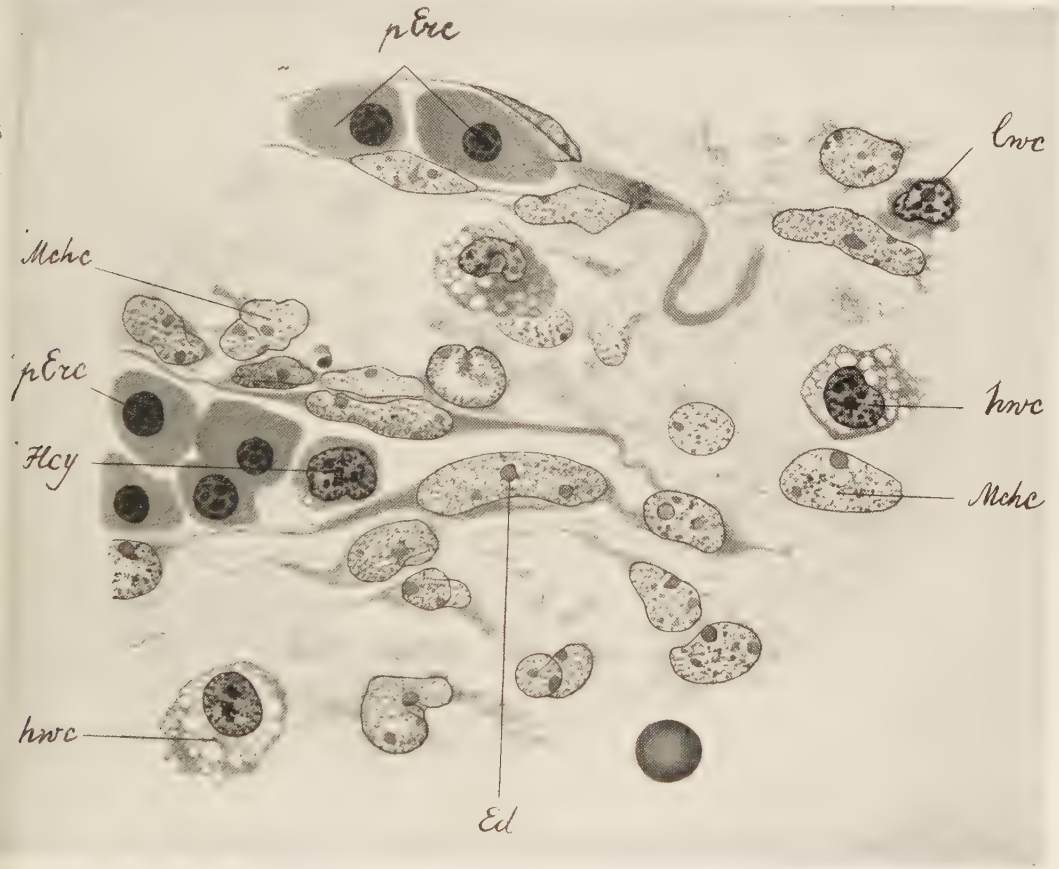

FIG. 204.—Mesenchyme from head of a human embryo of 20 mm. Mchc, mesenchymal cells; pErc, primitive erythrocytes in capillaries; Ed, endothelium; Hcy, intravascular hemocytoblast; lwc, lymphocytoid wandering cell; hwc, histioid wandering cells (free histiocytes, macrophages). Zenker formol fixation; hematoxylin eosin azure. Zeiss apochr. hom. imm. 2 mm, comp. oc. 8.

they as well as the lymphocytoid wandering cells (hemocytoblasts) of the mesenchyme indiscriminately produce blood elements —granulocytes and erythroblasts—diffusely scattered through the body in small foci. The endothelium of the blood vessels at this time has also not undergone any

differentiation and may continue for a while to give rise to new histiocytes through the same process of contraction and isolation, as in the common fixed mesenchymal elements. The primitive wandering cells of the mesenchyme, although keeping their potencies unrestricted and being virtually all identical, are highly polymorphous. Some of them may look more or less similar to monocytes.

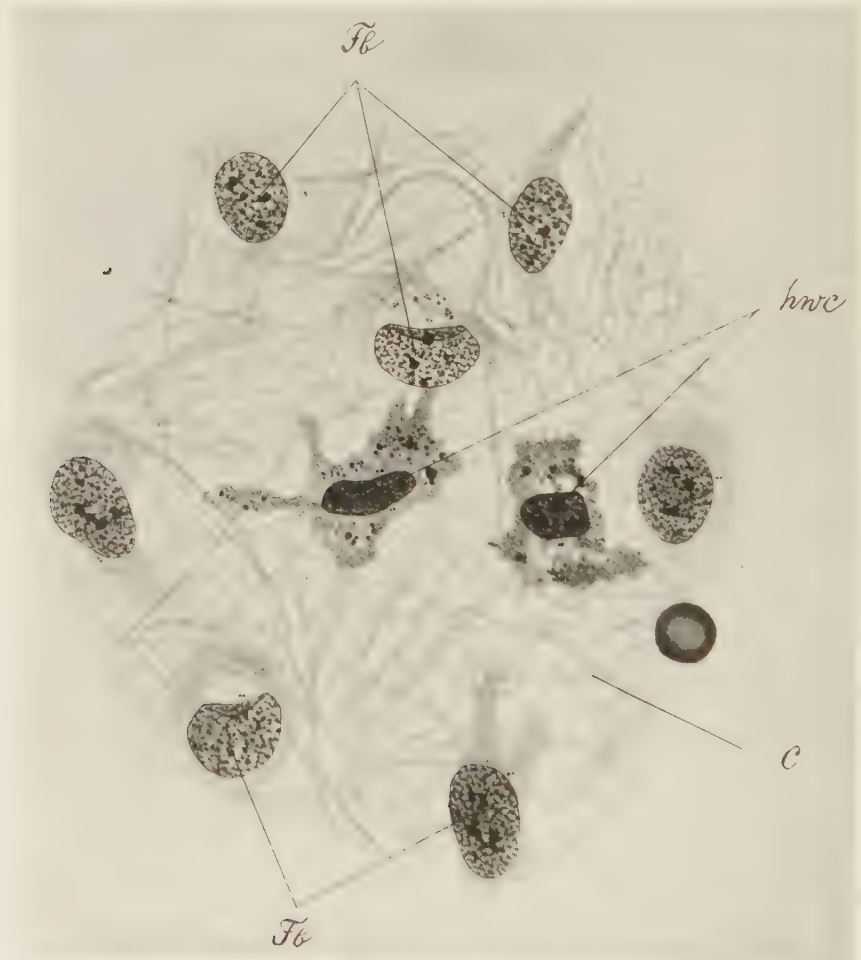

FIG. 205.—Intermuscular loose connective tissue from human embryo of 4½ months. Fb, fibroblasts; hwc, histioid wandering cells (histiocytes, macrophages); c, collagenous fibers. Zenker-formol fixation; Hematoxylin-eosin-azure. Zeiss apochr. hom. imm. 2 mm, comp. oc. 8.

In the later stages, when the majority of the fixed mesenchymal cells transforms into fibroblasts, the ubiquitous formation of new ameboid histio-

cytes from the fixed elements gradually subsides (rat embryo of 11 mm., guinea pig embryo of 20 mm., Alfejew, 1924); instead, an intense homoplastic mitotic proliferation of the existing ameboid histiocytes sets in. The heteroplastic neoformation of the latter continues only in places where mesenchymal cells remain in an undifferentiated condition, for instance in the immediate neighborhood of blood vessels. The same, of course, continues

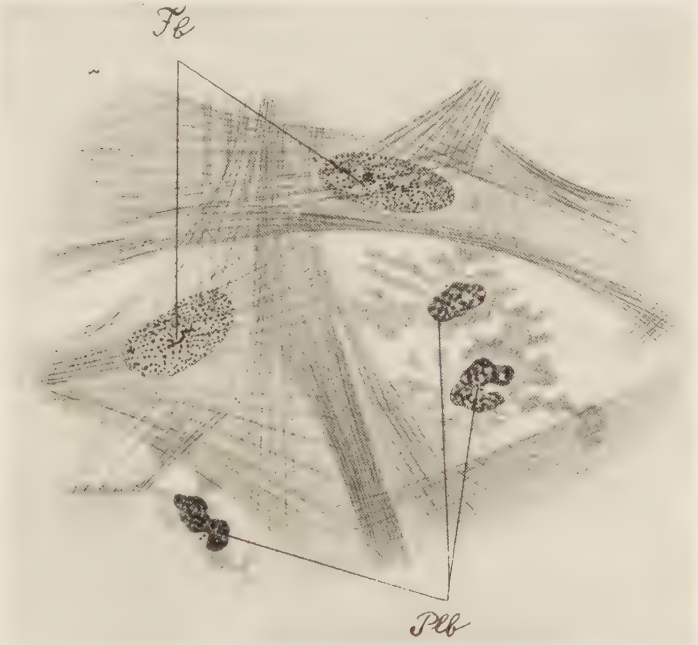

FIG. 206.—Scar tissue from capsule surrounding a foreign body introduced into loose subcutaneous tissue of rabbit 7 months previously. Fb, fibroblasts with tonofibrils; Plb, resting polyblasts (resting wandering cells, histiocytes). Zenker-acetic fixation; Iron hematoxylin. Zeiss apochr. hom. imm. 2 mm, comp. oc. 8. (After Maximow, 1903.)

for the whole life on a large scale in the localized areas of the connective tissue, which become the primordia of blood forming organs—bone marrow, lymph nodes and spleen.

In embryos of late stages the loose connective tissue, especially between the superficial muscles, contains very large numbers of highly ameboid proliferating histiocytic macrophages with pale vacuolated protoplasm and a small, excentrically located nucleus with irregular, wrinkled outlines (Fig. 205hwc). Whereas these cells in the early stages were endowed with the same potencies of development as the lymphocytoid hemocytoblastic wandering cells, they seem now to have lost a part of their potencies—they no longer produce blood cells and cannot transform themselves into hemocytoblasts; whereas the opposite (their occasional development from hemo-

cytoblasts) of course, remains possible. They can now be looked upon as true free histiocytes or macrophages. In tissue cultures they behave exactly as do the histiocytes of the adult organism; they store vital dyes.

With the appearance of these free histiocytes the original stock of fixed mesenchymal cells in the diffuse connective tissue definitively splits into three cell lineages—the elements keeping for ever their embryonic undifferentiated condition, the fibroblasts and the histiocytes.

The ultimate fate of the motile histiocytes scattered through the embryonic connective tissue varies. Some of them remain motile forever. They have been described above in the loose connective tissue of the adult as macrophages or free histiocytes. They may at any time enter the blood or lymph, or penetrate into the serous cavities (Alfejew, 1924) or into the ventricles of the brain (Alfejew, 1924). The majority of them, however, transform themselves gradually into resting elements. Their movements become slower and finally subside, the cell flattens or stretches and develops —especially in the omentum—long, branched, fixed processes with sharp, indented outlines. In the omentum they arrange themselves especially around the blood vessels, while in the common loose connective tissue they are more evenly distributed and do not show any particular predilection for blood vessels (Alfejew, 1924). The pictures remind one of the transformation of ameboid inflammatory macrophages, of the polyblasts, into resting polyblasts during scar formation (Maximow, 1902) (Fig. 206Plb).

In this way the active, histiocytic, embryonic wandering cells furnish the resting wandering cells or fixed histiocytes of the loose connective tissue. Some of these histiocytes can develop directly from fixed mesenchymal cells; in this case the motile stage is skipped.

In older embryos and in newborn mammals many resting wandering cells acquire more or less the aspect of fibroblasts. The same phenomenon has been observed by Maximow (1902) in the latest stages of productive inflammation and in tissue cultures (1923*a*) (Fig. 207).

The reticulum of the blood-forming organs develops in localized areas of the mesenchyme from an original mesenchymal cellular, net-like syncytium. Part of these cells remains forever in undifferentiated condition; part gives rise to hemocytoblasts (lymphocytes); part transforms into free or fixed histiocytes the reticular cells described above. Simultaneously the cellular syncytium produces a network of fibers.

The endothelial cells of the blood vessels in the earliest stages of embryogenesis are to be looked upon merely as flattened mesenchymal cells. In this undifferentiated condition they can, of course, give rise to hemocytoblasts and, implicitly, blood elements, to free histiocytes (macrophages) or any other type of cells of mesenchymal origin, found at this time in the body.

In the later stages the prospective potencies of the blood vessel endothelium become more and more restricted. The actual moment of this

change cannot be recognized in every case, because the histological aspect of the cells may not undergo distinct changes. We can judge of the condition of the endothelium only by the results of its cytopoetic activity.

In certain sections of the vascular system, however, the liver, the spleen, the bone marrow, etc., the endothelium of the venous capillaries, does not

FIG. 207.—Tissue culture of lymph node of rabbit (6 days). A large histiocyte (reticular cell), flattened on the surface of the coverslip and assuming the character of a fibroblast. Zenker formol fixation; eosin-azure. Zeiss apochr. hom. imm. 2 mm., comp. oc. 8. (After Maximow, 1923.)

attain the same grade of differentiation, as in the common blood vessels. It certainly very early loses the hemopoetic potency and hemocytoblasts and blood cells can no longer arise from it. But its elements transform themselves into histiocytes, into the "littoral cells" of the histiocytic system described above. At the same time, in the bone marrow and the spleen, the surrounding mesenchymal cells build up the histiocytic reticulum, which forever remains inseparably connected with the littoral elements.

XII. THE GENETIC RELATIONSHIPS BETWEEN THE HISTIOCYTES AND THE OTHER ELEMENTS OF THE CONNECTIVE TISSUE AND THE BLOOD AND THEIR PROSPECTIVE POTENCIES

All elements of the connective tissue and the blood can be separated into three large groups: (1) the fibrocytes or fibroblasts, including the endothelium; they are fixed elements, elaborating the intercellular substances or lining the walls of the vessels; (2) the histiocytes, elements playing a leading rôle in the local and general defense reactions; (3) the hemocytes, the blood cells, which circulate in the blood and lymph and whose functions are for the most part unknown.

The relations between these cells are especially manifest under abnormal conditions; they are best observed in inflammation and in tissue culture.

The changes undergone by the fixed histiocytes in inflammation and in vitro are very definite and do not differ, whether the tissue affected is common loose tissue, or omentum, or myeloid, or lymphoid tissue, or liver, etc. They are mobilized, contract and isolate themselves as free cells from the surrounding structures. Thus, they furnish a part of the "mononuclear exudate cells" or polyblasts of the inflamed tissue or a part of the polyblasts or macrophages which are found in abundance in cultures of connective tissue of any origin. These mobilized histiocytes are very active as phagocytes and store colloidal vital dyes in vivo and in vitro in granular form.

The development of the inflammatory macrophages, the polyblasts, from mobilized local histiocytes is an established fact. It can easily be observed in the living condition in tissue cultures (Fig. 197).

The old idea of the possibility of a transformation of fibroblasts into polyblastic macrophages has been recently revived by W. and M. v. Möllendorff (1926). Their arguments, however, have been criticized by Maximow (1926). According to this author the typical fibroblasts are highly differentiated elements, incapable of producing other cell types. The connective tissue contains numerous undifferentiated mesenchymal cells, especially arranged along the capillaries (for instance in the omentum) and these cells, of course, can produce any type of connective tissue or blood cells and in inflammation and tissue culture indeed are often seen to function as an additional local source of polyblasts (macrophages). Fischer (1927) describes development of macrophage-like cells from embryonic fibroblasts of the chick in tissue cultures. Here again the embryonic character of the fibroblasts may possibly account for the macrophage formation.

According to a widespread opinion the endothelium of the common blood vessels is endowed with a very large amount of cytopoetic and especially hemocyto- and histiocytopoetic potencies. The relation between endothelium and monocytes has been discussed above.

McJunkin (1919) and Foot (1919, 1920*a*, *b*, 1921*a*, *b*, 1922, 1923, 1925) tried to demonstrate this with the aid of a special technique—the intravenous injection of India ink. The carbon is phagocytized by the endothelium and the "labeled" endothelial cells were found to transform themselves under the influence of various stimuli into ameboid phagocytic elements. F. Herzog (1924, 1925) claimed to have observed the same in the living tongue of the frog. Marchand, who previously (1898, 1902) derived the polyblasts of the inflamed omentum from his so-called "adventitial cells," i.e., perivascular histiocytes, lately (1921, 1924 *a*, *b*) traced them back to the endothelium. G. Herzog (1921, 1922, 1923) describes the transformation of endothelium not only into histiocytes, but also into various blood cells and many other cell types, including smooth muscle cells, osteoblasts etc. Sabin, Doan and Cunningham (1925) believe that the "clasmatocytes," i.e., the histiocytes, originate from the endothelium. Oeller (1923, 1925), Siegmund (1925), Töppich (1925, 1926) and many others found formation of macrophages from endothelium in allergic reaction. The list of the advocates of an endothelial origin of histiocytes could be prolonged still further.

Maximow (1902, 1909*b*), on the contrary, has always defended the viewpoint, that the endothelium of the common blood vessels is a highly differentiated tissue, and that it is unable to furnish ameboid and phagocytic elements. The only new cell type the endothelial elements can produce is fibroblasts. This can be often observed in inflammation (Maximow, 1905) and in tissue cultures as well (Maximow, 1916, 1922, 1923*a*). In living cultures of the leptomeninges the endothelium is seen to grow out of the severed ends of the small arteries in the form of long bundles of transparent, slender, spindle-shaped cells. They gradually move away from each other, develop side processes and after two to three days cannot be distinguished from typical fibroblasts (Maximow, 1925*a*). They never store vital dyes and never transform themselves into ameboid elements, whereas the surrounding tissue under the same condition produces large quantities of carmine-storing polyblasts.

The findings of Foot and F. Herzog were recently controlled by Lang (1926*c*) and Stilwell (1926). These experimenters were unable to confirm the results quoted above. The carbon-containing endothelial cells do not turn into ameboid histiocytic elements in inflammation. The carbon particles pass through the intact endothelial membrane and are taken up by perivascular elements of embryonic or histiocytic nature. These may then assume the character of macrophages. The production of macrophages by the lung endothelium, claimed by Permar (1924) and others, was not confirmed by Aschoff (1924) and Lang (1925, 1926*a*). W. H. Lewis (1926*a*, *b*) in his recent investigations on aseptic inflammation also denies the rôle of endothelium in the production of macrophages.

The presumed endothelial cytopoetic allergic reaction of the lungs in the experiments of Töppich (1925, 1926), Oeller (1923, 1925) and Siegmund (1925, 1926) has also not met with general recognition. It is far more probable that the pictures they saw in their material were due to local intravascular accumulations of white blood corpuscles.

An important question is the problem of the prospective potencies of development in the histiocytes.

As has been mentioned, it is easy to demonstrate the transformation of fixed histiocytes into ameboid polyblasts or macrophages in inflammation, in generalized infections and in tissue culture (Fig. 197). All types of polyblasts which play an important rôle in general and local defense reactions—epithelioid cells, giant cells of the foreign body or tuberculous variety, pus phagocytes, free blood macrophages, etc.—can be traced back to them. This, of course, does not exclude the possibility of another origin of the same active phagocytic elements; a large part of the mammalian polyblasts in aseptic or purulent inflammation (Maximow, 1902, 1905), in the tuberculous process (Maximow, 1924*b*, 1925*b*) and in tissue cultures (Maximow, 1925*a*, 1927*a*; Bloom, 1927) originates from lymphocytes and monocytes.

When the stimuli which have caused the mobilization of the histiocytes and their transformation into polyblasts disappear, the active cells gradually assume a quiescent character. They flatten, develop long, not motile, branched processes and transform into resting wandering cells, that is, into fixed histiocytes (Fig. 206plb). In this condition they keep their inherent capacity for ameboism and phagocytosis and whenever a new stimulus arises, they again undergo mobilization.

In the late stages of scar formation the fixed, histiocytic polyblasts may transform themselves into typical fibroblasts (Maximow, 1902). This can be reproduced in tissue cultures (Maximow, 1923*a*, 1927*a*) (Fig. 207).

The described reactions of the histiocytes in tissue cultures have been recently confirmed by N. Chlopin (1925) and N. Chlopin and A. Chlopin (1925) for the histiocytes of the cold blooded vertebrates.

Whereas the polyblastic and fibroblastic potencies of the histiocytes are proved beyond doubt, and a part of the monocytes, as has been already discussed, may also originate from them, their capacity for producing hemocytoblasts, lymphocytes and other blood cells, i.e., their full mesenchymal potency, is doubtful.

Marchand has always claimed (1898, 1902) that in inflammation not only polyblasts, but also lymphocytes and plasma cells can originate through mitotic proliferation of adventitial cells (perivascular histiocytes). Marchand's student, G. Herzog (1916, 1921) went still farther—he asserts that even granulocytes arise from histiocytes and endothelial cells. Ferrata (1918, 1921) and his school in a long series of publications have developed the theory of the so-called "hemohistioblasts." These elements,

as has been mentioned, are nothing but ordinary storing and phagocytizing "clasmatocytoid" histiocytes; the Italian authors ascribe to them extraordinary cytopoetic potencies; a concept somewhat similar to G. Herzog's idea of the omnipotence of the vascular endothelium. The hemohistioblasts are supposed to produce all kinds of blood cells and they are even considered as the first primitive blood cells of the embryo. According to Siegmund (1923*a*) and Dieckmann (1922) blood cells in extramedullary hemopoesis originate from histiocytes (cells of v. Kupffer in the liver). Similar conclusions have been reached by Paschkis (1926*b*), Hoff (1927), R. Jaffé (1927) and others. Maximow (1924*a*) in his review on the relations between blood cells and connective tissue elements also temporarily adopted the idea of the hemopoetic activity of the histiocytes as embryonic, undifferentiated elements. N. Chlopin (1924) and N. Chlopin and A. Chlopin (1925), who studied the transformations of the reticulum of the marginal layer in the liver of the axolotl in vitro, believe its phagocytic elements to furnish not only polyblasts and fibroblasts, but also lymphocytes and myeloid blood cells. Volterra (1925) considers especially the perivascular histiocytes as undifferentiated mesenchymal elements.

Recent investigations of the author and his collaborators seem to discredit this idea of the embryonic nature of the histiocytes. That the small lymphocytes in inflammation arise not through proliferation of local histiocytes (resting wandering cells), but through migration from the vessels, has been shown by Maximow in 1902. The neoformation of lymphocytes in the germ centers, as can be seen in carminized animals, originates not from the phagocytic, storing histiocytes, but from the elements of the reticular syncytium which do not store the vital dye and are to be looked upon as embryonic elements. The same is true for the formation of myelocytes in the germ centers in extramedullary myelopoesis (Lang, 1926*b*).

It seems, therefore, that no valid proofs have been abduced for the embryonic character and especially for the hemopoetic ability of the histiocytes. Thus—in accordance with Kiyono and Nakanoin (1919)—the histiocytes have to be looked upon as elements which have undergone a certain degree of differentiation. They, as well as the polyblasts, possess, of course, larger potencies of development than the fibroblasts and the endothelium. They may turn into fibroblasts, eventually perhaps even into fat cells (Maximow, 1903); but they cannot act as stem cells for hemopoesis.

As a part of the polyblasts in inflammation originates from lymphocytes which in the unitarian theory are embryonic cells, it has to be assumed, that parallel with the development of the capacity of phagocytosis, of storing, of antibody formation, etc., the original potencies of the embryonic mesenchymal cells are of necessity becoming restricted; the first of these to be lost is the hemopoetic potency. The same must be true for the monocytes which as a rule also originate from embryonic cells, the lymphocytes.

The potencies of the monocytes are probably identical with the potencies of the histiocytes.

XIII. THE HISTIOCYTES IN THE LOWER VERTEBRATES

The lower vertebrates also possess histiocyte-like elements in their diffuse connective tissue, but they have not been studied sufficiently.

The loose connective tissue of the birds contains very large quantities of ameboid elements of various kinds and also resting wandering cells (Solucha, 1908; Kiyono and Nakanoin, 1919; Mjassojedoff, 1926); transitions between the active and resting histiocytes are very numerous. Eberhardt (1907–8) has shown, that in the loose connective tissue of the reptiles elements are present which correspond to the resting wandering cells of the mammals. Similar cells in the amphibians have been studied by Maximow (1906*a*) and Benninghoff (1923). In these animals the transitions between them and the ameboid elements on the one hand and the fibroblasts on the other hand are especially numerous. The histiocytes of the connective tissue of the amphibians store acid colloidal aniline dyes and carmine very slowly and never in such an elective way as is typical for the mammals (Wislocki, 1916; McClure, 1918; Ssyssojew, 1924). Maximow (1923*b*) found resting wandering cells in the loose connective tissue of the selachians. The experiments of Wislocki (1917) who tried to stain these cells intravitally in the teleosts, gave indefinite results.

In invertebrates the so-called "nephrophagocytes" probably correspond to the histiocytes of the vertebrates.

XIV. THE FUNCTIONAL PROPERTIES OF THE HISTIOCYTES

The similar structure of the various types of histiocytes is accompanied by many fundamental functional activities common to all of them.

The phagocytosis and storing of colloidal substances have already been discussed. All histiocytes are furthermore endowed with the potency of ameboid movements which manifests itself as a reaction to stimuli, acting upon the cells. The most important activity, however, is displayed by the histiocytes in the domains of metabolism and defense reactions (Aschoff, 1924; Schittenhelm, 1925). The phenomena of phagocytosis and of storing of colloids are intimately connected with it.

It has been shown by Kiyono (1914) and others that the histiocytes may simultaneously ingest and accumulate in their body different substances. If two different dyes are acting upon the cells, usually granules of two different colors appear in the protoplasm; granules of a mixed hue are rare.

In connection with this the problem of the so-called blockade of the histiocytic system arises. It has been shown, that through excessive saturation with a certain substance, the ability of the histiocytes to absorb another substance or to perform a certain function may be impaired (Lepehne, 1918; Nissen, 1922; Bieling and Isaac, 1921, 1922; Elek, 1924; Natali, 1925 and others). Sometimes the opposite occurs and the storing capacity is reduced or suspended because of other simultaneous demands exacted of these cells, as for instance, through immunization with strepto-

coccus vaccine (Paschkis, 1924). A local blockade of a restricted area of histiocytes seems also to be possible (Kusnetzowsky, 1923, Katsunuma and Sumi, 1924). However, it has been shown (Schulemann, 1912), that histiocytes, containing a large amount of a vital dye, such as carmine, still are able to engulf in the usual way other substances, as India ink. Thus, the problem of the histiocytic blockade is still unsettled. It seems, moreover, that blocked histiocytes can rapidly recover without displaying any distinct histological changes (Jungeblut and Berlot, 1926).

The histiocytes filled with certain substances can have various fates in the body. If the substance is intracellularly digestible, it may change its condition and disappear after a certain time; carmine granules acquire a yellow or black color. The soluble products are excreted by the organism and the cells regain their former status. In some cases the stored substance is supposed to be transferred to other cells; carmine for example passes from the v. Kupffer cells into the liver cells according to Schittenhelm and Erhardt (1925). Many storing histiocytes degenerate and disintegrate. Their inclusions then are set free, may be carried away by the lymph or blood and may be taken up by other histiocytes.

In cases where the histiocytes store indigestible substances, as colloidal silver or carbon, the process of "purification" of the histiocytic system is slow and complicated (Kiyono, 1914; Aschoff, 1924). The inclusions remaining in the cells may be freed through the disintegration of the same; they may be transported to various other places in the body and finally eliminated probably through the respiratory passages or the intestine.

The histiocytes play an important rôle in the hemoglobin and iron metabolism. They phagocytize and digest worn-out erythrocytes; they are believed to absorb and transform dissolved hemoglobin. As a result of these processes they may contain pigment, which gives the iron reaction. Furthermore, many investigators believe that the histiocytes, especially in the liver, elaborate bile pigment (McNee, 1913*a*, *b*; Lepehne, 1918, 1919; Bieling and Isaac, 1922; Eppinger, 1922). Rich (1924) succeeded in watching this process in living tissue cultures.

Anitschkow (1914*a*, *b*), Zinserling (1923), Schönheimer (1924) and others have demonstrated the rôle of the histiocytes in the metabolism and storing of fats and lipoids. It is known that through feeding animals with cholesterol the histiocytes all over the body can be filled with large quantities of droplets of anisotropic cholesterol esters.

The enzyme and antibody producing activity of the histiocytes has been claimed by many investigators. Their active rôle in the defense reaction against infections is illustrated best by their behavior in tuberculosis and leprosy, where they form the majority of the epithelioid phagocytizing cells. The behavior of the histiocytes in local defense reactions, in inflammation, has been already discussed.

XV. BIBLIOGRAPHY

Alfejew, S. 1924. Die embryonale Histogenese der Zellformen des lockeren Bindegewebes der Säugetiere. *Fol. haematol. Archiv*, **30**, 111.

Anitschkow, N. 1914*a*. Ueber experimentell erzeugte Ablagerungen von anisotropen Lipoidsubstanzen in der Milz und im Knochenmark. *Beitr. z. path. Anat. u. z. allg. Path.*, **57**, 201.

—— 1914*b*. Experimentelle Untersuchungen über die Ablagerung von Cholesterinfetten im subkutanen Bindegewebe. *Arch. f. Dermatol. u. Syph.*, **120**, 627.

Aschoff, L. 1913. Ein Beitrag zur Lehre von den Makrophagen. *Verhandl. d. deutsch. path. Gesellsch.*, **16**, 107.

—— 1924. Das reticulo-endotheliale System. *Ergebn. d. inn. Med. u. Kinderheilk.*, **26**, 1.

—— 1925. Morphologie des reticuloendothelialen Systems. In *Handb. d. Krankh. d. Blutes u. d. blutbild. Organe*, herausg. von A. Schittenhelm, Pt. 2, 473, Berl.: Julius Springer.

—— 1926. Bemerkungen zur Physiologie des Lungengewebes. *Ztschr. f. d. ges. exper. Med.*, **50**, 52.

Aschoff, L., and Kiyono, K. 1913. Zur Frage der grossen Mononucleären. *Fol. haematol. Archiv*, **15**, 383.

Awrorow, P., and Timofejewsky, A. 1914. Kultivierungsversuche von leukämischem Blute. *Virchow's Archiv*, **216**, 184.

Babkina, H. 1910. *The changes of the blood forming organs in aseptic inflammation.* Inaug. Diss. St. Petersburg (Russian); rev. in *Fol. haematol. Zentralorg.*, **11**, 202.

Benninghoff, A. 1923. Beobachtungen über Umformungen der Bindegewebszellen. *Arch. f. mikr. Anat. u. Entwicklungsmech.*, **99**, 571.

Benthin, W. 1923. Gibt es eine interstitielle Eierstocksdrüse? *Arch. f. Gynaekol.*, **120**, 227.

Bieling, R., and Isaac, S. 1921. Experimentelle Untersuchungen über intravitale Hämolyse. I. Der Mechanismus der intravitalen Hämolyse nach Injektion von hämolytischem Immunserum. *Ztschr. f. d. ges. exper. Med.*, **25**, 1.

—— 1922. Experimentelle Untersuchungen über intravitale Hämolysen. II. Der Verlauf der intravitalen Hämolyse nach Milzextirpation. *Ibid.*, **26**, 251.

Bittorf, A. 1920. Endothelien im strömenden Blute und ihre Beziehungen zu hämorrhagischer Diathese. *Deutsch. Arch. f. klin. Med.*, **133**, 64.

Bloom, W. 1925. Splenomegaly (type Gaucher) and lipoidhistiocytosis (type Niemann). *Am. J. Pathol.*, **1**, 595.

—— 1927. The transformation of the lymphocytes of the thoracic duct of the rabbit into polyblasts (macrophages) in tissue culture. *Proc. Soc. Exper. Biol. and Med.*, **24**, 567.

Boerner-Patzelt, D. 1925. *Morphologie und Histogenese des reticulo-endothelialen Systems. Das Reticuloendothel. Sammelbericht über den gegenwärtigen Stand der Forschungsergebnisse.* Leipz.: G. Thieme.

Bouffard. 1906. Injection des couleurs de benzidine aux animaux. *Ann. de l'Inst. Pasteur*, **20**, 539.

Carrel, A., and Ebeling, H. 1922. Pure cultures of large mononuclear leukocytes. *J. Exper. Med.*, **36**, 365.

Chlopin, N. 1925. Studien über Gewebskulturen im artfremden Blutplasma. I. Allgemeines. II. Das Bindegewebe der Wirbeltiere. *Ztschr. f. mikroskop. anat. Forsch.*, **2**, 324.

Chlopin, N., and Chlopin, A. 1925. Studien über Gewebskulturen im artfremden Blutplasma. *Arch. f. exper. Zellforsch., bes. Gewebezüchtung (Explantation)*, **1**, 193.

Cunningham, R. S., Sabin, F. R., and Doan, C. A. 1925. The development of leukocytes, lymphocytes and monocytes from a specific stem cell in adult tissue. *Contrib. to Embryol.* Carnegie Inst., Wash., **16**, 227.

Dieckmann, H. 1922. Histologische und experimentelle Untersuchungen über extramedulläre Blutbildung. *Virchow's Archiv*, **239**, 451.

Dominici, H. 1902. Polynucléaires et macrophages. *Arch. de méd. exper. et d'anat. path.*, **14**, Sér. 1, 1.

——— 1920–21. Études sur le tissu conjonctif et les organes hématopoïétiques des mammifères. *Arch. d'anat. micr.*, **17**, Ser. 1, 3.

Downey, H. 1915. The so-called "endothelioid" cells. *Anat. Record*, **9**, 73.

——— 1922. The structure and origin of the lymph sinuses of mammalian lymph nodes and their relations to endothelium and reticulum. *Haematologica*, **3**, 431.

Downey, H., and Weidenreich, F. 1912. Ueber die Bildung der Lymphocyten in Lymphdrüsen und Milz. IX. Fortsetzung der "Studien über das Blut und die blutbildenden und- zerstörenden Organe" von F. Weidenreich. *Arch. f. mikrosk. Anat.*, **80**, 306.

Dubreuil, G. 1913. Le chondriome et le dispositif de l'activité sécrétoire aux différents stades du développement des éléments cellulaires de la lignée connective, descendants du lymphocyte (globules blancs mononucléés de la lymphe et du sang, cellules connectives cartilagineuses et osseuses). *Arch. d'anat. microsc.*, **15**, 53.

Eberhardt, J. 1907–08. On the cell types of the blood and connective tissue of the turtle in normal conditions and in inflammation. Inaug.-Diss. St. Petersburg, (Russian); rev. in *Fol. haematol.*, Zentralorg., **8**, 228.

v. Ebner, V. 1902. A. Koelliker's *Handbuch der Gewebelehre des Menschen*. Ed. 6, **3**, Leipz.: W. Engelmann.

Elek, L. 1924. Experimentelle Untersuchungen über das reticulo-endotheliale System. *Klin. Wchnschr.*, **3**, 143.

Eppinger, H. 1922. Das reticulo-endotheliale System. *Wien. klin. Wchnschr.*, **35**, 333.

Evans, H. 1915. The macrophages of mammals. *Am. J. Physiol.*, **37**, 243.

Evans, H., Bowman, F., and Winternitz, M. 1914. An experimental study of the histogenesis of the miliary tubercle in vitally stained rabbits. *J. Exper. Med.*, **19**, 283.

Evans, H., and Schulemann, W. 1915. Ueber Natur und Genese der durch saure Farbstoffe entstehenden Vitalfärbungsgranula. *Fol. haematol., Archiv*, **19**, 207.

Evans, H., and Scott, K. 1921. On the differential reaction to vital dyes exhibited by the two great groups of connective tissue cells. *Contrib. to Embryol.* (Carnegie Inst., Wash., **10**, 1.

Ferrata, A. 1918. *Le Emopatie*. Milano: Società Editrice Libraria.

——— 1921. Studi sulle emopatie. I. Sulla istogenesi della leucemia granulocitica, *Haematologica*, **2**, 242.

Fischer, A. 1925. Sur la transformation, in vitro, des gros leucocytes mononucléaires en fibroblastes. *Compt. rend. Soc. de biol.*, **92**, 109.

——— 1927. Umwandlung von Fibroblasten zu Makrophagen in vitro. *Arch. f. exper. Zellforsch., bes. Gewebezüchtung (Explantation)*, **3**, 345.

Foot, N. 1919. Studies on endothelial reactions. I. The macrophages of the loose connective tissue. *J. Med. Research*, **40**, 353.

——— 1920*a*. Studies on endothelial reactions. II. The endothelial cell in experimental tuberculosis. *J. Exper. Med.*, **32**, 513.

——— 1920*b*. Studies on endothelial reactions. III. The endothelium in experimental pulmonary tuberculosis. *Ibid.*, **32**, 533.

——— 1921*a*. Studies on endothelial reactions. IV. The endothelium in experimental general miliary tuberculosis in rabbits. *Ibid.*, **33**. 271.

Foot, N. 1921*b*. Studies on endothelial reactions. v. The endothelium in the healing of aseptic wounds in the omentum of rabbits. *Ibid.*, **34**, 625.

——— 1922. Studies on endothelial reactions. vi. The endothelial response in experimental tuberculous meningoencephalitis. *Ibid.*, **36**, 607.

——— 1923. Studies on endothelial reactions. vii. Changes in the distribution o colloidal carbon noted in the lungs of rabbits following splenectomy. *Ibid.*, **37**, 139.

——— 1925. The endothelial phagocyte. A critical review. *Anat. Record*, **30**, 15.

Goldmann, E. 1909. Die äussere und innere Sekretion des gesunden und kranken Organismus im Lichte der "vitalen Färbung," Teil i. Bruns's *Beitr. z. klin. Chir.*, **64**, 192.

——— 1911. Studien zur Biologie der bösartigen Neubildungen, *Ibid.*, **72**, 1.

——— 1912. Neue Untersuchungen über die äussere und innere Sekretion des gesunden und kranken Organismus im Lichte der "vitalen Färbung." *Ibid.*, **78**, 1.

——— 1913. Der Verdauungsvorgang im Lichte der vitalen Färbung. *Verhandl. d. deutsch. Kongr. f. inn. Med.*, 30 Kongr., Wiesbaden.

Heidenhain, M. 1911. *Plasma und Zelle. Eine allgemeine Anatomie der lebendigen Masse.* 2. Lief. Jena: G. Fischer.

Herzog, F. 1924. Endothelien der Froschzunge als Phagocyten und Wanderzellen. *Ztschr. f. d. ges. exper. Med.*, **43**, 79.

——— 1925. Ueber Beziehungen zwischen Dilatation, Durchlässigkeit und Phagozytose an den Capillaren der Froschzunge. *Virchow's Archiv*, **256**, 1.

Herzog, G. 1916. Experimentalle] Untersuchungen über die Einheilung von Fremdkörpern. *Beitr. z. path. Anat. u. z. allg. Path.*, **61**, 377.

——— 1921. Zur Frage der Granulocytenbildung bei der Entzündung. *Zentralbl. f. allg. Path. u. path. Anat.*, **31**, 481.

——— 1922. Zellformen bei Meningoencephalitis. *Ibid.*, **33**, 228.

——— 1923. Ueber die Bedeutung der Gefässwandzellen in der Pathologie. *Klin. Wchnschr.*, **2**, 684.

Hess, F. 1922. Zur Herkunft der im strömenden Blut bei Endocarditis lenta vorkommenden Endothelien. *Deutsch. Arch. f. klin. Med.*, **138**, 330.

Hoff, F. 1927. Untersuchungen über das weisse Blutbild und seine biologischen Schwankungen. *Krankheitsforschung*, **4**, 89.

Holler, G. 1923. Studien über die Stellung der Monocyten im System der Blutzellen. *Fol. haematol.*, Archiv, **29**, 84.

Hynek, K. 1912. Zur Monocytenfrage. *Fol Haematol.* Archiv., **13**, 345.

Jaffé, R. H. 1922. Die Lehre von den Retikulo-Endothelien. *Wien. klin. Wchnschr.* **35**, 595.

——— 1927. Aleukemic myelosis. *Arch. Path. and Lab. Med.*, **3**, 56.

Jungeblut, C., and Berlot, J. 1926. The rôle of the reticulo-endothelial system in immunity. ii. The complement titer after blockade and the physiological regeneration of the reticulo-endothelial system as measured by reduction tests. *J. Exper. Med.*, **43**, 797.

Kartaschowa, F. 1925. Ueber Monocyten-Makrophagen im peripheren Blut bei einigen Infektionskrankheiten. *Deutsch. Arch. f. klin. Med.*, **146**, 226.

Katsunuma, S., and Sumi, K. 1924. Cellules réticulo-endothéliales et immunité locale. *Compt. rend. Soc. de biol.*, **91**, 1401.

Kaznelson, P. 1919. Seltene Zellformen des strömenden Blutes (Megakaryocyten, Histiocyten, Endothelen). *Deutsch. Arch. f. klin. Med.*, **128**, 131.

Kiyono, K. 1914. *Die vitale Carminspeicherung.* Jena: G. Fischer.

Kiyono, K., and Nakanoin, T. 1919. Weitere Untersuchungen über die histiocytären Zellen. *Acta schola med. univ. Imp. Kioto*, **3**, 55.

Kling, C. 1904. Studien über die Entwicklung der Lymphdrüsen beim Menschen. *Arch. f. mikr. Anat.*, **63**, 575.

v. Kupffer, C. 1876. Ueber Sternzellen der Leber. *Arch. f. mikr. Anat.*, **12**, 353.

——— 1899. Ueber die sog. Sternzellen der Säugetierleber. *Ibid.*, **54**, 254.

Kusnetzowsky, H. 1923. Ueber vitale Färbung von Bindegewebszellen bei Fettresorption. *Arch. f. mikr. Anat.*, **97**, 32.

Landau, M., and McNee, J. 1914. Zur Physiologie des Cholesterinstoffwechsels. *Beitr. z. path. Anat. u. z. allg. Path.*, **58**, 667.

Lang, F. 1925. The reaction of lung tissue to tuberculous infection in vitro. *J. Infect. Dis.*, **37**, 430.

——— 1926*a*. Ueber Gewebskulturen der Lunge. *Arch. f. exper. Zellforsch., bes. Gewebezüchtung (Explantation)*, **2**, 93.

——— 1926*b*. Experimentelle Untersuchungen über die Histogenese der extramedullären Myelopoese. *Ztschr. f. mikroskop. anat. Forsch.*, **4**, 417.

——— 1926*c*. Rôle of endothelium in the production of polyblasts (mononuclear wandering cells) in inflammation. *Arch. Path. and Lab. Med.*, **1**, 41.

Lepehne, G. 1918. Milz und Leber. Ein Beitrag zur Frage des hämatogenen Ikterus, zum Hämoglobin- und Eisenstoffwechsel. *Beitr. z. path. Anat. u. z. allg. Path.*, **64**, 55.

——— 1919. Zerfall der roten Blutkörperchen beim Icterus infectiosus (Weil). Ein weiterer Bietrag zur Frage des hämatogenen Ikterus, des Hämoglobin- und Eisenstoffwechsels. *Ibid.*, **65**, 163.

Letterer, E. 1924. Aleukämische Retikulose (ein Beitrag zu den proliferativen Erkrankungen des Retikuloendothelialapparates). *Frankfurt. Ztschr. f. Path.*, **30**, 377.

Lewis, M. 1925*a*. The formation of macrophages, epithelioid cells and giant cells from leukocytes in incubated blood. *Am. J. Path.*, **1**, 91.

——— 1925*b*. Origin of the phagocytic cells of the lung of the frog. *Bull. Johns Hopkins Hosp.*, **36**, 361.

Lewis, W. 1926*a*. Macrophages of the deep fascia of the thigh of the rat in spreads supravitally stained with neutral red and with janus green. (Amer. assoc. of anat., 42 Sess., New Haven.) *Anat. Record*, **32**, 215.

——— 1926*b*. Macrophages in sterile inflammation of the deep fascia of the rat. (Amer. assoc. of anat., 42 Sess., New Haven) *Ibid.*, **32**, 215.

Lubarsch, O. 1921. Zur Kenntnis des Makrophagen (reticulo-endothelialen) Systems. *Verhandl. d. deutsch. path. Gesellsch.*, 18 Tag., 63.

McClure, C. 1918. *On the behavior of bufo and rana toward colloidal dyes of the acid azo group.* Am. Anat. Mem., No. 8. The Wistar Inst. of Anat. and Biol., Phila.

McJunkin, F. 1919. The origin of the phagocytic mononuclear cells of the peripheral blood. *Am. J. Anat.*, **25**, 27.

——— 1925*a*. The origin of the mononuclear phagocytes of peritoneal exudates. *Am. J. Path.*, **1**, 305.

——— 1925*b*. Identification of three types of mononuclear phagocytes in the peripheral blood. *Arch. Intern. Med.*, **36**, 799.

——— 1926. Supravital staining of cultures of lymph node and liver endothelia. *Arch. f. exper. Zellforsch., bes. Gewebezücht. (Explantation)*, **3**, 166.

McNee, J. 1913*a*. Gibt es einen echten hämatogenen Icterus? *Med. Klinik*, **9**, 1125.

——— 1913*b*. Experiments on haemolytic icterus. *J. Path. and Bacteriol.*, **18**, 325.

Mallory, F. 1898. A histological study of typhoid fever. *J. Exper. Med.*, **3**, 611.

——— 1914. *The principles of pathologic histology.* Phila. and Lond.: W. B. Saunders Co.

Mandlebaum, F., and Downey, H. 1916. The histopathology and biology of Gaucher's disease (large-cell splenomegaly). *Fol. haematol.*, Archiv, **20**, 130.

Marchand, F. 1898. Ueber die bei Entzündungen in der Peritoncalhöhle auftretenden Zellformen. *Verhandl. d. deutsch. path. Gesellsch.*, 1 Tag., 63.

—— 1902. Ueber Clasmatocyten, Mastzellen und Phagocyten des Netzes. *Ibid.*, 4 Tag., 124.

—— 1913. Ueber die Herkunft der Lymphocyten und ihre Schicksale bei der Entzündung. *Ibid.*, 16 Tag., 5.

—— 1921. Ueber den Entzündungsbegriff. *Virchow's Archiv*, **234**, 245.

—— 1924*a*. Aeltere und neuere Beobachtungen zur Histologie des Omentum. *Haematologica* **5**, 304.

—— 1924*b*. Die örtlichen reaktiven Vorgänge (Lehrev on der Entzündung). In *Handb. d. allg. Path.*, herausg. v. L. Krehl u. F. Marchand, **4**, Abt. 1, 78, Leipz.: S. Hirzel.

Masugi, M. 1927. Ueber die Beziehungen zwischen Monocyten und Histiocyten. *Beitr. z. path. Anat. u. z. allg. Path.*, **76**, 396.

Maximow, A. 1902. Experimentelle Untersuchungen über entzündliche Neubildung von Bindegewebe. *Beitr. z. path. Anat. u. z. allg. Path.*, Supplementheft 5.

— 1903. Weiteres über Entstehung, Struktur und Veränderungen des Narbengewebes. *Ibid.*, **34**, 153.

—— 1904. Ueber entzündliche Bindegewebsneubildung bei der weissen Ratte und die dabei auftretenden Veränderungen der Mastzellen und Fettzellen. *Ibid.*, **35**, 93.

—— 1905. Beiträge zur Histologie der eiterigen Entzündung. *Ibid.*, **38**, 301.

—— 1906*a*. Ueber etnzündliche Bindegewebsbildung beim Axolotl. *Ibid.*, **39**, 333.

—— 1906*b*. Ueber die Zellformen des lockeren Bindegewebes. *Arch. f. mikr. Anat.*, **67**, 680.

—— 1907. Ueber die Entwicklung der Blut- und Bindegewebszellen beim Säugetierembryo. *Fol. haematol.*, **4**, 611.

— 1909*a*. Untersuchungen über Blut und Bindegewebe. I. Die frühesten Entwicklungsstadien der Blut- und Bindegewebszellen beim Säugetierembryo bis zum Anfang der Blutbildung in der Leber. *Arch. f. mikr. Anat.*, **73**, 444.

— 1909*b*. Die Histogenese der Entzündung (mit Berücksichtigung der gewebsbildenden hämatogenen Zellen). *Verhandl. d.* 16 *intern. med. Kongr. zu Budapest*, Sekt. 4b, 41.

1916. The cultivation of connective tissue of adult mammals in vitro. *Arch. russes d'anat., d'hist. et d'embryol.*, **1**, 105.

—— 1922. Untersuchungen über Blut und Bindegewebe. VII. Ueber "in vitro" Kulturen von lymphoidem Gewebe des erwachsenen Säugetierorganismus. *Arch. f. mikr. Anat.*, **96**, 494.

1923*a*. Untersuchungen über Blut und Bindegewebe. VIII. Die cytologischen Eigenschaften der Fibroblasten, Reticulumzellen und Lymphocyten des lymphoiden Gewebes ausserhalb des Organismus, ihre genetischen Wechselbeziehungen und prospektiven Entwicklungspotenzen. *Ibid.*, **97**, 283.

—— 1923*b*. Untersuchungen über Blut und Bindegewebe. X. Ueber die Blutbildung bei den Selachiern im erwachsenen und embryonalen Zustande. *Ibid.*, **97**, 623.

—— 1924*a*. Relation of blood cells to connective tissues and endothelium. *Physiol. Reviews*, **4**, 533.

1924*b*. Tuberculosis of mammalian tissue in vitro. *J. Infect. Dis.*, **34**, 549.

—— 1925*a*. Ueber die Entwicklungsfähigkeiten der Blutleukocyten und des Blutgefässendothels bei Entzündung und in Gewebskulturen. *Klin. Wchnschr.*, **4**, 1486.

— 1925*b*. Rôle of the nongranular blood leukocytes in the formation of the tubercle. *J. Infect. Dis.*, **37**, 418.

Maximow, A. 1926. Ueber undifferenzierte Blutzellen und mesenchymale Keimlager im erwachsenen Organismus. *Klin. Wchnschr.*, **5**, 2193.

——— 1927*a*. On the development of the nongranular leucocytes of the blood into polyblasts (macrophages) and fibroblasts in tissue culture. *Proc. Soc. Exper. Biol. & Med.*, **24**, 570.

——— 1927*b*. Bindegewebe und blutbildende Gewebe. In *Handbuch d. mikr. Anatomie*, herausg. von W. v. Möllendorff, **2**, 1, Berl.: Julius Springer. (In press.)

Meleney, H. 1925. The histopathology of Kala-azar in the hamster, monkey and man. *Am. J. Path.*, **1**, 147.

Metschnikoff, E. 1892. *Leçons sur la pathologie comparée de l'inflammation.* Paris: Masson.

——— 1901. *L'immunité dans les maladies infectieuses.* Paris.

——— 1905. *Immunity in infective diseases.* Cambridge: University Press.

Migay, F., and Petroff, J. 1923. Ueber experimentell erzeugte Eisenablagerungen und vitale Carminfärbung bei Kaninchen. *Arch. f. mikr. Anat.*, **97**, 54.

Mjassojedoff, S. 1926. Die Zellformen des Bindegewebes und des Blutes und die Blutbildung beim erwachsenen Huhn. *Fol. haematol.*, Archiv. **32**, 263.

v. Möllendorff, W. 1918. Zur Morphologie der vitalen Granulafärbung. *Arch. f. mikr. Anat.*, **90**, 463.

——— 1920. Vitalfärbungen an tierischen Zellen. Grundlagen, Ergebnisse und Ziele biologischer Farbstoffversuche. *Ergebn. d. Physiol.*, herausg. von L. Ascher und K. Spiro, **18**, 141.

——— 1927. Die örtliche Zellbildung in Gefässwänden und im Bindegewebe. *Münch. med. Wchnschr.*, **74**, 135.

v. Möllendorff, W., and v. Möllendorff, M. 1926. Das Fibrocytennetz im lockeren Bindegewebe, seine Wandlungsfähigkeit und Anteilnahme am Stoffwechsel. *Ztschr. f. Zellforsch. u. mikr. Anat.* (Ztschr. f. wiss. Biol., Abt. B): **3**, 503.

Mollier, S. 1911. Ueber den Bau der capillaren Milzvenen (Milzsinus). Eine kritische Studie und eigene Beobachtungen. *Arch. f. mikr. Anat.*, **76**, 608.

Natali, C. 1925. Morphologische Untersuchungen über die Bedeutung des reticuloendothelialen Systems bei intravitaler Hämolyse. *Ztschr. f. d. ges. exper. Med.*, **47**, 223.

Nathan, M. 1908. La cellule de Kupffer (cellule endothéliale des capillaires veineux du foie), ses réactions expérimentales et pathologiques. *J. d. l'anat. et de la physiol.*, **44**, 208 and 271.

Nissen, R. 1922. Der Einfluss kolloidaler gelöster Metalle auf die blutbereitenden Organe mit besonderer Berücksichtigung des reticulo-endothelialen Systems. *Klin. Wchnschr.*, **1**, 1986.

Oberling, C. 1924. Le système réticulo-endothélial. *Ann. d'anat. path.*, **1**, 87.

Oeller, H. 1923. Die funktionelle Bedeutung der Gefässwandzellen bei akuten Infektionen. *Med. Klinik.*, **19**, 97.

——— 1925. Experimentelle Studien zur pathologischen Physiologie des Mesenchyms und seiner Stoffwechselleistungen bei Infektionen. *Krankheitsforsch.*, **1**, 28.

Oppenheimer, R. 1908. Experimentelle Beiträge zur Histogenese des miliaren Lebertuberkels. *Virchow's Archiv*, Beiheft zu Bd. **194**, 254.

Orsós, F. 1926. Das Bindegewebsgerüst der Lymphknoten im normalen und pathologischen Zustande. *Beitr. z. path. Anat. u. z. allg. Path.*, **75**, 15.

Pappenheim, A. 1919. Morphologische Hämatologie. Bd. 2. Spezielle Morphologie und Genese der Blutzellen; die hämatopoetischen Organe; klinische Hämatologie. *Fol. haematol.*, Archiv, **24**, 1. Leipzig: W. Klinkhardt.

Paschkis, K. 1924. Zur Biologie des reticulo-endothelialen Apparates. I. Kritische und experimentelle Studien zur Funktion und zur Blockadefrage. Reticuloendothel und Immunkörperbildung. *Ztschr. f. d. ges. exper. Med.*, **43**, 175.

——— 1926*a*. Zur Frage der Abstammung der grossen Mononucleären. (Zur Biologie des reticulo-endothelialen Apparates II.) *Virchow's Archiv*, **259**, 316.

——— 1926*b*. Zur Biologie des reticulo-endothelialen Apparates. IV. Mitt. Ueber Folgen der Milzextirpation. *Ztschr. f. d. ges. exper. Med.*, **49**, 658.

Permar, H. 1924. The function of the endothelial cell in pathological conditions, especially in tuberculosis. *Am. Rev. of Tuberc.*, **9**, 507.

Pfuhl, W. 1926. Experimentelle Untersuchungen über die Kupfferschen Sternzellen der Leber. I. Mitt.: die verschiedenen Formen der Sternzellen, ihre Lage in den Leberkapillaren und ihre allgemeine Biologie. *Ztschr. f. Anat. u. Entwicklungsgesch.*, **81**, 90.

Portis, B. 1924. Rôle of omentum of rabbits, dogs and guinea pigs in antibody production. *J. Infect. Dis.*, **34**, 159.

Ranvier, L. 1889. *Traité technique d'histologie*, Ed. 2, Paris: E. Savy.

——— 1890. Des clasmatocytes. *Compt. rend. acad. des sciences*, **110**, 165.

——— 1900. Des clasmatocytes. *Arch. d'anat. micr.*, **3**, 123.

v Recklinghausen, F. 1863. Ueber Eiter- und Bindegewebskörperchen. *Virchow's Archiv*, **28**, 157.

Renaut, J. 1907. Les cellules connectives rhagiocrines. *Arch. d'anat. microsc.*, **9**, 495.

Ribbert, H. 1889. Ueber Regeneration und Entzündung der Lymphdrüsen. *Beitr. z. path. Anat. u. z. allg. Path.*, **6**, 185.

—— 1904. Die Abscheidung intravenös injizierten gelösten Carmins in den Geweben. *Ztschr. f. allg. Physiol.*, **4**, 201.

——— 1907. Ueber die Bedeutung der Lymphdrüsen. *Med. Klinik*, **3**, 1543.

Rich, A. 1924. The formation of bile pigment from hemoglobin in tissue cultures. *Bull. Johns Hopkins Hosp.*, **35**, 415.

Rössle, R. 1923. Referat über Entzündung. *Verhandl. d. deutsch. path. Ges.*, 19 Tag., 18.

Sabin, F. 1921. Studies on blood. The vitally stainable granules as a specific criterion for erythroblasts and the differentiation of the three strains of the white blood-cells as seen in the living chick's yolk sac. *Bull. Johns Hopkins Hosp.*, **32**, 314.

— 1923. Studies of living human blood cells. *Ibid.*, **34**, 277.

Sabin, F., Doan, C., and Cunningham, R. 1924. The separation of the phagocytic cells of the peritoneal exudate into two distinct types. *Proc. Soc. exper. biol. & med.*, **21**, 330.

——— 1925. Discrimination of two types of phagocytic cells in the connective tissues by the supravital technique. *Contrib. to Embryol.* Carnegie Inst., Wash., **16**, 125.

Sabin, F., and Doan, C. 1926. The presence of desquamated endothelial cells, the so-called clasmatocytes, in normal mammalian blood. *J. Exper. Med.*, **43**, 823.

Sacks, B. 1926. The reticulo-endothelial system. *Physiol. Reviews*, **6**, 504.

Schilling, V. 1909. Zur Morphologie, Biologie und Pathologie der Kupfferschen Sternzellen, besonders der menschlichen Leber. *Virchow's Archiv*, **196**, 1.

——— 1919. Ueber hochgradige Monocytosen mit Makrophagen bei Endocarditis ulcerosa und über die Herkunft der Gr. Mononucleären., *Ztschr. f. klin. Med.*, **88**, 377.

Schittenhelm, A. 1925. Normale und pathologische Physiologie des reticuloendothelialen Systems. In *Handb. d. Krank. d. Blutes u. d. blubild. Organe*, herausg. von A. Schittenhelm, **2**, 492, Berl.: Julius Springer.

Schittenhelm, A., and Erhardt, W. 1925. Untersuchungen über die Beziehungen des reticulo-endothelialen Systems zu den grossen Monocyten des Blutes mit Hilfe der Vitalspeicherung. *Ztschr. f. d. ges. exper. Med.*, **46**, 225.

Schömheimer, R. 1924. Ueber die experimentelle Cholesterinkrankheit der Kaninchen. *Virchow's Archiv*, **249**, 1.

Schulemann, W. 1912. Beiträge zur Vitalfärbung. *Arch. f. mikr. Anat.*, **79**, 223.

——— 1917. Die vitale Färbung mit sauren Farbstoffen in ihrer Bedeutung für Anatomie, Physiologie, Pathologie und Pharmakologie. *Biochem. Ztschr.*, **80**, 1.

Schultze, W. H. 1912. Ueber grosszellige Hyperplasie der Milz bei Lipoidaemie (Lipoidzellenhyperplasie). *Verhandl. d. Deutsch. path. Ges.*, 15 Tag., 47.

v. Schumacher, S. 1897. Ueber die Lymphdrüsen des Macacus rhesus. *Arch. f. mikr. Anat.*, **48**, 145.

——— 1899. Ueber Phagocytose und die Abführwege der Leukocyten in den Lymphdrüsen. *Ibid.*, **54**, 311.

Seifert, E. 1921. Zur Biologie des menschlichen grossen Netzes. *Arch. f. klin. Chir.*, **116**, 510.

Seyderhelm, I. 1923. Ueber das Vorkommen von Makrophagen im Blute bei einem Fall von Endocarditis ulcerosa. *Virchow's Archiv*, **243**, 462.

Shiomi, C. 1925. Explantationsversuche mit Lymphknoten auf Plasma unter Zusatz von Milz-, Nebennieren- und Knochenmarkextrakt unter Nachprüfung der Versuche von Maximow und unter besonderer Berücksichtigung der Bildung granulierter Zellen. *Virchow's Archiv*, **257**, 714.

Siegmund, H. 1923*a*. Untersuchungen über Immunität und Entzündung. *Verhandl. d. deutsch. path. Ges.*, 19 Tag., 114.

——— 1923*b*. Reizkörpertherapie und aktives mesenchymatisches Gewebe. *Münch. med. Wchnschr.*, **70**, 5.

——— 1925. Ueber einige Reaktionen der Gefässwände und des Endokards bei experimentellen und menschlichen Allgemeininfektionen. *Verhandl. d. deutsch. path. Ges.*, 20 Tag., 260.

——— 1926. Ueber das Schicksal eingeschwemmter Retikuloendothelien (Bluthistiocyten) in den Lungengefässen. Ein weiterer Beitrag zur Entstehung von Gefässgranulationen. *Ztschr. f. d. ges. exper. Med.*, **50**, 73.

Simpson, M. 1921. I. Vital staining of human blood with special reference to the separation of the monocytes. II. The experimental production of circulating endothelial macrophages and the relation of these cells to the monocytes. *Univ. of California publ. in anat.*, **1**, 1.

——— 1922. The experimental production of macrophages in the circulating blood. *J. Med. Research*, **43**, 77.

Solucha, N. 1908. *On the cell types of the connective tissue of the buds in normal conditions and in inflammation.* Inaug.-Diss. St. Petersburg (Russian). Rev. in *Fol. haematol.*, Zentralorg. **8**, 230.

Ssyssojew, T. 1924. Histologische Beobachtungen am intravital gefärbten Axoloto. *Virchow's Archiv*, **251**, 150.

Stilwell, F. 1926. On the phagocytic capacity of the blood vessel endothelium of the frog's tongue and its presumed transformation into wandering cells. *Fol. haematol.*, Archiv, **33**, 81.

Thomé, R. 1898. Endothelien als Phagocyten (aus den Lymphdrüsen von Macacus cynomolgus). *Arch. f. mikr. Anat.*, **52**, 820.

——— 1903. Beiträge zur mikroskopischen Anatomie der Lymphknoten. I. Das Reticulum der Lymphknoten. *Jenaische Ztschr. f. Naturwiss.*, **37**, 133.

Töppich, G. 1925. Die cellulären Abwehrvorgänge in der Lunge bei Erst- und Wiederinfektion mit Tuberkelbazillen. *Krankheitsforschung*, **2**, 15.

——— 1926. Der Abbau der Tuberkelbazillen in der Lunge durch Zellvorgänge und ihr Wiederauftreten in veränderter Form. *Ibid.*, **3**, 335.

Tschaschin, S. 1913. Ueber die "ruhenden Wanderzellen" und ihre Beziehungen zu den anderen Zellformen des Bindegewebes und zu den Lymphocyten. *Fol. haematol.*, Archiv, **17**, 317.

Vogt, E. 1923. Untersuchungen zur Biologie der Peritonealflüssigkeit des Menschen. *Med. Klinik*, **19**, 943.

Volterra, M. 1925. Sulla struttura dei capillari sanguigni e l'anatomia del sistema reticolo-endoteliale. *Monitore zool. ital.*, **36**, 49.

Weicksel, J. 1920. Ueber die grossen Mononucleären und Uebergangsformen Ehrlichs (Monocyten) und ihr Verhalten bei Tuberkulose. *Med. Klinik.*, **16**, 1326.

Weidenreich, F. 1901. Das Gefässsystem der menschlichen Milz. *Arch. f. mikr. Anat.*, **58**, 247.

——— 1905. Studien über das Blut und die blutbildenden und-zerstörenden Organe. II. Bau und morphologische Stellung der Blutlymphdrüsen. *Ibid.*, **65**, 1.

——— 1911. Die Leukocyten und verwandte Zellformen. Wiesbaden: J. F. Bergmann. (*Ztschr. f. d. ges. Anat.*, Abt. 3; *Ergebn. d. Anat. u. Entwicklungsgesch.*, **19**, 527.)

Weill, P. 1920. Ueber Erythrophagocytose im strömenden Blute. *Fol. haematol.*, Archiv, **26**, 27.

Wentzlaff, A. 1924. Ueber die Bluthistiocytose beim Frosche. *Beitr. z. path. Anat. u. z. allg. Path.*, **72**, 710.

Wislocki, G. 1916. The staining of amphibian larvae with benzidine dyes with especial reference to the behavior of the lymphatic endothelium. *Am. J. Physiol.*, **42**, 124.

——— 1917. The action of vital dyes in teleosts. *Anat. Record*, **12**, 415.

Wjereszinski, A. 1924. Ueber die freien Zellen der serösen Exsudate, ihren Ursprung, ihre genetischen Wechselbeziehungen und ihre prospektiven Potenzen. *Haematologica*, **5**, 41.

——— 1925. *Beiträge zur Morphologie und Histogenese der intraperitonealen Verwachsungen.* Leipz.: F. C. Vogel.

Wollenberg, H. 1925. Die historische Entwicklung der Monozytenfrage. *Ergebn. d. inn. Med. u. Kinderheilk.*, **28**, 638.

Zimmermann, K. 1923. Der feinere Bau der Blutcapillaren. *Ztschr. f. Anat. u. Entwicklungsgesch., Ztschr. f. d. ges. Anat.*, Abt. 1: **68**, 29.

Zinserling, W. 1923. Ueber die Anfangsstadien der experimentellen Cholesterinesterverfettung. *Beitr. z. path. Anat. u. z. allg. Path.*, **71**, 292.

Section XV

THE STRUCTURE OF THE HYPOPHYSIS CEREBRI OF MAN AND OF THE COMMON LABORATORY MAMMALS

CONTENTS

Section XV

		PAGE
I.	Primary Subdivisions	487
II.	Development of Hypophysis	489
III.	Vascular, Lymphatic and Nervous Supply	490
IV.	Microscopic Picture	491
	1. Pars distalis	491
	2. Pars intermedia	493
	3. Pars tuberalis	494
	4. Pars nervosa	495
V.	Process of Secretion	497
VI.	Cellular Pathology	497
VII.	Bibliography	498

Section XV

THE STRUCTURE OF THE HYPOPHYSIS CEREBRI OF MAN AND OF THE COMMON LABORATORY MAMMALS

PERCIVAL BAILEY

THE following brief account of the structure of the hypophysis will be based as far as possible on the human organ but, since the finer details of its constitution are imperfectly known, extended reference will necessarily be made to the hypophyses of other mammals, more particularly to the cat, since the gland in this latter mammal retains many of its embryonic characteristics.

The human hypophysis is a more or less spherical organ lying beneath the brain in the sella turcica of the sphenoid bone. It is covered by an extension of the dura mater known as the diaphragma sellae, which is pierced by a narrow stalk uniting the organ with the brain. The dura mater also lines the sella so that it comes thus to form a continuous capsule (Fig. 208), within which the subarachnoid space extends everywhere except at the extreme posterior extremity where the blood vessels enter the posterior lobe (Hughson, 1924).

The size and weight of the hypophysis vary considerably in the human adult but its average weight may be given as about 0.56 gm. Its dimensions are about 10 mm. anteroposteriorly, 6 mm. dorsiventrally and 13 mm. from side to side (Rasmussen, 1924).

1. PRIMARY SUBDIVISIONS

The hypophysis cerebri in mammals may be subdivided into several parts which have a distinctive microscopic structure. Their significance will appear clearly when their development is followed in the embryo. For the moment the gland of the adult cat may be used for orientation, a sagittal section of which is semi-diagrammatically represented in Figure 209.

It is customary to recognize two lobes, an anterior and a posterior, separated by an epithelial-lined cleft, since it is along this line that the organ may be easily divided into two parts. But these are merely gross anatomical subdivisions, and under the microscope the posterior lobe, as thus determined, may be seen to be further composed of two distinct portions, an inner core called the pars nervosa, being an extension from the hypothalamic region of the brain, while an outer epithelial covering, the pars intermedia, is composed of cells which are continuous at the stalk and at the posterior extremity with similar cells of the anterior lobe. The anterior lobe is more homogeneous and is known as the pars distalis.

In addition a thin layer of cells spreads out over the base of the brain and is called the pars tuberalis.

These various portions may be distinguished in every mammal, but vary in their size and relationships, the similarity being much more striking

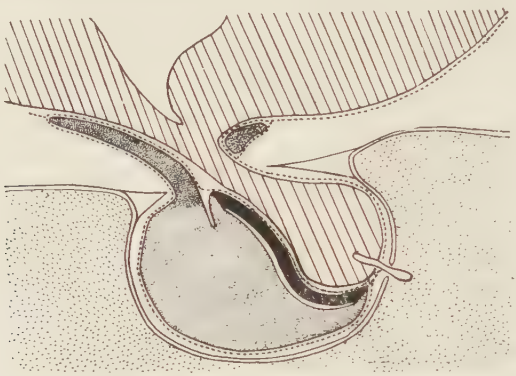

FIG. 208.—Schema of meningeal relations of hypophysis. Line of dashes indicates leptomeninges; diagonal lines, the nervous tissue; light stipple, the pars distalis; heavy stipple, the pars tuberalis; black, the pars intermedia. (After Atwell, modified.)

in fetal stages of development. For example, the cavity of the pars nervosa still communicates with the ventricle in the adult cat, while in other mammals, although present in fetal life, it becomes obliterated in the

FIG. 209.—Hypophysis of cat. 1, pars distalis; 2, hypophysial cleft; 3 pars intermedia; 4, pars nervosa; 5, infundibular cavity; 6, pars tuberalis, and 7, optic chiasm. (Redrawn after Herring.)

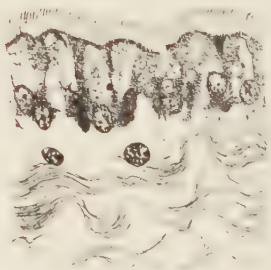

FIG. 210.—Ciliated cells of hypophyseal cleft. (Redrawn after Kiyono.)

adult stage. In the dog there is still a funnel-shaped infundibular cavity extending down to the upper portion of the pars nervosa, while in the monkey and man the posterior lobe is united with the brain by a long stalk of solid nervous tissue.

The epithelial-lined cleft between the anterior and posterior lobes is present in the hypophyses of all mammals except adult man, where it is either completely obliterated or persists as isolated cystic cavities which may be distinguished from other cavities in this region by their being lined with ciliated epithelium (Fig. 210). The pars intermedia is also practically absent in the adult human hypophysis.

II. DEVELOPMENT OF THE HYPOPHYSIS

From an embryological point of view the hypophysis may be subdivided also into two parts which differ from the gross anatomical subdivisions. One of them, the pars buccalis, arises from the ectoderm of the stomodeum just in front of the oral plate as a long evagination known as Rathke's pouch. This diverticulum grows upward and the apex, applying itself to the surface of the nervous tissue, becomes the pars intermedia. The remainder, with the exception of two paired lateral lobes, becomes greatly thickened to form the pars distalis.

The paired lateral lobes appear in the human embryo of 10.5 mm. C. R. length as ridges at the anterolateral angles of the buccal evagination near its attachment to the stomodeum. They fuse across the midline forming the pars tuberalis, and begin to grow forward by the 45 mm. stage. The pars tuberalis then grows forward and backward over the surface of the nervous tissue of the infundibulum and tuber cinereum (Atwell, 1926).

The attachment of the pars buccalis to the buccal epithelium becomes attentuated and finally severed, but its cavity persists except in the adult human hypophysis, and islands of its cells may remain in the pharyngeal wall or become enclosed in the developing sphenoid bone (Haberfeld, 1909).

The pars nervosa has a quite different origin. It arises as a downward evagination from the floor of the diencephalon in the region of the tuber cinereum. It is enveloped by the pars buccalis, more or less completely in the various mammals. Its cavity is lost, except in the adult cat, and the funnel-shaped extension of the third ventricle leading down to it is known as the infundibulum, which is especially well marked in the dog.

The relationship of the various parts of the hypophysis may be represented in the following schema:

Pars buccalis { pars tuberalis
pars distalis—anterior lobe
pars intermedia } posterior lobe
pars nervosa }

III. VASCULAR, LYMPHATIC AND NERVOUS SUPPLY

The pars tuberalis and pars distalis have a very rich blood supply (Fig. 211) from numerous small vessels which arise from the circle of Willis and descend in the pia mater of the infundibulum along the stalk (Dandy and Goetsch, 1911). The pars nervosa has a much less abundant vascular supply which enters mainly from its postero-inferior extremity where it is not invested by the pars buccalis. The pars intermedia is very poorly vascularized in all mammals, although numerous small vessels run in the connective tissue representing the pia mater which separates it from the pars nervosa (Herring, 1908).

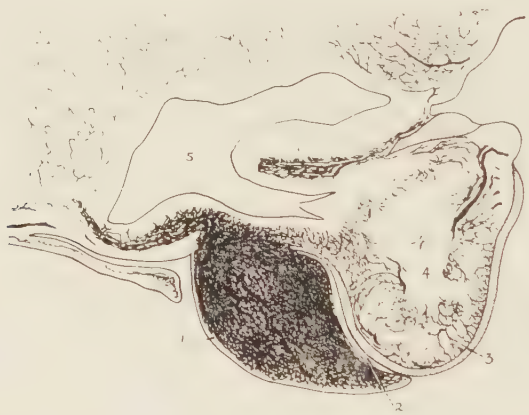

FIG. 211.—Blood supply of hypophysis of cat. 1, pars distalis; 2, hypophyseal cleft. 3, pars intermedia. 4, pars nervosa. 5, infundibulum. (Redrawn after Herring.)

The pars distalis receives its nerves from the carotid plexus (Dandy, 1917). They consist of fine amyelinated fibers which follow the vascular supply. At intervals branches leave the vessels to traverse the cellular columns and end between the glandular cells (Berkley, 1894). The occasional fibrils which are seen in the pars intermedia have not been traced definitely to their origin but seem to come from the pars nervosa (Pines, 1926).

The nucleus supraopticus gives origin to an important tract of fibers which descends the anterior wall of the infundibulum and spreads out in the pars nervosa. First described by Cajal, the existence of this tract has recently been confirmed by numerous authors (Savagnone, Pines, 1926, Greving, Nicolesco and Raileanu). Its fibers end in tangled masses around the blood vessels and among the cells (Tello, 1912).

Lymphatic vessels have never been demonstrated in the hypophysis.

IV. MICROSCOPIC STRUCTURE

1. *Pars distalis:*

The best known portion of the hypophysis, probably the most important, is the pars distalis. The finer details of its structure are very similar in all mammals. It is composed of columns of cells separated from one another by numerous large vascular sinuses and a small amount of connective tissue (Fig. 212).

Two main groups of cells may be distinguished, known respectively as chromophile and chromophobe, according to the intensity of their staining

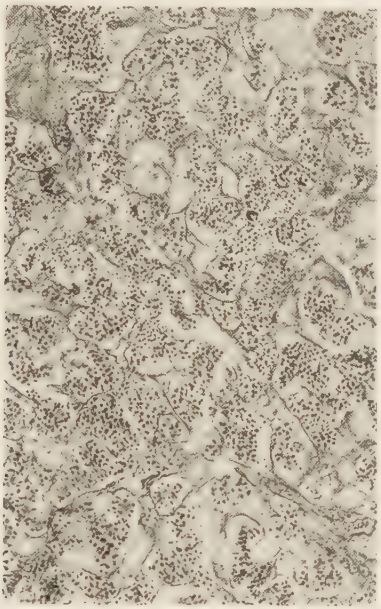

FIG. 212. - Photomicrograph of human hypophysis. Perdrau's method; × 80. To show connective tissue, between columns of glandular cells.

reactions. The chromophile cells owe the depth of their staining to the presence of granules embedded in their cytoplasm. The granules are also of two types generally called basophile and acidophile, it being once thought that the former stained only with basic and the latter with acid dyes. This opinion is now known to be incorrect, and it seems better to refer to them as beta and alpha granules respectively. Although transitional cells have been described, the majority of investigators believe that the two types of granules are never found in the same cell (Bailey, 1921).

In the human hypophysis the alpha and beta cells have no characteristic distribution, but are scattered in a haphazard way over the whole of the

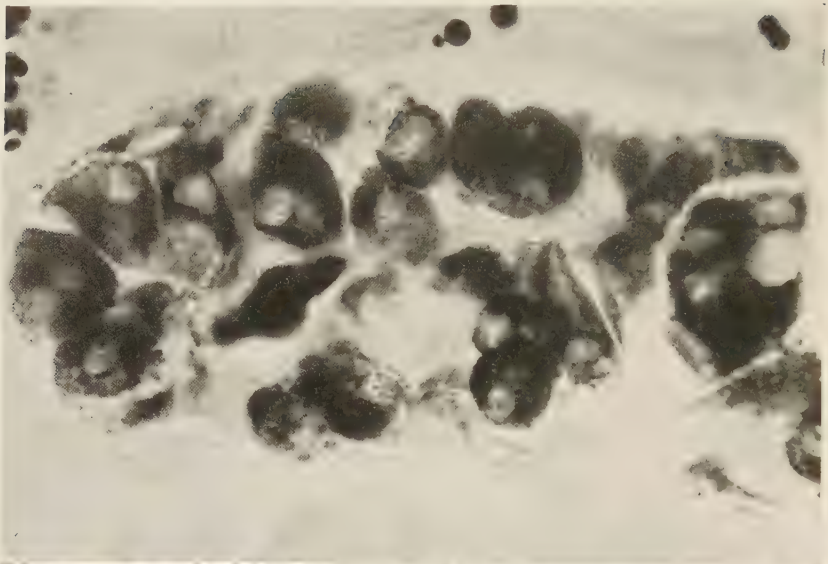

213

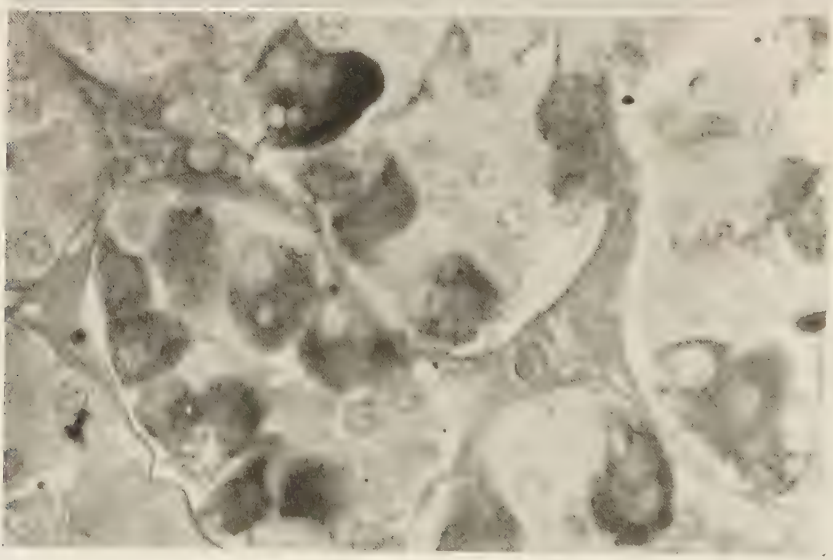

214

FIGS. 213 and 214.—Photomicrographs of human hypophysis. Fig. 213, "eosinophilic" cells. The alpha granules are specifically stained. Neutral ethyl violet-orange G. × 850. Fig. 214, "basophilic" cells. The beta granules are specifically stained. Kresofuchsin. × 850.

pars distalis, the alpha cells predominating (Rasmussen, 1921). Their granules are quite distinct, while in many lower mammals the beta substance exists in the form of amorphous masses.

The alpha granules are large, spherical and very distinct (Fig. 213). They are usually so closely packed in the cell as to obscure all other structural details. They first appear in the third fetal month. The beta granules appear somewhat later at the end of the third or the beginning of the fourth fetal month (Cooper, 1925). They are always finer and less distinct than the alpha granules. The cells which contain them are as a rule larger than the alpha cells (Fig. 214).

Often to be seen in the chromophile cells is a clear area near the nucleus called the macula (Rasmussen, 1921), containing the Golgi apparatus (Addison, 1917; de Beer, 1926), perhaps also the centrosomes. It is most easily seen in the beta cells, as are also the mitochondria since they are not so obscured by the granules as in the alpha cells.

Fig. 215.—Related cell. (Redrawn after Tello.)

The cells which do not contain granules are of two types. The most numerous have very little cytoplasm and are known as chief cells or reserve cells. A few chromophobe cells resemble in size and shape the chromophile cells and are believed by Kraus (1914) to be chromophile cells which have lost their granules ("entgranulierten Zellen"). The chief cells are often found in the center of the cellular columns, although they may constitute entire columns, especially near the stalk. Their cellular boundaries are not always very distinct, so that they resemble groups of nuclei embedded in a common cytoplasm (Kernhaufen). In the larger chromophobe cells, perhaps the "entgranulierten Zellen," Tello has found complicated reticular formations such as that shown in Figure 215.

Small globules of lipoidal substances are seen in all the cells, but especially in the beta cells.

The nuclei of both the chromphobe and chromophile cells are of two types: some are vesicular with scattered granules of chromatin, while others are smaller with a very heavy network of chromatin. The significance of this difference in the nuclei is unknown.

2. *Pars intermedia:*

The intermediate part is present in the human embryo but in later stages the cleft dividing it from the pars distalis is obliterated and the cytoplasm of its cells develops beta even alpha granules, so that in the adult gland this part can often no longer be identified (Kasche, 1926). In all other mammals it persists in the adult as a narrow band of cells immedi-

ately adjacent to the pars nervosa and separated from the pars distalis by a narrow cleft, the remnant of the cavity of the pouch of Rathke.

The pars intermedia is almost entirely avascular in all mammals. Its cells are of two types: (1) elongated, slender cells stretching the entire width of the part, which may be impregnated with Golgi's method (Fig. 216); and (2) polygonal cells resembling the chromophobe cells of the pars distalis. These latter cells are generally considered to contain no characteristic granulation, although Maurer and Lewis (1922) have described a delicate granulation in the pars intermedia of the pig, which they consider to be proper to these cells.

In the remnants of the pars intermedia of the human hypophysis may be found cells probably analogous to the Type 1 cells above, which are impregnated by Cajal's method (Fig. 217).

FIG. 216.—Ependymal cells. Pars intermedia of cat. (Redrawn after Retzius.)

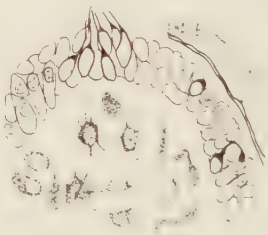

FIG. 217.—Ependymal (?) cells of human pars intermedia. (Redrawn after Tello.)

A striking feature of the pars intermedia of many hypophyses is the presence of numerous cysts (Cushing, 1912) of varying sizes. These do not constitute regular vesicles such as are found in the thyroid gland, but rather irregular cavities of varying sizes among the cells filled with colloid and hyaline material, and often with degenerating cells (de Beer, 1926). By distention these cavities may come to be surrounded by a pseudo-epithelium.

3. *Pars tuberalis:*

The tuberous portion represents a very insignificant part of the human hypophysis but is somewhat more developed in the dog and cat. In these animals its general structure resembles the pars distalis, being composed of columns of cells separated by numerous vascular sinuses. The cells, however, contain no granules and often undergo a hyaline or colloid transformation forming irregular cavities in the cellular columns (Herring), thus giving them a tubular appearance. These cavities are not lined by a regular epithelium and differ from the thyroid vesicles also, as indeed those of the pars intermedia, in that they are not formed during fetal life but appear in the fifth month post partum (Cooper, 1925).

An interesting formation in the human pars tuberalis consists of nests of squamous epithelial cells (Fig. 218). These lie scattered mainly on the anterior wall of the stalk but are occasionally found on the wall of the infundibulum, or in the upper part of the pars distalis, pars intermedia or even the pars nervosa (Kiyono, 1926).

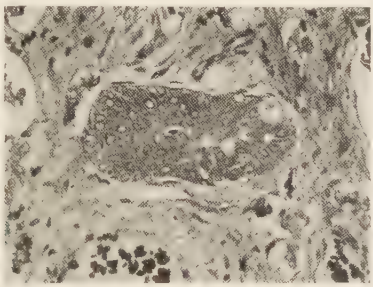

FIG. 218.—Squamous cells in stalk of human hypophysis. (After Kiyono.)

4. *Pars nervosa:*

It must be remembered that the pars nervosa was primitively an evagination from the neural tube. It had therefore a ventricular cavity, which persists only in the adult cat, and a pial outer surface. The essential elements of its structure may be found represented in a cross section of the infundibulum of the dog figured by Berkley (Fig. 219). Three different cellular elements are there to be seen: (1) typical ependymal cells with their

FIG. 219.—Infundibulum of dog. Golgi's method. 1, ependymal cell; 2, neuroglial cell; 3, cells of doubtful nature resembling nervous cells. (Redrawn after Berkley.)

cell bodies on the ventricular surface and processes stretching to the pial surface, (2) mossy neuroglial cells, and finally (3) larger pyramidal or spindle-shaped cells of uncertain nature. Berkley believed the last type to be nervous cells, but they never contain Nissl substance and it seems more probable that they are displaced ependymal cells. These three cellular types may be identified by Golgi's method in the pars nervosa of the dog and cat in varying proportions. In the dog the ependymal cells are

not a striking feature, for the cavity of the infundibular process is obliterated; but in the cat they predominate and according to Herring send their processes up the stalk into the tuber cinereum. This latter point needs to be reinvestigated for all other authors agree that the fibers seen in the stalk are nerve fibers coming down into the hypophysis.

In the human pars nervosa a few mossy neuroglial cells have been impregnated by Golgi's method in the region of the stalk, but its bulk is composed of spindle-shaped or irregular cells which give off fragile processes that cannot be sharply stained or impregnated by any method. These cells often contain greenish-brown granules of pigment (Fig. 220) which are readily stained by neutral red (Kohn, 1910).

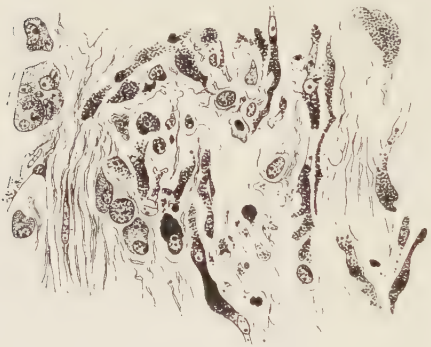

Fig. 220.—Pigmented cells of human pars nervosa. (Redrawn after Kohn.)

Fig. 221.—Nervous terminations in posterior lobe. Golgi's method. (Redrawn after Berkley.)

The course and termination of the nerve fibers which descend into the hypophysis from the nucleus supraopticus have been carefully investigated by Tello. For the most part they accompany the blood vessels which are most numerous in the region of the infundibulum, forming complicated whirls around their walls. Other fibers form similar whirls around groups of cells. The same formations were seen by Berkley (Fig. 221), with the Golgi method. Still other fibers end with bulbs which resemble those of regenerating nerves. They are flattened, enlarged and show fibrillary dissociation.

In many places these nerve fibers terminate in rounded hyaline masses which often retain traces of their fibrillary structure (Fig. 222). These hyaline bodies are sometimes considered (Bell) to be due to the degeneration of those cells of the pars intermedia which often invade the pars nervosa, although it is generally conceded that they never contain nuclei (Herring, Cooper). In the human hypophysis these hyaline bodies appear first in the second year of post-partum life (Cooper).

V. PROCESS OF SECRETION

The manner in which the hypophysis secretes is not definitely known. The pars distalis has a glandular structure. It has been believed on indirect evidence that the alpha granules constitute an active secretory product (Benda; Dott and Bailey, 1925; Evans, 1923). The histological picture is quite static. The only variations known to occur due to physiological changes in the general state of the animal are (1) increase in the number of beta cells in the woodchuck (*Marmota monax*) when entering into its period of sexual activity on awakening from hibernation (Rasmussen); and (2) increase of the alpha cells ("Schwangerschaftzellen") during pregnancy in the human female (Erdheim and Stumme, 1909). The second change is much less definitely established than the first and should be controlled by the exact methods employed by Rasmussen.

FIG. 222.—Hyaline bodies in human pars nervosa. Cajal method. (Redrawn after Tello.)

The colloid and hyaline material which collects in the pars tuberalis, the pars intermedia and the pars nervosa has been considered to represent a secretory product (Herring; Collin; Cushing, 1926) which passes up the stalk into the third ventricle. This material varies considerably in its staining reactions and has no constant characteristics which enable it to be proved that it has a unique origin and chemical constitution. In the intermediate lobe it is formed by degeneration of the cells (de Beer), while the work of Tello indicates that the hyaline material of the pars nervosa has a quite different origin, arising by degeneration of nervous fibers.

Mauer and Lewis argue that the delicate granulation of the cells of the pars intermedia of the pig must represent a secretory antecedent. Its presence in the pars intermedia of other mammals has not been confirmed.

VI. CELLULAR PATHOLOGY

Many changes occur in the hypophysis during disease, but they seem to be in no wise specific, with the exception of the change occurring in acro-

megaly. In this disease there is usually an adenoma composed of eosinophilic cells, perhaps sometimes a diffuse hyperplasia in which most of the cells become eosinophilic. The adenoma of acromegaly is also characterized by the presence of large multinucleated and crescent cells (Bailey and Davidoff, 1925). More frequently adenomas are found composed of chromophobe cells which are not accompanied by acromegaly.

Cysts are occasionally found in the neighborhood of the hypophysis, which are lined with ciliated epithelium presumably arising from the hypophysial cleft. More frequent are epitheliomats which have the same structure as the small masses of epithelial cells found near the stalk of the normal hypophysis (Duffy, 1920).

VII. BIBLIOGRAPHY

Addison, W. H. F. 1917. The Golgi apparatus in the cells of the distal glandular portion of the hypophysis. *Anat. Record,* **11,** 317.

Atwell, Wayne J. 1926. The development of the hypophysis cerebri in man, with special reference to the pars tuberalis. *Am. J. Anat.,* **37,** 159.

Bailey, P. 1921. Cytological observations on the pars buccalis of the hypophysis cerebri of man, normal and pathological. *J. Med. Res.,* **42,** 349.

Bailey, P., and Davidoff, L. M. 1925. Concerning the microscopic structure of the hypophysis cerebri in acromegaly. *Am. J. Path.,* **1,** 185.

Beer, G. R. de. 1926. *Comparative anatomy, histology and development of the pituitary body.* London: Oliver and Bond.

Berkley, Henry J. 1894. The finer anatomy of the infundibular region of the cerebrum, including the pituitary gland. *Brain,* **17,** 515.

Cooper, Eugenia R. A. 1925. *The histology of the more important human endocrine organs at various ages.* Oxford Medical Publications.

Cushing, H. 1912. *The pituitary body and its disorders.* Philadelphia: Lippincott.

—— 1926. *Studies in intracranial physiology and surgery.* II. *The hypophysis.* Oxford University Press.

Dandy, W. 1913. The nerve-supply to the pituitary body. *Am. J. Anat.,* **15,** 333.

Dandy, W., and Goetsch, E. 1911. The blood-supply to the pituitary body. *Am. J. Anat.,* **2,** 137.

Dott, N. and Bailey, P. 1925. Hypophysial adenomata. *Brit. J. Surg.,* **13,** 314.

Duffy, W. C. 1920. Hypophysial duct tumors. *Ann. Surg.,* **72,** 3.

Erdheim and Stumme. 1909. Ueber die Schwangerschaftsveränderung der Hypophyse. *Ziegler's Beiträge,* **46,** 1.

Evans, H. M. 1923–24. *The function of the anterior hypophysis.* New York: Harvey Lectures.

Haberfeld, W. 1909. Die Rachendachhypophyse, andere Hypophysengangreste und deren Bedeutung für die Pathologie. *Ziegler's Beiträge,* **46,** 133.

Herring, P. T. 1908. The histological appearances of the mammalian pituitary body. *Quart. J. Exp. Physiol.,* **1,** 121.

Hughson, W. 1924. Meningeal relations of the hypophysis cerebri. *Johns Hopkins Hosp. Bull.,* **35,** 232.

Kasche, Fritz. 1926. Die Histologie der Pars intermedia der Hypophyse beim erwachsenen Männe. *Zts. f. mikr.-Anatom. Forschung.,* **6,** 191.

Kiyono, H. 1926. Ueber das Vorkommen von Plattenepithelherden in der Hypophyse. *Virchow's Archiv*, **252**, 118.

Kohn, Alfred. 1910. Ueber das Pigment in der Neurohypophyse des Menschen. *Arch. f. mikr. Anat.*, **72**, 337.

Kraus, E. J. 1914. Die Beziehungen der Zellen des Vorderlappens des menschlichen Hypophyse zueinander unter normalen Verhältnissen und in Tumoren. *Ziegler's Beiträge*, **58**, 159.

Maurer and Lewis. 1922. The structure and differentiation of the specific cellular elements of the pars intermedia of the hypophysis of the domestic pig. *J. Exper. Med.*, **36**, 141.

Pines, I.-L. 1926. Ueber die Innervation der Hypophysis cerebri. II. *Mitth. Zts. f. d ges. Neur. u. Psych.*, **100**, 123.

Rasmussen, A. T. 1921. The hypophysis cerebri of the woodchuck (Marmota monax). *Endocrinology*, **5**, 33.

—— 1924. A quantitative study of the human hypophysis cerebri, or pituitary body. *Endocrinology*, **8**, 509.

Retzius, Gustav. 1894. Neuroglia der Neuro-hypophyse. *Biol. Untersuchungen;* Neue Folge, **6**, 21.

Tello, F. 1912. Algunas observaciones sobre la histologia de la hypofisis humana. *Trab. d. lab. de invest. biol.* **10**, 145.

Section XVI
THE PINEAL GLAND

CONTENTS

Section XVI

PAGE

I. Comparative Anatomy 504
II. Comparative Embryology 505
III. Comparative Cytology 506
1. Cyclostomes 506
2. Selachians 508
3. Ganoids 509
4. Teleosts 509
5. Amphibia 511
6. Reptilia 511
7. Birds 512
8. Mammals 514
9. Homo sapiens 525
10. Summary of cytological evidence in mammals 532
IV. Physiological Significance 537
1. Feeding experiments 537
2. Injection experiments 538
3. Experimental removal of pineal body 539
Mammals 540
V. Clinico-Pathological Evidence 541
VI. Conclusions 542
VII. Bibliography 543

Section XVI

THE PINEAL GLAND

FREDERICK TILNEY

INVESTIGATION of the pineal body, during the past hundred years, has uncovered some of the numerous difficulties to be overcome in the problem presented. In many essential details it has left our knowledge in an unsatisfactory state. There are two fundamental questions concerning the pineal. Is this structure an active endocrine gland? Or is it in man a mere vestigial remnant of an important organ possessed by some infrahuman animals? There can be no doubt that in certain lower vertebrates the pineal body has a function closely related to vision. In some it assumes the form of a definite gland. In still others it partakes of characters at once glandular and visuo-sensory.

If admitted to membership in the endocrine system, the pineal may be presumed to hold distinctive relations to other glands. Its closest associations in this respect are said to be with the testis, ovary and pituitary. In such an alignment the epiphysis would of necessity be related to those metabolic processes involved in somatic growth and sexual differentiation.

Thus the problem of the pineal body seems to run the gamut of many functional possibilities. There are not a few authorities who vigorously support its endocrinic claims as a human organ. Others quite as energetically cast doubt upon its functional significance.

The pineal body was known to the Greeks and called by them the *σῶμα κωνοίδες* and *κωναρίον* because of its conical shape. It was also termed the *epiphysis* because of its relation to the rest of the brain. Latin authors refer to it as the *turbo, corpus turbinatum, glandula turbinata, glandula piniformis, glandula conoides, conarium, penis cerebri* and *virga cerebri.*

Because of its resemblance to a pine cone, it was called by Chaussier and Willis the *corpus pineale.* It has been called by the Germans the *Zirbel* and *Zirbeldrüse,* a designation which doubtless has led to the more or less general use at present of the term pineal gland. Several of the early writers called it the *glandula superior* in contradistinction to the pituitary gland which was referred to as the *glandula inferior.* All of these terms were, in the main, devised to meet the conditions in man and higher mammals, and thus do not prove wholly satisfactory for certain of the lower vertebrates. Earlier workers, especially those who dealt with ichthyopsid and sauropsid forms, employed the terms epiphysis and corpus pineale with little discrimination. The complexity of the structure in the lower reptiles, in amphibia and in fish is such that it may only in a very general way be called the pineal. Many of the forms just mentioned present, instead of a single epiphyseal process, two well-marked structures projecting dorsad from the roof of the interbrain. Ontogenetically, both of these processes are connected with the epiphyseal anlage, and yet if one of them were called the epiphysis, which should it be and by what term should the other be designated?

In a certain respect the suggestion of Hill (1891) to call one process the *anterior epiphysis* and the other the *posterior epiphysis* has much to recommend it on morphological grounds. Unfortunately, connotation has so rigidly associated the term epiphysis with the much altered and modified conditions as they occur in man and mammals, as almost certainly to lead to confusion in the broader application proposed by Hill. More available, although not without their defects, are the proposals of Studnicka (1896), according to which the posterior epiphyseal process becomes the *pineal organ* and the anterior process the *parapineal organ*. The use of the term pineal at once reverts to the mammalian forms, for description of which it was first employed. To apply this term, for example, in the fish where it has no descriptive value, cannot be in accord with the best morphological tendencies. Yet to Studnicka should be accredited the most thorough and extensive consideration of this subject; his definitions may, for this reason, be regarded as standards, especially if the desire to avoid new terms is kept in mind.

Accepting Studnicka's terminology of an anterior process, the parapineal organ, and the posterior one, the pineal organ, it is necessary to recognize certain subdivisions in each of these organs. The pineal organ has an *end sac*, a *stalk* and a *proximal portion;* the latter in some cases is connected with the rest of the interbrain by means of a short, slightly constricted piece, the *peduncle*. The parapineal organ, likewise, has an *end sac*, a *stalk*, and a less well-defined *proximal portion*. Much variation exists in the forms presenting these several parts—in many instances one or more of the parts described may be absent—yet, to make the terminology as comprehensive as possible, all of these portions should be included. Upon this basis the following constituents may be recognized in the *epiphyseal complex:*

I. The pineal organ, consisting of
   1. An end vesicle
   2. A stalk
   3. A proximal portion
   4. A peduncle
II. The parapineal organ, consisting of
   1. An end vesicle
   2. A stalk
   3. A proximal portion

The proximal portion and peduncle of the pineal organ correspond to the epiphysis or corpus pineale of mammalian anatomy. The proximal portion is probably analogous to the cellular part of the pineal body, while the peduncle is comprised largely of nerve fibers.

I. COMPARATIVE ANATOMY

Cyclostomes. In cyclostomes the epiphyseal complex presents a pineal organ and a parapineal organ. Both of these lie in close apposition to each other, extending cephalodorsad in such a direction that their terminal portions come to overlie the dorsal sac.

Selachians. The pineal region in selachians is similar to that of *Petromyzon,* with the exception that the parapineal organ does not appear. The selachians are remarkable for another fact; namely, that one member of this class, *Torpedo,* develops no part whatsoever of the epiphyseal complex.

Ganoids. This region in ganoids is generally characterized by the absence of the parapineal organ. In *Amia* alone is there any rudiment of an anterior portion of the epiphyseal complex.

Teleosts. In teleosts the parapineal organ does not appear and the pineal organ itself is in a seemingly retrogressive condition.

Amphibia. Urodeles and *Apoda* possess only the pineal organ. In no other group of vertebrates is the pineal body so little developed. In *Anura* the epiphysis consists of the proximal saccular part of this structure and the end vesicle. The latter constitutes the "cutaneous gland."

Reptilia. In certain reptiles both the pineal and parapineal organs make their appearance. The parapineal organ gives rise to an eye-like structure called the *parietal eye.* This eye, however, is present only in the lower reptiles. The pineal organ, on the other hand, in many reptiles presents a well-developed appearance. No chapter in the morphology of the epiphysis is more replete with interest than that dealing with the remarkable conditions observed in this region of the brain in reptilia. From observations upon the Saurians and Pro-Saurians have come far-reaching theories into the phylogenesis of the vertebrates, and some illuminating efforts have been made to trace the evolution of this phylum through the unpaired parietal eye back to the invertebrates.

This eye which occurs in certain of the *Lacertilia* is, on the other hand, entirely absent in *Ophidians, Chelonians* and *Crocodilians.* In all reptiles, with the exception of *Lacertilia,* the epiphyseal complex is so rudimentary that only the proximal portion of the pineal organ remains. Indeed, in *Crocodilia* even this is said to be absent.

Aves. In birds the proximal portion of the pineal organ, the part usually called the epiphysis or corpus pineale, alone develops. It usually appears as a small circumscribed sac connected with the roof of the interbrain, or else it has a definitely glandular structure with true acini of varying size.

Mammals. The epiphysis in mammals undoubtedly represents the proximal portion of the pineal organ. It is a solid, more or less conical-shaped body connected with the roof of the interbrain by one or more sets of peduncles. As a result of the development of the corpus callosum, the epiphysis has gradually assumed a position which brings it into relation with the superior colliculi of the midbrain.

II. COMPARATIVE EMBRYOLOGY

The embryological development of the epiphyseal complex depends upon the appearance of two evaginations in the caudal portion of the diencephalic roof-plate. One or both of these evaginations may be suppressed. In some cases the pineal anlage alone develops; in others, only the parapineal.

In *Ammocoetes,* Gaskell called attention to a right and left pineal eye. It is his opinion that here the pineal and parapineal organs represent a paired set of eyes. Their relation to each other, in which the parapineal organ occupies the more cephalic position, was determined, according to Gaskell, by the exigencies of development. In reality, however, he believes that the ancestors of the vertebrates must have possessed a pair of median eyes.

In *Selachians* a single evagination arises in the roof-plate immediately in front of what is later to be the posterior commissure. This evagination gives rise to the pineal organ.

In *Urodeles* the anlage of the epiphyseal complex is a single saccular evagination from the roof of the interbrain.

A well developed eye in some *reptiles* has been the cause of much discussion as to the embryological process by means of which this structure is differentiated. According to the older view, the parietal eye arose, as in the case of the isolated end vesicle of amphibia, by a process of constriction from the terminal portion of the pineal organ. Subsequently the view was advanced that instead of a process of constriction it was rather a subdivision of a single evagination from the roof-plate which gave rise to the parietal eye; more recently, however, the opinion has been expressed by several observers, that the parietal eye owes its existence to an anlage quite independent from that of the pineal organ and situated anterior to the latter in its point of development from the roof-plate of the interbrain.

The description which holds good for the more primitive reptiles must be modified in dealing with the more highly organized and modern forms of this class. There is no evidence to show an attempt toward the development of the parietal eye in *Ophidia*, *Chelonia* or *Crocodilia*. In *Crocodilia* the anlage of the entire epiphyseal complex is said to be wanting.

In most *birds* the epiphyseal complex makes its first appearance as a single evagination.

The only portion of the epiphyseal complex which appears in the anlage in *mammals* is the proximal part of the pineal organ. There is little evidence of the parapineal element. At first this anlage is a simple evagination, then several lateral diverticula of about the same size make their appearance and later give rise to many follicles. The lumen of each follicle from the beginning is smaller than the acini in birds and is ultimately obliterated so that there are finally solid follicles surrounded by connective tissue and blood vessels.

III. COMPARATIVE CYTOLOGY

From the comparative cytology of the epiphyseal complex, it becomes evident that specialization in these organs has followed two main lines: First, the structures have either differentiated in the interest of forming visual organs or, second, they have given rise to glandular tissue. In some instances both of these tendencies may be observed; that is to say, in certain species the differentiation has been in the interest of visual apparatus in one part of the epiphyseal complex, while in another part distinct glandular tendencies are apparent. It seems advisable for the purpose of obtaining as comprehensive a view as possible of the cytology of this portion of the brain to consider the leading features of the finer structure in the pineal body of each of the classes of vertebrates.

1. *Cyclostomes:*

The striking cytological features in cyclostomes are the specializations in both pineal and parapineal organs toward the formation of visual structures. The end vesicle of the parapineal, as well as the pineal organ, presents a retina. This structure in the pineal organ contains cells of a distinct rod-like shape which have, therefore, been designated the *rod cells*. Other cellular elements are also observed in the ventral wall of the end vesicle, which

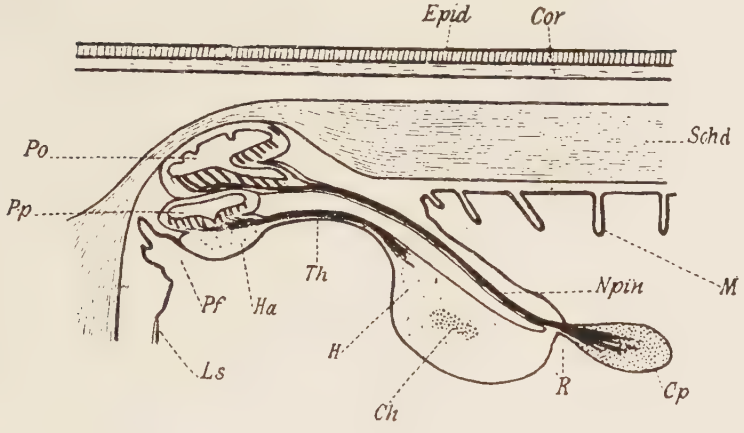

FIG. 223.

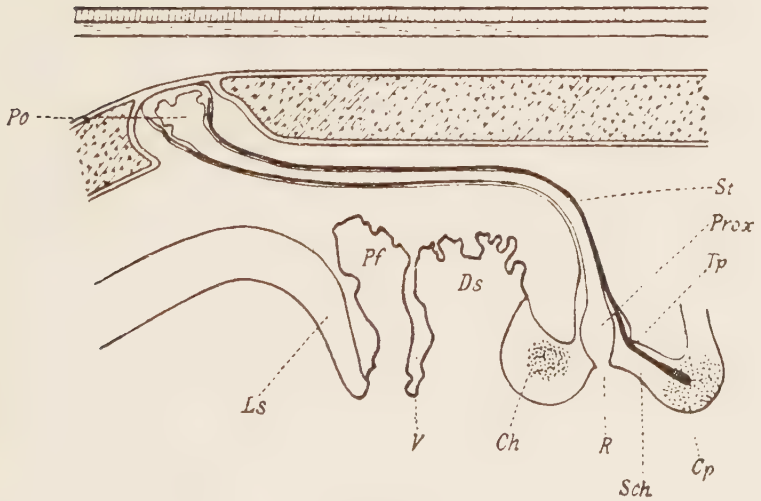

FIG. 224.

FIGS. 223 and 224.—Schematization of pineal region in Cyclostomes (Fig. 223). In Selachians (Fig. 224). Ls, lamina terminalis; V, velum transversum; Pf, paraphysis; Ds, dorsal sac; Ch, commisura habenularis; Po, pineal organ; Tp, tractus pinealis; Sch, pars intercalaris posterior; Cp, commisura posterior; M, midbrain; R, recessus pinealis; Pp, parapineal; Th, thalamus; H, habenula; Npin, neuropineal; Schd, skull. (After Studnicka, 1905.)

appear to be of a sensory nature. Certain large elements have been recognized in the deeper layers of the tissue and by some authorities are considered to be ganglionic cells. In addition, there are cells of an ependymal nature or modifications of the latter which give the impression of neuroglia tissue. There can be little question that the retina of this organ is well enough defined to deserve that designation. Whether it is actually functional as a visual organ is not altogether clear, for the relation of the pineal eye in cyclostomes to the surface of the head does not afford the most advantageous conditions for a distance receptor.

The end vesicle of the parapineal organ closely resembles the finer structure in the corresponding part of the pineal organ. There are, however, certain differences which are more those of degree than of kind. The rod cells, such conspicuous elements in the pineal organ, are less well defined in the parapineal organ and so also are the ganglionic cells.

The differentiation of the dorsal wall of the end vesicle in the pineal as well as in the parapineal organ manifests a tendency toward lens formation, for in both cases the cells in this region are entirely pigment-free and give rise to a translucent structure known as the *pellucida*. Further evidence of the visual adaptation observed in the end vesicle of the two structures of the epiphyseal complex is the fact that the cavity of the vesicle is filled with a coagulum in the meshes of a delicate syncytium, a structure which so closely resembles a primitive vitreous that it may be regarded as analogous, if not homologous, to that structure. The presence in the retina of a widely distributed white pigment lends the necessary opacity to the visual membrane. Both end vesicles contain this pigment; its presence serves further to convey the impression of differentiation along visual lines.

The stalks of both the pineal and parapineal organs bear a certain amount of confirmatory evidence in favor of the belief that the epiphyseal complex in cyclostomes has made the attempt at visual adaptation. Nerve fibers are uniformly observed in the stalks; those coming from the pineal end vesicle terminate in the posterior commissure, while those seemingly in connection with the parapineal end vesicle end in the habenular commissure. Some collateral evidence is afforded by the appearance of a parietal cornea, a fiberless tissue which surrounds the pineal and parapineal end vesicles.

All of these histological facts, based upon the observation of cyclostomes, indicate what may be considered an abortive, yet a well-advanced attempt to the formation of two eyes. There is no evidence of glandular formation in any part of the epiphyseal complex in cyclostomes.

2. *Selachians:*

The characteristics of finer structures, so conspicuous in *Petromyzon* and its congeners, are strikingly absent in the next higher order, the sela-

chians. In consequence of the apparent lack of differentiation, the entire parapineal organ is absent, while the pineal organ, although conspicuous for its size, shows no tendency toward the formation of a retina, pellucida, white pigment or nerve fibers. It is a question whether the pineal organ in selachians should be considered as a primitive organ or as one in a stage of retrogression. The walls of the end vesicle are made up exclusively of ependymal cells and contain neither spindle nor rod cells. In one form, *Scyllium*, Galeotti (1897) described a peculiar appearance of the cells of the end vesicle which seemed to indicate a secretory function. This conclusion of Galeotti's depends on the appearance of fuchsinophile granules not only in the nuclei of the cells, but also scattered diffusely throughout the cytoplasm. Studnicka also recognized these cells and, while he was unwilling to attribute any definite function to them, he was of the opinion that they could not be secretory in nature.

It is apparent, therefore, in passing from the cyclostomes to the selachians that there is a striking absence of any visual differentiation or any tendency in this direction, while the presence of certain cytological characters in the cells furnishes evidence pointing to a possible glandular formation in the end vesicle of the pineal organ.

3. *Ganoids:*

The pineal organ alone develops in ganoids, although in a single form, namely, *Amia*, an abortive parapineal organ makes its appearance. The end vesicle of the pineal organ in ganoids generally shows some tendency toward the development of a retinal or pellucidal layer, although neither of these is well marked. Studnicka, as the result of his studies upon ganoids, does not believe that there is any evidence of glandular activity in the end vesicle or proximal portion in selachians. On the other hand, he does not deny that there may possibly be secretory function in the pineal organ of ganoids.

4. *Teleosts:*

The epiphyseal complex in teleosts differs from that in selachians and ganoids in being a much larger structure. The end vesicle, furthermore, manifests in nearly every species a pronounced tendency toward the convolution of its walls. Not only is this process apparent upon the surface, but section of the vesicle shows it to consist of many folds and diverticula, all of which give to it the appearance of a tubular gland in communication with the third ventricle by means of a long hollow stalk. Galeotti (1897), in *Leuciscus*, found evidence of secretory activity in the presence of fuchsinophile granules similar to those described by him in selachians. The product of this secretion, he thinks, is delivered to the lumen of the end vesicle and thus to the ventricle of the diencephalon. Studnicka observed

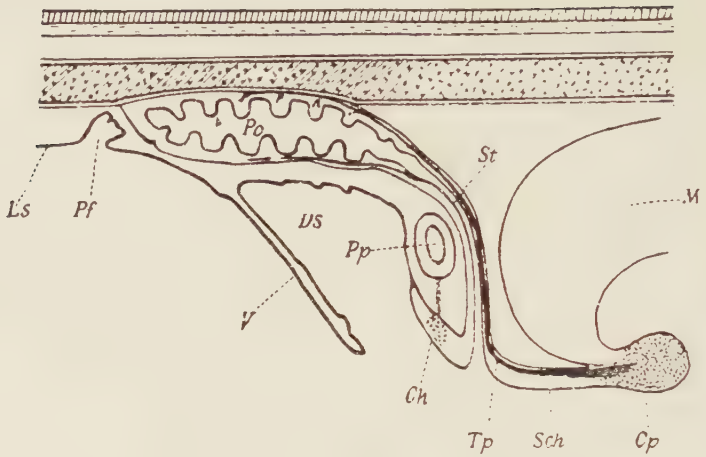

FIG. 225.

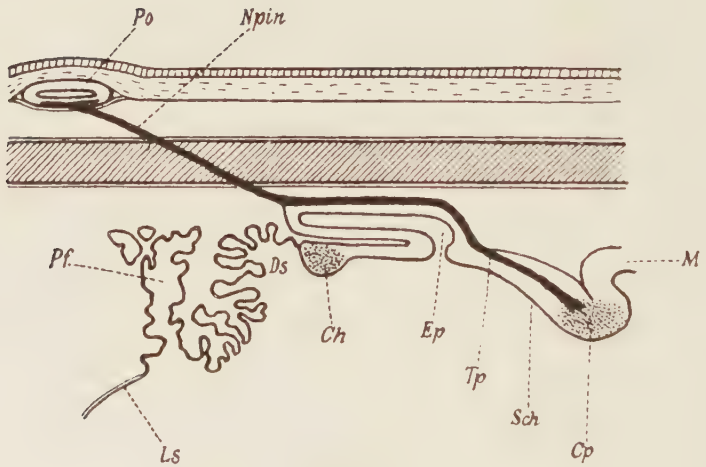

FIG. 226.

FIGS. 225 and 226.—Schematization of pineal region in Teleoists (Fig. 225). In Amphibia (Fig. 226). Ls, lamina terminalis; v, velum transversum; Pf, paraphysis; Ds, dorsal sac; Ch, commissura habenularis; Po, pineal organ; Ep, proximal portion pineal organ; Tp, tractus pinealis; Sch, pars intercalaris posterior; Cp, commissura posterior; M, midbrain; Pp, parapineal; St, stalk of pineal organ; Npin, neuro pineal. (After Studnicka, 1905.)

cells having a similar appearance, and although he did not commit himself definitely as to their nature, he nevertheless expressed the belief that the organ is not entirely a gland. Some nerve fibers of the stalk seem to represent a rudimentary pineal nerve.

5. Amphibia:

The first recognition and description given by Stieda (1865) in which he called the end vesicle a frontal subcutaneous gland, was evidently a misinterpretation of the conditions in amphibia. The end vesicle in these animals is fairly well developed, presenting a retina and lens which, although clearly recognizable as such, have attained scarcely more than an abortive state in their development. A long slender stalk made up almost exclusively of nerve fibers connects this organ with the tip of the proximal portion and constitutes a *nervus pinealis*, in the strict sense, which terminates in the posterior commissure. Galeotti, (1897), in *Spelerpes fuscus*, observed evidence of secretory activity, and this he also found in *Bufo* and *Rana*. The evidence of secretory activity depended upon the appearance of fuchsinophile granules in the cytoplasm. Studnicka, following Galeotti, found, as he had previously observed in selachians and teleosts, many cells in adult amphibia containing cytoplasmic granules. These he interpreted as cells having a sensory nature. Galeotti based his belief of secretory activity in the pineal organ not merely upon the presence of fuchsionphile granules, but quite as much upon epithelial characters of the cells which were arranged in alveoli, thus giving the end vesicle and the proximal portion a glandular appearance.

It is apparent from this evidence that amphibia in general present a very abortive attempt toward the formation of retinal and lenticular structures, while the end vesicle and the proximal portion of the pineal organ both show some evidence of glandular formation.

6. Reptilia:

The finer structure of the epiphyseal complex in the primitive reptiles, including *Sphenodon*, shows that in these forms the parapineal organ attains its highest differentiation as a visual structure. The pineal organ, however, shows no tendency whatsoever in this direction, while, on the other hand, its proximal portion affords many indications that its differentiation has been along glandular lines. In ophidia and chelonia the proximal portion of the pineal organ alone persists and has the appearance of a highly vascular, richly branched, tubular gland. The structure generally known as the parietal eye is a prominent morphological feature in primitive forms of reptiles. It is absent in certain geckonidae and in a number of agamidae. It attains its greatest differentiation in *Sphenodon* and here presents a well-marked retina, lens, vitreous, cornea and nerve, the latter

connected with the ganglion habenulae. The accessory structures related to the parietal eye, including the cornea, parietal fossa and parietal spot, all give evidence of an almost complete adaptation for visual function.

Studnicka believes that the rich capillary blood supply in ophidia speaks in favor of the glandular nature of the organ, its secretion being contributed to the blood stream. In chelonia the cellular elements are mostly ependymal and neurogliar and no nerve cells or nerve elements are found. There is, however, no clear evidence of the secretory nature of the epiphyseal complex in these forms.

The conclusions which may be drawn with reference to reptiles seem to indicate that in the primitive forms the parapineal organ assumes the highest differentiation which it attains as a visual structure. There is some evidence that the pineal organ, even in these animals, manifests a tendency toward glandular formation. In ophidians, however, there can scarcely be a doubt that the proximal portion of the pineal organ is the only element which persists and that it has a definitely glandular structure. This is probably true also in chelonians. The pineal gland in the snake and turtle probably contributes its secretion to the blood stream, but may also impart a portion of it to the cerebrospinal fluid. The more recent reptiles manifest no disposition on the part of the epiphyseal complex to develop any sensory or other type of neural mechanism.

7. Birds:

The conspicuous change in the epiphyseal complex noted in the transition from the primitive reptiles to those of more recent history is strikingly emphasized when the conditions in this region of the brain in birds are reviewed. Here, as in the snakes and turtles, there is complete suppression of the parapineal organ, and that tendency toward the differentiation of a visual apparatus which seems to have reached its height in *Sphenodon*, has so far receded as to leave no indication in birds of its earlier existence. This histological feature of itself is highly significant. When taken in conjunction with the appearance offered by the finer structure of the pineal body in birds, it seems to set all doubt aside as to the inherent tendency of the epiphyseal complex along its major lines of differentiation. In every species of birds which has so far come under observation, the differentiation in the pineal body has been in the interest of glandular formation. This evidence is not alone to be found in the character of the cells which compose the body, but even more in the arrangement of these cells whose alveolar patterns constitute irrefutable reasons for regarding the epiphysis as a true gland in birds.

Three types of this gland are found in the avian forms; namely, (1) the tubular type in which the secretion is delivered to the ventricular system, (2) the endocrinic type, in which the secretion reaches the blood

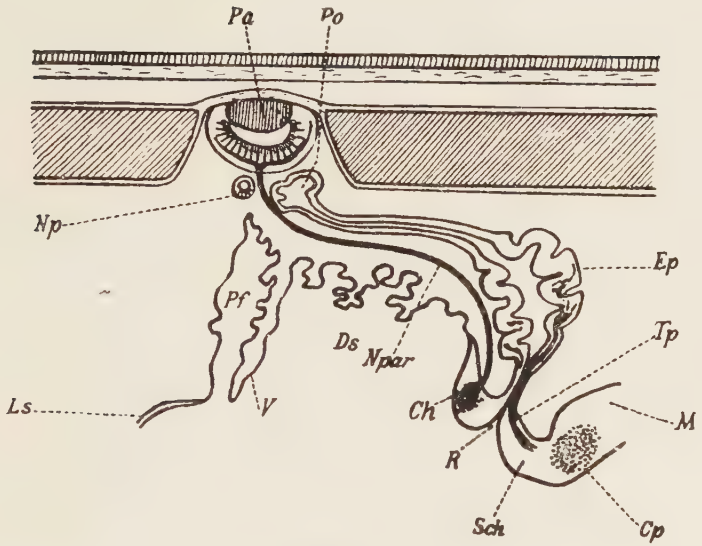

FIG. 227.

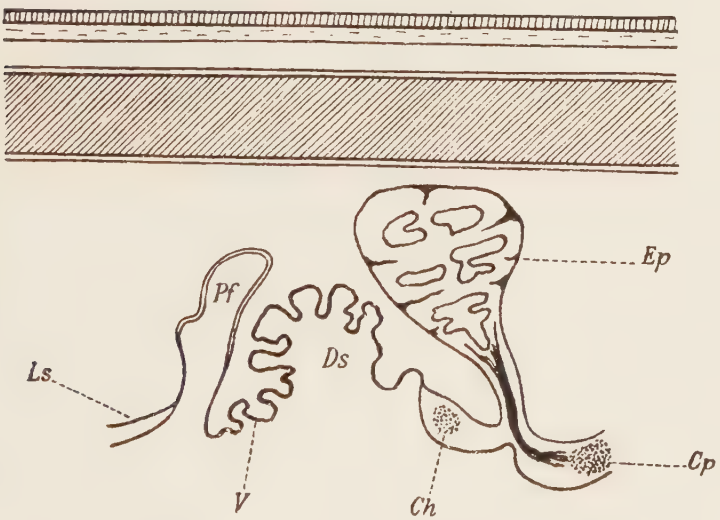

FIG. 228.

FIGS. 227 and 228.—Schematization of the pineal region in Sphenoden (Fig. 227). In Ophidia (Fig. 228). Ls, lamina terminalis; v, velum transversum; Pf, paraphysis; Ds, dorsal sac; Ch, commissura habenularis; Pa, parapineal organ; Npar, nervus parapinealis; Po, pineal organ; Ep, proximal portion pineal organ; Tp, tractus pinealis; Sch, pars intercalaris posterior; Cp, commisura posterior; M, midbrain; Np, accessory parapineal organ; R, recessus pinealis. (After Studnicka, 1905.)

stream, and (3) a mixed type, partaking of the character of each of the former varieties. This evidence afforded by birds is so conclusively in favor of the glandular nature of the epiphysis as to leave no grounds for dispute.

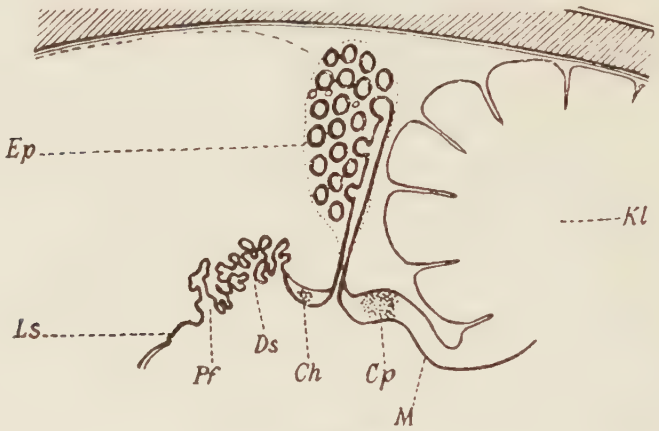

FIG. 229.

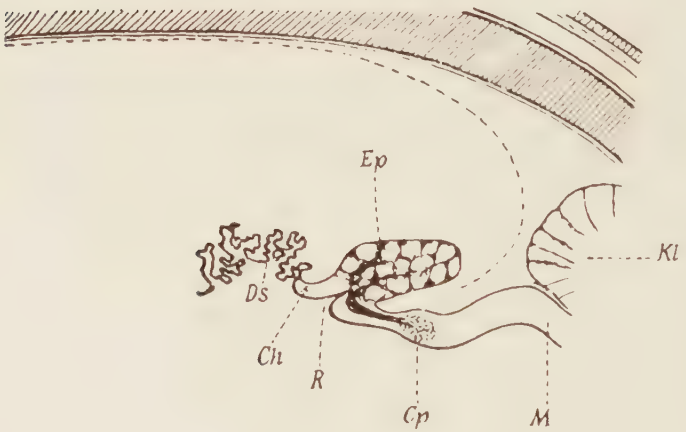

FIG. 230.

FIGS. 229 and 230.—Schematization of the pineal region in Aves (Fig. 229); in Mammals (Fig. 230). Ds, dorsal sac; Ch, commissura habenularis; R, recessus pinealis; Ep, proximal portion of the pineal organ (epiphysis); Cp, commissura posterior; M, midbrain; Kl, cerebellum; Ls, lamina terminalis; Pf, paraphysis. (After Studnicka, 1905.)

8. *Mammals:*

In considering the cytological character of the pineal body in mammals, concerning which there is much difference of opinion, it is advantageous to discuss the ectodermogenic and mesodermogenic elements entering the

body. Of the elements derived from the ectoderm the following have been observed: (1) parenchymal cells, (2) ependymal cells, (3) neuroglial cells, (4) ganglionic cells and (5) nerve cells. The following elements derived from the mesoderm have been described: (1) connective tissue cells, (2) connective tissue trabeculae, (3) blood vessels, (4) certain cells called muscle or myoid cells, (5) lymphocytes and (6) lymphoid reticulum.

Hollard, in 1837, regarded the epiphysis as a glandular structure with nerve fibers in its peduncle only. Valentin, in 1843, believed that the pineal body possessed a parenchyma which was something entirely different from the gray matter of the brain. He

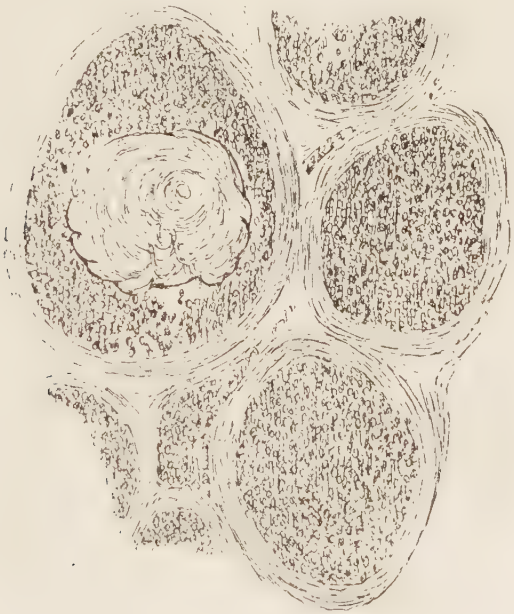

FIG. 231.—Follicles and parenchyma of pineal body in man, showing concretion of brain sand. (After Henle, 1879.)

observed certain "nuclear formations" which had a striking resemblance to the tissue of the pituitary gland. Kölliker, in 1850, described the epiphysis in mammals as consisting of small, round cells, multipolar nerve cells and compact bundles of nerve fibers. But it is to Faivre, in 1855, that we are indebted for the first extensive study in the comparative histology of the epiphysis. Faivre investigated microscopically the pineal body of man, horse, guinea pig, dog, ox, rabbit and pig. He recognized three elements in the human pineal body, i.e., (1) a fibrovascular envelope, (2) a globular parenchyma and (3) acervulus cerebri. Faivre's observation was in accord with Valentin's, that the pineal body differs essentially from the brain. He concludes that the parenchyma is made up largely of those globules which were nuclei of large elliptical cells in the organ. He seems to have been the first to recognize that these cells contained granules and also that the parenchymal cells were smaller in the child than in the adult.

Calrke, in 1860, found nerve fibers, nuclei and brain sand, but no nerve cells. These elements were arranged in a reticular structure which resembled the olfactory mucous membrane. Luys, in 1865, considered the organ as a structure composed of nerve cells and fibers, in general analogous to the mammillary bodies. Leydig, in 1868, stated that the pineal body in the mouse resembles the pituitary gland in reptiles with certain small differences. Frey, in 1867, observed in adults multipolar ganglionic cells, rounded cells without prolongations and isolated nerve tubes. Meynert (1877) asserted that the parallelism between the pituitary body and the epiphysis is a mistaken idea. The pineal body should be considered a ganglionic derivation of the tegmentum. It contains two types of cells, one having a diameter of 15 micromillimeters, the other of 6 micromillimeters. It differs from the other ganglia only in the fact that the cells are much closer together. Krause (1868) described nerve fibers in the epiphysis having a double contour. Stieda (1868) observed anastomosing processes of cytoplasm with nuclei in a reticulum. Bizzozero (1871) found two distinct elements in the organ, namely, stroma consisting of prolongations of the capsule and a definite parenchyma. In this latter were two types of cells. In the larger of these the cytoplasm contained granules. He noted that the pineal gland in the newborn and in the infant contains the same elements as in the adult. The only difference is in the fact that the smaller elements have a few branches, while the larger cells have none. The cells are arranged in alveoli.

Meynert, in 1877, concluded that the epiphysis was a nerve ganglion. Hagemann, in 1872, found two types of epithelial cells, namely, round cells and fusiform cells which are bipolar and multipolar nerve cells. The pineal body, in his opinion, is a combination of epithelial cells and nerve cells. Cruveilhier (1877) found in the epiphysis pale, round cells, small nerve cells, large multipolar cells and calcareous concretions. Mihalkovics (1877) concluded that the pineal cells were not lymphatic corpuscles, but resembled the cells in the lining of the cerebral ventricles. Schwalbe (1881) considered the pineal cells to be modified epithelium with a striking resemblance to lymphatic corpuscles. Cionini (1885 to 1886) first demonstrated the presence of neuroglial elements, the nerve fibers observed belonging to the blood vessels. Darkschewitsch (1886) refuted the idea that the pineal body is nothing more than a "simple gland." By the Weigert method he found the nerve fibers from the following sources: (1) internal capsule, (2) striae medullares, (3) Meynert's bundle, (4) optic tract and (5) posterior commissure. Meynert and Pawlowsky have already noted the connection between the posterior commissure and the pineal body. Henle (1887) considered the pineal body as a lymphatic ganglion. Its parenchyma consisted of two types of cells, round cells resembling lymph corpuscles and angular cells with many points.

Ellenberger (1888) maintained that the pineal body in the horse is very similar to a lymphatic gland. It is highly vascular; in it are but a few nerve fibers and these are difficult to trace to their origin. Flesch (1888) studied the pineal body in the horse, pig, dog, bat and man. He was able to find brain sand in man only. He does not believe that the organ is rudimentary, but regards it as an epithelial structure. There are some nerve fibers in it. Its relation to the size of the brain is not definite. It has, in Flesch's opinion, a physiological action in mammals, is very vascular, while its specific cells contain pigment granules. It seems to be a secretory organ and may contain a heat-regulating center.

Edinger (1897) found the pineal body in higher mammals to be formed of neuroglia cells. True nerve elements are absent. Chauveau (1885) observed groups of polyhedral cells separated by connective tissue trabeculae. He also mentions calcareous deposits in domestic animals. Mingazzini (1889) believes the pineal elements resemble lymphatic corpuscles. Soury (1899) found a substance like adenoid tissue filling the spaces of a fine network. Weigert (1895) described the pineal body, especially its ventral portion, as composed of a thick layer of neuroglia fibers of such a specific nature that the like

FIG. 232.—A striated muscle fiber from pineal body of Bos taurus. (After Dimitrova, 1901.)

of it is not found elsewhere in the central nervous system. The cells are very numerous and traversed by many fibers. Cajal (1895) found sympathetic fibers entering the pineal body with the vessels. These fibers form a rich interstitial plexus. The fibers surround but do not penetrate the cytoplasm of the glandular cells. Galeotti (1897) makes the claim that the pineal body is a secretory organ and believes there is evidence of this in many vertebrates besides mammals. The pineal cells elaborate a pigment in addition to their secretory product. He recognized nerve cells which are in relation with the superior and posterior commissures, ependymal cells constituting the middle portion of the body, in relation with the pineal recess, and epithelial cells which constitute the epiphyseal tube in some animals and the epiphysis in mammals. Lord (1899) described the parenchyma of the human pineal body as formed of small stellate cells resembling those of adenoid tissue, together with other paler cells of variable size.

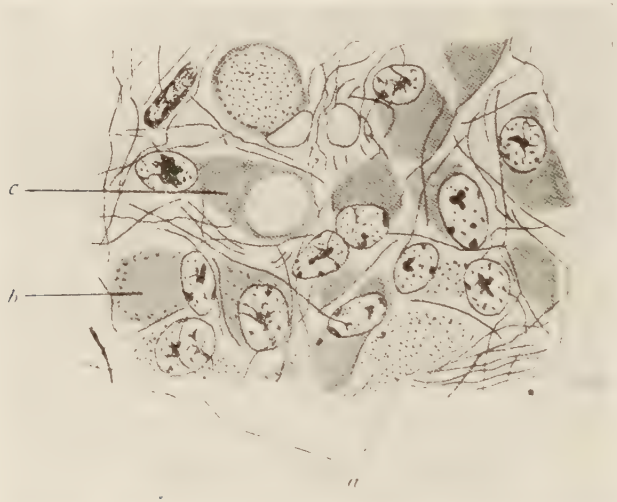

FIG. 233.—Cells with granular protoplasm in the pineal body of Bos taurus (Weigert's method). (After Dimitrova, 1901.)

Nicolas (1900) found striated muscle cells in the distal portion of the pineal body in the ox and calf. Dimitrova (1901), a pupil of Nicolas, studied the pineal body in mammals, young and old, including man, ox, calf, sheep, horse, dog and cat. She maintains that Nicolas' observations were confirmed by her studies and that striped muscle cells do occur in the pineal body of the ox and calf. In her opinion, the essential constituent of the epiphysis in mammals is neuroglia, and she concludes that in addition to the essential neuroglial nature of the pineal body there exist, in the ox, calf, sheep and dog, certain cavities which resemble thyroid vesicles or the anterior pituitary lobe. In young cats some cells which are independent of the neuroglia seem to resemble the elements described by Cajal and Retzius as sympathetic, and may be neuroglia cells in process of development. Favaro (1904) gave the following conclusions of his studies by means of the Weig-

ert method upon many mammals, including artiodactyla, perissodactyla, rodentia, insectivora, carnivora and primates. Fibers in relation to the pineal body are:

1. Prepineal fibers:
   a. Transverse commissural
   b. Oblique commissural
2. Fibrae seu fasciculus prepinealis
3. Pineal fibers
   a. Superior transverse commissural fibers
   b. Superior oblique commissural fibers
   c. Posterior transverse commissural fibers
   d. Diagonal commissural fibers
   e. Superior and posterior fibrae propriae.

Anglade and Ducos (1908 to 1909) found neuroglia constantly present in the human pineal body but also alveoli-formed cells of a different character. Sarteschi (1910) found that, as compared with the adult animals, the epiphysis in the young rabbit and guinea pig was distinctly more glandular and in this regard similar to the organ in birds. In the course of growth certain regressive changes occur. Neuroglia and glandular cells were present in all of the forms which Sarteschi studied. Constantini (1910) studied the pineal body of the ox, horse and man. He describes two types of epithelial cells, i.e., (1) acidophiles and (2) basophiles. He concludes that the pineal body in mammals is an organ of internal secretion. Cutore (1910), on the basis of a study of many different mammals, concludes that there are the following histological elements in the pineal body: (1) Epithelial cells containing granules and delimiting the cavities of tubules or acini; (2) Lymphatic elements very numerous in larger mammals and massed about the epithelial cells; (3) Connective tissue forming trabeculae producing an apparent trabeculation of the parenchyma. This connective tissue contains elastic fibers, blood vessels, lymph spaces and pigment cells probably belonging to the category of mast cells. Some of the latter cells give evidence of a process of fragmentation. (4) Calcareous concretions of calcium carbonate and phosphate. These latter are sometimes found as inclusions in the cytoplasm or in the meshes of the connective tissue. Cutore believes it to be an organ of complex structure, constituted of neuroglia, epithelium, lymphatic and connective tissues, so arranged as to form acini and so highy vascular that it cannot be considered to be in a state of regression, as is claimed by Möller, Charpy, Dejerine and others. Indeed, the highly specialized and characteristic structure of the pineal body is sufficient justification to attribute to it an internal secretory function. Galasescu and Urechia (1910) found, in the vicinity of some of the blood vessels, round and oval cells with deeply staining nuclei situated centrally in a cytoplasm which stains with acid stains, e.g., eosin and fuchsin. The

cytoplasm is granular and well demarcated. These acidophils resemble those seen in the parathyroids. The authors propose to term these cells the "Paravascular Acidophils." They believe these elements play a definite part in the internal secretion of the pineal body.

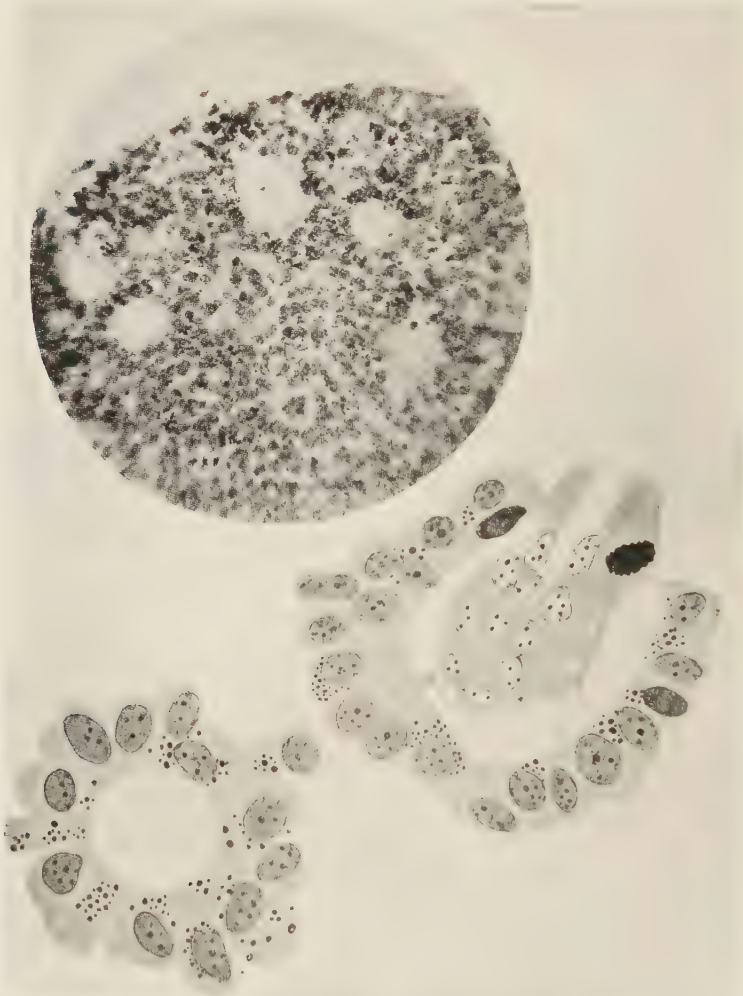

FIG. 234.—Histological characters of the pineal body in the sheep. (After Jordan, 1911.)

Krabbe (1911) studied one hundred human pineal bodies, both male and female, from birth to seven years of age, and from fourteen years to ninety-two. There was a gap in his subject between the ages of seven and fourteen years. He found two types of cells in the epiphysis: (1) special pineal cells

and (2) neuroglia cells. He thinks the granules in the cells leave the protoplasm, traverse the intercellular space to enter the blood, lymph or cerebrospinal fluid. Krabbe does not agree with Dimitrova that the fundamental

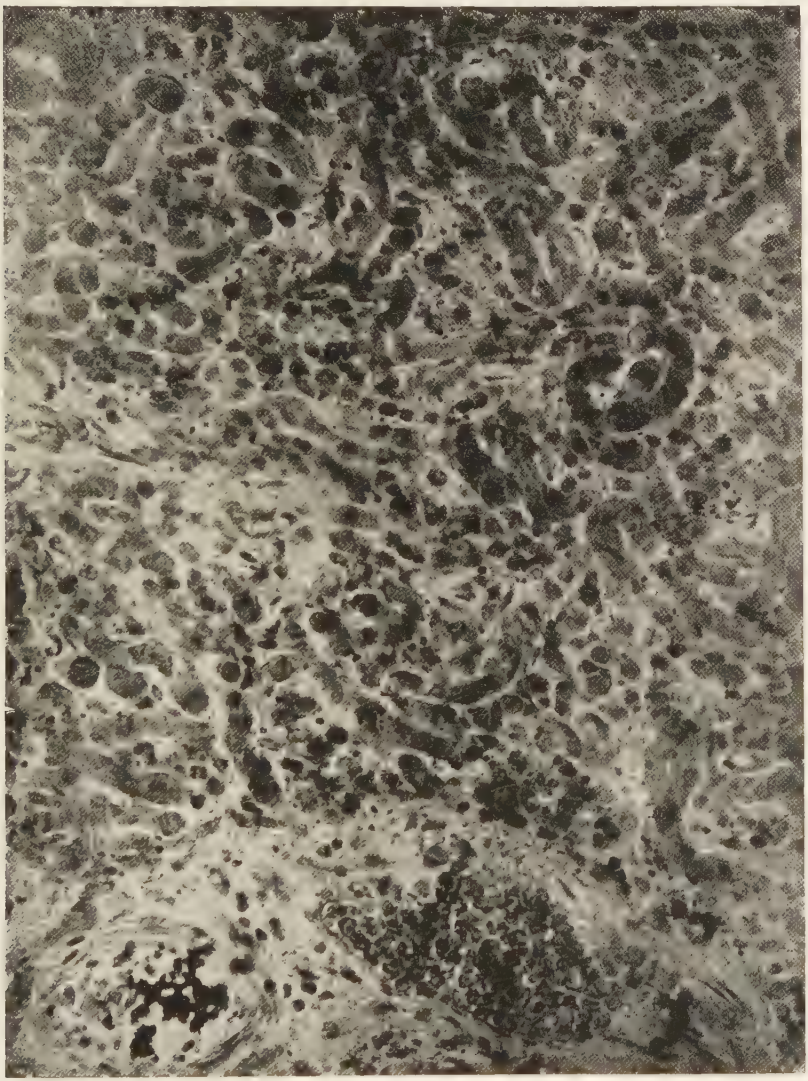

Fig. 235.—Section of pineal body in Macropus grayi. (After Tilney & Warren, 1917.)

element of the pineal body is neuroglia, for he considers her criteria in distinguishing neuroglia insufficient. He himself never observed muscle fibers in any of the forms which he studied. Krabbe concludes that the piphysics

in man shows certain signs of involution, as, for example, concretions, hyperplasia of connective tissue, neuroglial plaques with cysts, and the presence of cells in a state of disintegration. The involution begins at seven years of

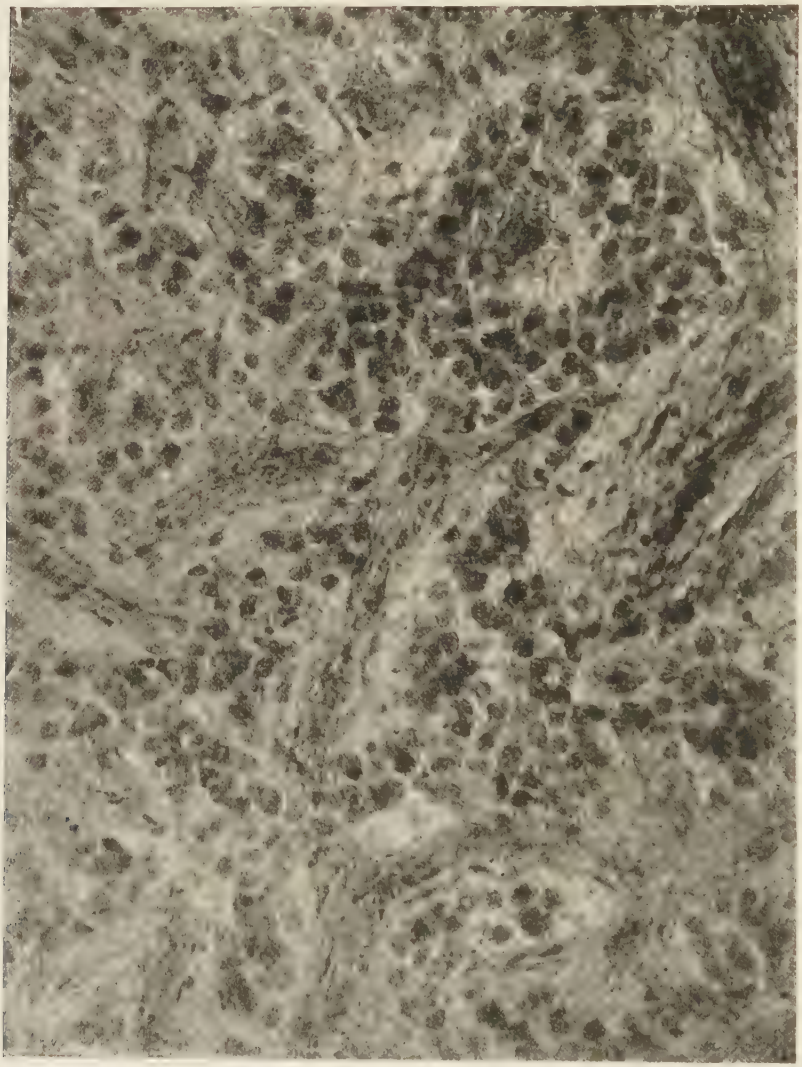

FIG. 236.—Section of pineal body in Capra hylocrius. (After Tilney & Warren, 1917.)

age, but even in the adult the pineal body shows signs of active function. The secretory process is manifest in the following manner: (1) basophilic granules in the nuclei; (2) the latter evacuated into cytoplasm. This process goes on during the entire life of the individual, even into old age.

Biondi (1912) called attention to the finding of Constantini and Galeotti of acidophils in the pineal body. Biondi made a special study for mitochondria by the method of Regand. He was able to demonstrate small granules which he thinks must be regarded as mitochondria. This he cites as evidence of the secretory nature of the epiphysis. He calls attention to the fact, however, that Nageotte and Mawas have both stated that neuroglia cells also contain mitochondria.

Jordan (1911) following the histogenesis of the pineal body of the sheep, studied six stages from 5 cm. to 21 cm., also of the eight-months-old lamb, yearling and old sheep. He found no muscle fibers. Between birth and the first year the pineal body increases fivefold in size. In the fetus there are blind alveoli and the organ is definitely lobulated by ingrowths from the pia. Parenchymal cells form these alveoli. Vascular follicles are abundant. The parenchyma consists of a more or less differentiated ependyma. After the first year there are signs of local degeneration manifesting themselves as an increase in connective tissue, neuroglia, brain sand, clumps of pigment granules, and a decrease of parenchymal cells. The entire pineal body decreases in size after the first year. He concludes that there is no cytological evidence in favor of the secretory function of the sheep's pineal body. He points out, however, that the general structure of the epiphysis, including its lobulation, its connective tissue framework, its parenchymal follicles, blind alveoli, perivascular lymph spaces, great vascularity, and presence of cytoplasmic granules, is indicative of a glandular function of internal secretion. He interprets the cysts which appear in the pineal body and the melanic cytoplasmic granules as probably having an ancestral significance. In Jordan's opinion, if the pineal body subserves any important function at all, this is true only of the first eight months of postnatal life. Jordan in the same year, studying the pineal body in the opossum, states that the organ in this species has two forms: one, long and tubular as in birds, and the other short and cup-shaped, resembling particularly that of carnivora. The epiphysis is composed of a syncytical network, in the meshes of which are scattered more or less highly differentiated or modified ependymal cells and delicate bundles of nerve fibers. In the opossum it appears to be in a state of instability. Its long tubular form connects it phylogenetically with the birds and reptiles, while its short, cup-shaped form affiliates it with the carnivora. Regarding the function of the pineal body in the opossum, Jordan believes that his observations show it to be unimportant in the body metabolism of mammals. This does not necessarily mean that there is no specific secretion from the organ, but rather that it has no direct or indirect influence upon vegetative functions.

Nerve fibers in the mammalian epiphysis have been observed by Kölliker (1850) who appears to be the first to demonstrate these elements. Krause (1868) recognized the fact that the fibers have a double contour,

and Darkschewitsch (1886) showed that they were myelinated nerve fibers. Connections have been demonstrated to exist between the pineal body by means of these fibers with the following parts: (1) internal capsule; (2)

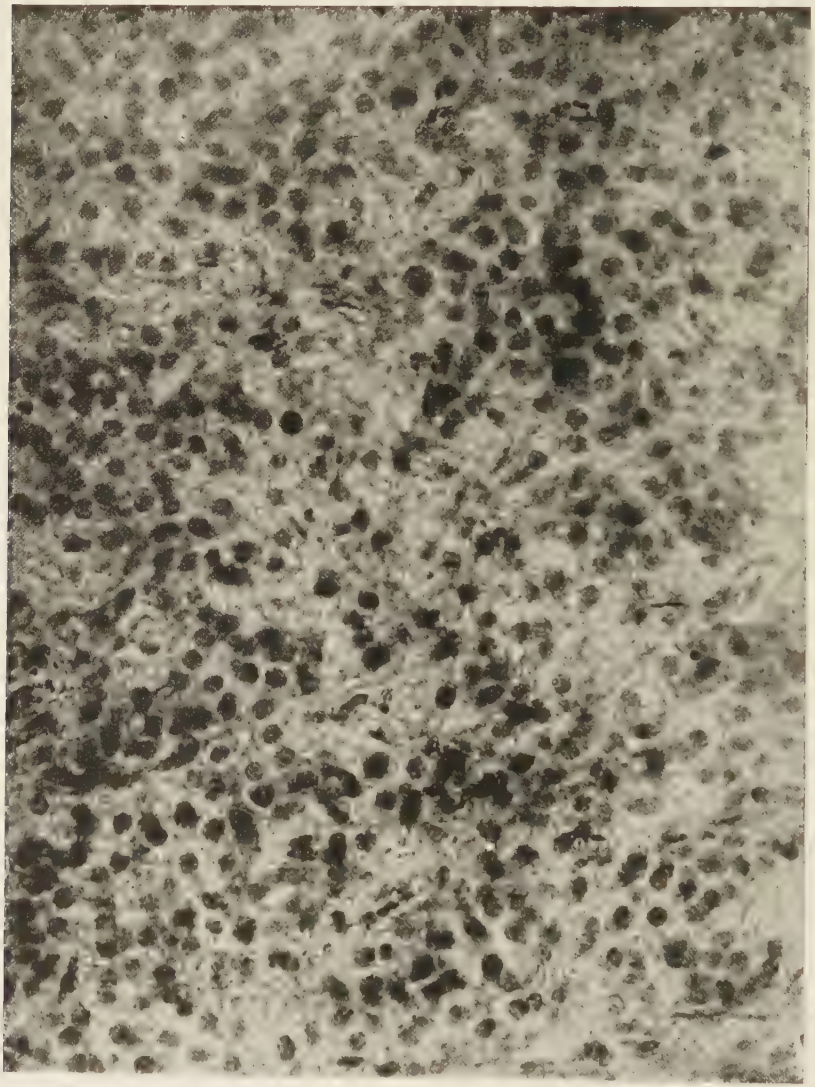

FIG. 237.—Section of the pineal body in Zalophus californianus. (After Tilney and Warren, 1917.)

striae medullares; (3) Meynert's bundle; (4) optic tract by Darkschewitsch (1886); (5) posterior commissure by Meynert (1877) Pawlowsky (1874), Cionini (1888), Favaro (1904) and Cutore (1910); (6) commissura

habenularis by Kölliker (1850), Hagemann (1872), Favaro (1904), and Cutore (1910); (7) sympathetic system, by Henle (1879), Cionini (1886) and Cajal (1904).

Ganglion or nerve cells in the epiphysis have been described by Kölliker (1850) and Hagemann (1872). Cajal (1895) also found ganglion cells in the pineal body and described two types. Dimitrova (1901) was able to find ganglionic cells in young cats only.

Pigment has been found in the epiphysis of mammals by Flesch (1888). Galeotti (1897) observed pigment particles in the cytoplasm and nuclei. Dimitrova (1901) found a golden-brown pigment in the parenchymal cells. Cutore (1910) observed pigment in the pineal cells.

Brain sand has been described by many authors in a number of mammals. Haller (1768) considered it pathological, but Soemmering's classical study upon the acervulus clearly demonstrated that these concretions are normal in man. Malacarne in 1795 found brain sand in the epiphysis of the goat. Wenzel (1812) described it in man as being of two varieties according to its color, yellow or white. Hagemann (1872) considered it a normal constituent of the adult pineal body in man. He also observed it in the ox. Krause (1876) found it in many adult mammals. Flesch describes brain sand in the epiphysis of the horse, sheep, pig and dog.

9. *Homo sapiens:*

A large number of observers have given their attention to the pineal body in man and many diverse opinions have been expressed concerning it. In Cutore's summary giving the histology and dimensions of the pineal body in man, he concludes that the human pineal body develops slowly, retaining even up to the time of birth its primitive diverticular form. In the adult, however, this organ has become relatively voluminous and the original recess is much reduced to form the ventriculus or recessus pinealis. The superior or habenular commissure is small. The pineal fibers are limited in number and distributed to the inferior third of the organ. In the disposition of the parenchyma there is seen a distinct tendency for the cells to arrange themselves in circular areas clearly delimiting small cavities in which there appears an amorphous or crystalline substance. Elastic tissue is scanty, but pigment cells are numerous and concretions of varying sizes appear in large numbers. The vascularization is rich, especially around the aciniform groups of cells. Neuroglia and cylindrical ependymal cells are also present. Connective tissue processes from the pia mater form an irregular partition of tissue into lobules. Seigneur (1912) considers the pineal body in man a gland, the cells of which are of two types, those which are polyhedral with granules in the cytoplasm which are most numerous about the nucleus; some of these cells have vacuoles. The second type of cells are even larger and contain large nuclei which stain deeply and occupy

an excentric position in the protoplasm. In the newborn, lobation of the gland is much more easily discerned than in the later periods of life.

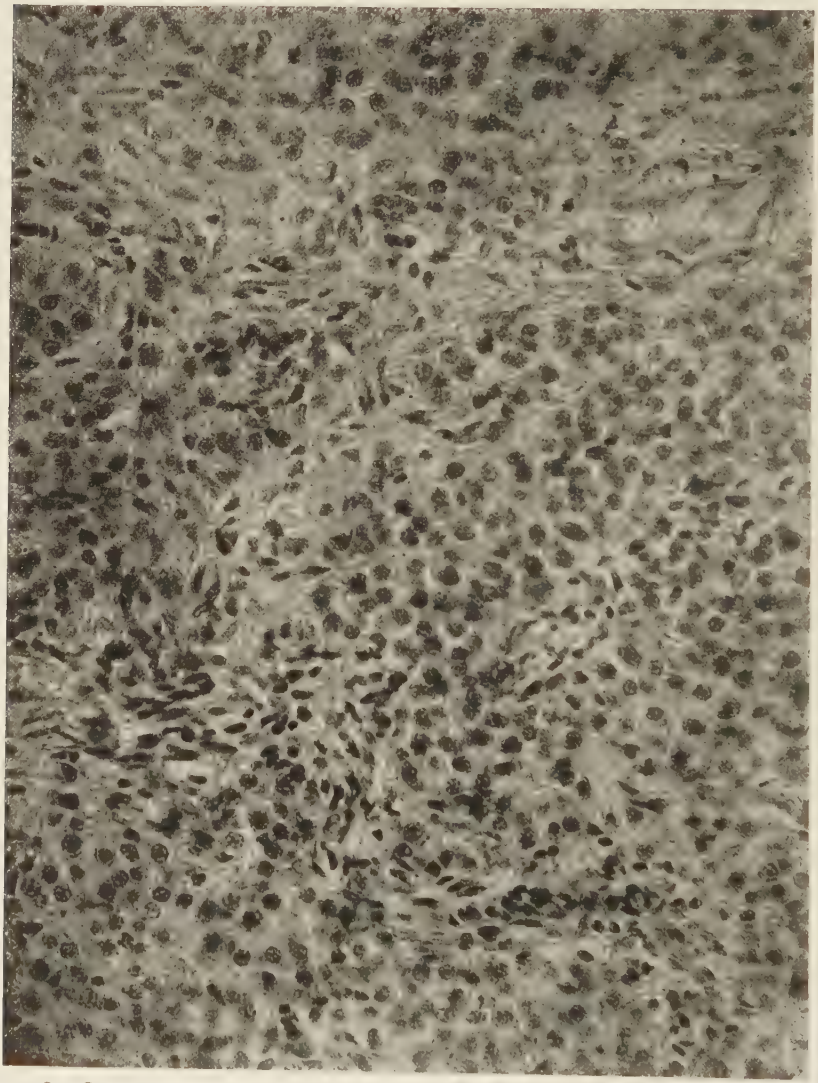

FIG. 238. Section of pineal body in Lepus cuniculus. (After Tilney & Warren, 1917.)

The writer believes that in the adult human pineal body the types of cells already described as present in the epiphysis of other mammals may be observed. The large cells with granular cytoplasm and large deeply staining nuclei are the most prominent elements. They are arranged in regular

masses very similar to those observed in *Simia satyrus*, although the intervening areas are less extensive, so that in man the cell masses seem to run into each other without a sharp line of demarcation. A dense network of

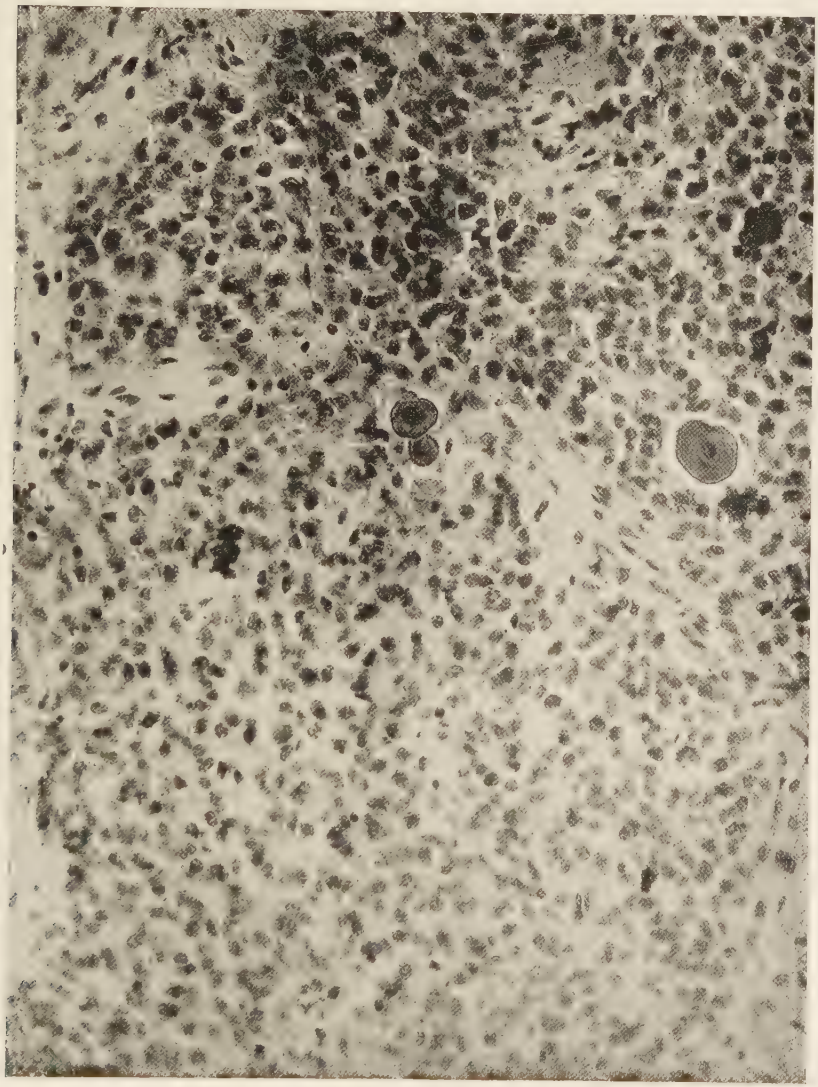

FIG. 239.—Section of the pineal body of human adult. (After Tilney and Warren, 1917.)

connective tissue trabeculae forms the framework of the organ, while the vascularity of the structure is richer than that of any other form observed. Concretions of varying sizes are present throughout the entire gland.

The histogenesis of the pineal gland was studied in the cat and human. The inception of differentiation in the cat presents itself as a marked thickening in the walls of the more caudal of the two epiphyseal evaginations.

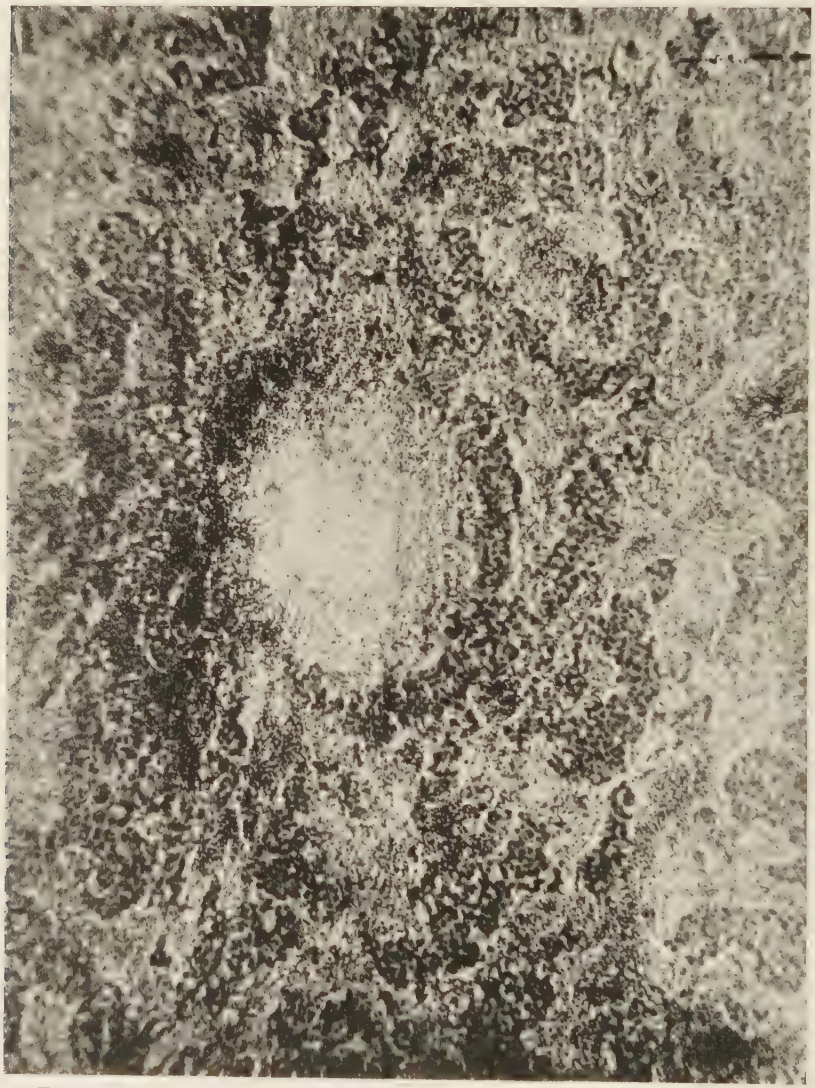

FIG. 240.—Section of the pineal body of a two months' old kitten. (After Tilney and Warren, 1917.)

In the 70 mm. cat this thickening is so pronounced that the recess in the anlage is reduced to a narrow lumen. The cells multiply at the caudal extremity of the now almost solid epiphysis. From the stage of 120 mm. to

term a process of diverticular formation occurs. This starts at the base of the gland at its attachment to the roof-plate and gradually extends to its

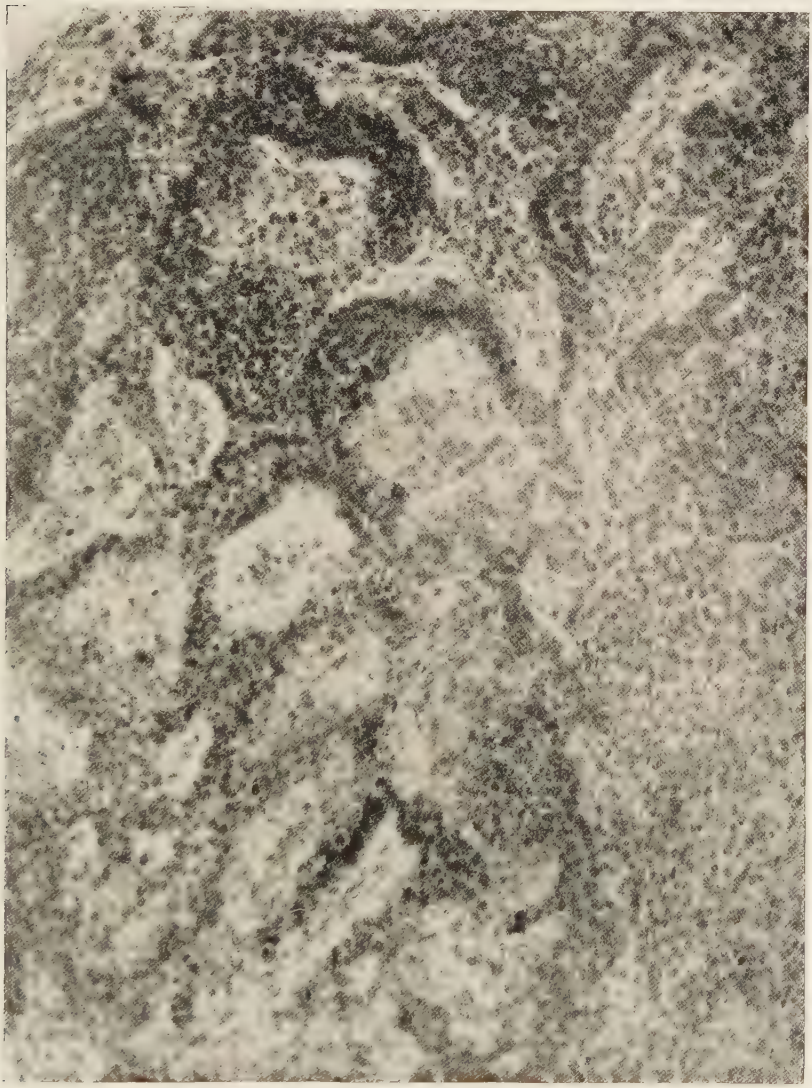

FIG. 241.—Section of the pineal body in a newlyborn infant showing the completion of the diverticular invasion from base to apex. (After Tilney & Warren, 1917.) × 300.

distal extremity. Many of these diverticula remain in connection with the third ventricle, but as they elongate toward the tip of the pineal body some of them lose this connection and finally appear as blind acini or cell cords.

In this way the original more or less indifferent cell area of the primitive anlage is invaded by cells from the diverticula above described. Simultaneous with the invasion of these diverticula, blood vessels are seen to

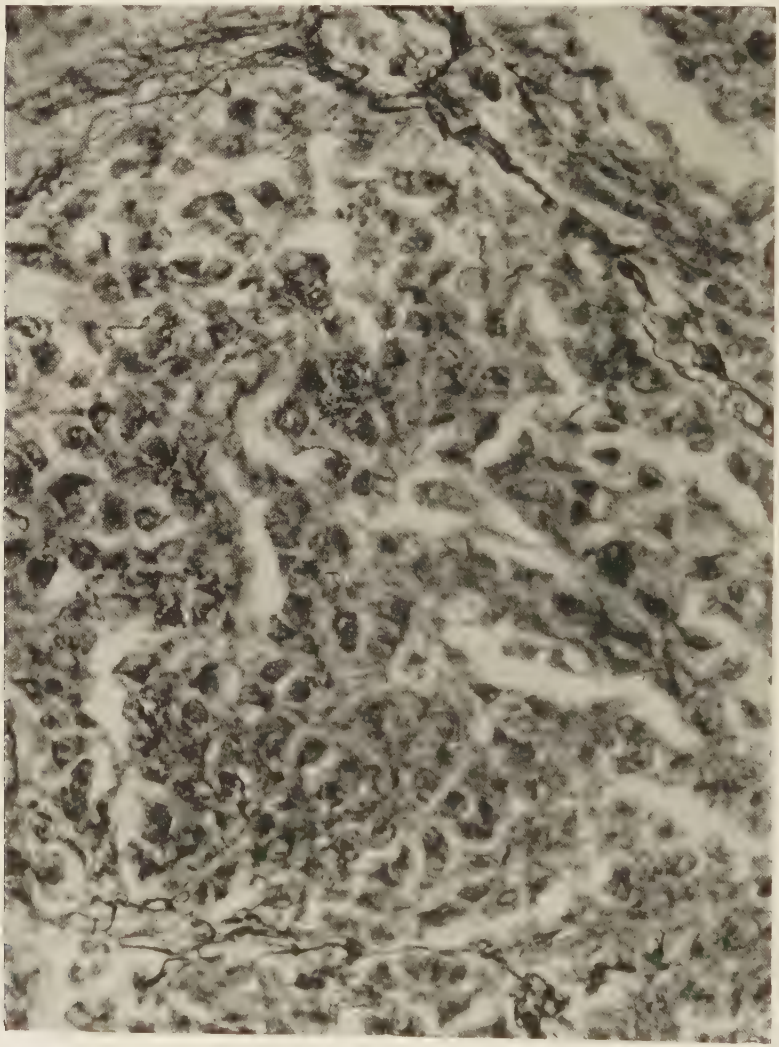

FIG. 242.—Human Pineal. (Bielschowsky.) × 500.

make their way into the tissue between the acini and cell cords. This vascular invasion seems to take place from the periphery going to the center, but it is possible that independent blood spaces are formed which, by concretion, subsequently form a vascular network, the latter coming into rela-

tion with the blood vessels surrounding the pineal body. This process in the histogenesis of the pineal body in the cat is better illustrated in the development of the human fetus. In man the process of diverticular inva-

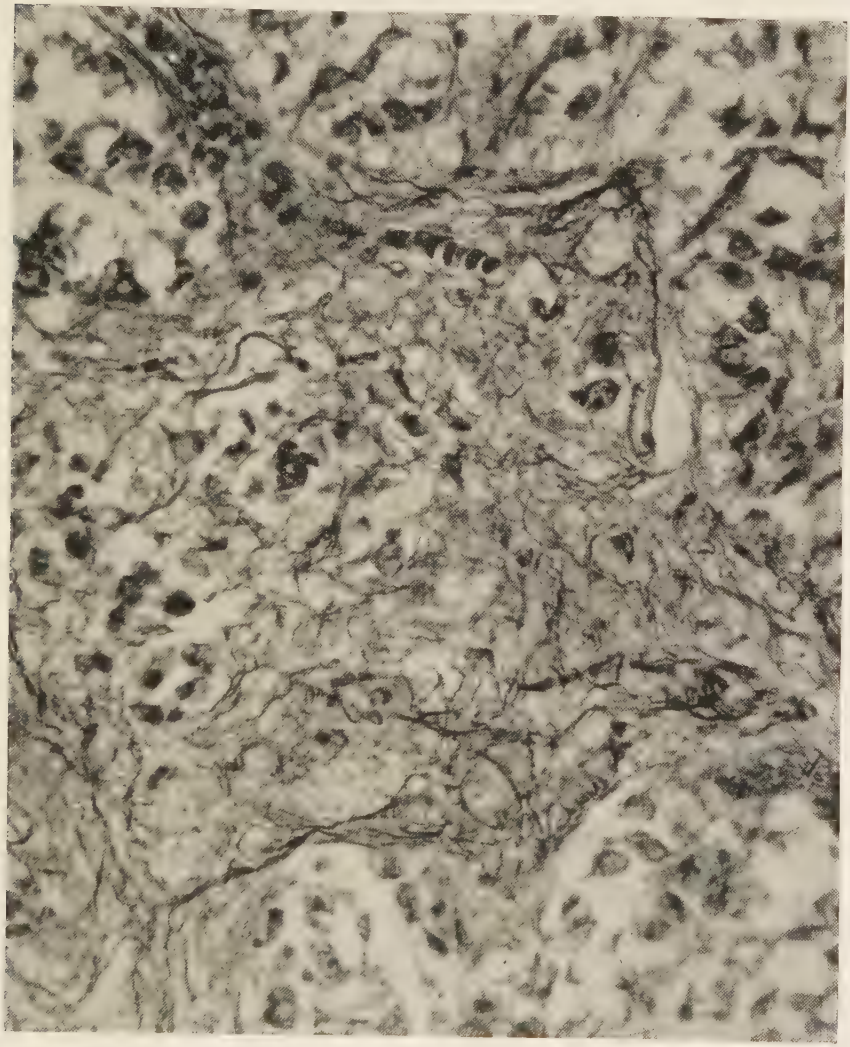

FIG. 243.—Human Pineal. (Bielschowsky.) × 500.

sion into the original cellular mass of the primitive anlage begins at the base of the epiphysis and manifests itself in a thick strand of darkly staining cells extending out and into a mass of undifferentiated tissue. At term the invasion has extended completely through the epiphysis and the deeply

staining strands of cells are now arranged in convoluted cords or take the form of apparent acini. In the meshes between these cords capillaries appear to have made their way in from the surface of the epiphysis and form a rich network about the cell cords and apparent acini. This ontogenetic differentiation in the two forms just described would certainly seem to indicate a process which had as its object the rich vascularization of discretely outlined epithelial areas. Such a differentiation would seem to adapt itself best to the purposes of internal secretion.

Marburg (1908) shows in the development of the human pineal gland histological appearances closely resembling those described by the writer. He maintains that in spite of all the involutional processes in the gland, it cannot be denied that even up to the late periods of life there are wholly intact glandular cells present in the organ which must certainly be taken to indicate a still existing function.

More recent studies of the comparative cytology of the pineal gland supply further evidence of the glandular nature of this structure in mammals. Figs. 244 to 247 give the appearance of the human gland contrasted with that of the dog and sheep. The human specimen is that of an adult, and shows clearly the tendency of the concretions of brain sand to form in consequence of concentric lamellation. Furthermore, the concretions begin in areas occupied by fairly well-defined aciniform collections of cells. Such aciniform arrangement is even more clearly shown in the pineal of the dog. Here also the cell cord arrangement of the large pineal cells is obvious. A similar tendency for the cells to take the form of cords is seen in the higher magnification of the human pineal (Fig. 246). While this is perhaps less conspicuous in the sheep pineal (Fig. 247), it is none the less obvious that the very large pineal cells are grouped as fairly well-defined acini scattered here and there among dense cords of pineal cells.

The vascularization of the pineal gland is well illustrated in the dog and in the sheep. The large, sinus-like blood spaces surrounding the aciniform groups of cells and the cell cords, is a striking histological feature. The actual presence of lymphatics in this tissue is difficult to discern. Many of the sinus-like blood spaces seem to be surrounded by irregular perivascular lacunae.

The tendency for the cells in the human pineal to arrange themselves in irregular acini is shown in Figures 242, 243 both of which are Bielschowsky preparations. The connective tissue trabeculae invest more or less well-defined areas which seem to have a definite aciniform arrangement.

10. Summary of cytological evidence in mammals:

It is perhaps in mammals that the most extensive observations have been made with reference to the cytology of the pineal body. Indeed, it is in these animals that the greatest variety of opinion has been expressed.

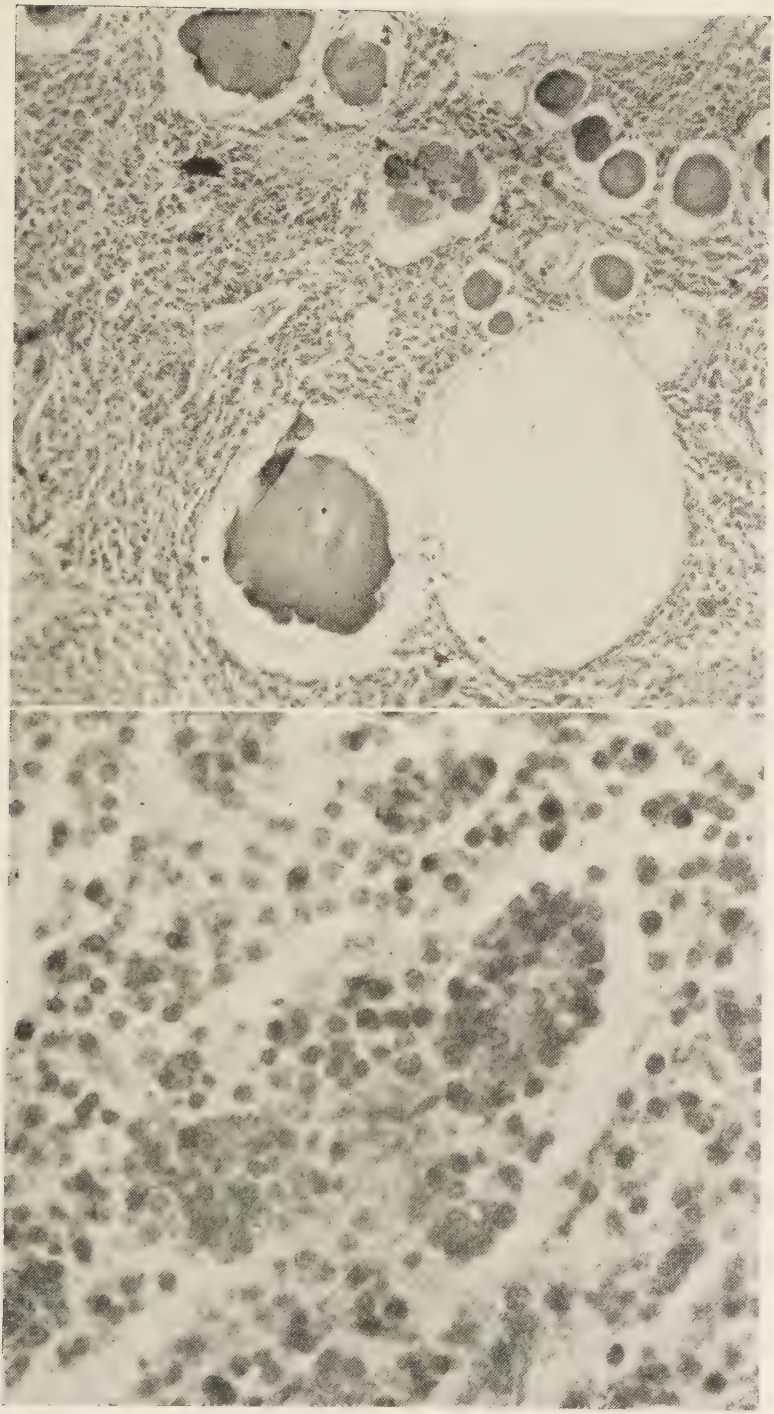

244

245

FIGS. 244 and 245.—Human Pineal (Fig. 244). Hematoxylin, eosin. × 95. Dog pineal (Fig. 245). Azur-eosin. × 700.

It would seem advisable to group these different views concerning the histological character of the organ.

A large group of investigators adheres to the belief that the pineal body is a blood vascular gland. This group includes, among others, Valentin, Faivre, Leydig, Bizzozero, Galeotti, Constantini, Cutore, Galasescu-Urechia, Krabbe, Biondi and Kidd. Jordan, although he does not advocate the improbability of glandular formation, believes that the organ is essentially neural in its structure.

Several investigators maintain that the epiphysis in mammals consists exclusively of neuroglia. Among these are Cionini, Edinger and Weigert. Mihalkovics believed that the cellular consistence of the pineal body in mammals was exclusively of the ependymal type. Those of another group assert that the epiphysis resembles a lymph gland. Of this opinion are Schwalbe, Henle, Ellenberger, Mingazzini and Lord.

Although it has been frequently claimed by many writers among both the early and recent workers in this field that the epiphysis is a vestige, it is interesting to note that no suggestion of such a possibility is made by any of the authorities just cited. This is of particular significance because this list includes the names of those who have given the most extensive attention to the histological character of the epiphysis in mammals. Milhakovicz' conception of the histology of the pineal body seems hardly tenable, for it requires but little study covering a number of different mammalian forms to become convinced that the cellular elements entering into the epiphysis have nothing in common with the ependymal cells. Even though it may be admitted that a certain number of the cellular constituents of the epiphysis are ependymal in type, it cannot, in the light of our present knowledge, be held that the organ is made up exclusively of this type of cells.

On the other hand, it is not possible to accede to the contention of those who uphold the idea that the epiphysis is similar to lymphatic glands. Not only does the character of the chief cellular elements in the pineal body of mammals make this position seem untenable, but even more does the arrangement of these cells point away from the supposition that this is in any sense lymphoid in character. Few cells in the body are more conspicuous for this histological character than the chief or parenchymatous elements of the mammalian epiphysis. The large and centrally placed nucleus, the extensive and glandular cytoplasm, mark these cells so definitely that they may be recognized without any difficulty even in those instances when they become ectopic because of such migration as not infrequently results from tumor formation in the pineal body.

Recent work by the writer is illustrated in the figures which show the character of the pineal gland cells in kangaroo, sea lion, camel, goat, rabbit, orang and in man. The ontogenesis of the epiphysis in cat shows that in the early stages of differentiation the nuclei of the ependymal cells are so

246

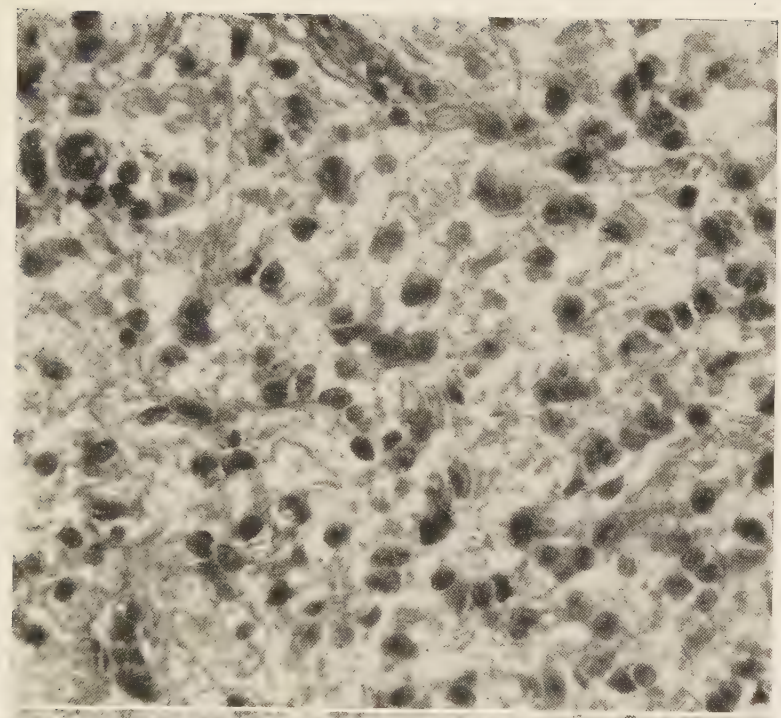

247

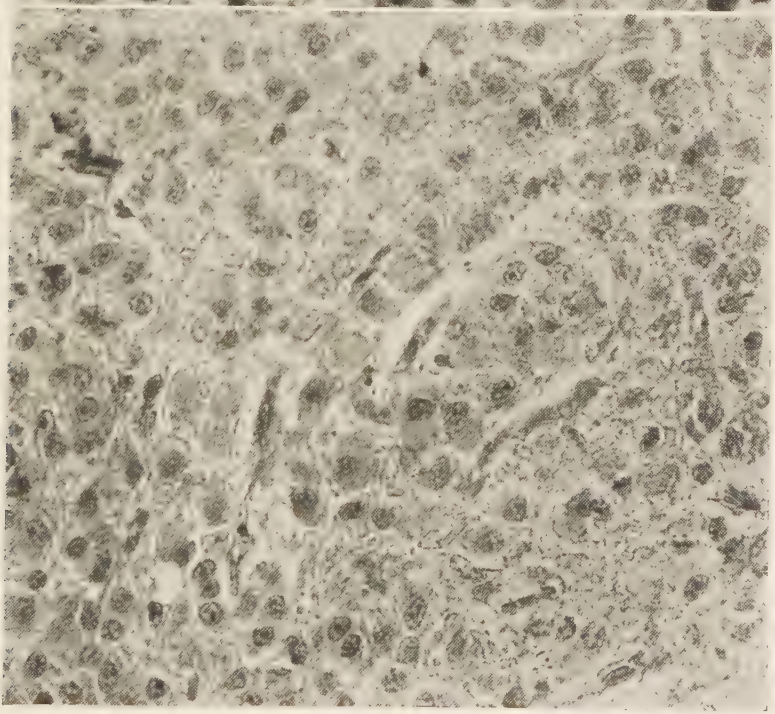

FIGS. 246 and 247.—Human Pineal (Fig. 246). Hematoxylin-eosin. × 500. Sheep Pineal (Fig. 247). Azur-eosin. × 500.

large and the cytoplasm so scanty that they give the impression of lymphoid tissue, but in the later stages the cytoplasm increases so considerably in amount that it is no longer possible to conceive of these cells as lymphoid in character. In fact, they have in the later periods of fetal and early postnatal life all the appearances usually associated with glandular cells. As compared to the cells in the glandular portion of the hypophysis, the size of the pineal cells is two or three times as great. This difference in size affords a striking point of differentiation in those pathological conditions in which the pineal cells in the course of tumor formation have migrated into and through the posterior lobe of the hypophysis and invaded the pituitary gland. The contrast is so marked as to present no difficulty in the identification of the two varieties of cells.

That the epiphysis is made up of neuroglia cells in large part, if not entirely, has been the contention of several observers. The presence of short, branching fibers in close proximity to the pineal cells has seemed to be the basis for this view. On the other hand, if the pineal cells in mammals are to be regarded as neuroglia, it must be granted that they are certainly unlike the neuroglia cells observed in other parts of the central nervous system. Dimitrova, who makes out such a strong case in favor of the neuroglial character of the epiphysis, seems to base her conclusions upon criteria which are not wholly convincing, for the mere presence of demonstrable fibers in the neighborhood of the cells does not of itself indicate that these cells are neuroglial in character. Furthermore, this view neglects to take into account the highly specialized character of the pineal cells. If, on the other hand, it be granted that the cell constituency of the epiphysis is, in major part, neurogliar, this admission would not wholly invalidate the idea that the structure is glandular in nature; for, according to recent researches of Nageotte and Mawas, neuroglia cells contain mitochondria and hence should be considered as glandular elements. In this light, the neuroglia throughout the entire nervous system is endowed with secretory function. In general, however, it does not seem necessary to invoke this interpretation of the neuroglia in order to place the pineal body in the class of glandular structures, for the character of the pineal cells is in itself sufficient argument in favor of a function different from that attributed to the neuroglia in the ordinary sense and most in favor of a glandular activity.

The observations of Nicolas, later confirmed by Dimitrova, in which muscle cells were reported as histological elements of the epiphysis in several *Ungulates*, have not been confirmed by other observers, and some authorities have been categorical in their affirmation concerning the absence of such elements. That the epiphysis may contain nerve cells and nerve fibers is probable, but there is no evidence in mammals of the existence of any neural mechanism in the pineal body.

IV. PHYSIOLOGICAL SIGNIFICANCE

Numerous attempts have been made to determine what function, if any, the pineal body possesses. Is it indispensable to life, or does it play some rôle important to a particular phase of metabolic activity? These questions have been tested by several different methods of investigation, among them feeding experiments, intravenous injections, experimental extirpation and glandular implantation.

1. *Feeding experiments:*

Dana and Berkeley (1913) were the first to carry out systematic feeding experiments. They employed kittens, young guinea pigs and rabbits as their test animals. A solution of nucleoprotein obtained from calves' pineal bodies was the substance administered. In consequence of this feeding, half-grown guinea pigs gained in a given time 11 per cent more than controls not fed with the solution. Young pineal-fed kittens also rapidly outgrew control animals in motor activity, size, intelligence and resistance to intercurrent disease. Young rabbits fed in this way also grew more rapidly than control animals. The gain was remarkable—one of the specimens trebling its weight during the time of the experiments.

These feeding experiments were repeated by McCord in 1915. In these tests chicks and guinea pigs were employed. The guinea pigs fed with pineal tissue of the calf gained 23 per cent in body growth over the control group. There was some increase in adipose tissue in this overgrowth, but in general the tissue development was distributed and not localized to one region of the body. In no instance did this excessive growth pass beyond the adult normal size. No tendency toward gigantism was observed. McCord was of the opinion that the administration to young animals of minute quantities of pineal tissue from young animals stimulates rapid growth of the body, but not beyond the normal size. There are also some indications of precocity in mental and sexual development, but these phenomena are less well established.

Feeding experiments with tadpoles were reported by McCord and Allen in 1917. On the tenth day of larval life, pineal-fed tapdoles showed a uniformly lighter coloration than the control animals which were muscle-fed. Thirty minutes after feeding pineal tissue, the tadpoles which prior to the feeding were uniformly dark became so translucent that all of the viscera were plainly visible through the body wall. These alterations in pigmentation are invariably induced in tadpoles upon the administration of pineal materials, whether they be fresh, minced glands, simple desiccation preparations, simple aqueous extracts or lipo-derivatives of the glands.

Pineal feeding has also been employed in human subjects, especially in under-developed or defective children. Dana and Berkeley (1913) appear to be the first to have attempted this experimental effort. They carried out their studies upon defective school children in New York City.

Goddard (1917) selected a group of twenty-five mentally deficient children of each sex and of different grades of intelligence from the lowest to the highest. Careful physical and psychological controls were made. Goddard concluded that all of these findings must be considered as negative, although shortly after the institution of the feeding there are measurable indications of mental stimulation in some instances. These do not persist with continued treatment. It is not believed that any of these feeding studies in children afford sufficient evidence concerning the value of pineal therapy.

Hutton (1924) calls attention to the fact that the pineal gland attains its largest size (0.2 gm.) in the early years of life, and in man undergoes regressive changes after puberty. He reports the results of considerable experience in pineal feeding of the dried gland to under-developed children. From his observations he concludes that the effects of such feeding are practically nil. There is little or no evidence to support the statement that the gland has anything to do in the interplay of judgment or emotion, nor have lesions in the pineal any relation to criminal tendencies either in the young or in the old.

2. *Injection experiments:*

Observations upon the results following intravenous or subcutaneous administration of pineal extracts are confined almost exclusively to the immediate effects. These effects differ from the intense reactions to suprarenal extracts or pituitary extracts in that pineal injections cause much less pronounced response.

Howell (1898) administered pineal extracts in control experiments on the action of pituitary extracts. The results were not sufficient to attach any significance to the reactions caused by the pineal.

Cyon, in 1903, made injections in rabbits and reported that such pineal injections were without definite effect upon blood pressure.

Dixon and Halliburton, in 1909, observed a transient fall of blood pressure in similar experiments. No changes were reported in the heart rate, amplitude, respiration or volume of the kidney.

In 1912, Scott and Ott adduced some evidence indicating that pineal extracts cause vasodilatation in the erectile tissue in the generative organs of the male cat. These injections also stimulate contraction of the intestinal wall and uterus with a slight diuresis and glycosuria. They also cause an increase in the activity of the mammary gland.

A precise study of the immediate effects of pineal extracts was reported by Jordan and Eyster in 1911. The material here employed was sheep's pineal gland, fresh or preserved in alcohol. Their experiments convinced them that intravenous injection causes a fall of blood pressure associated with vasodilatation in the intestines, and energizes systole in the cat's heart. It also results in transitory diuresis with glycosuria.

Dana and Berkeley in 1913 reported some studies on cardiovascular activity. It is their opinion that the effects of pineal injections upon blood pressure are virtually negative.

McCord, in 1915, injected pineal extract in the jugular veins of dogs anesthetized with chloretone. His results were quite contradictory. Some of the animals were quickly killed by a single injection, while in others a similar injection brought about no observable effect.

Horrax (1916) is in general agreement with earlier experimenters in the belief that the intravenous injection of pineal extracts, taken from young animals, causes a constant but relatively slight fall in blood pressure. These injections cause no increase in the flow of the cerebrospinal fluid.

In general, it seems fair to conclude that the immediate effects following intravenous injection of pineal gland extracts are usually not pronounced. These injections have little specificity in their action and the observations with reference to the cardiovascular system are not marked enough to assume that the pineal gland in any sense acts as a cardiovascular depressant.

3. *Experimental removal of the pineal body:*

Pinealectomy has been practised on amphibia, birds and mammals.

Amphibia. Adler (1914) and Hoskins (1919), successfully removed the pineal body from a number of frogs, but the effects of such removals were largely negative.

Atwell (1921), after removal of the pineal gland from the tadpole, observed no pigmentary disturbance. Removal of the gland, however, soon after removal of the pituitary in the frog tadpole, does not bring about the silvery reaction characteristic of the removal of the hypophysis alone.

Birds. Izawa (1912, 1923, 1925, 1926) succeeded in securing fifteen chicks which survived removal of the pineal. The cocks showed marked over-growth of the testicle and comb. There were no corresponding changes in the hens.

Christea (1912), on the other hand, found no alteration in body growth, and also observed that the growth of the testes and the secondary sex characters was distinctly retarded.

Foa (1912) extirpated the pineal gland in a number of chicks which caused a greater development in the testes and a greater growth in the crests than in the non-operated control animal. The difference begins to manifest

itself five months after the operation and increases constantly up to the ninth month. The operation produces no effect on the general development of the body of the fowl.

Urechia and Grigoriu (1922) found the hypophysis to be three times as large in pinealectomized birds as in normal controls. They also report a rapid growth in the body, which follows an apparent early retardation in somatic development.

Clemente (1923) after the removal of the pineal in birds, reports a definite over-growth in the body, testes and secondary sex organs in the male.

Izawa, again (1923), reports that pinealectomized young cocks grow more rapidly than controls. They begin to crow earlier and show a premature development of the combs and testes. Young pinealectomized hens manifest premature development of the ovary and Fallopian tubes. From these observations Izawa believes that the chief function of the pineal body is to repress the premature development of the sexual organs in the female as well as in the male. Taken as a whole, the responses in the fowl are more definite than in the mammal.

Mammals. Sarteschi conducted two separate series of pineal extirpations, the first in 1910 upon rabbits in which his results were essentially negative. In 1913 he repeated this work upon young rabbits and puppies and reported the production of the macrogenitosomia praecox syndrome. After removal of the pineal, the testes were as greatly hypertrophied as in Foa's cockerels. Sarteschi concluded that in rabbits pineal removal determines a more rapid development of the body with sexual precocity and notable enlargement of the testes. The same conclusions hold good in puppies, in one of which the testes were of adult size before the animal was five months old. On the basis of his studies Sarteschi accepted Pellizzi's hypothesis that the pineal body exercises a moderating action on the growth of the body and genital differentiation.

Foa (1914) pinealectomized rats and concluded that no appreciable effect was produced in the female. In the male, however, removal of the pineal provokes more rapid somatic growth than in the control, for a time. His experiments on rats show that extirpation of the pineal gland does not determine an absolute hypertrophy of the testicles, but rather a premature development of them.

Horrax (1916) reported the successful removal of the pineal body from guinea pigs and rats. The results in males, taken as a whole, show very little difference in the body weight of the experiment as compared with the control animals. In regard to the growth of the genital organs, a much more notable increase in favor of the experiment animals takes place. It is also to be noted that in the pinealectomized guinea pig there is a marked increase in the size of the seminal vesicles. In pinealectomized female guinea pigs

no differences could be detected in the size or weight of the genital organs. Of twenty females with total pineal extirpation, three became pregnant, while among the same number of controls there were but two. All three experimental guinea pigs were delivered of their young ten days or more before the controls. From this observation it would seem that the period necessary to attain maturity is greatly reduced as the result of pineal removal.

Dandy (1915), by means of a new and simple operative technique, successfully performed pineal extirpation upon a number of young dogs, mainly puppies from ten days to three weeks old. His experiments led him to the conclusion that pineal extirpation gives rise to no sexual precocity, indolence, adiposity, emaciation, somatic or mental prematurity or retardation. No evidence was found that the pineal has an active endocrine function, in either young or adult dogs. The organ is not essential to life and seems to have no influence upon the animal's well-being.

Hofmann (1925), as the result of pinealectomy in white rats, reported that the reactive change from one organ to another, especially such as concerns the inner secretion, was not observed in the animals operated upon.

V. CLINICO-PATHOLOGICAL EVIDENCE

A considerable variety of pathological changes may affect the pineal body. Some of these abnormal conditions have led to definite conceptions concerning the function of the pineal gland.

Zandren (1921) gave a detailed analysis of a symptom complex in a boy 16½ years old who had no pineal. He concluded from this case that the function of the pineal gland is without doubt that of an internal secretory nature. Its principal task is the initiation of puberty which probably is effected by an interaction between the epiphysis and the sexual glands. The granulation of the cells observed by the anatomists at the age of eight to nine years, may possibly be the basis of this secretion. The absence of complete involution, even at a mature age, argues that the gland has internal secretory functions even after puberty.

Hyperplastic states in the gland are of much more common occurrence. Cysts of various kinds, particularly retention cysts, lined with ependymal cells, have also been reported. A deposition of brain sand, "acervulus cerebri," in man is regarded as a sign of involution in the pineal. Tumors of many varieties are common in the epiphysis. These include gliomata, teratomata, carcinomata, mixed and compound tumors.

Pellizzi, in 1910, described a definite syndrome characterized by premature sexual development and marked premature growth of the body in young children. This syndrome he called macrogenitosomia praecox and attributed it to disease of the pineal.

Keene O. Haldman (1927), in a contribution on tumors of the pineal gland, reports 2 cases of pineal tumors which came under his observation and gives an excellent review of tumors involving this portion of the brain, previously reported. He summarizes 113 cases of pineal gland tumor and finds the syndrome of macrogenitosomia praecox observed in 16 cases, all in males between the ages of three and sixteen years.

VI. CONCLUSIONS

In considering the contributions made by pineal feeding, pineal injection, pineal removal, in conjunction with clinico-pathological observations, it must be admitted that knowledge concerning the epiphysis is still in an unsatisfactory state. We may perhaps concede that this organ does possess a function in man and in most mammals. It is not improbable that this function is particularly determined by an internal secretion, a secretion, however, which is certainly not indispensable to life. The exact influence of the pineal secretion is still obscure, although it seems to be a fair working hypothesis that the endocrinic activity of the gland plays some rôle in the development of puberty and, it may be, in the early growth of the body.

From the standpoint of comparative morphology, it seems permissible to draw more decisive conclusions. It is certain that the pineal region of the brain is preponderantly glandiferous in its derivatives. The morphogenetic impulse imparted by such a gland-forming area could not fail to have a profound influence upon one of its constituents, the epiphysis.

The pineal body cannot be a vestige from the evidence based upon its gross morphology for the following reasons:

The phyletic constancy of the epiphysis in the vertebrate phylum; its variations and morphological specializations; its relatively greater phyletic constancy with reference to other structures in the pineal region; the gross evidence of its progressive specialization in ophidians, birds and mammals; the resistance to the encroachment of a prominent neomorph in the mammalian brain, that is, the corpus callosum, which has produced such marked alterations in the other constituents of the diencephalic roof-plate.

The pineal gland cannot be considered a vestige in the light of the cytological evidence, since the tendency toward specialization is definitely in the interest of glandular formation in ophidians, chelonians, birds and mammals. Ontogenetically, in two forms at least (the cat and man) the development of the pineal body follows the general lines of glandular differentiation. The pineal body is, therefore, a glandular structure and, as such, is necessary in some way to metabolism.

The cytology of the organ gives clear evidence that the epiphyseal complex of vertebrates possesses a pluripotentiality whose fundamental inherent tendency is in the interest of glandular differentiation, but in a

few instances, as in cyclostomes, amphibia and primitive reptiles, the pineal organ may become further differentiated in the interest of a highly specialized sensory mechanism which has or has had visual function. As a gland, it may in some cases contribute its secretion to the cerebrospinal fluid, but in the higher vertebrates, as in ophidians, chelonians, most birds and mammals, it is an endocrinic organ, contributing the products of its secretion to the blood stream.

VII. BIBLIOGRAPHY

Adler, L. 1914. Extirpation der Epiphyse. *Arch. f. Entwcklngs. d. Organ.*, **40**, 18.

Anglade and Ducos. 1908. *Note preliminaire sur l'anatomie et la physiologie de la glande pinéale.* Soc. d'anat. et de physiol. de Bordeaux. Procès verbal official de la séance du 14 Decembre.

——— 1912*a*. Sur les pédoncules de la glande pinéale. *J. de Med. de Bordeaux*, **42**, 772.

——— 1912*b*. Les plaques et les formations lacunaires dans la glande pinéale. *Ibid.*, **42**, 772.

Atwell, W. J. 1921. Pigment changes following removal of the epithelial hypophysis and the pineal gland in the frog tadpole. *Endocrinology*, **5**, 221.

Béraneck, E. 1893*a*. Contribution à l'embrogénie de la glande pinéale des amphibiens. *Rev. Suisse de Zool.*, **1**, 255.

——— 1893*b*. L'individualité de l'oeil parietal. Réponse à M. de Klinchowstroem. *Anat. Anz.*, **8**, 669.

Biondi, C. 1912. Histologische Beobachtungen an der Zirbeldrüse. *Ztschr. f. d. ges. Neurol. u. Psychiat.*, **9**, 43.

Bizzozero, G. 1868. Sul parenchima della ghiandola pineale. *Riv. ist. Lomb. di Sc. et Leti.*, Scr. 2, 1.

——— 1871*a*. Beitrag zur Kenntnis des Baues der Zirbeldrüse. Vorläufige Mitt. *Zentralb. f. Med. Wissensch.*, No. 46, Jahrg. 9.

——— 1871*b*. Sulla struttura del parenchima della ghiandola pineale umana. *Riv. ist. Lomb. di Sc. et Lett.*, S. 2, 4.

——— 1862–79. *Opera Scient.* Milano, 1905, **1**, 175.

Cajal, S. Ramon y 1895. Apuntas para el estudio del bulbo raquideo cerebelo y origin de los nervios encefalicos. *Anales de la Sociedad Esponola de Historia Natural.*

——— 1904. *Texture del sistema nerviosa del hombre y de los vertebrados*, Madrid. 2.

Charpy, A. 1894. *Traité d'anatomie humaine*, Paris. 3.

Chauveau, A. 1885. *Comparative anatomy of the domesticated animals.* Turin.

Christea. 1912. Cited by Izawa.

Cionini, A. 1885. Sulla struttura della ghiandola pineale. *Riv. sper. di freniatria a di med. legale* (11) Reggio Emilia (1).

——— 1886. Sulla struttura della ghiandola pineale. *Ibid.*, **12**, 4.

——— 1888. La ghiandola pineale e il terzo occhio dei vertebrati. *Riv. sper. di freniatria* **14**, 65; *Neurol. Centralb.*, **20**, 621.

Clarke, J. L. 1860. Structure of the pineal gland. *Proc. Roy. Soc.*, **11**.

Clemente, G. 1923. Contributo allo studio della ghiandola pineale nell' uomo e in alcuni animali. *Endocrinol. e patol. Cosit.*, **2**, 44.

——— 1923–24. Contributo allo studio della ghiandola pineale nell' uomo e in alcuni mammiferi. *Gio. di biol. e med sper.*, **1**, 76.

Constantini, G. 1910. Intorno ad alcune particolarita di struttura della ghiandola pineale. *Patbologica*, **2**, 439.

Cruveilhier, J. 1829. *Anatomie pathologique, etc.* Paris.
——— 1877. *Traité d'anatomie descriptive, etc.* Paris. 3.
Cutore, G. 1909. Di una particolare formazione prepineale nel Bos taurus. L. *Arch. ital. di anat. e di embriol.*, 8, 230.
——— 1910. Il corpo pineale di alcuni mammiferi. *Ibid.*, 9, 402.
——— 1912. Alcune notizie sul corpo pineale del macacus sinicus L. e del cercopithicus griseus viridis L. *Fol. neuro-biol.*, 4, 267.
Cyon, E. v. 1903. Zur Physiologie der Zirbeldrüse. *Arch. f. d. ges. Physiol.*, 98, 327.
Dana, C. L., and Berkeley, W. N. 1913. The function of the pineal gland with reports of feeding experiments by H. H. Goddard and Walter S. Cornell. *Med. Rec.*, 83, 835.
Dandy, W. E. 1915. Extirpation of the pineal body. *J. Exper. Med.*, 22, 237.
Darkschewitsch, L. v. 1886*a*. Anatomie der Glandula pinealis. *Neurol. Zentralb.*, 5, 29.
——— 1886*b*. Einige Bemerkungen über den Faserverlauf in der hinteren Commissure des Gehirns. *Ibid.*, 5, 99.
Dejerine, J. J. 1895. *Anatomie des centres nerveux.* Paris.
Descartes, R. 1649. *Les passions de l'âme.* Art. 31 and 32. Amsterdam.
Dimitrova, Z. 1901. *Recherche sur la structure de la glande pinéale chez quelques mammifères.* No. 2 (Louvain).
Dixon, W. E., and Halliburton, W. D. 1909. The pineal body. *Quart. J. Exper. Physiol.*, 2, 283.
Edinger, L. 1892. *Untersuchungen in der vergleichenden Anatomie des Gehirns.* II. *Das Zwischenhirn der Selachier und der Amphibien.* Abh. der Senckenberg. Naturf. Ges in Frankfurt a/M.
——— 1897. *Lexioni sulla struttura degli organi nervosi centrali dell' uomo e degli animali.* Trad. Ital. Milano.
——— 1900. *Vorlesungen über den Bau der nervosen centralorgane.* Ed. 6. Leipz.
——— 1909. *Bau und Verrichtungen des Nervensystems.* Leipz.
Ellenberger, W. 1888. *Vergleichende Histologie der Haussäugethiere.* Berl.
Eycleshymer, A. C. 1892. Paraphysis and epiphysis in Amblystoma. *Anat. Anz.*, 7, 215.
Eycleshymer, A. C., and Davis, B. M. 1897. The early development of the epiphysis and paraphysis in Amia. *J. Comp. Neurol.*, 7, 45.
Faivre, E. 1855. Observations sur le conarium. *Comp. rend. Soc. di Biol.*, 2nd ser. 1, Pt. 2, 105.
——— 1857. Étude sur le conarium et les plexus choroïdes chez l'homme et les animaux. *Ann. des Sc. Natur.*, Ser. 4, 7.
Favaro, G. 1903. Intorno al sacco dorsale del pulvinar pineale nell' encefalo dei mammiferi. *Monitore Zool. ital.*, 14, 275.
——— 1904*a*. Di un organe speciale della volta diencefalica in Bos taurus L. *Ibid.*, 15, 111.
——— 1904*b*. Le fibre nervose prepineale e pineale nell' encefalo dei mammiferi. *Arch. ital. di Anat. e di Embriol.*, 3, 750.
Flesch, M. 1887*a*. Über das Scheitelauge der Wirbeltiere. *Mitt. der Naturf. Ges. in Bern.* No. 1169–1194.
——— 1887*b*. Struktur des zentralen Nervensystems des Sympathikus. In Ellenberger, *Vergleichende Histologie der Haussäugetiere.* Berl. P. 749.
——— 1888. Über die Deutung der Zirbel bei den Säugetieren. *Anat. Anz.*, 3, 172.
Foa, C. 1912–13. Hypertrophie des testicules et de la crête apres l'extirpation de la glande pinéale chez le coq. *Arch. ital. de biol.*, 57, 233.
——— 1914. Nouvelle recherches sur la fonction de la glande pinéale. *Arch. ital. de biol.*, 61, 79.
Frey, H. 1867. *Handbuch der Histologie und Histochemie des Menschen.* Leipz.

Galasescu, P., and Urechia, C. J. 1910. Les cellules acidophiles de la glande pinéale. *Compt. rend. de la Soc. de biol.*, 68, 623.

Galeotti, G. 1897. Studio morfologico e citalogico della volta del diencefola in alcuni vertebrati. *Riv. di patol. nervosa e mentale*, 2, 481.

Gaskell, W. H. 1908. *The origin of vertebrates*. Lond.

Goddard, H. H. 1917. The Vineland experience with pineal extracts. *J. Am. M. Ass.*, 68, 1340.

Goette, A. 1873. Kurze Mitteilungen aus der Entwicklungsgeschichte der Unke. *Arch. f. mikr. Anat.*, 9, 391.

Graaf, H. W. de. 1886. Zur Anatomie und Entwicklung der Epiphysis bei Amphibien und Reptilien. *Zool. Anz.*, Jahrg., 9, 191.

Gravenhearst. 1829. *Reptilia musei Zoologici Vratislaviensis*. Fasc. 1, Leipz. (Tab. 7).

Hagemann, G. 1872. Über den Bau des Conarium (Dissert. Göttingen). *Arch. f. Anat. u. Phys.*, 429.

Haldeman, K. O. 1927. (To be published in *Arch. Neurol. and Psychiat.*)

Haller, A. 1768. *De cerebro avium et piscium. Operum anatomici argumenti minorum.* 3. Lausanne.

Henle, J. 1871. Nervenlehre. In *Handbuch der Anatomie*. Braunschweig, 3, Abt. 2, 288.

——— 1879. *Handbuch der Nervenlehre*. Braunschweig.

——— 1887. *Handbuch der Systematischen Anatomie des Menschen. Nervenlehre*. Braunschweig.

Hill, C. 1891. Development of the epiphysis in Coregonus albus. *J. Morphol.*, 3, 503.

His, W. 1892. Zur allgemeinen Morphologie des Gehirns. *Arch. f. Anat. u. Entwcklngsgesch.*, Anat. Abt., 346.

——— 1893. Vorschläge zur Einteilung des Gehirns. *Ibid.*, 157.

Hoffmann, C. K. 1884. Zur Ontogenie der Knockenfische. *Arch. f. mikr. Anat.*, 23, 45.

——— 1886. Weitere Untersuchungen zur Entwicklungen der Reptilien. *Morph. Jahrb.*, 11, 192.

——— 1890. Epiphyse und Parietalauge. In Bronn's *Klassen und Ordnungen des Tierreiches*, 6, Abt. 3, 1981.

Hofmann, E. 1925. Zur Frage der inneren Sekretion der Zirbeldrüse bei der Ratte. *Arch. f. d. ges. Physiol.*, 209, 685.

Hollard, H. 1837. *Précis d'anat. comparée en tableau de l'organisation consistires dans l'ensemble de la série animale*. Paris. P. 586.

Horrax, G. 1916. Studies on the pineal gland. I. Experimental Observations. II. Clinical Observations. *Arch. Int. Med.*, 17, 607.

Horrax, G., and Bailey, P. 1925. Tumors of the pineal body. *Arch. Neur. and Psychiat.*, 13, 423.

Hoskins, E. R., and Hoskins, M. M. 1919. Growth and development of amphibia as affected by thyroidectomy. *J. Exper. Zool.*, 29, 1.

——— 1920. The inter-relation of the thyroid and hypophysis in the growth and development of frog larvae. *Endocrinology*, 4, 1.

Howell, W. H. 1898. The physiological effects of extracts of the hypophysis cerebri and infundibular body. *J. Exper. Med.*, 3, 245.

Hutton, J. H. 1924. The pineal gland and its function. *Med. J. and Rec.*, 120, 476.

Izawa, Y. 1923. Contribution to the physiology of the pineal body. *Am. J. Med. Soc.*, 166, 185.

——— 1925. Studies on the pineal body. I. On the postnatal growth of the pineal body of the albino rat with observations on its histology. *J. Comp. Neur.*, 39, 1.

——— 1926. Anatomical changes which follow removal of the pineal body from both sexes of the immature albino rat. *Am. J. Physiol.*, 77, 126.

Jordan, H. E. 1911. The microscopic anatomy of the epiphysis of the opossum. *Anat. Record,* **5,** 325.

——— 1911–12. Histogenesis of pineal body of sheep. *Am. J. Anat.,* **12,** 249.

——— 1912. Results of recent studies of the mammalian epiphysis cerebri. *Trans. Am. Micr. Soc.,* **31,** 231.

Jordan, H. E., and Eyster, J. A. E. 1911 12. The physiological action of extracts of the pineal body. *Am. J. Physiol.,* **29,** 115.

Kidd, L. J. 1913. The pineal body; a review. *Rev. Neurol. and Psychiat.,* **2,** 1.

v. Kölliker, A. 1850. *Mikroskopische Anatomie des Menschen.* Bd. 2. Leipz.

——— 1879. *Entwicklungsgeschichte des Menschen und der höheren Tiere.* Zweite Auflage, Leipz.

——— 1887. Über das Zirbel oder Scheitelauge. Sitzungsber. der Wurzburger Phys.-Med. Ges. *Muenchener med. Wochenschr.,* **34,** 210.

——— 1896. *Handbuch der Gewebelehre des Menschen.* Leipz.

Krabbe, K. H. 1911. Sur la glande pinéale chez l'homme. *Nouvelle Iconograph de la Salpêtrière,* **24,** 257.

——— 1915. *Histologic studies of the pineal gland.* (Histologchi Andersogelsis over corpus pineale.) *Biblio f. Laeges. Kibin,* **107,** 175.

——— 1923. The pineal gland especially in relation to the problem of its supposed significance in sexual development. *Endocrinology,* **7,** 379.

Krause, W. 1868. *Die Anatomie des Kaninchens.* Leipz. (Also 1884.)

——— 1876. *Allegemeine und mikroskopische Anatomie.* Hanover.

Leydig, F. 1853. *Anatomisch-histologische Untersuchungen über Fische und Reptilien.* Berl.

——— 1868*a*. *Traité d'histologie comp. de l'homme et des animaux.* P. 199.

——— 1868*b*. Über Organe eines sechsten Sinnes, zugleich als Beitrag zur Kenntniss des feineren Baues der Hautt bei Amphibien und Reptilien. *Nov. act. Acad. nat. curios.,* **34.**

——— 1872. *Die in Deutschland lebenden Arten in Saurier.* Tübingen.

——— 1887. Das Parietalorgan der Wirbeltiere. *Zool. Anz.,* Jahrg. 10, 534.

——— 1889. Das Parietalorgan der Reptilien und Amphibien kein Sinneswerkzeug. *Biolog. Zentralb.,* **8,** 706.

——— 1890. Das Parietalorgan. Zweite vorlaufige Mitteilung. *Ibid.,* **10,** 278.

——— 1891. Das Parietalorgan der Amphibien und Reptilien. *Abh. der Senckenbg. Ges.,* Frankfurt a/M., **16.**

——— 1896. Zur Kenntnis der Zirbel und Parietalorgane. *Ibid.,* **19.**

——— 1897. Zirbel und Jacobsonsche Organe einiger Reptilien. *Arch. f. mikr. Anat.,* **50.**

Lord, J. R. 1899. The pineal gland; its normal structure, some general remarks on its pathology, etc. *Trans. Path. Soc. Lond.,* **50,** 18.

Luys, J. B. 1865. *Recherches sur le système nerveux cérébrospinale.* Paris.

McCord, C. P. 1915*a*. The pineal gland in relation to somatic, sexual and mental development. *J.A.M.A.,* **63,** 232; **65,** 517.

——— 1915*b*. The pineal gland. *Interstate M. J.,* **22,** 354.

——— 1917. The pineal gland—the influence of the pineal gland upon growth and differentiation with particular reference to its influence upon prenatal development. *Surg., Gyn. and Obst.,* **25,** 250.

McCord, C. P., and Allen, F. P. 1917. Evidences associating pineal gland function with alterations in pigmentation. *J. Exper. Zool.,* **23,** 207.

Malacarne. 1873. Cited by Legros, Thèse de Paris.

Marburg, O. 1908. Adipositas cerebralis. *Wien. Med. Wchnschr.,* **58,** 2617.

Marburg, O. 1908–09. Zur Kenntnis der normalen und pathologischen Histologie der Zirbeldrüse die Adipositas cerebralis. *Arb. a. d. Neur. Inst., a. d. Wien Univ.*, **17**, 217.
——— 1912. Die Klinik der Zirbeldrüsen Krankungen. *Ergeb. med. u. Kinderh.*, **10**, 146.
Mawas, J. 1910. Note sur la structure et la signification glandulaire probable des cellules neuroglique du systéme nerveux central des vertébrés. *Compt. rend. de la Soc. de Biol.*, **69**, 45.
Meynert, T. 1877. Von Gehirn der Säugetiere. In Strickers *Handb. der Lehre von Geweben.*, Leipz., **2**, 743.
Mihalkovicz, V. 1874. Entwickelung der Zirbeldrüse. *Zentralb. f. med. Wissensch.*, No. 16, 241.
——— 1877. *Entwicklungsgeschichte des Gehirns.* Leipz. P. 94.
Mingazzini, G. 1889. *Organi nervosi.* Rome.
v. Möller, J. 1890*a*. Einiges über die Zirbeldrüse des Chimpanse. *Verhandl. d. naturf. Ges. in Basel*, **8**, 755.
——— 1890*b*. On the anatomy of the chimpanzee brain. *Arch. f. Anthropologie*, **17**.
Nageotte, J. 1910. Phénomènes de sécrétion dans le protoplasma des cellules nevroglique de la substance grise. *Compt. rend. de la Soc. de Biol.*, **68**, 1068.
Nicolas, A. 1891. *Sur le troisième oeil der vertébrés.*
——— 1900. Note sur la presence des fibres musculaires striés dans la glande pinéale de quelques mammifères. *Compt. rend. de la soc. biol.*, **52**, 876.
Orr. 1899. Note on the development of amphibians, chiefly concerning the central nervous system. *Quart. J. Micr. Sc.*, **29**.
Pawlowsky. 1874. Über den Faserverlauf in den hinteren Gehirncommisur. *Ztschr. f. wiss. Zool.*, **24**, 284.
Pellizzi, G. B. 1910. La sindrome epifisaria "macrogenigosomia precoce." *Riv. ital. di neuropat. psichiat. e ellettroterap. Cantania*, **3**, 193, 207, 250, 272.
Reichert, K. B. 1859–1861. *Der Bau des menschlichen Gehirns.* 2 Abt. Leipz.
Reissner. 1851. *De auris internae formatione.* Dorpat.
Retzius, A. 1822. Bidrag til Ader og Nerfsystemets anatomie hos Myxine glutinosa. *Kongl. Veten. akad.*, Handlingar, Stockholm, 233.
Retzius, G. 1895. Über den Bau des sogen. Parietalauges von Ammocoetes. *Biolog. Untersuchungen*, N.F., 7.
Sarteschi, U. 1910–11. Richerche istologiche sulla glandula pineale. *Fol. neurobiolog.*, **4**, 675.
——— 1912–13. Sindrome epifisaria "macrogenitosomia precoce" attenuta sperimentalimente nei mammiferi. *Pathologia*, **5**, 707.
Schwalbe, G. 1881. Lehrbuch der Neurologie. In Hoffmann's Handbuch der *Anatomie des Menschen.* 2 Aufl.: Erlangen, 2 (2).
Scott, J. C., and Ott, I. 1912. The action of corpus luteum and of the pineal body. *Monthly. Cycl. and M. Bull.*, **5**, 207.
Seigneur, P. 1912. *Étude critique sur la glande pinéale normale et pathologique.* Thèse de Paris, No. 375.
Soemmering, S. T. 1785*a*. *Ce capillis vel prope, vel untra glandulam pinealem sitis magonza.*
——— 1785*b*. *Script. neurol. min. selecti* [etc.]. Lips. **3**.
——— 1798. *De corpor. humani Fabrica.* Mainz. 4.
Soury, J. 1899. *Système nerveux centrale.* Paris.
Stieda, L. 1865. Über den Bau der Haut des Frosches (Rana temporaria). *Arch. f. Anat. Phys. u. Wiss. Med.*, 52.
——— 1868. Studien über das zentrale Nervensystem der Vögel und Säugethiere. *Ztschr. f. wiss. Zool.*, **19**.

Stieda, L. 1870. Studien über das zentrale Nervensystem der Wirbeltiere (Frosch, Kaninchen, Hund). *Ibid.*, **20.**

——— 1873. Über die Deutung der einzelnen Teile des Fischgehirns. *Ibid.*, **23.**

——— 1875*a*. Über den Bau des zentralen Nervensystems der Amphibien und Reptilien.

——— 1875*b*. Über den Bau des zentralen Nervensystems der Axolotl.

——— 1875*c*. Über den Bau des zentralen Nervensystems der Schildkröte. *Ztschr. f. wiss. Zool.*, **25.**

Studnicka, F. K. 1893. Sur les organes pariétaux de Petromyzon planeri. *Sitzungsb. d.k.-böhm. Gesellsch. d. Wissensch. in Prag.*, **1**, 1.

——— 1895. Zur Anatomie die sogenannten Paraphyse des Wirbeltiergehirns. *Ibid.*,

——— 1895–96. Beiträge zur Anatomie und Entwicklungsgeschichte des Vorderhirns der Kranioten. *Ibid.*, Abt. 1, 1895; Abt. 2, 1896.

——— 1898. Zur Kritik einiger Angaben über die Existenz eines Parietalauges bei Myxine glutinosa. *Ibid.*,

——— 1899. Über den feineren Bau der Parietalorgane von Petromyzon marinus. *Ibid.*,

——— 1900*a*. Zur Kenntnis der Parietalorgane und der sog. Paraphyse der niederen Wirbeltiere. *Verbandl. der anat. Gesellsch. a. d. xvii Versammlung in Pavia*, **14**, 101.

——— 1900*b*. Untersuchungen über den Bau des Ependyms der nervösen centralorgane. *Anatom. Hefte*, **15**, 301.

——— 1905. Die Parietalorgan (Monograph). In Oppel's *Lehrb. d. vergl. mikr. Anat. d. Wirbelt.*, Bd. **5**, Jena.

Testut, J. L. 1900. *Traité d'anatomie humaine*. Ed. 4: Paris. **2.**

Urechia, C. I., and Grigoriu, C. 1922. L'extirpation de la glande pinéale et son influence sur l'hypophyse. *Compt. Rend. de Soc. de Biol.*, **87**, 815.

Valentin, G. 1843. *Traité de neurologie*. Trans. by A. J. L. Jourdan. Paris.

Voltaire, F. M. A. 1828. Cited by Majendie in *Memoir Physiologique Expérimentale et Pathologique.*, **7**, 211.

Weigert, C. 1875. Teratom der Zirbeldrüse. *Virchow's Arch.*, **65**, 212.

——— 1895. Beiträge zur Kenntniss der normalen menschlichen Neuroglia. *Abhandl. d. Senckenbg. Naturf. ges.* Frankfurt a/M., **19.**

Wenzel, J. A. 1812. *De penitiori structura cerebri hominis atque brutorum*. Tuebingae.

Willis, T. 1664. *Cerebri anatome*. Lond. Cap. **14**, 46.

Zandren, S. 1920–1921. A contribution to the study of the function of the glandula pinealis. *Acta Med. Scandinav.*, **54**, 323.

Section XVII

THE THYROID, PARATHYROIDS AND THYMUS

CONTENTS

SECTION XVII

PAGE

I. THYROID 551
1. Comparative anatomy 551
2. Embryology 552
3. Developmental defects 554
4. Normal anatomy 555
5. Blood vessels 556
6. Nerves 557
7. Microscopic 557
8. Interfollicular epithelium 558
9. Mode of secretion and excretion 559
10. Physiology 560
11. Effects of removal 560
12. Regeneration 563
13. Transplantation 563
14. Interrelations 564
15. Pathology 566
16. Simple goiter 568
17. Exophthalmic goiter 569
18. Myxedema 569
Bibliography thyroid 570

II. PARATHYROID GLANDS 575
1. Embryology 575
2. Comparative anatomy 576
3. General morphology 577
4. Blood supply 578
5. Innervation 578
6. Classification into types 578
7. Secretory epithelium 579
8. Physiology 581
9. Blood chemistry of tetany 582
10. Regeneration and hypertrophy 583
11. Transplantation 584
12. Interrelations 585
Bibliography (parathyroids) 585

III. THYMUS 588
1. Embryology 588
2. General morphology 591
3. Blood supply 592
4. Lymphatics 593
5. Innervation 593
6. Small thymic cells 593
7. Reticular cells 594
8. Hassall's corpuscles 594
9. Myoid cells 595
10. Cystic and duct-like spaces 595
11. Eosinophile cells 596
12. Stroma 597
13. Age involution 597
14. Physiology 598
15. Interrelations 600
16. Pathology 601
Bibliography (thymus) 603

Section XVII

THE THYROID, PARATHYROIDS AND THYMUS*

DAVID MARINE

I. THYROID

MÜLLER (1856) first made known to the scientific world the fact that during metamorphosis the endostyle organ of *Ammocoetes* disappears and at its site a few typical thyroid follicles develop. Owing to the survival, therefore, of one class of vertebrates—the *Cyclostomata*—it has been possible to trace the thyroid of all higher vertebrates as a direct descendant of the endostyle organ. This organ exists as an elaborate, ventral, midline pharyngeal groove in *Tunicata, Amphioxus* and *Ammocoetes*.

During the metamorphosis of *Ammocoetes* (which lasts about one month and occurs at the end of their third year of life) the endostyle organ undergoes atrophy with complete disappearance of three of its four specialized types of epithelium including the duct, and out of the fourth type are developed a few non-encapsulated, rounded, colloid-containing thyroid follicles (Marine, 1913*a*). Occasionally the epithelial cells retain their cilia after metamorphosis. The type of thyroid follicle present in adult *Cyclostomata* (*Petromyzon*) persists throughout all the higher vertebrates in essentially the same anatomical form. In none of the Cordates above the *Cyclostomata* is there an endostyle organ. Dohrn (1887) and others have shown that a transient and rudimentary formation of pharyngeal grooves can be made out in the very early development of certain rays and sharks but even this remnant of the endostyle cannot be traced to the higher vertebrates.

1. *Comparative anatomy:*

In the fishes two main types of thyroid may be recognized: (1) the Teleostean type consists of widely scattered follicles about the ventral aorta between the first and third gill arches. (2) The Elasmobranchian type consists of closely grouped thyroid follicles surrounded by a capsule. The lining epithelium of the follicles in bony fish is normally cuboidal in type, while in the Elasmobranchii it is high cuboidal and often columnar. Cowdry (1921) observed in the dog fish that each follicular cell was supplied with a single large long flagellum which projected into the colloid. He was unable to demonstrate flagella in other Elasmobranchii. These flagellated cells must be sharply distinguished from true cilia which the writer has seen occasionally in the thyroid follicles of adult lampreys.

In frogs and amphibians generally the thyroid is paired. Each lobe is separate and surrounded by a fibrous capsule.

In reptiles generally the adult thyroid is unpaired and lies in the thoracic cavity just above the pericardium.

*Figures in this section will be found on plates following bibliography.

In birds the thyroid lobes are separate oval bodies placed in the thorax on each side of the vertebral column in close relation to the branchiocephalic arteries, a short distance above their origin. They are usually partially embedded in lobules of the thymus and the parathyroids III and IV usually lie just below the lower poles.

In mammals the thyroid consists of two lobes which lie on either side of the trachea, about the level of its juncture with the larynx. There is great variation in its position, both in different species and within the same species. In some species, as the rabbit, guinea pig, ox, monkey and man, the two lobes are regularly connected across the midline, anterior to the trachea, by an isthmus, and in other mammals, like the dog and cat, the isthmial portion is usually absorbed. But under conditions which bring about increased activity in early embryonic life, as in endemic goiter districts, the isthmial portion frequently remains.

2. *Embryology (Fig. 248):*

The thyroid in fishes, amphibians and reptiles arises from a single median ventral invagination of the pharyngeal entoderm in the region just anterior to the first branchial cleft. In birds also Remak (1855) stated the gland was derived from an unpaired median ventral invagination of the pharyngeal epithelium in the region of the first branchial cleft. He observed that as development proceeded the anlage divided into a T-shaped mass and shifted backward with the aortic arches to its final intrathoracic position. The thyreoglossal tract and isthmus were absorbed. This view of the embryology of the thyroid in birds was accepted until Stieda (1881) stated that the gland had a lateral origin as well as a median. Mall (188-) came to the conclusion of Remak, that the chick thyroid is derived wholly from the median anlage. The derivatives of the fourth branchial cleft Mall designated as "Körpern Y" and concluded that they took no part in the development of the thyroid. Subsequent work has established the original views of Remak, W. Müller (187-) and Mall, that the avian thyroid is derived solely from the single median ventral pharyngeal anlage in the neighborhood of the first branchial cleft.

In mammals only is there at present any doubt as to the single and median origin of the thyroid. The evidence brought forward during the last twenty years has apparently cleared up the controversy and established the uniformity of the origin of this gland throughout all vertebrates. The controversy arose from Stieda's (1881) observation on sheep embryos, who gave the first important description of the paired bodies from the fourth branchial cleft and called them "lateral thyroid anlagen." He believed the whole thyroid was derived from these two lateral bodies. Born (1883), working with pig embryos, confirmed Stieda's discovery of the lateral thyroid anlage, but showed that the median anlage also formed thyroid tissue

and fused with the lateral thyroid anlagen, thus deriving the thyroid from three separate sources. His (1885), working with human embryos, also found these lateral thyroid anlagen arising from the fourth pouch and concluded that the median anlage formed the isthmus and pyramidal processes, while the lateral anlagen formed the lateral lobes. This view, while it prevailed for the next twenty years, was questioned by Kastschenko (1887). Working with the sheep embryo, he concluded that these lateral "thyroid anlagen" played no important rôle in the development of the thyroid. Van Bemmelen (1889) homologized the "Körpern Y" (Mall) of chicks, the postbranchial bodies (Maurer, 1888) of amphibians and the lateral thyroid

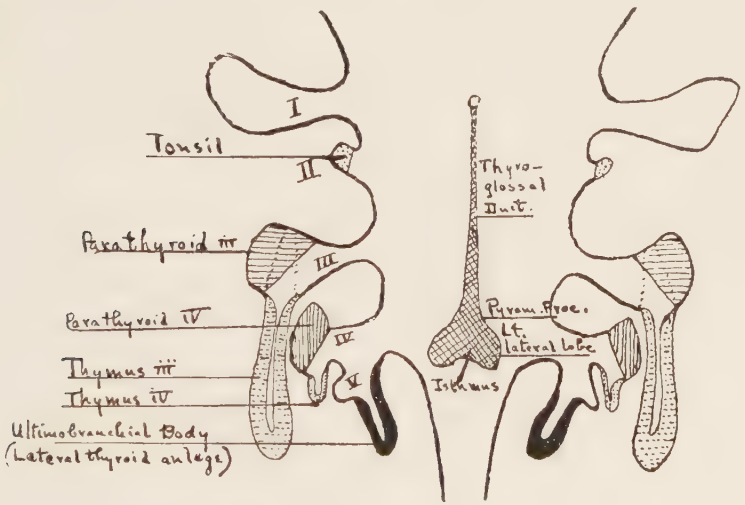

FIG. 248.—Schema of the branchiogenic derivatives in man. (After Grosser, O., in Keibel and Mall, Human Embryology, 1912, 2, 461.)

anlagen (Stieda, Born) of mammals with the suprapericardial bodies of Elasmobranchs. The later work of Maurer (1899), of Herrmann and Verdun (1900) has further established that the lateral thyroid anlagen or postbranchial bodies play no part in the development of the thyroid, that in the lower mammals (monotremes and marsupials) they tend to remain separate from the thyroid, although in placental mammals they are as a rule imbedded in the posterior lateral portion of the thyroid lobes. Grosser (1910) has confirmed this fate of the lateral thyroid anlagen. He recommends an abandonment of the term "lateral thyroid anlagen" as a misnomer and substitutes the term "ultimo-branchial body" instead of postbranchial body, because it is believed that in the human embryo these bodies are derived from the rudimentary fifth branchial cleft rather than from the fourth.

The ventral median invagination of the pharyngeal entoderm is located in front of the tracheal invagination. The anlage is at first a hollow tube and the upper part may persist as the canal of His. The caudal portion soon becomes solid and grows down or is dragged down with the trachea and like the trachea divides into right and left lobes. The site of the pharyngeal invagination is marked in later life by the foramen caecum. Normally the thyreoglossal tract between the foramen caecum and the thyroid isthmus undergoes absorption beginning at the fifth week in human embryos according to His, leaving only the lateral lobes connected across the trachea anteriorly in the region of the third and fourth tracheal rings by a flattened band of thyroid about 2 cm. in width and about 6 to 8 mm. in thickness. The human thyroid in particular exhibits great variations from this theoretically normal type, which in one way or another center about the development, down-growth and fate of the thyreoglossal tract, and offer the strongest supporting evidence for the single, median origin of the entire gland. The further development of the thyroid anlage is usually stated to be as anastomosing solid cords which are cut up by the ingrowth of vessels and stroma to form the follicles. Norris (1916) has shown that this is wrong. The so-called cords of the prefollicular stage represent sections of epithelial bands two cells in thickness and forming irregular fenestrated plates. The primary follicles arise directly from these epithelial plates by the rearrangement of the cells, cell proliferation, increases in the size of the cells, and lumen formation which he found to occur in a 24 mm. embryo. The further growth of the thyroid requires the formation of new follicles from the primary follicles. These are usually formed from solid epithelial bands or hollow buds whose cavities are at first continuous with the original follicle lumen.

3. *Developmental defects:*

The most common abnormality in the human thyroid is the presence of a pyramidal process. As Streckeisen (1886) has shown, it is most frequently seen in districts of endemic goiter (90 per cent at Basle) and least common on the seacoast. The presence of a distinct pyramidal process and a persistent thyreoglossal tract indicates an increased functional need for thyroid tissue at the period of embryonic life when this tract should undergo absorption. The pyramidal process or lobe usually replaces the isthmial band of which it is the unabsorbed portion. There may be two pyramidal processes due to the thyreoglossal tract dividing high up. In that event there is a pyramidal process extending obliquely downward and outward from each lateral lobe and the isthmus is absent. The pyramidal process may be connected directly with either the right or left lobes, more frequently with the left. Occasionally there is complete absorption of the isthmus in man, as normally occurs in many of the lower animals, leaving the two lobes isolated. Rarely one finds in man that one of the lobes (more frequently the right) is rudimentary or absent. This is due to the failure of the thyroid anlage to divide. A similar anomaly is seen in the development of the lung. Occasionally the descent of the thyroid anlage is arrested above the hyoid bone. In such instances there is usually a large thyroid mass beneath the foramen caecum and no thyroid tissue below the hyoid bone. There may also be thyroid

tissue around the foramen caecum and in interrupted masses or in a continuous column from the foramen through the hyoid bone and terminating in the pyramidal process coexistent with well-formed lateral thyroid lobes. This condition again is more frequently seen in association with endemic goiter. These more or less isolated masses of thyroid tissue along the line of descent of the thyreoglossal tract have been variously designated as "lingual," "sublingual," "suprahyoid" and "infrahyoid" thyroids (Marshall, 1895). Complete absence of the thyroid anlage occurs. Maresch (1898), Erdheim (1904) and others have studied such cases. They have shown that the parathyroids are usually normal and that in connection with the fourth parathyroids a cystic entodermal rest corresponding to the postbranchial or ultimo-branchial body or lateral thyroid anlage may usually be found. Getzowa (1907, 1911), working with the atrophic goiterous thyroids of the cretins and idiots, has observed these cell rests and cysts of the postbranchial body. She noted that these rests did not react with the thyroid and concluded that they took no part in the formation of thyroid tissue. Thyreoglossal cysts may develop from the unabsorbed thyreoglossal duct. These may be lined either with squamous epithelium or with ciliated epithelium. In many of the cases with persistent thyreoglossal tracts the hyoid bone contains a foramen through which the tract passes. This is due to the hyoid developing much later in embryonic life than the thyroid, and when the tract persists the hyoid is developed around it. Accessory or aberrant thyroid tissue apart from that described in relation to the thyreoglossal tract occurs with great frequency in man and almost constantly in dogs. It is most frequently seen in the region of the ascending and transverse portions of the aortic arch. More rarely thyroid fragments are present in the thymus, at the bifurcation of the trachea, or as far down as the esophageal opening in the diaphragm.

4. *Normal anatomy:*

Thomas Wharton (1659) first accurately described the thyroid and gave it its present name. It is difficult to define the normal elements of the thyroid because of the extreme lability of this tissue. Variations in size and structure not only may occur from day to day, but there are variations dependent upon season, climate, geographical location, age, sex, food and state of nutrition, which have to be taken into consideration. Changes in the structure of the thyroid which the author considers abnormal will be discussed under Pathology. The most important factor influencing the size of the thyroid is the amount of iodine available. In the writer's experience a thyroid that has less than 0.1 per cent of iodine per gram of dry gland cannot be normal and a gland that has had continuously a content of greater than this amount cannot be abnormal anatomically.

The normal human adult thyroid weighs between 20 and 25 gms. and does not exceed 0.35 gm. per kilo of body weight. It is slightly larger per unit of body weight in women and relatively much larger in infants than in adults, being 1 to 700–1000 for infants and 1 to 2000–2500 for adults. The gland is roughly U-shaped and consists of two lateral lobes, 5 to 6 cm. in length and 2 cm. in width, connected by an isthmus across the trachea anteriorly, usually between the second and fourth tracheal rings. The isthmus varies in width from 1 to 2 cm. and in thickness from 6 to 8 mm. The lateral lobes are rather firmly attached to the thyroid and cricoid cartilages and the isthmus to the trachea. It therefore moves with the trachea on swallowing. The only portion of the gland which is readily

palpable is the isthmus. This may be felt to ride under the finger held against the trachea in the suprasternal notch while the individual swallows. The lateral lobes lie behind the sternohyoid, sternothyroid and sternomastoid muscles which prevent their palpation with certainty either from above in the angle of the sternothyroid and sternomastoid muscles or from the side behind the sternomastoid. The isthmial lobe (pyramidal process), when present, is readily palpable, as is also its upward prolongation, the thyreoglossal stalk. The lateral lobes are concave on their inner surfaces to fit the curvature of the larynx and trachea, while the external surfaces of the lobes are slightly convex.

The entire gland is invested with an outer areolar capsule which strips readily and an inner thin and translucent true capsule. Trabeculae extend into the gland from the true capsule and vaguely mark out lobules and support the blood and lymph vessels. These trabeculae and their ramifications constitute the gland stroma which is normally scant (Wegelin, 1910).

The color of the normal thyroid is similar in all animals and varies from a pale, translucent amber red to a bright amber red. In consistence it is firm and elastic. On section the larger follicles are visible to the eye and vary from 0.05 mm. to 0.5 mm. in diameter. All the follicles contain a viscid, clear, amber-colored globulin—colloid—which gives to the thyroid its specific characteristics, both chemical and physical. The colloid material in the follicle is believed to be only the vehicle for storing the very active hormone, thyroxin, to which it is loosely bound chemically.

5. *Blood vessels:*

The thyroid is one of the three or four most vascular tissues in the body. The normal blood flow is estimated at from 3.5 to 6.0 c.c. per gram. This may be doubled or more in extreme hyperplasias. The blood supply is derived from the right and left superior thyroid arteries which arise from the external carotids, from the right and left inferior thyroid arteries which arise from the right and left thyroid axis and from the inconstant thyroid ima, which arises either from the innominate artery or from the arch of the aorta. The thyroid arteries form extensive anastomoses on the surface but none in the depths of the gland. Schmidt (1894), Horne (1892) and Hesselberg (1910) have described endothelial buds ("Knospen") in the arterioles, which may act to reduce the speed of the blood flow and break the pulse wave effects which in a gland with so short and wide a capillary path would otherwise pass through to the veins. The thyroid may be perfused at the pressure of 15 to 20 mm. Hg. The capillaries are very wide and form rich anastomosing networks about each follicle, second in magnitude only to the capillary network of the lung alveoli. The veins are of large size and form a prominent network beneath the capsule. From these are formed large venous trunks which, though very irregular, may be grouped into (1) the superior thyroid veins which leave the gland with the superior thyroid artery and pass into the internal jugular vein, (2) the middle thyroid veins which leave with the inferior thyroid artery and pass into the jugular veins and (3) the inferior thyroid veins which emerge from the lower pole and isthmial portion and pass into the left innominate vein (Major, 1909).

The gland is richly supplied with lymphatics which arise as networks of spaces about the follicles and pass to the subcapsular zone along the septa where they form a very large plexus. On leaving the gland they pass to the deep cervical lymph glands along the internal carotid arteries (Bartels, 1901; Matsunaga, 1909).

6. *Nerves:*

The thyroid nerves are entirely of the non-medullated variety, according to Rhinehart (1912), and in comparison with the thymus and parathyroid, the thyroid is very richly supplied. These nerves leave the spinal cord between the second and seventh thoracic segments and end about the ganglion cells of the middle and superior cervical ganglia. The postganglionic fibers reach the thyroid directly along the blood vessels or indirectly through the superior laryngeal and recurrent laryngeal nerves. All the nerves enter the gland in the adventitial coats of the vessels, around which they form elaborate plexuses. These plexuses give off numerous branches to the blood vessels, while other branches penetrate between the follicles to form the perifollicular plexuses which completely surround all follicles. The final endings are short, varicosed fibrillae with straight or curved knob-like enlargements which end against the basal portions of the cells, but never entering or penetrating between the cells. Only a few cells in each follicle can be demonstrated to come into relation with nerve endings. No ganglion cells are present (Engel, 1926).

The anatomical evidence would indicate both vasomotor and secretory nerves. The former have been abundantly demonstrated, while the latter are still doubtful, despite the large amount of effort expended. The methods used in attempting to demonstrate secretory fibers are so indirect that the results obtained may be accounted for in a variety of ways. That some sort of a regulatory nervous control, in addition to chemical control, normally exists need not be doubted, but to designate such a nervous mechanism, secretory nerves, is another matter. On the other hand, the method of thyroid transplantation (Manley and Marine, 1915) supplies very direct evidence that nerves are not essential in order that the gland may exhibit all the known characteristics of functional activity.

7. *Microscopic (Figs. 249, 250):*

The unit of the thyroid is the individual follicle. Williamson and Pearse (1923) have described the thyroid unit as consisting of a system of closed tubules more or less suspended in a lymph sac. The accuracy of this conception has not been established. The microscopic appearance of the follicle is similar in all animals from fish to man. The follicles are irregular, rounded, oval, elongated or even tubular closed spaces of highly variable dimensions (0.05 to 0.5 mm.), lined by a single layer of low cuboidal or at most cuboidal

epithelium (high cuboidal or columnar epithelium always indicates hypertrophy). Superficially the cells are fairly regular in size and rest on a slight condensation of the perifollicular connective tissue, but as noted by Langendorff (1889) there is no true basement membrane. Langendorff demonstrated two types of cells in the follicles of calves and dogs: (1) chief cells and (2) colloid cells. All subsequent observers have confirmed this fact. The number of chief cells is always much greater. In some follicles there may be no colloid cells: in others, one or two, and occasionally whole follicles may be seen composed of these cells. These two types of cells are present in all animals examined (amphibians, reptiles, birds and mammals). In sections prepared by the Ehrlich-Biondi method, Lagendorff was able to distinguish the chief cells which remain clear from the colloid cells which stain red. The colloid cells, according to Uhlenhuth (1925), stain readily with acid dyes after fixation in fluids containing acetic acid. The nuclei of the colloid cells are, as a rule, smaller, more pycnotic and more centrally placed. The nuclei of the chief cells are larger, vesicular and lie towards the base. The secretory process has been studied by many workers including Biondi (1888), Hürthle (1894), Andersson (1894), Bensley (1916), and Uhlenhuth (1923, 1924), and it is now generally accepted that colloid-like droplets formed in the cytoplasm swell the cells which ultimately rupture and extrude their contents into the follicular spaces. The evidence for two separate types of epithelial cells with possibly separate functions as suggested by Bensley is not convincing. Uhlenhuth believes the Bensley cells are colloid cells which discharge their contents into the follicular spaces and after this discharge they collapse to become Langendorff colloid cells which in turn may regenerate or be destroyed. The evidence at present available would indicate that the chief cell, the Bensley cell, and the Lagendorff cell probably represent stages of the secretory cycle through which the normal epithelial cell passes.

8. *Interfollicular epithelium:*

In the human thyroid there are normally small groups of undifferentiated thyroid cells lying in the interfollicular stroma. The number of these cells varies. They are most numerous in the thyroid during late fetal life and infancy and normally decrease with age. In the thyroids from districts of endemic goiter they are much more numerous than in those from non-goiterous districts. They are present in the thyroids of lower animals, particularly the rat, but never to the degree seen in man. These cell rests may be considered as the excess of undifferentiated and vegetative thyroid tissue developed during the period of fetal differentiation and normally destined to undergo gradual absorption, but potentially capable of growth and varying degrees of differentiation whenever a sufficient stimulus for increased thyroid activity is applied. Wölffler (1880) was the first to point

out their relation to thyroid adenomata. Adenomata are integral and essential parts of endemic goiter in man. The fact that both the cell rests and adenomata occur with great frequency in man and with great rarity in the lower animals cannot be overlooked.

Lymphoid cells represented by scattered small foci in the stroma are normally present in the thyroid. Under certain conditions associated with general overgrowth of lymphoid tissue, as in status lymphaticus and exophthalmic goiter, the lymphoid cells of the thyroid may undergo extraordinary hyperplasia with the development of typical lymph gland structure, invade and even destroy the thyroid follicles over large areas (Simmonds, 1913).

Actively phagocytic reticulo-endothelial cells (tissue mast cells of the older workers) occur in the interfollicular stroma. According to Williamson and Pearse (1926), they are more prominent in the hyperplastic gland, and these authors assume that they takep art in the normal activities of the thyroid.

Mitochondria occur in the form of thin filaments in the normal cell. These are always markedly increased in size and length as the cells become hypertrophic. The filaments are arranged parallel to the long axis of the cell and are most numerous in the zone between the nucleus and follicular lumen. Seecof (1925*) and others have shown that the increase in mitochondria is a characteristic feature of all thyroid hyperplasias and has no necessary relation to its clinical association.

The Golgi or reticular apparatus is normally located between the nucleus and the follicular lumen. Cowdry (1922) found in the guinea pig thyroid about one cell in every 500 in which the Golgi apparatus was located between the nucleus and the base of the cell, and has been able to trace its migration from the follicular side of the nucleus to the proximal side and vice versa.

9. *The mode of secretion and excretion:*

The thyroid gland has the morphological appearance of a storage gland and it can be readily demonstrated experimentally that a rapid storage of colloid and an equally rapid excretion of colloid occur. The mechanism, however, of its secretion and excretion is not understood. Bensley (1916) has advanced the view that the polarity of the thyroid cell has been reversed so that it secretes normally in the direction of the perifollicular capillaries. He bases this conception on the demonstration in the opossum thyroid that secretion antecedents are contained in vacuo-like areas and concentrated toward the basal end of the cell instead of the free end, as occurs in ordinarily secreting glands like the pancreas.

Cowdry (1922) believed the occurrence of thyroid cells in which the Golgi apparatus was reversed offered further support of Bensley's view. Under this hypothesis Bensley (1916) would explain the storage of colloid

*See also Seecoft, David P. *Am. J. Path.*, 1927, 3, 363.

in the follicles by assuming a disturbance in the adjustment of the rate of secretion so that when the gland produces its secretion in excess of the body needs it is excreted into the follicles. As to the mode of excretion, the older histologists noted the presence of colloid-like material in the perifollicular lymphatics and interpreted this as indicating that the colloid was discharged into the lymphatics either by osmosis through the cell or by way of intracellular passages. Rogoff and Goldblatt (1921) have shown by means of the tadpole test that the thyroid hormone passes into the blood stream, and Carlson, Hektoen and Shulhof (1925) have demonstrated by means of the precipitin test the presence of thyreoglobulin in the lymph obtained from dog's thyroid, although they admit it is present in much greater quantities in the blood of the thyroid veins.

10. Physiology:

Our knowledge of the physiology of the thyroid began with Gull's (1874) association of atrophy of this gland with myxedema (Gull's disease). The Reverdin brothers (1882) and T. Kocher (1883) reported the accidental occurrence of a symptom complex similar to myxedema (cachexia strumipriva) following the removal of the thyroid for goiter in man. Von Eiselsberg (1890), Wegelin (1925) and many others later reported cases of cachexia strumipriva. These observations in man stimulated a great deal of experimental work on animals by Horsley (1886) and Wagner (1884) on dogs, and by Gley (1891*a*, *b*) on rabbits. None of these observers knew of the importance of the parathyroids, and most of the animals died of tetany as did many human cases following thyroidectomy. Indeed, as we now understand the function of the parathyroids these early observers mistook symptoms of parathyroidectomy for those of thyroidectomy. After Gley (1891*a*) pointed out that no symptoms occurred in the rabbit if the III parathyroids (glandules thyroidiennes) were not removed, many species of animals have been subjected to thyroidectomy, using standard surgical technique and eliminating the parathyroid factor.

11. Effects of removal:

The most striking effect of thyroidectomy is a reduction in total metabolism. This decrease (measured as heat production) begins between the fifth and seventh day after thyroidectomy in the rabbit and reaches its lowest level between the twentieth and thirtieth day (Marine, 1923). The maximum decrease in heat production may reach 35 to 40 per cent and corresponds closely to that observed in the severest form of spontaneous myxedema in man. While qualitatively, the symptoms of thyroidectomy in both young and adult animals are similar, the visible manifestations of thyroidectomy are strikingly more prominent in animals thyroidectomized during the period of growth. Adult herbivora like the rabbit, sheep and goat may show very little change clinically beyond the dryness and thicken-

ing of the skin, dryness and thinning of the hair, a gain in weight, lowering of the body temperature and mental and physical sluggishness. Heat production measurements, however, always show a marked decrease. In growing animals there are in addition to the above symptoms the gross manifestations of stunted physical, mental and sexual development. The thyroid, therefore, does not appear to be strictly essential for the vegetative life of adult animals in the sense that the parathyroids or suprarenals are, and in the young it is only indirectly essential in that it is necessary for growth and differentiation.

Murray (1891) made the important discovery that injecting a glycerol extract of the thyroid or feeding the gland by mouth completely cured cases of Gull's disease. Since then, it has been found that feeding thyroid gland completely compensates for the loss of the thyroid gland.

Magnus-Levy (1895,1897) showed that the essential effect of feeding thyroid substance to cases of myxedema and to normal individuals as well was to raise the rate of metabolism. Up to the present time this is the only known pharmacological and physiological effect of the thyroid.

Baumann (1896) discovered the presence of iodine in the thyroid and isolated an amorphous substance by acid hydrolysis (iodothyrin) containing as high as 9.3 per cent of iodine. A. Oswald (1897, 1901) observed that iodine was contained in the colloid and that the colloid consisted mainly of globulin. He showed that the iodine varied in general with the amount of visible colloid.

The extensive investigations of Marine and Williams (1908) and Marine and Lenhart (1909*a*, *b*) on the relation of iodine to the histological structure of the thyroid in man, dog, sheep, ox, pig, cat and fish showed that there is a very close relation between the iodine store and the histological condition of the gland; namely, that the iodine store varied in general with the amount of stainable colloid and inversely with the degree of hyperplasia. The relations of iodine to the histological structure as found by Marine and Lenhart are given in the following table.

TABLE 1

RELATIONS OF IODINE TO THE HISTOLOGICAL STRUCTURE OF THE THYROID GLAND

	Normal	Early hyperplastic stage	Moderate hyperplastic stage	Marked hyperplastic stage	Colloid or resting stage
Man	2.17*	0.88	0.71	0.32	2.00
Dog	3.32	0.62	0.37	0.11	1.99
Sheep	2.47	....	0.40	0.01	3.00
Ox	3.46	1.65	....	0.19	
Pig	2.51	1.10	....	....	2.35

* Iodine in milligrams per gram of dried gland.

Iodine appears in the thyroid very early in fetal life. Fenger (1913) found it as early as the third month of fetal life in cattle. The extraordinary affinity of the thyroid for iodine was first shown by Baumann and his pupils (1896). Marine (1915) showed that as much as 18.5 per cent of a single dose of 38 mgms. KI given to a dog by mouth may be stored in the thyroid within two hours. This affinity for iodine is also demonstrable in perfusion experiments with surviving thyroid. The maximum storage of iodine per gram of dried thyroid has been found to be between 5 and 6 mgms., while the minimum is zero, and the average around 2 mgms. The maximum iodine store of the normal adult thyroid is about 30 mgms., while the average is between 10 and 15 mgms. The minimum amount of iodine necessary for the maintenance of normal gland structure for ordinary laboratory animals is about 1 mgm. per gram of dried gland.

The storage of iodine in the thyroid causes a very rapid involution of any existing hyperplasia and the return of the gland cells to their normal appearance. The pharmacological and physiological activity of the thyroid is proportional to the iodine content, and for therapeutic purposes it has been standardized on the basis of 0.2 per cent iodine since 1902.

Attempts to isolate the iodine-containing hormone in crystalline form began with Baumann (1896) and despite the continued efforts of a large number of chemists this was not accomplished until Kendall (1915) announced its isolation and named the substance thyroxin. According to Kendall, thyroxin crystallizes in rosettes and sheaves of needles, melts around 250°C., is insoluble in acid but soluble in alkali, contains about 65 per cent iodine and has the empirical formula $C_{11}H_{10}O_3NI_3$. From numerous analyses, Kendall and Osterberg (1919) concluded that this substance was 4, 5, 6 trihydro-triiodo- 2 oxy-beta-indolepropionic acid of the following constitution:

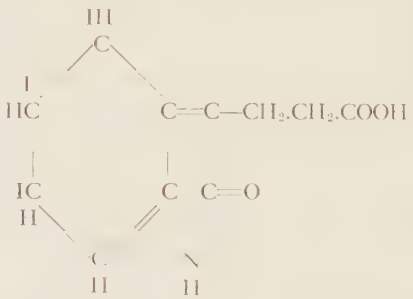

The inherent chemical improbability of such a formula was universally recognized, but owing to a lack of sufficient thyroxin for analysis, it was not until Harington (1926*a*) announced the perfection of a simple method for the more complete isolation of thyroxin, that sufficient amounts for study were obtained. Harington's analyses give thyroxin the empiric formula $C_{15}H_{11}O_4NI_4$. Structurally Harington (1926*b*) has shown thyroxin to be beta-tetra-iodo-(3, 5, 3′, 5′)*-4-(4′-hydroxy pheynoxy) phenyl-alpha-amino propionic acid, with the following formula:

* There is still some doubt about the positions of the four iodine atoms.

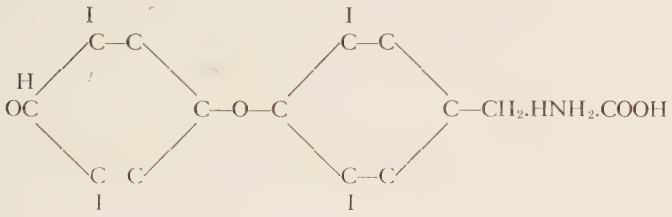

The work of Harington indicates that thyroxin is related to tyrosine and eliminates the view that tryptophane is the mother substance of thyroxin, as Kendall's work suggested.

While not all the iodine is present as thyroxin, so far as is known thyroxin accounts for the essential action of thyroid substance on metabolism. The major function, therefore, of the thyroid, as we now understand it, is to provide a means through its iodine-containing hormone (thyroxin) for maintaining a higher rate of metabolism than would otherwise exist, and also through fluctuations in its activity it provides a means for varying the rate of metabolism to meet changing physiological needs.

12. Regeneration:

Mammalian and avian thyroids regenerate rapidly after partial removal (Marine and Lenhart, 1909c). Two major factors—the amount of thyroid removed and the administration or withholding of iodine-containing compounds—and many minor factors, diet, age, species, state of nutrition, pregnancy and many physiological conditions, determine the degree of regeneration. In the dog, if one removes three-fourths of the gland, ordinarily regeneration occurs in the remaining portion; but if small amounts of iodine are given such regeneration does not take place. If much more than three-fourths of the gland in dogs is removed iodine will not protect against regeneration, but desiccated thyroid will still protect. Halsted (1896) made an extensive study of thyroid regeneration in dogs. Ribbert (1889) showed that regeneration begins within a few days after partial removal and occurs first in the subcapsular zone. Anatomically and chemically the thyroid changes in regeneration are identical with those occurring in the spontaneous hyperplasias of goiter and are controllable by the same methods. That is, cellular hypertrophy and hyperplasia do not occur until the iodine store falls below a given level (1.0 mgm. per gram).

13. Transplantation:

Transplantation of the thyroid has been extensively studied by the Cristianis (1905), L. Loeb (1918) and by Manley and Marine (1916). Thyroid tissue autografts readily in any part of the body and shows all the chemical and morphological reactions seen in the non-transplanted

tissue. The growth of a transplant varies with the degree of thyroid insufficiency created in the host. The administration of iodine and desiccated thyroid inhibits the growth of thyroid transplants. Frozen thyroid tissue of rabbits also autografts readily. Homeografts are usually absorbed. Barring technical errors, however, they all "take," but begin to undergo absorption as early as the seventh or eighth day. Some animals destroy initial homeografts much more slowly than this, indicating that there are different degrees of foreignness of the transplanted proteins in animals as well as in man. In man, by transplanting within the same blood group, it is probable that the average life of homeografts might be prolonged, but homeotransplantation at present has no permanent value and must continue so until some means is discovered to overcome the foreign protein reaction.

Heterotransplantation of the thyroid never succeeds.

14. Interrelations:

Correlations of function are brought about by the acceleration or inhibition of functional activity by means of chemical factors (hormones) acting directly on the cells through the blood and lymph streams or indirectly through nerve impulses. The important correlations of the function of the thyroid with other glands are given below:

Thyroid—Parathyroid. No interrelation of function is known (see interrelationships under parathyroid).

Thyroid—Thymus. The view that the thymus and thyroid functions are correlated has considerable general evidence to support it—the most important of which is referred to under *thymus* interrelationships.

Thyroid—Suprarenal Gland. The interrelationship postulated by Eppinger, Falta and Rudinger (1908) which assumed that the chromaffin system directly stimulated the thyroid has received experimental support from Ascher and Flack's (1910) demonstration that the blood pressure response in rabbits to a given dose of adrenaline was greater after stimulation of the thyroid nerves than before such stimulation.This observation has been confirmed from several sources (Levy, 1916). The Goetsch epinephrine test in exophthalmic goiter is a clinical application of this reaction. A. Oswald (1915) showed that a similar increase in the epinephrine response could be obtained by injecting iodothyreoglobulin. The mechanism of this reaction is still in doubt, although it is assumed that the thyroid hormone sensitizes the cells innervated by the sympathetic nervous system, presumably at the cytoneural junction.

Feeding thyroid to rats and rabbits causes hypertrophy of the suprarenal cortex (R. G. Hoskins, 1910) and increases the epinephrine store (Herring, 1920).

Marine and Baumann (1921) showed that if the suprarenals of rabbits are sufficiently injured, as by freezing or partial removal, a marked rise in heat production (as much as 60 per cent) occurs from three to six days after suprarenal injury and continues from a few days to several months. If the thyroid gland is removed prior to the suprarenal injury, no rise in heat production occurs (Marine and Baumann, 1922). Marine and Baumann (1922) were unable to show that thyroidectomy notably prolonged the life of suprarenalectomized rabbits. Zwemer (1925) reported that thyroidectomized cats sur-

vived suprerenalectomy longer than non-thyroidectomized cats. Cramer (1916) believes that since both thyroxin and epinephrine have the power of causing increased heat production, there is a very close relationship between the physiological activities of these two glands. A further close relationship is suggested by the fact that both thyroxin and epinephrine are related chemically to tyrosine.

Thyroid—Hypophysis. Rogowitch (1889) first pointed out that the pars anterior and intermedia enlarged following the removal of the thyroid. This has been generally confirmed and interpreted as indicating that the hypophysis could function vicariously for the thyroid. It has been frequently reported that the hypophysis contains iodine, but Simpson and Hunter (1910) showed conclusively that iodine is not a normal constituent of the hypophysis in amounts greater than that of the body tissues in general.

In acromegaly the thyroid is enlarged and this usually is associated with an increased metabolic rate. L. Loeb and Kaplan (1924) claimed that feeding anterior hypophysis substance prevents compensatory hypertrophy of the thyroid of guinea pigs following partial removal.

On the other hand, the observations of Smith (1916, 1922) definitely show that ablation of the anterior hypophysis in tadpoles causes extreme atrophy of the thyroid. Feeding anterior hypophysis substance does not activate the atropic thyroid, but injecting moderate amounts of fresh ox anterior lobe substance causes the atrophic thyroid to regenerate, and larger doses cause marked hypertrophy and hyperplasia. These facts indicate a direct functional relationship between the thyroid and hypophysis and anterior hypophysis, even though its exact nature and limitations cannot be defined.

Thyroid—Sex Glands. The association of thyroid enlargement with puberty, pregnancy, menopause and the more frequent occurrence of goiter in the female have been known since antiquity. We are, however, still ignorant of the nature of this association. Removal of the sex glands often causes involution of the thyroid and a slight depression of its functional activity (as indicated by heat production measurements). Gaskell (1908), on the basis of a hypothetical resemblance of the endostyle organ to the uterus of scorpions, sought to explain the relation of the sex glands to the thyroid by assuming that the endostyle organ of *Ammocoetes* was descended from the uterus of animals like the scorpion and king crab. Torrey and Horning (1922) state that cockerels when fed with large amounts of thyroid substance assumed hen plumage. The meager evidence available would tend to indicate that the interstitial cells of the ovary and perhaps also the suprarenal cortex play a part in this relationship in the female. The thyroid enlargement associated with sex gland activity is identical in appearance with that seen in simple goiter.

Thyroid—Pancreas and Liver. Falta (1910) assumed that the thyroid and pancreas were antagonistic since an epinephrine injection which in normal dogs causes a marked glycosuria does not produce glycosuria in thyroidectomized dogs. Similar observations have been made by Grey and de Sautelle (1909) on dogs and by Pick and Pineles (1910) on goats. Underhill and Hilditch (1910), however, deny that thyroidectomized dogs in which great care has been exercised to preserve the two external parathyroids are less susceptible to adrenaline glycosuria. Cohen and Peiser (1912) have reported the frequent association of the symptoms of Graves' disease with acute pancreatitis. Thyroid feeding reduces the glycogen in the liver. In Graves' disease the alimentary tolerance for glucose is often decreased, while in myxedema it is increased. The significance of these facts as regards any thyroid-liver or pancreas relationship is very doubtful. What evidence there is seems to indicate that any thyroid-liver-pancreas interrelationship is an indirect one dependent on epinephrine. Whipple and Christman (1914) have shown that thyroidectomy does not influence the excretion of phenoltetrachlorphthalenin of the liver.

15. Pathology:

The diseases of the thyroid due to disturbance of its functions may be divided into two groups as follows (Marine, 1923):

I. Thyroid insufficiency
   a. Simple goiter (endemic, sporadic)
   b. Myxedema
      1. Infantile (cretinism)
      2. Adult (Gull's disease)

II. Exophthalmic goiter

These two groups are now popularly designated hypo- and hyperthyroidism. They overlap to some extent. Myxedema may supervene in the course of exophthalmic goiter and exophthalmic goiter may develop on the basis of a simple goiter, although there does not appear to be any necessary relationship between the two groups. The lower animals are as susceptible to simple goiter as is man, while exophthalmic goiter does not occur in them spontaneously. Simple goiter is primarily a thyroid disease depending upon a relative or absolute deficiency of iodine while exophthalmic goiter is primarily a disease of the nervous system more particularly of the visceral nervous system.

The essential anatomical changes of the thyroid in goiter are relatively simple and may be indicated in the following scheme (Marine and Lenhart, 1911*a*):

Normal thyroid→hypertrophy→hyperplasia → exhaustion atrophy / colloid or resting stage

Colloid thyroid→hypertrophy→hyperplasia → exhaustion atrophy / colloid or resting stage

Colloid →hypertrophy→hyperplasia → exhaustion atrophy / colloid or resting stage

(Compare Figs. 251 to 257)

The secondary changes in the thyroid comprise a great variety of progressive, regressive, degenerative, inflammatory, atrophic and neoplastic changes which, as Virchow (1863) pointed out, are terminal metamorphoses and complications occurring in long-standing goiters.

The anatomical cycle indicated above is the same for all animals with the ductless thyroid (Marine, 1907*a*, *b*; Marine and Lenhart, 1910). The thyroid cell begins to hypertrophy when the iodine store falls below a critical level (in our experience below 0.1 per cent) and continues this hypertrophy and hyperplasia until exhaustion atrophy or recovery (involu-

lution) occurs. By anatomical recovery, one means the involutoin of the active hyperplasia to the colloid or resting stage. Colloid goiter is the nearest condition to normal, both anatomically and chemically, that a thyroid which has once been in a state of active hyperplasia can assume, and such colloid goiters are capable of exhibiting all of the reactions which a normal gland can exhibit (Marine and Lenhart, 1909c). Thus they can repeat the cycle of hypertrophy, hyperplasia and involution many times during the life history of the animal. This cycle of cell changes is not specific for any disease with which the thyroid is associated but occurs in response to any stimulus for increased activity which brings about depression of the iodine store irrespective of its clinical association.

The first change in the thyroid in developing goiter is a decrease in the iodine store. The blood flow is increased, the stainable colloid decreases. The follicular epithelium changes from the normal low cuboidal to cuboidal to columnar and in extreme degrees of hyperplasia to high columnar with infoldings and plications. There are all degrees of the abnormal cell growth from the slightest departure from normal (hypertrophy) to the marked proliferations (hyperplasia). A similar series of chemical and anatomical changes occur incompensatory regeneration following removal of sufficient thyroid (Figs. 251 to 254).

As the epithelial cells increase in size, their nuclei correspondingly enlarge, become vesicular and occupy a basal position. The mitochondria also increase in number and become filamentous, arranged parallel with the long axis of the cell, and are most numerous between the nucleus and the lumen proper.

The hypertrophy and hyperplasia may be arrested at any stage, either spontaneously or due to the administration of iodine. In that event the blood supply decreases, the colloid accumulates in the alveoli up to and even above its normal density and the epithelium involutes back to a normal low cuboidal type if the involution is complete. The thyroid in this completely involuted state is designated colloid goiter (Fig. 255). From this colloid or resting state the gland may undergo hyperplasia again followed by involution, and the process of hyperplasia and involution may be repeated possibly hundreds of times during the life history of the animal.

On the other hand, the hyperplasia, however extreme, may not bring about physiological compensation. In that event, the hyperplasia does not involute but goes on to terminate eventually as a fibrotic atrophy due to exhaustion. Exhaustion is believed to result from sustained hyperactivity without periods of physical rest. This condition is often seen in the late stages of exophthalmic goiter and in endemic cretinism. Microscopically the colloid is practically absent. The epithelial cells are in the early stages high columnar with infoldings and plications as in the active hyperplasia. Later the cells lose their uniform and regular shape and size so character-

istic of the early stages of active hyperplasia. The cells become irregular, some very large, others very small. There is often some piling up of the epithelial cells. The nuclei are in general large, often hyperchromatic, sometimes small and pycnotic and very irregular in size and shape. Mitotic figures may still be seen but the new formation of cells is not sufficient to offset cell death and the follicles become smaller though still preserving the infoldings of the earlier uniform hyperplasia. The stroma is relatively, perhaps absolutely, increased and as the follicles become smaller due to the loss of their secreting epithelium the fibrous bands become wider and give to the gland the appearance of a diffuse fibrosis or cirrhosis in which lie the nests of distorted and degenerated cells of the former follicles. This is the simplest picture of the thyroid changes that occur in the exhaustion atrophies of myxedema and cretinism (Figs. 256 and 257).

One of the most striking demonstrations of the capacity of cells to recover when given physical rest may be seen in the exhaustion atrophies of the thyroids of cretin lambs and pups. I have seen thyroids, so atrophic that it was impossible to recognize them as thyroid tissue, undergo practically complete recovery to normal type both as regards their chemical and anatomical condition following the administration of a few milligrams of iodine daily over a period of two months (Marine, 1923), (Figs. 258, 259, and 260).

In the lower animals with the exception of the rat the cell cycle including hyperplasia and involution is quite regular and uniform, while in man it frequently becomes irregular and nodular—the so-called stroma nodosa or adenomatous goiter. These nodules or adenomas are formed by the more rapid growth of certain foci of thyroid cells in response to the general stimulation of the thyroid (Marine, 1913*b*). It is believed that they may arise both from differentiated thyroid alveoli and from cell rests as pointed out by Wölffler (1883). These adenomas are an integral and essential part of endemic goiter in man and are due to the same stimulus which excites the thyroid as a whole to hypertrophy. These multiple circumscribed glandular growths are functionally active. Yet they have certain of the attributes of tumor, one of which is that their growth once initiated is frequently not controlled by iodine as is all physiological hyperplasia. The terminal metamorphoses are far more serious than those of simple hyperplasia since in addition to their possible rôle in the etiology of Graves' disease, possibly 90 per cent of the malignant epithelial tumors of the thyroid arise from them.

16. Simple goiter:

Simple or endemic or sporadic goiter is a compensatory or work hypertrophy of the thyroid dependent upon a relative or absolute deficiency of iodine (Marine, 1924).

This deficiency of iodine may result from:

1. Factors which increase the needs of the organism for thyroxin, such as occur during puberty, pregnancy and lactation, during the menopause, during certain infectious diseases and intoxications following sufficient

injury to the suprarenal gland or following the use of diets composed mainly of fats and proteins.

2. Factors which interfere with the absorption or utilization of the normal intake of iodine. We have no knowledge of such factors although it is conceivable that intestinal flora or intestinal parasites could utilize or divert the iodine normally ingested.

3. Factors which bring about an abnormally low intake or actual deprivation of iodine either naturally or experimentally.

The normal source of iodine is from food or water, although traces may be taken from the air in the immediate vicinity of the sea. In districts of endemic goiter it has been essentially shown, first by Chatin (1852), that both the food and water derived from such soils are very low in iodine.

17. Exophthalmic goiter:

Exophthalmic goiter or Graves' disease, on the other hand, appears to be a disease of the nervous system in which the visceral nervous system is most prominently involved. It is characterized by a profound disturbance of the regulatory control and functional interactions of all organ activities, and the most prominent manifestations of the disease are increased metabolism of thyroid origin, general asthenia, tachycardia and moderate enlargement of the thyroid. The thyroid plays an important rôle in the clinical manifestations of the disease but we must look beyond the thyroid for the essential and primary lesions (Marine and Lenhart, 1911*b*). The thymus, liver, pancreas and suprarenals are also involved in this disease in an important but still unknown way.

18. Myxedema:

This is a chronic disease due to a high grade thyroid insufficiency and characterized by greatly reduced metabolism, resulting in stunted mental and physical development if occurring during the growing period and in trophic disturbances, cachexia and mental deterioration if occurring in adults. The disease may be arbitrarily divided into two groups, (1) infantile myxedema or cretinism, and (2) adult myxedema or Gull's disease.

1. Infantile myxedema may occur sporadically or endemically—the latter found in association with endemic goiter. Goiter is the first step on the road to cretinism (Morel, 1864). Many observers believe that cretinism is a more complex nutritional disturbance than can be explained on the basis of a thyroid insufficiency. This belief is based on the facts that many other conditions—dwarfism, Froehlich's disease, rickets and Mongolian idiocy—have in the past been confused with cretinism and that postnatal treatment with desiccated thyroid is usually not successful, while in myxedema of adults desiccated thyroid is highly successful. The postnatal therapeutic test is a fair or physiological test because the most irreparable effects

of thyroid insufficiency occur during fetal and early postnatal life. A more appropriate test is the administration of iodine to the mother during pregnancy and in the first days of life. This has been done in endemic cretin puppies with complete recovery or prevention.

The work of Smith (1916), Allen (1917) and Evans (1924) showing that removal of the anterior hypophysis in tadpoles causes atrophy of the thyroid, if applicable to higher animals, would indicate that the hypophysis may be a factor in cretinism. Opposed to Smith's finding, however, is the fact that most cases of experimental and spontaneous myxedema and cretinism have enlargement of the anterior hypophysis. Certainly the major lesion in cretinism is a thyroid insufficiency. While a loss of thyroid function sufficient to cause myxedema or cretinism may be due to injury or destruction of the thyroid by trauma or infection, also destruction of the anterior hypophysis (Smith, 1922), congenital absence or smallness of the thyroid or atrophy of unknown nature is the most important cause of endemic cretinism.

2. Myxedema of adults. This is the best understood effect of a pathological decrease in thyroid function, because it is not complicated by the ill-understood and intricate process of growth and differentiation. Spontaneous and operative myxedema are entirely the same. The first recognized experimental myxedemas were produced in man by the Reverdin brothers (1883) and by T. Kocher (1883) by the removal of goiters. Spontaneous myxedema is from six to eight times more frequent in women and exophthalmic goiter is the most important known antecedent. The disease as pointed out by Gull is usually associated with exhaustion atrophy of the thyroid, but it is now known that thyroid enlargement may be present just as in congenital myxedema.

BIBLIOGRAPHY (THYROID)

Allen, B. M. 1917. Effects of the extirpation of the anterior lobe of the hypophysis of *Rana pipiens*. *Biol. Bull.*, **32**, 117.

Andersson, O. A. 1894. Zur Kenntniss der Morphologie der Schilddrüse. *Arch. f. Anat. u. Entw., Anat. Abth., Leipz.*, 177.

Ascher, L., and Flack, M. 1910. Die innere Sekretion der Schilddrüse und die Bildung des inneren Sekretes unter dem Einfluss von Nervenreizung. *Ztschr. f. Biol.*, **55**, 83; also *Zentralbl. f. Physiol.*, **24**, 211.

Bartels, P. 1901. Ueber den Verlauf der Lymphgefässe der Schilddrüse bei Säugethieren und beim Menschen. *Anat. Hefte*, **16**, 333.

Baumann, E. 1896. Ueber das normale Vorkommen von Jod im Thierkörper. *Zeitschr. f. Physiol. Chem.*, **21**, 319.

Baumann, E., and Roos, E. 1896. Ueber das normale Vorkommen des Jods in Thierkörper. *Ibid.* **21**, 481.

Bemmelen, van. 1889. Ueber die Suprapericordialkörper. *Anat. Anz.*, **4**, 400.

Bensley, R. R. 1916. Normal mode of secretion in thyroid gland. *Am. J. Anat.*, 1916, **19**, 37.

Biondi, D. 1888. Beitrag zu der Structure u. Function der Schilddrüse. *Berl. klin. Woch.*, **25**, 954.

Born, G. 1883. Ueber die Derivate der embryonalen Schlundbogen u. Schlundspalten bei Säugethieren. *Arch. f. mikr. Anat.*, **22**, 271.

Carlson, A. J., Hektoen, L., and Schulhof, R. 1925. Attempts to produce experimental increase in the rate of output of thyroglobulin by the thyroid gland. *Am. J. Physiol.*, **71**, 548.

Chatin, A. 1852. Recherche de l'iode dans l'air, les eaux, le sol et les produits alimentaires des Alpes de la France. *Gaz. d. Hôp., Paris*, **25**, 14, 38, 50, 86, 94.

Cohen, M., and Peiser, H. 1912. Einige Störungen der inneren Sekretion bei Pankreaserkrankungen. *Deutsch. med. Woch.*, **38**, 60.

Cowdry, E. V. 1921. Flagellated thyroid cells in the dogfish (Mustelus canis). *Anat. Record*, **22**, 289.

——— 1922. The reticular material as an indicator of physiologic reversal in secretory polarity in the thyroid cells of the guinea pig. *Am. J. Anat.*, **30**, 25.

Cramer, W. 1916. On the thyroid-adrenal apparatus and its function in the heat regulation of the body. *J. Physiol. (Proc.)*. **50**, 38.

Cristiani, H. 1905. Évolution histologique de greffes faites avec du tissu thyroïdien conservé. *J. de Physiol. et de path. gén.*, **7**, 261.

Dohrn, A. 1887. Studien zur Urgeschichte des Wirbelthierkörpes. XII. *Mitteil. Zool. Stat., Neapel*, **7**, 301.

Eiselsberg, A. 1890. *Ueber Tetanie im Anchlusse an Kropf-Operationen.* Wien: A. Holder. 37 pp.

Engel, W. 1926. Zur Innervation de Schilddrüse. *Pflüger's Arch.*, **211**, 433.

Eppinger, H., Falta, W., and Rudinger, C. 1908. Ueber die Wechselwirkungen der Drüsen mit innerer Sekretion. I. *Zeitschr. f. klin. Med.*, **66**, 1.

Erdheim, J. 1904. Ueber Schilddrüsenaplasie. II, III. *Beit., z. path. Anat. u. allg. Path.*, **35**, 366.

Evans, H. M. 1924. *The function of the anterior hypophysis.* The Harvey Lectures. Philadelphia: J. B. Lippincott Co. P. 212.

Falta, W. 1910. Die Beziehungen zwischen Pankreas und Schilddrüse. *Med. Klin.*, **6**, 40.

Fenger, F. 1913. On the iodine and phosphorus contents, size and physiological activity of the foetal thyroid gland. *J. Biol. Chem.*, **14**, 397.

Gaskell, W. H. 1908. *The origin of vertebrates.* London: Longmans, Green and Co. 537 pp.

Getzowa, S. 1907. Ueber die Glandula parathyreoidea; intrathyreoideale Zellhaufen derselben und Reste des postbrachialen Körpers. *Virchow's Archiv.*, **188**, 181.

——— 1911. Zur Kenntnis des postbranchialen Körpers und der branchialen Kanälchen des Menschen. *Ibid.*, **205**, 208.

Gley, E. 1891*a*. Sur le fonctions de la glande thyroïde chez le lapin et chez le chien. *Compt. rend. Soc. Biol.*, **34**, 843.

——— 1891*b*. Sur les effets de l'extirpation du corps thyroïde. *Ibid.*, **43**, 551.

Grey, E. G., and de Sautelle, W. T. 1909. The relations of the thyroid glands to glycosuria. *J. Exper. Med.*, **11**, 659.

Grosser, O. 1910. Zur Kenntnis des ultimo-branchialen Körpers beim Menschen. *Anat. Anz.*, **37**, 337.

Gull, W. 1874. On a cretinoid state supervening in adult life in women. *Trans. Clin. Soc.*, **7**, 180.

Halsted, W. S. 1896. An experimental study of the thyroid gland of dogs with especial consideration of hypertrophy of this gland. *Johns Hopkins Hosp. Repts.*, **1**, 373.

Harington, C. R. 1926*a*. Chemistry of thyroxine. I. *Biochem. J.*, **20**, 293.

Harington, C. R. 1926*b*. Chemistry of thyroxine. II. *Ibid.*, **20**, 300.

Herring, P. T. 1920. The influence of the thyroids on the functions of the suprarenals. *Endocrinology*, **4**, 577.

Herrmann, G., and Verdun, P. 1900. Note sur les corps post-branchiaux des Caméliens. *Compt. rend. Soc. Biol., Paris*, **52**, 933, 936.

Hesselberg, C. 1910. Die menschliche Schilddrüse in der fötalen Periode und in den ersten 6 Lebensmonaten. *Frank. Zeit. Path.*, **5**, 322.

His, W. 1885. *Anatomie menschlicher Embryonen*. Leipzig. Monograph.

Horne, R. M. 1892. Blood vessels of the thyroid gland in goitre. *Lancet*, **2**, 1213.

Horsley, V. 1886. Further researches into the function of the thyroid and the effects of removal. *Proc. Roy. Soc.*, **40**, 6.

Hoskins, R. G. 1910. Congenital thyroidism. *Am. J. Physiol.*, **26**, 426.

Hürthle, K. 1894. Beiträge zur Kenntniss des Secretionsvorgangs in der Schilddrüse. *Pflüger's Arch.*, **56**, 1.

Kastschenko, N. 1887. Das Schicksal der embryonalen Schlundspalten bei Säugethieren. *Arch. f. mikr. Anat.*, **30**, 1.

Kendall, E. C. 1915. The isolation in crystalline form of the compound containing iodin which occurs in the thyroid. *J. Am. Med. Assn.*, **64**, 2042.

Kendall, E. C., and Osterberg, A. E. 1919. The chemical identification of thyroxin. *J. Biol. Chem.*, **40**, 265.

Kocher, T. 1883. Ueber Kropfextirpationen und ihre Folgen. *Arch. f. Klin. Chir.*, **29**, 254.

Langendorff, O. 1889. Beiträg zur Kenntniss der Schilddrüse. *Arch. f. Anat. u. Physiol., Suppl.-Bd.*, 219.

Levy, R. L. 1916. Studies on the conditions of activity in endocrine glands. IV. *Am. J. Physiol.*, **41**, 492.

Loeb, L. 1918. Syngenesioplastic transplantation of the thyroid in the guinea pig. *J. Med. Res.*, **39**, 39.

Loeb, L., and Kaplan, E. E. 1924. Studies on compensatory hypertrophy of the thyroid gland. VI. *J. Med. Res.*, **44**, 557.

Magnus-Levy, A. 1895. Ueber den respiratorischen Gewechsel unter dem Einfluss der Thyreoidea sowie unter verschiedenen pathologischen Zuständen. *Berl. Klin. Wchnschr.*, **32**, 650.

—— 1897. Untersuchungen zur Schilddrüsen-Frage. *Zeitschr. f. Klin. Med.*, **33**, 269.

Major, R. H. 1909. Studies on the vascular system of the thyroid gland. *Am. J. Anat.*, **9**, 475.

Mall, F. P. 1887. Entwickelung der Branchialbogen und Spalten des Hühnchen. *Arch. f. Anat. u. Physiol., Leipz.*, 1.

Manley, O. T., and Marine, D. 1915. Studies in thyroid transplantation. *Proc. Soc. Exper. Biol. and Med.*, **12**, 202.

—— 1916. Transplantation of ductless glands with reference to permanence and function. *J. Amer. Med. Assoc.*, **67**, 260.

Maresch, R. 1898. Kongenitaler Defekt der Schilddrüse bei einem elf jahrigen Mädchen mit vorhandenen Epithelkörperchen. *Zeit. f. Heilk.*, **19**, 249.

Marine, D. 1907. On the occurrence and physiological nature of glandular hyperplasia of the thyroid (dog and sheep) together with remarks on important clinical (human) problems. *Johns Hopkins Hosp. Bull.*, **18**, 359.

—— 1907*b*. On the physiological nature of the "glandular hyperplasias of dogs' thyroids with a detailed report of a case typical of the group. *J. Infect. Dis.*, **4**, 417.

—— 1913*a*. The evolution of the thyroid gland. *Johns Hopkins Hosp. Bull.*, **24**, 135.

—— 1913*b*. Benign epithelial tumors of the thyroid gland. *J. Med. Res.*, **27**, 229.

Marine, D. 1915. Quantitative studies on the *in vivo* absorption of iodine by dogs' thyroid glands. *J. Biol. Chem.*, **22**, 547.

——— 1923. The importance of our knowledge of thyroid physiology in the control of thyroid diseases. *Arch. Int. Med.*, **32**, 811.

——— 1924. Etiology and prevention of simple goiter. *Medicine*, **3**, 453.

Marine, D., and Baumann, E. J. 1921. Influence of glands with internal secretion on the respiratory exchange. II. *Am. J. Physiol.*, **57**, 135.

——— 1922. Influence of glands with internal secretion on the respiratory exchange. III. *Ibid.*, **59**, 353.

Marine, D., and Lenhart, C. H. 1909*a*. Further observations on the relation of iodin to the structure of the thyroid gland in the sheep, dog, hog, and ox. *Arch. Int. Med.*, **3**, 66.

——— 1909*b*. Relation of iodin to the structure of human thyroids. *Ibid.*, **4**, 440.

——— 1909*c*. Colloid glands (goitres): their etiology and physiological significance. *Johns Hopkins Hosp. Bull.*, **20**, 131.

——— 1910. On the occurrence of goitre (active thyroid hyperplasia) in fish. *Ibid.*, **21**, 95.

——— 1911*a*. The pathological anatomy of the human thyroid gland. *Arch. Int. Med.*, **7**, 506.

——— 1911*b*. Pathological anatomy of exophthalmic goiter. The anatomical and physiological relations of the thyroid gland to the disease; the treatment. *Ibid.*, **8**, 265.

Marine, D., and Williams, W. W. 1908. The relation of iodin to the structure of the thyroid gland. *Arch. Int. Med.*, **1**, 349.

Marshall, C. F. 1895. Variations in the form of the thyroid in man. *J. Anat. and Physiol.*, **29**, 234.

Matsunaga. 1909 and 1910 Die parenchymatösen Lymphbahnen der Thyreoidea und ihre Sekretion. *Arch. Anat. Physiol. Anat. Abt.*, 339; *ibid.*, 28.

Maurer, F. 1888. Schilddrüse Thymus und Keimenreste der Amphibien. *Morph. Jahrb.*, **13**, 246.

——— 1899. Die Schilddrüse, Thymus und andere Schlundspaltenderivate bei der Eideckse. *Ibid.*, **27**, 119.

Morel, B. 1864. *Du goitre et du crétinisme, étiologie, prophylaxis, traitement.* Paris.

Müller, A. 1856. Ein vorlaufiger Bericht über die Entwickelung der Neunaugen. *Arch. f. Anat. u. Physiol., Leipz.*, 323.

Müller, W. 1871. Ueber die Entwicklung der Schilddrüse. *Jenaische Zeitschr. f. Naturw.*, **6**, 354, 428.

Murray, G. R. 1891. Note on the treatment of myxoedema by hypodermic injections of an extract of the thyroid gland of a sheep. *Brit. Med. J.*, **2**, 798.

Norris, E. H. 1916. The morphogenesis of the follicles in the human thyroid gland. *Am. J. Anat.*, **20**, 411.

Oswald, A. 1897. Ueber den Jodgehalt der Schilddrüse. *Zeitschr. f. Physiol. Chem.*, **23**, 265.

——— 1901. Zur Kenntniss des Thyreoglobulins. *Ibid.*, **32**, 121.

——— 1915. Die Beziehungen der Schilddrüse zum Blutkreislauf und zu dessen Nervenapparat. *Zentralbl. f. Physiol.*, **30**, 509.

Pick, E. P., and Pineles, F. 1910. Untersuchungen über die physiologisch wirksame Substanz der Schilddrüse. *Zeitschr. f. Exper. Path. u. Therap.*, **7**, 518.

Remak, R. 1855. *Untersuchungen über die Entwickelung der Wirbelthiere.* Berlin. Monograph.

Reverdin, J. L., and Reverdin, A. 1883. Note sur vingt-deux opérations de goitre. *Rev. méd. d. la suisse Rom., Genève*, **3**, 169, 233, 309, 413.

Rhinehart, D. A. 1912. The nerves of the thyroid and parathyroid bodies. *Am. J. Anat.*, **13**, 91.

Ribbert, H. 1889. Ueber die Regeneration des Schilddrüsengewebes. *Virchow's Archiv.* **117**, 151.

Rogoff, J. M., and Goldblatt, H. 1921. Attempt to detect thyroid secretion in blood obtained from the glands of individuals with exophthalmic goiter and other conditions involving the thyroid. *J. Pharm. Exper. Therap.*, **17**, 473.

Rogowitch, N. 1889. Die Veränderungen der Hypophyse nach Entfernung des Schilddrüse. *Ziegler's Beitrag. z. path. Anat.*, **4**, 453.

Schmidt, M. B. 1894. Ueber Zellknospen in den Arterien der Schilddrüse. *Virchow's Archiv*, **137**, 330.

Seecof, D. P. 1925. Studies on mitochondria. I. *Am. J. Path.*, **1**, 295.

Simmonds, M. 1913. Ueber lymphatische Herde in der Schilddrüse. *Virchow's Archiv*, **211**, 73.

Simpson, S., and Hunter, A. 1910. The possible vicarious relationship between the pituitary and thyroid glands. *Quart. J. Exper. Physiol.*, **3**, 121.

Smith, P. E. 1916. The effect of hypophysectomy in the early embryo upon the growth and development of the frog. *Anat. Record*, **11**, 57.

Smith, P. E., and Smith, I. P. 1922. The repair and activation of the thyroid in the hypophysectomized tadpole by the parenteral administration of fresh anterior lobe of the bovine hypophysis. *J. Med. Res.*, **43**, 267.

Stieda, L. 1881. *Untersuchungen über die Entwickelung der Glandula thymus, Glandula thyroidea und Glandula carotica.* Leipzig. Thesis. 38 pp.

Streckeisen, A. 1886. Beiträge zur Morphologie der Schilddrüse. *Virchow's Archiv*, **103**, 131, 215.

Torrey, H. B., and Horning, B. 1922. Hen-feathering induced in the male fowl by feeding thyroid. *Proc. Soc. Exp. Biol. and Med.*, **19**, 275.

Uhlenhuth, E. 1923. The elaboration and release of the colloid of the thyroid. *Proc. Soc. Exp. Biol. and Med.*, **20**, 494.

——— 1924. The function of the Bensley cell in the thyroid of the salamander, amblystoma opacum. *Anat. Record*, **27**, 223.

——— 1925. Die Kolloidzelle und ihre Funktion in der Schilddrüse des Marmorsalamanders. *Zeit. f. wiss. Zool.*, **125**, 483.

Underhill, F. P., and Hilditch, W. W. 1910. Certain aspects of carbohydrate metabolism in relation to the complete removal of the thyroids and partial parathyroidectomy. *Am. J. Physiol.*, **25**, 66.

Virchow, R. 1863. *Die krankhaften Geschwülste.* Berlin, **3**, 4.

Wagner, J. 1884. Ueber die Folgen der Extirpation der Schilddrüse nach Versuchen an Thieren. *Wien. med. Blätter*, **7**, 771.

Wegelin, C. 1910. Ueber das Stroma der normalen und pathologischen Schilddrüse. *Frankfurt. Zeitschr. Path.*, **4**, 147.

——— 1925. Zur Kenntnis der Kachexia thyreopriva. *Virchow's Archiv*, **254**, 689.

Wharton, T. 1659. *Adenographia: sive glandularum totius corporis descriptio.* Amstelaedamii. P. 107.

Whipple, G. H., and Christman, P. W. 1914. Liver function as influenced by the ductless glands. *J. Exper. Med.*, **20**, 297.

Williamson, G. S., and Pearse, I. H. 1923. The structure of the thyroid organ in man. *J. Path. and Bact.*, **26**, 459.

——— 1926. A reticle of endothelial cells in the thyroid and parathyroid. *Ibid.*, **29**, 167.

Wölfer, A. 1880. *Ueber die Entwickelung und den Bau der Schilddrüse mit Rücksicht auf die Entwickelung der Kröpfe.* Berlin. Monograph.

Wölfer, A. 1883. Ueber die Entwickelung u. den Bau des Kropfes. *Arch. f. Klin. Chir.*, 29, 1, 754.

Zwemer, R. L. 1925. A thyroid-adrenal interrelationship. *Proc. Soc. Exp. Biol. and Med.*, 23, 31.

II. THE PARATHYROID GLANDS

The glandulae parathyroideae were first recognized as independent structures and named by Sandström (1880). As the name implies, he thought these bodies were embryonic thyroid rests. Undoubtedly Owen (1862) saw them in the rhinoceros, Virchow (1863) in man, Baber (1881) in dogs (with excellent drawings), and many others had seen these bodies but either paid no attention to them or considered them as lymph glands or as accessory thyroids. Kohn (1895, 1896) made a very complete anatomical study of these glands in mammals (dog, cat and rabbit) and designated them "Epithelkörperchen" after Maurer (1887) who had described similar bodies in frogs, in order further to separate them from the thyroid which the terms "parathyroid" and "Nebenschilddrüse" suggest. Kohn was the first important contributor to oppose vigorously the view that the parathyroids were thyroid rests, and strongly supported the view that they were independent structures.

This unfortunate early association of the parathyroids and the thyroid has persisted and the term "parathyroid" has become permanent in English and French biological literature. During the development of our knowledge, especially of their embryology, many confusing terms have been used to designate these glands. Thus Prenant (1896) called them "glandules thymiques"; Gley (1891), "glandules thyreoidiennes;" Groschuff (1900), "parathymus III and IV," and Herrmann and Verdun (1899), "glandules branchiales." The suggested relation with the thyroid that this term implies also influenced most of the earlier studies on their function, and Gley (1891), who first showed definitely that the symptoms resulting from thyroidectomy alone in the rabbit are entirely different from those following thyroidectomy which included the III parathyroids, considered them as accessory thyroids. A great deal of the work, both on the anatomy and physiology, of these bodies down to 1910 assumed that the thyroid and parathyroids were closely related organs although Vassale and Generali (1896) clearly showed in dogs and cats that parathyroidectomy without thyroidectomy caused fatal tetany, while if one parathyroid remained functionally active tetany did not occur.

1. *Embryology* (*Fig. 248*):

The parathyroids arise as paired structures from the entoderm of the III and IV branchial clefts and in close association with the corresponding embryological anlagen of the thymus gland (Kürsteiner, 1899).

The IV parathyroids remain in close association with the IV thymus, and are often seen embedded in the thyroid lobes in those animals in which the IV thymus persists (cat). Also in addition there are almost always in cats and frequently in the rabbit and dog cystic spaces, epithelial cords or duct remnants lined with ciliated epithelium. These masses are the remnants of the ductus pharyngo-branchialis communis and the postbranchial bodies. In man, the persistence of duct remnants, or a IV thymus, or the inclusion of the IV parathyroid in the thyroid is exceedingly rare, but as Getzowa (1907) has shown, remnants of the postbranchial body may be found in man occasionally in close association with the IV parathyroid. The III parathyroid in man becomes separated from the III thymus as this organ migrates caudally in its development, although it always retains a close anatomical connection with the cervical portion of the III thymus in those animals, in which the cervical thymus persists (ox, sheep, pig).

2. *Comparative anatomy:*

While the association of the parathyroids with the thymus is a more fundamental one, certainly on the basis of embryology and possibly physiology as well, than with the thyroid, their topographical relations to the thyroid are of more practical value and descriptions regarding their location since the time of Sandstroem are usually phrased in reference to the thyroid. Thus the III parathyroids are referred to as superior (in carnivora generally), as external and as inferior (in herbivora generally and in man) and as anterior.

The IV parathyroids are similarly referred to as internal or posterior. Kohn (1895) used the term "external" to mean on the surface of the lateral lobes of the thyroid and "internal" to mean within the thyroid. These terms are confusing and have lost much of their significance because of the great variation in the position of these glands in the different species and the considerable variation in any given species. It is frequently impossible to demonstrate the theoretical four parathyroids in man and in animals, even after one has had great experience in searching for them. Von Verebély (1907) reported finding four parathyroids in 108 out of 138 dissections. This would indicate that frequently one or more parathyroids are congenitally absent or fail to develop to recognizable size. Complete aplasia, however, has never been proved, possibly because it is incompatible with life, even during the fetal period.

Accessory parathyroids are of frequent occurrence in all mammals in which extensive search for them has been made. They appear more frequent and in larger numbers in herbivora (rabbit, sheep and ox). The occurrence of accessory parathyroids is to be expected from the fact that these bodies arise from four different embryological sites and that the branchial cleft region undergoes such great structural changes during development that

small fragments of the parathyroid anlagen could readily be broken off as these are dragged around during development. Haberfeld and Schilder (1909) were able to demonstrate accessory parathyroids in all rabbit thymuses examined. Shapiro and Jaffe (1923) demonstrated them in 12 per cent of the cats merely by the examination of a single routine histological section taken from the thymus area. Nicolas and Swingle (1925) found them in 35 per cent of the cats examined by them, and Farner and Klinger (1920), by resorting to serial sections of the upper thymus area, demonstrated accessory parathyroids in nearly all the cats they examined. The most common sites for accessory parathyroids are (1) in the upper portion of the thymus, (2) in or about the thyroid lobes and (3) in the intervening tissue between the thyroid and thymus, laterally to the carotid trunks and posteriorly to the phrenic nerves (Askanazy, 1911). The frequency of accessory parathyroids accounts in large part for the widely different results obtained from parathyroid extirpation. Probably most of the accessory parathyroids, and in particular those lying in the interlobular septa of the thymus, arise from the third anlage and represent fragments separated from the main mass in its caudal migration.

Parathyroids have been recognized in all animals down to the fishes. In certain Elasmobranchs Thompson (1910) described cell rests in the thyroid gland which he believed might be homologous with the parathyroids of higher animals. In birds there are regularly two parathyroids on each side, immediately adjacent to each other, and usually situated below the lower pole of the thyroid lobes. In man the III parathyroids usually lie posterior to and often somewhat below the lower poles of the lateral thyroid lobes, and nearly always within a radius of 1 cm. of the lower poles of the thyroid. In enlarged thyroids they are passively drawn closer to the thyroid and in large goiterous glands they may be markedly elongated (to as much as 20 mm.) and flattened against the convex lower border of the lateral lobes to which they may become adherent, making it difficult to enucleate the thyroid lobes without injuring them.

3. *General morphology:*

The IV parathyroids are most frequently located on the posterior lateral angle of the thyroid lobes about the junction of the upper and middle thirds and usually lie in a small groove or depression formed by the entrance of a radicle of the inferior thyroid artery. Rarely in man are the IV parathyroids actually embedded in the thyroid, although this usually occurs in the cat, rabbit and frequently in the dog. The III parathyroids are usually larger, often as much as twice as large as the IV parathyroids.

Their weights vary greatly. The average for the IV parathyroids is around 0.020 gm. and for the III 0.035 gm. The shape of these bodies also varies greatly. When free from pressure effects they are slightly flattened, oval bodies of soft consistence and measure

on the average 6 to 7 mm. in length, 3 to 4 mm. in breadth, and 1.5 to 2 mm. in thickness. They vary in color in man from a light yellowish red to golden brown red to brown red. The writer has gained the impression that the color tends to darken somewhat with age and that there is a vague parallelism in the degree of pigmentation of the thyroid and parathyroid. In carnivora the color is pearly white or faintly yellow. The color is largely due to the interlobular fat and intracellular lipoids, though Erdheim (1903) has demonstrated hemosiderin pigment in the parathyroids of infantile tetany in which condition capillary hemorrhages into the parathyroids are said to be frequently found.

4. Blood supply:

The parathyroid glands have a very large blood supply derived from primary and secondary branches of the inferior thyroid artery (Halsted and Evans, 1907). The IV parathyroid is occasionally supplied by a branch arising from an anastomosing trunk of the inferior and superior thyroid arteries. The artery enters the gland at the hilus and immediately divides into numerous branches which run in the septa. In microscopic sections of the gland these branches are large and out of proportion to the size of the gland. The columns of gland cells are supplied with a very rich network of wide sinus-like capillaries whose endothelium comes in direct contact with all the gland cells. The main vein leaves the gland at the hilus but has no constant further course. Sometimes it empties into the thyroid, tracheal or esophageal branches. One of the most striking gross characteristics of the human and herbivorous parathyroid is the anastomosing network of large sinus-like collecting veins beneath the capsule.

5. Innervation:

According to Rhinehart (1912) the parathyroids are very scantily supplied with nerve fibers, and it is his opinion that all of the fibers present could be accounted for as vasomotors. These nerves are all non-medullated and enter with the artery around the branches of which the fibers form a thin perivascular plexus. The smallest arteries appear to have only a single nerve twig. A few fibers seem to run in the connective tissue between the cell columns but none of these leaves the connective tissue and penetrates into the cell groups. The nerves to the parathyroids are supplied from the same cervical sympathetic group that supplies the thyroid gland.

6. Classification into types (Figs. 261 to 263):

Morphologically it has been customary to divide the parathyroids into three groups first suggested by Welsh (1898): (1) the compact uniform type, (2) the anastomosing strand or column type and (3) the lobular type. The gland in man and in the herbivora is usually of the compact type in early life and tends to become lobular in old age. In the parathyroid of adults not infrequently one sees all three types in the same gland, but the most characteristic type of young adults is the anastomosing strand type. In dogs the

anastomosing strand arrangement remains throughout life, while in cats the gland is more of the compact uniform type. The variable and changing arrangement of the cells is probably due to the stroma which becomes more prominent with old age. In very early life the supporting stroma which is derived from fine connective tissue strands extending in from the capsule forms a delicate uniform reticulum except for the relatively huge arterial trunks. This is seen in the compact uniform arrangement of the cell of infants' parathyroids. Later the stroma becomes septa-like and gives the gland the anastomosing strand appearance characteristic of young adults and still later in life as the stroma bands become more prominent and the oxyphil groups more numerous the gland takes on a definite lobulated appearance. The stroma contains elastic fibers and a few smooth muscle fibers. Scattered throughout the stroma but in particular in the hilus are cells described as mast cells (by Getzowa, 1907, Bergstrand, 1919 and others), but which of late have been recognized as reticulo-endothelial cells homologous with similar cells in the thyroid, thymus, liver and other organs. These cells contain large granules which stain readily with acid fuchsin.

7. *Secretory epithelium:*

The parenchyma is made up of closely packed, relatively large cells. Two types of cells, and according to some authors three types, may be recognized; first, chief cells, second, small dark chief cells (Petersen, 1903, Getzowa, 1907 and Noodt, 1922) and third, large, bright oxyphilic cells (Welsh, 1898).

The *clear chief cells* appear to be the essential type. They represent the only type present in man up to the tenth year of life on the average, and in some species, as in the dog, cat and guinea pig, they are the only type present throughout life. The chief cells have clear, almost unstaining, plant-like, non-granular protoplasm with relatively large, pale vesicular nuclei which are often not in the center of the cell.

The *oxyphil cells* usually begin to appear in late childhood (as early as the seventh year). These cells are much larger than the chief cells, occur singly or in groups and are characterized by large amounts of granular protoplasm which stain intensely with acid dyes. The nucleus is much smaller than in the chief cells and the chromatin filaments are closely packed and deeply staining.

The *dark chief cells* are at best only a subgroup of the chief cells and in appearance they are intermediate between the clear chief cells and the oxyphil cells. Their protoplasm is very finely granular and stains faintly with acid dyes. The nucleus is somewhat smaller and less vesicular than that of the clear chief cells. These so-called chief cells are present much earlier in life (even in infants) than the large oxyphil cells, which suggests that they are possibly the early stages of the large oxyphil cells. However,

the parathyroids of dogs, cats, rats and other animals have cells comparable to these dark chief cells but never have the large oxyphil cells of Welsh.

We have no knowledge of any differences in function corresponding with these anatomical differences. The fact that in infancy only clear chief cells or dark chief cells are present, that oxyphil cells are present only in certain species of animals and that these constantly increase in man from about the tenth year of life to old age would indicate that oxyphil cells are not essential elements for the functional activity of the gland. The prevailing opinion at present is that the dark chief cells and the oxyphil cells indicate different stages of secretory activity, and that the oxyphil cells are the ripened and mature cells which ultimately undergo degenerative changes and disappear. The groups of fat cells which are seen in the parathyroids of animals in which oxyphil cells occur, may occupy the spaces formerly containing the oxyphil cells. On the other hand, Koopman (1921) believes the oxyphil cells are morphologically similar and of corresponding functional significance to the oxyphil cells of the islands of Langerhans and of the anterior hypophysis.

Both the oxyphil and the chief cells contain mitochondria. Courrier and Reiss (1922) thought the Golgi apparatus was located toward the pole opposite to the attachment of the cell at its basement membrane and interpreted this as indicating secretory polarity. Cowdry (1922), on the other hand, found great variations in the cytoplasmic location of the Golgi apparatus. Bobeau (1911) has described the occurrence of neutral fat and what he believed to be lipoid granules and in addition granules which he interpreted as secretion granules. Cowdry has reviewed this work and concludes that nothing indicating the mode of secretion of the parathyroid cell has so far been demonstrated. Glycogen is usually present in both the chief cells and oxyphil cells, occurring in large quantities in the former and in very small quantities in the latter. According to Noodt (1922) glycogen may be absent from the oxyphil cells. The glycogen content appears to be independent of age, sex and disease and is unusually resistant to destruction. Neutral fat occurs both within the cells and as clusters of fat cells in the stroma.

Colloid is frequently seen in the parathyroids of adults. It usually occurs in follicles but is occasionally seen in the stroma. Follicle formation in the parathyroid increases with age just as in the case of the anterior pituitary and suprarenal cortex. The colloid histologically is a homogeneous protein mass taking acid dyes and morphologically resembles that present in the thyroid and pituitary. It is well known, however, that any albuminous material in closed cavities may assume the appearance of colloid. No chemical examinations of the parathyroid colloid are available. The appearance of colloid-containing follicles was cited by older workers in further support

of the view that the parathyroids were functionally closely related to the thyroid. Studies of the parathyroids in myxedema (Erdheim, 1903; Getzowa, 1907) have disproved this suggestion.

So also the early literature contains several references to the presence of iodine in significant amounts in the parathyroids, and certain workers assumed that the iodine was contained in the colloid of the follicles just as in the case of the thyroid. Subsequent work (Estes and Cecil, 1907), however, has shown that parathyroids which are not contaminated with thyroid do not contain iodine in any greater concentration than that of the body tissues in general exclusive of the thyroid. The presence of colloid in the parathyroids is best considered either as a degenerative process or as a stasis of an albuminous material in the spaces formed by the differentiation of the columns of cells into follicles. Vincent and Jolly (1905) pointed out that differentiation into follicles may be increased during compensatory hypertrophy in dogs.

Finally it may be pointed out that the parathyroids are highly resistant to post-mortem changes and to putrefaction. The writer has seen parathyroids of dogs with well-preserved histological details after being kept in a hay infusion for six days, while the thyroid tissue subjected to the same treatment is histologically unrecognizable. Cristiani (1905) also emphasized the extraordinary resistance of parathyroid cells of the rat to the injurious effects of various fluids (heterologous sera, hypo- and hypertonic salt solutions) in connection with his work on thyroid and parathyroid transplantation.

8. *Physiology:*

Effects of Extirpation. Removal of the parathyroids in all species of animals in which it has been done leads to a fatal symptom-complex characterized by hyperexcitability of the nerves, beginning in from twenty-four to seventy-two hours, which goes on to tonic and clonic spasms of the muscles. Under certain conditions of nutrition the tetany may begin in dogs within four hours and end fatally in seven hours after parathyroidectomy (Marine, 1914). Tetany develops earlier in rabbits and is more rapidly fatal than in the dog and cat. In cats particularly and to some extent in other animals there are two distinct clinical manifestations of parathyroidectomy: (1) a typical tetany with tachycardia, tachypnea and muscle twitchings, and (2) a slowly progressing lethargy and coma. This symptom-complex is called parathyroid tetany.

Other forms of tetany are: (1) infantile, associated with rickets; (2) gastric, associated with chronic pyloric stenosis and believed to be due to loss of HCl through vomiting (MacCallum, 1920; McCann 1918); (3) hyperpnea tetany (Grant and Goldman, 1920), due to alkalosis; (4) tetany due to intravenous injection of sodium bicarbonate (Harrop, 1919) and alkaline sodium phosphate (Binger, 1918); (5) tetany of pregnancy and lacta-

tion; (6) tetany-like symptoms due to poisoning with guanidine and methyl guanidine (Paton and Findlay, 1916), and (7) tetany due to overfeeding rats with desiccated thyroid (Cameron and Carmichael, 1922). These forms of tetany differ markedly, both from parathyroid tetany and from each other, and with the exception of tetany of pregnancy and lactation, there is as yet no proof that they are directly related to parathyroid insufficiency. It is possible, however, that although these several clinical types of tetany appear to differ radically in their etiology, the final changes in the blood and tissues which bring about the symptoms may be due to a lack of the parathyroid hormone (MacCallum, 1924).

Parathyro-priva tetany is the best understood form of tetany, and its relation to the parathyroids is now beyond dispute. This relationship has been arrived at after much dispute. Much of the conflicting evidence without doubt has been due to the fact that under favorable conditions of nutrition extremely small fragments of parathyroid or accessory parathyroids are sufficient to prevent tetany, while under unfavorable conditions typical parathyroid tetany may develop with all parathyroids intact and microscopically even hyperplastic, as occurs in spontaneous tetanies of pregnancy and lactation. Parathyroid tetany is more violent and more rapidly fatal in young animals, and high protein diets also hasten the onset of symptoms.

9. *Blood chemistry of tetany:*

MacCallum and Voegtlin (1909) definitely associated the symptoms of parathyroid tetany with a decrease in the blood and tissue calcium. The calcium of the blood serum may be reduced 50 per cent. These authors also demonstrated that intravenous, oral or parenteral administration of soluble calcium salts restored the blood calcium level and temporarily relieved the tetany. Dogs may be kept alive and free from tetany for weeks by the daily administration of calcium. Luckhardt and Goldberg (1923), Dragstedt and Peacock (1923) and others believe that completely parathyroidectomized dogs may be kept alive indefinitely on a low protein diet and calcium. The evidence is not convincing and the writer believes that in the total absence of parathyroids life cannot be indefinitely prolonged by calcium and that the 50 per cent of survivals is explained by the presence of accessory parathyroids and by the calcium tiding the animal over until compensation or adjustment to low blood calcium levels is brought about. Such animals are, however, always more susceptible to tetany and may be said to be in a state of latent tetany. Greenwald (1911) showed that there was a phosphorus retention in dogs after parathyroidectomy, and Collip (1926) has shown that phosphorus retention is even more marked in parathyroidectomized rabbits. Salts of strontium and magnesium also relieve to a slight extent the symptoms of parathyroid tetany, but the action of magnesium is largely accounted for by its depressant and anesthetic effect.

While the experiments of MacCallum and his associates seemed definitely to associate the hyperexcitability of the nervous system with lowered blood calcium and these views were in addition supported by the basic physiological observations of J. Loeb (1901) that injections of salts which precipitate calcium cause muscular twitching, nevertheless, the old view that tetany was due to the accumulation of toxins in the blood which the parathyroids normally neutralize was not disposed of. This so-called antitoxic theory at one time or another has also been proposed to explain the function of the thyroid, suprarenal and other glands of internal secretion. The toxic theory was supported by the obser-

vations of F. C. Koch (1912) who demonstrated the presence of methyl guanidine in the urine of parathyroidectomized dogs. Paton and his co-workers extended this observation by showing that injections of guanidine and of methyl guanidine produce symptoms closely resembling parathyroid tetany. While it is claimed by some that guanidine lowers the blood calcium, it is denied by others. Certainly the administration of calcium does not relieve the symptoms of guanidine poisoning as it regularly does in parathyroid tetany. The recent work of Henderson (1919), Greenwald (1924), Collip and Clark (1926) and others seems clearly to establish that the production of guanidine is a secondary metabolic disturbance and has no essential relationship to parathyroid tetany.

The causal relation of the lowering of the blood calcium to tetany has recently been further supported by the work of Collip (1925) who in 1924 prepared an extract of a protein nature (parathyrin) from ox parathyroids, which when injected intravenously into normal or parathyroidectomized dogs markedly raises the blood calcium. It relieves all the symptoms of tetany, and parathyroidectomized dogs may be kept alive for months with the daily injection of this material. Subsequent work by Collip has shown that the rise in blood calcium is proportional to the amount of extract injected, and both normal and parathyroidectomized dogs may be killed by excessive doses of it, which raises the blood calcium from a normal level of 9 to 10 mgms. to over 20 mgms. per 100 c.c. of blood.

It has long been recognized that the excretion of calcium, while increased in tetany, does not parallel the fall in the blood calcium, and Greenwald has definitely shown that the blood phosphorus rises markedly and its excretion is decreased during tetany. Collip has recently confirmed this for dogs and in addition has shown that in parathyroidectomized rabbits a much greater rise in blood phosphorus occurs during tetany. It is well known that calcium is ineffective in relieving the tetany of rabbits, and Collip has shown that injections of both calcium and parathyroid extract fail to raise the blood calcium of rabbits in parathyroid tetany. These facts add further support to Greenwald's view that the rise in phosphorus may be as important in the pathogenesis of tetany as the fall in blood calcium.

As Collip (1926) has shown, the parathyroid hormone acts as a mobilizer of calcium, and one of the essential functions of the parathyroid secretion is in regulating the concentration of calcium ions in the blood. Greenwald (1926) has suggested that the hormone effects this regulation by preventing calcium precipitation. Much remains to be done on the partition of calcium in the blood and the relation of calcium and phosphorus metabolism before a comprehensive view of their relation to parathyroid function is established.

10. *Regeneration and hypertrophy:*

Parathyroid tissue, in sharp contrast with the thyroid or thymus, has slight regenerative capacity. Even after removal of three parathyroids in dogs, cats or rabbits, the remaining gland may undergo no obvious enlargement, yet the animals remain in good health. On the other hand, young animals maintained on a low calcium diet show definite hypertrophy of the parathyroids without partial removal. Similar slight enlargement of the parathyroids may be seen in pregnancy and lactation tetany. In birds (Marine, 1914) hypertrophy is more readily produced. Inadequate diets and the daily administration of mineral acids, like hydrochloric, with a ration of crushed corn and liver, regularly lead to moderate hypertrophy in fowls, the two parathyroids often being larger than the attached thyroid

lobe. Erdheim (1914) observed enlargement of the rat parathyroids in experimental rickets, and Pappenheimer and Minor (1921) have recorded similar observations in human rickets. They believe that in human rickets there is actual hyperplasia, and they find, as others have found, that the type of cell remains unaltered during the hypertrophy and hyperplasia. Enlargement of the parathyroids in birds and rats on inadequate diets may, however, be of the same nature and significance as enlargement of the suprarenal gland in starvation, and not necessarily due to disturbances in calcium and phosphorus metabolism.

Hyperplasia of the parathyroids is seen in other diseases than rickets, particularly those associated with injury to or impairment of ossification and in chronic nephritis. Klemperer (1923) noted hypertrophy of the parathyroids associated with extensive bone metastases in a case of carcinoma of the breast. Erdheim (1907), Kerl (1925) and many others have reported enlargement of the parathyroids with adenoma-like formations in cases of osteomalacia and osteoporosis. Hypertrophy of the III (external) parathyroids of rabbits was observed by Grant and Gates (1924) following exposure to ultraviolet rays. Adenomas or adenoma-like hyperplasia (MacCallum, 1905) of one or more parathyroids (usually the III) are not uncommon, either independently or peculiarly associated with chronic nephritis (Barker, 1922), and instances of carcinoma have been recorded.

The parathyroids have been associated with the pathology of a number of other diseases, among which may be mentioned paralysis agitans (Lundborg, 1904; Berkeley, 1905), epilepsy, myasthenia gravis (Chvostek, 1908), Graves' disease, pellagra, scleroderma and eclampsia (Vassale, 1906). There is no evidence that the parathyroids are principally involved in any of the diseases.

11. *Transplantation:*

Autotransplantation of the parathyroids is easily accomplished in all ordinary laboratory animals. Parathyroids may be transplanted in any part of the body and proof of the function of such transplants has been furnished by Leischner (1907) and Halsted (1909). Homeotransplants are usually unsuccessful in the dog, cat and rabbit, although recently Cristiani (1925) has reported successful homeografts in the rat. The view of Halsted (1909) that it was necessary to create a parathyroid insufficiency before autografts would take is incorrect. Manley and Marine (1916) obtained many accidental transplants of the IV parathyroid in the subcutaneous tissue of rabbits in transplanting bits of the thyroid lobe where both III parathyroids and at least one of the IV parathyroids were intact. So also we accidently obtained two parathyroid transplants in transplanting the thymus of thirty rabbits.

12. *Interrelations:*

No definite interrelationship with other glands of internal secretion has been established for the parathyroids. The idea that the parathyroids could function vicariously for the thyroid was intentionally implied in the names selected for these structures by Sandström (1880) and Gley (1891). Vincent and Jolly (1905) believed that not only did the parathyroids function vicariously for the thyroid but that in doing so they assumed the morphology of the thyroid. The work, especially of Kohn, MacCallum and Collip, has entirely disproved these views and rendered it impossible that any close relationships will be found. The lowered alimentary tolerance for sugar and a hypersentiveness to epinephrin after parathyroidectomy constitute the most suggestive evidence available. On embryological grounds the most likely interrelationship would appear to be with the thymus, and papers are constantly appearing in the literature suggesting some relation of the thymus to osteogenesis and calcium metabolism.

BIBLIOGRAPHY (PARATHYROIDS)

Askanazy, M. 1911. Ein Epithelkörperchen in Nervus phrenicus. *Cent. allg. Path. u. path. Anat.*, **22**, 1034.

Baber, E. C. 1881. Researches on the minute structure of the thyroid gland. *Phil. Trans.* (Lond.), **172**, 577.

Barker, L. F. 1922. Clinical syndrome due to disorders of the parathyroid glands. In *Endocrinology and Metabolism*. New York: D. Appleton and Co. **1**, 577.

Bergstrand, H. 1919. Parathyreodeastudien, 1. Zur normalen Anatomie der Glandula parathyreoidea. *Acta Med. Scandinav.*, **52**, 791.

Berkeley, W. M. 1905. Is paralysis agitans caused by defective secretion or atrophy of the thyroid glandules? *Med. News*, **87**, 1060.

Binger, C. 1918. Toxicity of phosphates, in relation to blood calcium and tetany. *J. Pharm. and Exper. Therap.*, **10**, 105.

Bobeau, G. 1911. Recherches cytologiques sur les glandules parathyroïdes du cheval. *J. d. l'anat. et physiol.*, **47**, 371.

Cameron, A. T., and Carmichael, J. 1922. The comparative effects of parathyroid and thyroid feeding on growth and organ hypertrophy in the white rat. *Am. J. Physiol.*, **58**, 1.

Chvostek, F. 1908. Myasthenia gravis und Epithelkörper. *Wien. klin. Woch.*, **21**, 37.

Collip, J. B. 1925. The extraction of a parathyroid hormone which will prevent or control parathyroid tetany and which regulates the level of blood calcium. *J. Biol. Chem.*, **63**, 395.

——— 1926*a*. A study of parathyroidectomized rabbits. *Proc. Am. Physiol. Soc., Am. J. Physiol.*, **76**, 219.

——— 1926*b*. The parathyroid glands. *Medicine*, **5**, 1.

Collip, J. B., and **Clark, E. P.** 1926. Concerning the relation of guanidine to parathyroid tetany. *J. Biol. Chem.*, **67**, 679.

Courrier, R., and Reiss, P. 1922. Appareil réticulé de Golgi et polarité sécrétoire des cellules parathyroïdiennes. *Compt. rend. Soc. d. Biol.*, **86**, 867.

Cowdry, E. V. 1922. Anatomy, embryology, comparative anatomy and histology of the parathyroid. In *Endocrinology and Metabolism.* New York: D. Appleton and Co. **1**, 501.

Cristiani, H. 1905. De la persistance des greffes des glandes parathyroïdes. *Compt. rend. Soc. de Biol.*, **58**, 754.

Cristiani, H., and Cristiani, A. 1925. Reussite et persistance des homogreffes de la glande parathyroïde. *Ibid.*, **92**, 1278.

Dragstedt, L. R., and Peacock, S. C. 1923. Studies on the pathogenesis of tetany. I. *Am. J. Physiol.*, **64**, 424.

Erdheim, J. 1903. Zur normalen und pathologischen Histologie der Glandula thyreoidea, parathyreoidea und Hypophysis. *Beitr. z. path. Anat. u. z. allg. Path.*, **33**, 158.

——— 1907. Ueber Epithelkörperbefunde bei Osteomalacie. *Sitzungsber. d. k. Akad. Wiss.*, **116**, 311.

——— 1914. *Rachitis und Epithelkörperchen.* Wien. 321 pp. (Monograph.)

Estes, W. L., and Cecil, A. B. 1907. The relation of iodine to the parathyroid. *Johns Hopkins Hosp. Bull.*, **18**, 331.

Farner, E., and Klinger, R. 1920. Experimentelle Studien über Tetanie. II. *Mitt. a. Grenzgeb. der Med. u. Chir.*, **32**, 469.

Getzowa, S. 1907. Ueber die Glandula parathyreoidea, intrathyreoideale Zellhaufen derselben und Reste des postbranchialen Körpers. *Virchow's Archiv*, **188**, 181.

Gley, E. 1891. Sur les fonctions de la glande thyroïde chez le lapin et chez le chien. *Compt. rend. Soc. de biol.*, **43**, 843.

Grant, J. H. B., and Gates, F. L. 1924. The effect on the external parathyroid glands of the exposure of rabbits to ultra-violet light. *J. Gen. Physiol.*, **6**, 635.

Grant, S. B., and Goldman, A. 1920. A study of forced respiration: experimental production of tetany. *Am. J. Physiol.*, **52**, 209.

Greenwald, I. 1911. The effect of parathyroidectomy upon metabolism. *Ibid.*, **28**, 103.

——— 1924. Are guanidines present in the urines of parathyroidectomized dogs? *J. Biol. Chem.*, **59**, 329.

——— 1926. The effect of the administration of calcium salts and of sodium phosphate upon the calcium and phosphorus metabolism of thyroparathyroidectomized dogs, with a consideration of the nature of the calcium compounds of blood and their relation to the pathogenesis of tetany. *J. Biol. Chem.*, **67**, 1.

Groschuff, K. 1900. Ueber das Vorkommen eines Thymussegmentes der vierten Kiementasche beim Menschen. *Anat. Anz.*, **17**, 161.

Haberfeld, W., and Schilder, C. 1909. Die Tetanie der Kaninchen. *Mitt. a. d. Grenzgeb. d. Med. u. Chir.*, **20**, 728.

Halsted, W. S. 1909. Auto- and isotransplantation, in dogs, of the parathyroid glandules. *J. Exper. Med.*, **11**, 175.

Halsted, W. S., and Evans, H. M. 1907. The parathyroid glandules. Their blood supply and their preservation in operation upon the thyroid gland. *Ann. Surg.*, **46**, 489.

Harrop, G. A. 1919. The production of tetany by the intravenous infusion of sodium bicarbonate. *Johns Hopkins Hosp. Bull.*, **30**, 62.

Henderson, P. S. 1919. The guanidin content of muscle in tetania parathyreopriva. *J. Physiol.*, **52**, 1.

Herrmann, G., and Verdun, P. 1899. Remarques sur l'anatomie comparée des corps post-branchiaux. *Compt. rend. Soc. de Biol.*, **51**, 855.

Kerl, F. 1925. Hyperplasia of the parathyroids in osteomalacia and osteoporosis. *Deut. med. Woch.*, **51**, 1271.

Klemperer, P. 1923. Parathyroid hyperplasia and bone destruction in generalized carcinomatosis. *Surg., Gynec. and Obst.*, **36**, 11.

Koch, W. F. 1912. On the occurrence of methyl guanidine in the urine of parathyroidectomized animals. *J. Biol. Chem.*, **12**, 313.

Kohn, A. 1895, 1896. Studien über die Schilddrüse. *Arch. f. mikr. Anat.*, **44**, 366; *ibid.*, **48**, 398.

Koopman, H. 1921. Beitrag zur Epithelkörperchenfrage, unter besonderer Berücksichtigung der Acidophilie der Zelle. *Frank. Zeit. f. Path.*, **25**, 342.

Kürsteiner, W. 1899. Die Epithelkörperchen des Menschen in ihre Beziehung zur Thyroidea und Thymus. *Anat. Hefte*, **11**, 391.

Leischner, H. 1907. Ueber Epithelkörperchen-Transplantationen und deren practische Bedeutung in der Chirurgie. *Arch. f. klin. Chir.*, **84**, 208.

Loeb, J. 1901. On an apparently new form of muscular irritability (contact irritability?) produced by solutions of salts (preferably sodium salts) whose anions are liable to form insoluble calcium compounds. *Am. J. Physiol.*, **5**, 362.

Luckhardt, A. B., and Goldberg, B. 1923. Preservation of the life of completely parathyroidectomized dogs by means of the oral administration of calcium lactate. *J. Am. Med. Assoc.*, **80**, 79.

Lundborg, H. 1904. Spielen die Glandulae parathyreoideae in der menschlichen Pathologie eine Rolle? *Deut. Ztschr. f Nervenh.*, **27**, 217.

MacCallum, W. G. 1905. Tumor of the parathyroid gland. *Johns Hopkins Hosp. Bull.*, **16**, 87.

——— 1924. On the pathogenesis of tetany. *Medicine*, **3**, 137.

MacCallum, W. G., Lintz, J., Vermilye, H. N., Leggett, T. H., and Boas, E. 1920. The effect of pyloric obstruction in relation to gastric tetany. *Johns Hopkins Hosp. Bull.*, **31**, 1.

MacCallum, W. G., and Voegtlin, C. 1909. On the relation of tetany to the parathyroid glands and to calcium metabolism. *J. Exp. Med.*, **11**, 118.

McCann, W. S. 1918. A study of the carbon dioxide-combining power of the blood plasma in experimental tetany. *J. Biol. Chem.*, **35**, 553.

Manley, O. T., and Marine, D. 1916. Transplantation of ductless glands with reference to permanence and function. *J. Amer. Med. Assoc.*, **67**, 260.

Marine, D. 1914*a*. Observations on tetany in dogs. *J. Exper. Med.*, **19**, 89.

——— 1914*b*. Parathyroid hypertrophy and hyperplasia in fowls. *Proc. Soc. Exper. Biol. and Med.*, **11**, 117.

Maurer, F. 1887. Schilddrüse, Thymus und Kiemenreste der Amphibien. *Morphol. Jahrbücher*, **13**, 296.

Nicolas, J. S., and Swingle, W. W. 1925. An experimental and morphological study of the parathyroid glands of the cat. *Am. J. Anat.*, **34**, 469.

Noodt, K. 1922. Zur normalen und pathologischen Histologie der Epithelkörperchen. *Virchow's Archiv*, **238**, 262.

Owen, R. 1862. On "small compact yellow glandular body attached to thyroid" of rhinoceros. *Trans. Zool. Soc., (Lond.)*, **4**, 12.

Pappenheimer, A. M., and Minor, J. 1921. Hyperplasia of the parathyroids in human rickets. *J. Med. Res.*, **42**, 391.

Paton, D. N., and Findlay, L. 1916. The parathyroids: Tetania parathyreopriva: Its nature, cause, and relation to idiopathic tetany. Part IV. The etiology of the condition and its relationship to guanidin and methyl-guanidin intoxication. *Quart. J. Exp. Med.*, **10**, 315.

Petersen, H. 1903. Anatomische Studie über die Glandulae parathyroideae des Menschen. *Virchow's Archiv*, **174**, 413.

Prenant, A. 1896. Sur le développement des glandes accessoires de la glande thyroïde et celui de la glande carotidienne. *Anat. Anz.*, **12**, 242.

Rhinehart, D. A. 1912. The nerves of the thyroid and parathyroid bodies. *Am. J. Anat.*, **13**, 91.

Sandström, I. 1880. Ueber eine neue Drüse beim Menschen und bei verschiedenen Säugethieren. *Upsala läkaref. förh.*, **15**, 441. Reviewed in *Schmidt's Jahrb.*, 1880, **187**, 114.

Shapiro, S., and Jaffe, H. 1923. On the occurrence of accessory parathyroids and their relation to survival of animals after parathyroidectomy. *Endocrinology*, **7**, 720.

Thompson, F. D. 1910. The thyroid and parathyroid glands throughout vertebrates. *Proc. Roy. Soc.*, **82**, 389.

Vassale, G. 1906. Eclampsie gravidique et insuffisance parathyreoïdiennes. *Arch. ital. de Biol.*, **46**, 143.

Vassale, G., and Generali, F. 1896. Sur les effets de l'extirpation des glandes parathyréoïdiennes. *Arch. ital. de biol.*, **26**, 61.

v. Verebély, T. 1907. Beiträge zur Pathologie der branchialen Epithelkörperchen. *Virchow's Archiv*, **187**, 80.

Vincent, S., and Jolly, W. A. 1905. Some observations upon the functions of the thyroid and parathyroid glands. *J. Physiol.*, **32**, 65.

Virchow, R. 1863. *Die krankhaften Geschwülste.* Berlin: Hirschwald. **3**, 13.

Welsh, D. A. 1898. Concerning the parathyroid glands; a critical, anatomical, and experimental study. *J. Anat. and Physiol.*, **32**, 293, 380.

III. THE THYMUS

The thymus is still the "enigmatic organ." It is the least understood of all the so-called glands of internal secretion. Contentions and controversies involve most of the questions regarding its anatomy (embryology and histology), physiology and pathology. No attribute of sufficient magnitude to prove or disprove that the thymus is an independent gland has as yet been discovered.

1. *Embryology (Fig. 248):*

The thymus of mammals arises as paired structures from the entoderm (in some instances -the mole and guinea pig -also from the ectoderm) of the third and fourth branchial clefts. In fishes, amphibians, reptiles and birds thymic tissue may also arise from the second and fifth branchial clefts. In most mammals the thymus IV is a rudimentary and transitory structure, although in some animals, notably the cat, there is always developed a thymus IV which remains in close connection with the parathyroid IV, together with duct-like remnants of the ductus pharyngobranchialis communis and the postbranchial body. From analogy with the thyroid one must bear in mind the possibility that under the strain of functional necessity in early embryonic life thymus tissue arising from the fourth branchial cleft may persist more frequently than would occur under normal conditions. All embryologists are in agreement that the major portion of the vertebrate thymus arises from the entodermal epithelium of the medial and ventral portion of the third branchial cleft. Whether in some

mammals, like the mole and guinea pig, the thymus is purely ectodermal and in others, like the pig, partially ectodermal, is still debated.

The III thymus anlage grows out first as a thick-walled cylinder. This elongates and thickens towards its free end and soon loses its lumen to become the body of the thymus. The parathyroid III is still closely associated with the upper end of the thymus and both normally lose their connection with the branchial clefts as these undergo absorption, but in some animals, notably the dog, cat and occasionally in man, cystic remnants of the branchial clefts may remain throughout life. (These will be referred to later.) Both the parathyroid III and the thymus migrate caudally, the parathyroid III usually becoming separated from the thymus III and its descent arrested near the lower pole of the thyroid. It is probable that the accessory parathyroids, the so-called accessory system of Pepere (1908), which are so frequently found in the upper portion of the mammalian thymus arise from fragments of the parathyroid that have become separated during this migration. The head of the thymus in most mammals undergoes absorption, but if this does not occur, a thymus lobule persists in association with the parathyroid III, as normally occurs in the ox, sheep and pig.

The body of the thymus on each side usually migrates caudally in front of the left innominate vein and reaches the pericardium in human embryos of 12 to 19 mm. The two lobes of the thymus come in close contact with each other medially but never actually fuse (Hammar, 1910).

The epithelial character of the thymus is plainly evident until the end of the second month of uterine life. At this stage the cells of the central portion of the thymus anlage thin out, become more loosely arranged and give off protoplasmic processes which anastomose to form the reticulum. The outer layer of epithelial cells is more columnar in type and radially arranged. According to Hammar (1905), the differentiation of the medulla and cortex begins in human embryos of 50 to 60 mm. It is also about this period that the primary lobules are formed by the ingrowth of connective tissue carrying the blood vessels. These connective tissue septa form major constrictions but never completely sever the medulla which remains as a continuous mass with numerous branches. As the cortex develops, secondary convolution-like folds further subdividing the lobules occur. Small thymic cells (lymphocytes) begin to appear about the end of the second month.

Concerning the further development of the thymus, divergent views have been and still are held. In regard to the nature of the anatomical changes which occur as the gland passes from a purely epithelial structure in early embryonic life to the complex lymphoid-like tissue at the height of its differentiation, it does not seem probable that these questions can be satisfactorily answered by morphological studies alone.

As to the manner in which the embryonic epithelial thymic structure comes to assume its lymphoid appearance, there are three major views:

The first or "pseudomorphosis theory" (His, 1885; Stieda, 1881), assumed that the epithelial thymus was early invaded by connective tissue elements and blood vessels from the surrounding mesenchyme, which thus destroyed the original epithelium except for scattered islands which became Hassall's corpuscles. Later a lymphocytic invasion took place and the further development of the gland was that of a true lymphoid tissue.

The second or "transformation theory" (Kölliker, 1879; Beard, 1902; Stöhr, 1905; Bell, 1906; Pappenheimer, 1910) assumed that the fully developed thymus and all its essential components arose from the original epithelial cells by repeated divisions and modifications of form.

The third or "substitution theory," developed largely through the studies of Hammar (1908), Maximow (1909) and Danchakoff (1908), assumed that the reticulum and Hassall's corpuscles are the only elements developed from the original epithelial anlage, while the small thymic cells (lymphocytes) and eosinophiles are of mesodermic origin. Hammar bases his view of the mesodermal origin of the small thymic cells primarily on his studies of the development of the thymus in a series of Teloeost embryos. At one stage of their development he describes an infiltration of the epithelial lobules with lymphocytes from the surrounding mesenchymal tissues, where they undergo rapid proliferation, Maximow (1912), Danchakoff (1908) and Badertscher (1915) have made similar observations on the thymus of reptiles, birds and mammals, and differ with Hammar only in believing these cells are derived from connective tissue rather than from blood cells. Pappenheimer (1910) has criticized these studies as not offering sufficient proof for the identification of these cells as true lymphocytes. Nor does the principle of differentiation of cells as applied by Danchakoff (1916) offer a reliable criterion for identifying the small thymic cell as a true lymphocyte. More recently Pappenheimer (1917) has studied the reaction of small thymic cells to cytotoxic serums prepared by injecting rat thymus into rabbits. He finds that suspensions of thymus cells and lymphocytes are equally agglutinated and cytolized by such serums and interprets this finding as strongly supporting Hammar's view that the small thymic cells are true lymphocytes.

Recently (Figs. 264 to 267) the method of transplantation has been utilized by Gottesman and Jaffe (1926) for studies on the histogenesis of the thymus. As is well known, the thymus transplants with great ease in any part of the body. Very characteristic changes occur in autotransplants in rats, guinea pigs and rabbits, the guinea pig best of all (Gottesman and Jaffe). During the first four or five days complete degeneration of the small thymic cells takes place and at the same time a rapid degeneration of reticular cells occurs. By the fifth or sixth day there is a marked overgrowth of reticulum with the beginning formation of Hassall's corpuscles from apparently redundant or spent reticulum cells, but no trace of small thymic cells can be made out within the transplant and very few lymphocytic cells in the tissue surrounding the transplant. From the sixth to the eighth day one can detect scattered single or groups of small thymic cells in various parts of the reticulum without any evidence of invasion from without. These small cells increase in number with great rapidity and within two days (about the tenth day in the rat) there is a distinct demarcation into cortex and medulla. While lymphoblastic cells are present in all tissues and are readily capable of transplantation, it is difficult to understand how so uniform a plan of regeneration could occur equally in transplants in any part of the body and in animals of any age, if the small thymic cells arose from migrated lymphoblastic elements.

The same kind of changes occur in the regeneration of a transplanted fragment of lymph gland; namely, all the lymphocytic cells disappear within four to five days, regeneration of the reticulum into a uniform epithelioid mass takes place and later the appearance of scattered single and groups of lymphocytes occur in this newly formed reticulum. In the case of the lymph gland transplant, no one doubts the origin and nature of the lymphocytes and the tendency has been to assume a similar origin for the thymic lympho-

cytes. Gottesman and Jaffe have confirmed Pappenheimer's earlier observations on the occurrence of transitional forms between the reticular cells and the small thymic cells in their studies of regenerating thymus transplants, and all their studies are in support of the view of Kölliker, Stöhr, Bell, Schridde, (1909) and others—that the small thymic cell arises from the reticular epithelium. While the fact that the small thymic cells and lymphocytes resemble each other in all their morphological characteristics, in their susceptibility to roentgen-ray injury, in their serological reactions, in having ameboid movement and in their general pathological behavior must be accepted as strong evidence in favor of their identity, the writer believes the data are still insufficient to establish this identity. However, all recent studies are in accord in supporting the view that the reticulum is derived solely from the original epithelium and that Hassall's corpuscles arise from the further differentiation and later degeneration of reticular cells.

2. *General morphology:*

The fully developed human thymus is roughly triangular in shape with the base resting on the pericardium. It consists of two (occasionally three or four) lobes usually somewhat unequal in size, loosely joined along their medial border (but never actually fused) except for the upper portion or horns of each lobe, which diverge and extend 2 or 3 cm. into the neck on either side of the trachea. The lobes are divided into primary lobules and these are further subdivided into secondary lobules or follicles 1 to 2 mm. in diameter. Each of these lobules is composed of a central part or medulla and an external part or cortex.

As pointed out by Hammar (1911), the ingrowth of the primary septa does not completely cut off the medulla which remains at least until involution is well advanced as a continuous but very irregular and multi-branched cord. The cortex shows wide variations in thickness. The separation into cortex and medulla zones depends upon variations in the number and distribution of the small thymic cells and varies greatly with age, involution and disease. The gland is grayish pink in color, of soft consistence and when congested with blood has characteristic petechial-like spots on the lobules where the congested medulla is not covered with cortex. Statements regarding the size are necessarily conflicting because of the great variability due to age, to pathological involution, to various degrees of what must still be designated "lymphatic constitution" (status lymphaticus), to geographical location (especially goiter districts) and to possible differences due to race. Friedleben (1858) made the first extensive study of the weight of the thymus in relation to age. His figures are as follows:

TABLE 1

WEIGHT OF THE THYMUS IN RELATION TO AGE (FRIEDLEBEN)

Age	No. of cases	Weights (gms.)		
		Aver.	Max.	Min.
New-born	72	13.98	25.8	6.08
1–9 mos.	13	20.14	34.1	9.74
9 mos.–2 yrs	7	26.6	37.7	19.97
3–14 yrs.	6	26.31	31.9	19.7
15–25 yrs.	4	21.54	23.6	17.8
26–35 yrs.	2	3.02	4.21	1.82

The most frequently quoted data are those of Hammar (1906) on 126 cases of individuals dying acutely. His figures are as follows:

TABLE II

WEIGHT OF THE THYMUS IN RELATION TO AGE, IN INDIVIDUALS DYING ACUTELY (HAMMAR)

Age	No. of cases	Weights (gms.)		
		Aver.	Max.	Min.
New-born	23	13.26	25.88	7.6
1– 5 yrs.	23	22.98	49.0	8.5
6–10 yrs.	5	26.1	30.0	20.0
11–15 yrs.	4	37.52	52.0	20.0
16–20 yrs.	10	25.58	47.0	15.2
21–25 yrs.	15	24.73	45.0	7.3
26–35 yrs.	15	19.87	30.0	4.29
36–45 yrs.	12	16.27	28.0	8.2
46–55 yrs.	7	12.85	21.0	2.5
56–65 yrs.	6	16.08	30.0	5.6
66–75 yrs.	4	6.0	8.0	3.0

Bratton (1925) has analyzed 337 cases of previously healthy children under sixteen years of age dying from acute causes at the London Hospital and obtained the following average weights:

TABLE III

AVERAGE WEIGHT OF THE THYMUS IN CHILDREN UNDER SIXTEEN, DYING ACUTELY (BRATTON)

Age	Average weight, grams
New-born	11.18
0 - 6 yrs.	24.19
6–11 yrs.	29.00
11–16 yrs.	27.24

These three compilations may be taken as representative of numerous other compilations that have appeared in the literature. The figures of Hammar are perhaps somewhat high, and it is probable that cases of status lymphaticus have been included. In general, one can state that the absolute weight of the thymus increases rapidly up to the end of the second year of life and then changes but little until the seventh year when it again increases slightly, to fall again after the eleventh year. The weight of the thymus relative to body weight, according to Bratton, increases for part of the first six months and then decreases rapidly. Relative to sex, the thymus in the male is larger during the first four years of life and remains approximately equal in the two sexes until the eleventh year, after which it tends to be larger in the female.

3. *Blood supply:*

The blood is derived mainly from the internal mammary arteries but also from branches of the inferior thyroid and pericardial arteries.

The arteries are distributed to the cortical zone of the lobules through the stroma. There they break up into a capillary network which converges toward the large venous spaces in the medulla. Where the main lobular vein emerges, the medulla extends to the stroma. The veins of the thymus are thin-walled and capable of enormous congestion. The veins for the most part empty into the left innominate vein.

4. Lymphatics:

According to His (1861) and Matsunaga (1910), the lymphatics arise as plexuses aroūnd the individual follicles but do not penetrate them. These fuse to form a network beneath the capsule of the lobule from which larger trunks arise and follow the courses of the blood vessels, more particularly the arteries in the interlobular septa. These trunks, according to Severeanu (1909), drain into three groups of lymph glands: (1) anterior, between the sternum and the thymus, usually consisting of four or seven nodes; (2) superior, usually one on each side just above the upper border of the cervical prolongation, and (3) posterior or prepericardial, consisting of several (usually four) small nodes.

5. Innervation:

The nerve supply of the thymus has never received much attention. According to Sjolander and Shandberg (1915) and Braeucker (1923), they arise from the same source as those of the thyroid and parathyroid, namely, the cervical sympathetic and vagus, and reach the gland through the cardiac branches and cardiac plexus. Hallion and Morel (1912) demonstrated by means of the plethysmographic method that the thymus vessels have vasoconstrictor fibers whose central connections leave the spinal cord in the first four or five thoracic dorsal rami.

6. The small thymic cells:

These cells contain round, densely staining nuclei, 3 to 4 mm. in diameter, surrounded by a very scanty cytoplasm which stains faintly with basic dyes. There are wide variations in the staining intensity and even in the shape and size of the nuclei. Pappenheimer (1910) has called attention to a series of nuclear changes consisting of pycnosis with budding and extrusion of nuclear particles and caryorrhexis which he looks upon as regressive and degenerative, and on account of the constancy of these nuclear changes in both the normal and pathological thymus, he suggests that they may have a functional significance. The localization, number and distribution of the small thymic cells in the lobule varies in different glands and in different stages of development and involution. These cells lie in the meshwork of the reticulum. In the fully developed gland they are found most closely aggregated in the cortex. Mitochondria are present just

as in true lymphocytes and are much larger than those of the reticular cells, but nothing indicative of secretory polarity or secretion antecedents has been made out (Cowdry, 1922). They have the power of ameboid movement (Hammar, 1907).

7. *Reticular cells:*

These are the original epithelial cells of the thymus. They are seen to best advantage and in purest form in regenerating autotransplants of the guinea pig thymus, and to a less satisfactory degree after roentgen-ray injury just before the appearance of the small thymic cells. In the normal gland the small thymic cells overshadow them. During development reticular cells become highly variable in size and shape. They are two or three times the size of small thymic cells. The nucleus is large, vesicular, poor in chromatin, round or oval and usually contains a nucleolus. The cell outlines during the stage of pure reticular regeneration in a transplant are distinct, while in the fully developed thymus their outlines are indefinite. The protoplasm is drawn out into irregular prolongations which anastomose with similar processes from other reticular cells and thus produce a protoplasmic network or syncytium, in the meshes of which lie the small thymic cells. In addition to the irregular protoplasmic processes, the reticular cells contain distinct fine fibrils. These are formed on the surface of the cells and extend from one cell to another in straight lines. The number of these fibrils is not great, and in some cells they appear to be absent. The reticular cells may attain great size and undergo regressive changes which will be discussed under Hassall's corpuscles. As has already been indicated, reticular cells are capable of rapid division following roentgen-ray injury and particularly in developing transplants. Multinucleated giant cells may be formed and these as well as the ordinary reticular cells have marked phagocytic powers. This is most strikingly seen in regenerating transplants, but, as is well known, phagocytosis of broken-down small thymic cells is readily demonstrated in the normal thymus.

8. *Hassall's corpuscles (Figs. 265 to 267):*

Hassall (1846) gave the first clear description of these structures. These unique structures have been variously interpreted as remnants of the branchial cleft epithelium included in the developing thymus, as remains of the original epithelial anlagen, as structures derived from connective tissue, as structures developed from the endothelium of blood vessels and finally as structures developed from reticular cells. Due largely to the work of Hammar (1914), the latter view is accepted as the correct one. According to it, they are formed from hypertrophic, spent or degenerative reticular cells. In the human thymus these first appear at the end of the second month and increase rapidly during the remainder of the fetal period and then more

slowly until age involution begins at last, and Hammar thinks they may be formed until old age. Wallisch (1903) has proved the increase in number by showing that the volume of Hassall's corpuscles in a young child greatly exceeds the total volume of the thymus in a three months fetus. Hassall's corpuscles may consist of single hypertophic reticular cells or of single, compounded and even branching groups of cells, and depending on the age of the corpuscle, the cells may appear as active, irregularly polygonal or as flattened, hyalinized crescentic cells concentrically arranged about a central core consisting of nuclear débris. These hyalinized cells usually contain fat droplets, ingested nuclear material and leucocytic elements. They may undergo liquefaction and become cystic—so-called Dubois (1850) abscesses (Chiari, 1894)—or calcified.

Whether as Hart (1914a) has suggested, the Hassall's corpuscles have a special functional or secretory activity like the islands of Langerhans, for which there is at present no evidence, there can be no question that in their typical form they must be looked upon as spent, redundant, degenerating and hyalinized cells. In the fully developed thymus the average diameter of Hassall's corpuscles varies from 20μ to 50μ, although much larger and much smaller corpuscles occur.

9. *Myoid cells (sarcolytes):*

Sigmund Mayer (1888) described in the frog's thymus peculiar long spindle-shaped cells occurring in the reticulum and showing distinct, concentrically arranged fibrillae with cross striations. Schaffer (1893) described them in the thymus of bony fishes and on account of their resemblance to rudimentary striped muscle fibers he designated them "sarcolytes." Pensa (1902) described similar cells in birds and reptiles, and Pappenheimer (1910) described the occurrence of these cells in the thymus of a five and one-half months human fetus. Pensa thought these cells were embryonic muscle fibers derived by inclusion from the musculature of the branchial clefts. Hammar (1905) suggested that these cells were peculiarly differentiated reticular cells and therefore closely related to Hassall's corpuscles. Pappenheimer (1910) has observed the occurrence of striations in the cells of Hassall's corpuscles. These cells undergo regressive changes and completely disappear in old age, even in birds, where they are normally most numerous. So far as is known, they are never present in mammals after birth. Their significance is unknown.

10. *The cystic and duct-like spaces (Fig. 269):*

In the thymus of most mammals occasionally, and with great frequency (20 per cent of 375) in the dog's thymus, one sees irregular, branching cystic spaces lined with cuboidal or ciliated columnar epithelium. These cystic spaces may occur throughout the gland and vary greatly in number in

LANE LIBRARY. STANFORD UNIVERSITY

different thymuses. Occasionally they make up most of the thymus volume in dogs. They may be in the septa between the lobules but are most frequently seen within the thymus lobule with thymus tissue completely surrounding and closely adherent to the cyst walls. When traced through serial sections, these cystic spaces end blindly or as solid epithelial nests and may appear to be continuous with the reticulum. The number of Hassall's corpuscles is in inverse proportion to the number of duct spaces.

As to the mode of origin and significance of these spaces there has been much speculation. It is believed that these duct-like spaces arise from two sources: First, by the inclusion and persistence of remnants of the branchial cleft epithelium dragged downward with the thymus anlage. Such cystic spaces are usually seen in the septa of the head or cervical portion of the thymus. Secondly, they may arise from the failure of the original thymic tubule to lose its lumen or from the further differentiation of the thymic cord into tubules as a result of some stimulus causing an increased rate of thymus growth during early embryonic development. In support of the view that the original entodermal duct of Remak or that the thymic epithelial cord may under some peculiar stimulation differentiate into cystic spaces, we have the observation that such duct-like spaces in the thymus are of much more frequent occurrence in districts of endemic goiter than in nongoiterous districts. The writer has come to this conclusion after the examination of large series of dog thyroids and cat thyroids obtained from the Great Lakes basin and from New York. As to the relation of these ducts to the formation of Hassall's corpuscles, Schambacher (1903) believed that Hassall's corpuscles could be formed from them. The writer (1915) also believes that Hassall's corpuscles may be formed from the epithelium of the smaller ducts that arise from the original entodermal tube but never from the branchial cleft inclusions seen in the cervical portion of the thymus.

11. *Eosinophile cells:*

Monnuclear and polymorphonuclear eosinophiles are regularly present in highly variable amounts in the thymus from early fetal life (third month) until age involution. Schaffer (1891) first described the presence of eosinophile cells, although Watney's (1882) granular cells are probably identical. Eosinophilic cells are most numerous during late fetal and the first two years of extrauterine life, although this is very variable. They are found in the interlobular stroma, especially about the vessels, in the cortical and also in the medullary portion of the lobule, particularly in those portions of the medulla in direct contact with the interlobular septa where the lobular veins emerge. The great majority of the eosinophiles are mononuclear or myelocytic. Badertscher (1920) has studied the origin of these cells in the developing pig's thymus. He supports the view that they are true eosinophile cells derived from the same cells (large lymphocytes) which give rise to the small thymic cells, and therefore supports Hammar's view that both the eosinophilic cells and the small thymic cells arise from infiltrated mesenchymal cells. Others (Schridde, 1909), while supporting the view that the eosinophiles arise from migrated blood cells, also hold that the small thymus cells are of epithelial origin (Schridde, 1923).

12. *Stroma:*

The connective tissue ingrowths from the primitive capsule causes the formation of the primary lobules at the end of the second month of fetal life in the human thymus. These ingrowths of connective tissue represent the beginning of the thymus stroma. At first the lobules are widely separated by loose cellular connective tissue, but as the rate of growth of the thymus increases, the lobules become closer and closer together and the stroma compressed into thin septa. This condition persists until the end of the second year when the rate of thymus growth to body growth markedly decreases. From this time until sexual maturity the stroma again becomes more prominent without any decrease in the parenchyma, so that the further increase in the weight of the thymus which takes place during childhood is due mainly to the increase in stroma. As age involution sets in, there is a rapid increase in the size of the stroma bands. These interlobular septa normally do not penetrate the gland substance except for the thin connective sheaths accompanying the blood vessels. Adipose tissue makes its appearance in the stroma in late childhood and increases rapidly after involution sets in. All the large blood and lymph vessels are carried in the stroma. The stroma always contains lymphocytes in greater or less numbers, plasma cells, reticulo-endothelial cells (tissue mass cells) and eosinophiles. The eosinophile cells may be present in such numbers as to distend the interlobular septa.

13. *Age involution (Figs. 270 to 272):*

By age involution is meant the normal atrophy of the thymus in man and animals, which sets in about the age of puberty and continues until old age. While it is believed that the normal or physiological involution is different from the pathological or accidental involution due to disease, there are no very definite distinguishing anatomical features. The two types of involution may occur simultaneously, and accidental involution and regeneration must occur in most individuals one or more times before the normal involution sets in. A similar age involution of lymph glands also begins about the age of puberty and this is another evidence of their close physiological relationship.

Waldeyer (1890) observed that widely separated strands of thymic tissue composed largely of reticular cells normally remain in the fatty tissue of the thymus area throughout life, and thus disposed of a prevalent view that the thymus completely disappeared in old age. More recent studies indicate that the thymus parenchyma (excluding stroma) in man ordinarily reaches its maximum weight about the end of the second year, and remains more or less stationary until puberty when an abrupt decline sets in. Hammar (1906) states that up to the age of puberty (eleven to fifteen

years) there is an increase in the size of the organ. This increase in the size after the second year is largely due to the increase in the interlobular stroma and very slightly, if at all, to the actual increase in the thymic parenchyma.

Why sexual maturity should mark the turning point in the size of the thymus is unknown. Some have claimed that the sex glands play a decisive rôle in initiating this anatomical and physiological decline of the organ. There is abundant evidence that the cause is a far more complex culmination of the interactions of the glands of internal secretion and at least involves the thyroid, suprarenal and sex glands and probably others as well (see Physiology). After sexual maturity there is a rapid reduction in the volume of parenchyma for the first four or five years, then it becomes more and more gradual. This initial and rapid reduction in volume is due largely to a decrease in the number of small thymic cells, hence cortical. The lobules shrink in size, the interlobular spaces are correspondingly widened and the connective tissue assumes the character of adipose tissue. Later the medulla decreases in volume, in part due to a decreased rate of division of the reticular cells and in part to their actual disintegration. Hassall's corpuscles usually decrease before the onset of age involution, but at that time the decrease becomes more rapid. New reticular cells, new Hassall's corpuscles and new small thymic cells, however, are being formed during involution, only at a slower rate, and Hammar contends that all these elements are being formed throughout life. There is usually only a slight increase in the intralobular connective tissue in normal involution, although a true sclerosis of the lobule may occur in the involutions due to disease. In well-advanced involution there is always a very marked decrease in the blood supply associated with obliterating endarteritic changes which some of the early observers (Afanassiew, 1877) mistook for Hassall's corpuscles. The mechanism of the decrease in the number of small thymic cells—how much is due to increased migration and how much to their disintegration and ingestion by reticular cells in situ—is undetermined.

14. *Physiology:*

The function of the thymus is unknown. In its principal physiological and pathological reactions it closely resembles the true lymphoid tissues and most of the literature associates its function with those tissues; but in recent years, with the development of the conception of its basic epithelial nature, our views as to its function have shifted accordingly.

There is no proof that it has an internal secretion and some observers would summarily exclude it from the list of glands of internal secretion. There is abundant evidence that it plays some important rôle in the animal economy, although the evidence obtained from its extirpation and the study of the effects of feeding or injecting the gland or its extracts have on the whole been disappointing.

The facts that it persists throughout life, that beginning at puberty it undergoes a physiological involution, that during starvation, acute infections and intoxications it undergoes an acute involution, that in certain conditions such as status lymphaticus and after gonadectomy its normal involution is delayed and under other conditions as in Graves' disease, acromegaly and following suprarenalectomy it may regenerate —all indicate

that it plays some important part in the maintenance of normal nutrition at least during the period of growth up to sexual maturity.

The results of extirpation, as first shown by Friedleben (1858) on dogs and goats, prove that the organ is not essential to life. In more recent times the extirpation experiments of Hammar (1905*a*) and Vincent (1904) on frogs, of Taruli and LoMonaco (1897) and Park and McClure (1919) on dogs, of Park (1917), Paton and Goodall (1904) and others on guinea pigs, of Pappenheimer (1914) and others on rats, of Marine and Manley (1917) and Van Allen (1926) on rabbits have confirmed and extended Friedleben's conclusions and have shown definitely that thymectomy is usually not followed by detectable symptoms.

This apparent uniformity of results has tended to create the impression that thymectomy has no untoward effects or that its functions may be immediately compensated for by other lymphoid tissues—a conclusion which the writer believes is at present unjustified.

On the other hand, the work of Soli (1909) on hens led him to conclude that the gland played some part in the normal metabolism of calcium. After a latent period of two to four weeks he noted that thymectomized hens laid eggs of smaller size and with imperfectly calcified shells. Basch (1903), working with young puppies, also noted a latent period of two to three weeks before symptoms appeared. The most important symptoms observed by Basch were defective ossification, fragility of the skeleton and hypersensitiveness of the peripheral nerves—symptoms which led him to assume some relation to rickets. He however, concluded that while the gland was not indispensable to life, it exercised an important function in early life in promoting growth and calcification of the bones. Klose (1910) and Klose and Vogt (1910) have extended and confirmed the observations of Basch. They also recognized a latent period of two to four weeks without symptoms. Then there appeared evidence of impaired calcification, stunting and weakness which they designated "cachexia thymopriva," leading eventually to death from "coma thymicum" from three to fourteen months. The results of Basch and Klose are obviously not correct.

Of greater interest are the studies of Barbàra (1918). He concludes that the thymus is concerned in the defense of the body against toxins. He believes that the thymus forms substances (opsonins?) that stimulate phagocytosis and in addition it either forms complement or stimulates other organs to produce it. That the lymphoid tissues (spleen, lymph glands) are intimately concerned in the formation of antibodies, there is abundant evidence. The observation of Také and Marine (1923) that suprarenalectomized rabbits and of Jaffe (1924) that suprarenalectomized rats form antibodies more rapidly than normal animals, although their resistance to toxins is greatly reduced has been associated by these investigators with the regeneration of the lymph glands and thymus which follows supra-

renalectomy in these animals. So also the observation of Tanabe (1923) that cases of status lymphaticus among Japanese soldiers, although these individuals react severely to injections of typhoid vaccine, produce as high (sometimes higher) agglutin titers as normal individuals, may be interpreted as involving a thymus factor.

The difficulties of complete removal, the occurrence of infection and the presence of accessory thymic tissue have undoubtedly been factors in the results reported, but it cannot yet be stated that thymectomy is without effects.

The effects of feeding thymus and of the injection of extracts have yielded doubtful or negative evidence. Gudernatsch (1914) reported that feeding thymus delayed metamorphosis of tadpoles. Romeis (1925) and Abderhalden (1926) have confirmed this observation. Other observers (Uhlenhuth, 1918) have obtained doubtful results or ascribed the effects to an inadequate diet. E. R. Hoskins (1916) and Downs and Eddy (1920) obtained no effects from feeding thymus to rats and rabbits respectively. Riddle (1924), working with doves and pigeons, observed a group which on the diet used produced soft-shelled eggs and in addition a deficiency of albumen. He further found that the administration of 20 mgms. of dry ox thymus daily corrected this defect.

Chemically Bang (1904) has found that the thymus tissue yields as much as five times the quantity of nucleic acid as lymph glands and on the basis of this observation, Klose (1910) has postulated that one of the functions of the thymus may be in furnishing nucleic acid to the organism. All observers are in agreement that the thymus is an important source of blood lymphocytes and possibly of eosinophiles (Baderstcher, 1915). There is a close parallelism between the number of lymphocytes in the peripheral blood and the activity of the thymus. The view that red blood cells are formed in the thymus at any period is still doubtful though strongly supported by Badertscher (1920).

15. Interrelations:

The most outstanding known physiological features have to do with the interrelations of the thymus with the sex glands, the thyroid and the suprarenals. Calzolari (1898) showed that removal of the testes in rabbits delayed thymus involution. This observation has been many times confirmed (Henderson, 1904; Goodall, 1905; Gellin, 1911, and Marine, Manley and Baumann, 1924). Gonadectomy does not cause hypertrophy of the thymus. Reports to the contrary the writer believes are due to other factors (suprarenals). Suprarenalectomy in rabbits (Marine, Manley and Baumann, 1924) and rats (Jaffe, 1924*a*, *b*) not only prevents involution but causes rapid regeneration even of highly involuted thymuses, provided the thyroid gland is intact. Thyroidectomy, on the other hand, hastens involution in

rabbits (Jeandelize, Lucien and Parisot, 1909; Marine, Manley and Baumann, 1924) as well as prevents the thymus regeneration which ordinarily follows suprarenalectomy. Hammett (1923) found that thyroparathyroidectomy in rats markedly reduced the growth of the thymus. Fulci (1913) and Henderson (1904) observed that pregnancy also hastens involution. R. G. Hoskins (1910), Utterström (1910), Kahn (1916), Courrier (1921) and others have noted that thyroid feeding causes enlargement of the thymus. It is probable that all these interrelated effects are brought about by influences transmitted through the blood stream. This is suggested by observations of the writer—that active subcutaneous thymus transplants in rabbits involute during pregnancy. No positive evidence of an interrelation with the spleen (Mann, 1919; Marine, Manley and Baumann, 1924), with the pituitary or with the parathyroids has been made out. As has already been indicated, on the basis of embryology a relation with the parathyroids would seem the most likely, and it happens that most of the alleged effects of thymectomy are related to calcium metabolism and impairment of ossification. The fact that the thymus remnants may undergo hypertrophy after removal of the major portion of the thymus is also of physiological interest. Friedleben (1858) and Basch (1906) noted this, and although frequently denied it has been recently clearly demonstrated by Gottesman and Jaffe (1926) in rats.

16. *Pathology:*

No clinical disease in which the thymus is primarily involved is known, and in its pathological relations as in its physiological relations it is intimately associated with the lymphoid tissues.

There are many conditions, however, in which the thymus seems to be secondarily involved and a few in which the thymus appears to be intimately related. Of the latter may be mentioned exophthalmic goiter, status lymphaticus, acromegaly and Addison's disease.

If tumors are excluded, the pathological changes in the thymus associated with diseases may be grouped under two headings: (1) atrophies, and (2) hypertrophy and hyperplasia (delayed involution).

The thymus is a very labile tissue, capable of enormous overgrowth under certain conditions (in the rabbit and rat complete regeneration of a highly involuted thymus may occur in two weeks) and of equally rapid atrophy, a condition which Hammar (1905*b*) has designated "accidental involution."

Accidental involution differs from normal involution in that it occurs rapidly and at any age. It is seen in all animals and under seemingly a great variety of conditions, as acute and chronic infections, various intoxications, acute and chronic inanition, following roentgen-ray injury and during pregnancy. All these conditions cause in some unknown way a massive migration and destruction of the small thymic cells. The disintegrated

small thymic cells are ingested in huge quantities by the reticular cells. The gland may shrink to one-fifth its previous weight within a week. Later the reticular cells become fatty, swollen and undergo degeneration leading to a marked decrease, also, in the volume of the medulla, but never to the extent of the cortical decrease. Hassall's corpuscles, according to Hammar (1905*b*), Jonson (1909) and others, are relatively increased but absolutely decreased and in extreme degrees of accidental involution they may disappear. The several kinds of accidental involution differ somewhat as regards the relative destruction of cortex and medulla.

Hypertrophy and hyperplasia of the thymus are relatively rare. Under this heading may also be included "persistent" thymus and "delayed involution." The essential change appears to be a preservation of the fully active thymus at a period in life when involution would be expected.

The most important clinical association of enlarged or persistent thymus is status lymphaticus (status thymicus, status thymicolymphaticus, asthma thymicum, mors thymica)—the lymphatic constitution of the middle ages. Despite the famous dictum of Friedleben (1858), "Es gibt keine Thymus Tod" and the work of Paltauf (1889), Hedinger (1906) and Wiesel (1904) that the enlarged thymus is only a symptom of a general pathological condition, there still appears a huge literature in which an enlarged or persistent thymus is depicted as a cardinal and even causative factor in the constitutional anomaly. Following Kopp's (1830) view, many observers still ascribe the symptoms of thymic asthma and thymus death to mechanical or pressure effects of the enlarged gland. Others, like Svehla (1896) and Hart (1923), have in particular supported the view that status lymphaticus was due to hyperthymization, that is, the circulation of a toxic substance supplied by the hyperplastic thymus. Wiesel's extensive studies led him to the conclusion that in thymic asthma and thymus death the clinical phenomena are best interpreted as due to an injurious raising of the vagus tone with insufficiency of the chromaffin (sympathetic) system. Whether the increased parasympathetic tone is due to a secretion of the thymus, as some have postulated, or is due to a weakness of the sympathetic (suprarenal system) cannot be stated. It seems certain that the explanation of thymus death, thymic asthma and even status lymphaticus must be sought for in this field rather than through pressure or mechanical effects. In view of the work of Paltauf (1889), Wiesel (1904), Hedinger and the experimental work of Crowe and Wislocki (1914), of Marine, Manley and Baumann (1924) and of Jaffe (1924*a*, *b*) on the effect of suprarenalectomy and gonadectomy alone and combined, it is certain that impairment of suprarenal function in some way is the cause of the thymus hyperplasia. Since removal of the suprarenals in rabbits and rats regularly causes thymus hyperplasia (regeneration), the enlargement of the thymus so frequently noted in Addison's disease and first emphasized by Hedinger (190–) may also be brought into relation with a deficient function of the suprarenal system (chromaffin system, Wiesel).

Lack of development of the gonads and gonadectomy if performed before puberty delays but does not prevent thymus involution and certainly does not cause thymus hyperplasia.

Thymus hyperplasia as first pointed out by Marie (1893) occurs in the majority of cases of exophthalmic goiter—as high as 95 per cent of the cases reported by Cappelle (1908), Matti (1912) and many others. Some authors, notably v. Haberer (1914), Hart (1914*b*), Halsted (1914) and others have held the view that the hyperplastic thymus secretes substances which produce certain of the symptoms (vagotonic) of this disease. Others consider the hyperplastic thymus seen in Graves' disease as a manifestation of status lymphaticus complicating but separate from Graves' disease, and still others consider thymus enlargement as an integral part of the disease (possibly antagonistic to the thyroid) but symptomatic. Actual regeneration of the thymus, while it has not been experimentally proved in Graves' disease, is generally accepted. Experimental work showing that feeding thyroid to mothers causes the thymus of the offspring to enlarge, that removal of the thyroid tends to cause involution of the thymus and that removal of the suprarenals actually may cause thymic regeneration in experimentally controlled animals suggests that the thymus changes in Graves' disease are intimately but secondarily related to the alterations of function of the thyroid and suprarenal glands occurring in this disease. In acromegaly thymus enlargement occurs with about the same frequency as in Graves' disease. In all these states it should be emphasized that the lymphoid tissue throughout the body—spleen, lymph glands, tonsils—are also enlarged. Histologically the persistent or hyperplastic thymus is in general the same, irrespective of its clinical association and in general resembles that of a normal thymus in full development. In long-standing cases of status lymphaticus, sclerosis with more or less reduction in the essential thymic elements occurs. Thymus enlargement has also been reported in a significant number of cases of myasthenia gravis.

BIBLIOGRAPHY (THYMUS)

Abderhalden, E. 1926. Ueber das Wesen der Wirkung der Verfütterung von Thymusgewebe auf Wachstum und Entwicklung von Froschlarven. *Arch. f. d. ges. Physiol.*, 211, 324.

Afanassiew, B. 1877. Ueber die konzentrischen Körperchen der Thymus. *Arch. f. mikr. Anat.*, 14, 1.

Badertscher, J. A. 1915. The development of the thymus in the pig. *Am. J. Anat.*, 17, 317.

——— 1920. Eosinophilic leukocytes in the thymus of postnatal pigs. *Anat. Record*, 18, 23.

Bang, I. 1904. Chemische Untersuchungen der lymphatische Organe. *Beitr. z. chem. Physiol. u. Path.*, 5, 317.

Barbàra, M. 1918. La fisiopatologia della tiroide e del timo nei rapporti colle infezioni. *Societa Editrice Libraria, Milano*, 1.

Basch, K. 1903. Ueber Ausschaltung der Thymusdrüse. *Wien. klin. Wochenschr.*, 16, 393.

——— 1906. Beiträge zur Physiologie u. Pathologie der Thymus. Ueber die Ausschaltung der Thymusdrüse. *Jahrb. f. Kinderh.*, 64, 285.

Beard, J. 1902. The origin and histogenesis of the thymus in Raja bata. *Zool. Jahrb.*, 17, Hft. 1–2.

Bell, E. T. 1906. The development of the thymus. *Am. J. Anat.*, 5, 29.

Braeucker, W. 1923. Die Nerven des Thymus. *Zeit. f. Anat. u. Entwicklungsgesch.*, 69, 309.

Bratton, A. B. 1925. The normal weight of the human thymus. *J. Path. and Bact.*, 28, 609.

Calzolari, A. 1898. Recherches experimentales sur un rapport probable entre la fonction du thymus et celle des tecticules. *Arch. ital. d. biol.*, 30, 71.

Capelle, W. 1908. Ueber die Beziehungen der Thymus zum Morbus Basedow. *Beitr. z. klin. Chir.*, 58, 353.

Chiari, H. 1894. Ueber Cystenbildung in der menschlichen Thymus, zugleich ein Beitrag zur Lehre von der Dubois'chen Abscessen. *Zeit. f. Heilkunde*, 15, 403.

Courrier, R. 1921. Action sur le thymus de l'ingestion de glande thyroide. *Compt. rend. Soc. d. biol.*, 84, 226.

Cowdry, E. V. 1922. In *Endocrinology and Metabolism*. New York; D. Appleton and Co. 2, 368.

Crowe, S. J., and Wislocki, G. B. 1914. Experimental observations on the suprarenal glands with especial reference to the functions of their interrenal portions. *Bull. Johns Hopkins Hosp.*, 25, 287.

Danchakoff, V. 1908. Untersuchungen von Blut und Bindegewebe bei Vögeln. *Arch. f. mikr. Anat.*, 73, 117.

——— 1916. The differentiation of cells as a criterion for cell identification, considered in relation to the small cortical cells of the thymus. *J. Exper. Med.*, 24, 87.

Downs, A. W., and Eddy, N. B. 1920. Effect of subcutaneous injections of thymus substance in young rabbits. *Endocrinology*, 4, 420.

Dubois, P. 1850. Du diagnostic de la syphilis considéré comme une des causes possibles de la mort du foetus. *Gaz. Méd. d. Paris*, Series 3, 5, 392.

Friedleben, A. 1858. *Die Physiologie der Thymusdrüse in Gesundheit und Krankheit vom Standpunkte experimenteller Forschung und klinischer Erfahrung. Ein Beitrag zur Lebensgeschichte der Kinderheit.* Frankfurt a. M. literarische Anstalt. 366 pp.

Fulci, F. 1913. Die Restitutionsfähigkeit des Thymus der Säugetiere nach der Schwangerschaft. *Cent. f. allg. Path. u. path. Anat.*, 24, 968.

Gellin, O. 1911. Die Thymus nach Extirpation bezw. Röntgenbestrahlung der Geschlechtsdrüsen. *Zeit. f. exp. Path. u. Ther.*, 8, 71.

Goodall, A. 1905. The postnatal changes in the thymus of guinea pigs, and the effect of castration on thymus structure. *J. Physiol.*, 32, 191.

Gottesman, J. M., and Jaffe, H. L. 1926. Studies on the histogenesis of autoplastic thymus transplantations. *J. Exper. Med.*, 43, 403.

Gudernatsch, J. F. 1914. A further contribution to the knowledge of organs with internal secretion. *Am. J. Anat.*, 15, 431.

von Haberer, H. 1914. Ueber die klinische Bedeutung der Thymusdrüse mit spezieller Berücksichtigung des Morbus Basedowii und des Status thymicus. *Med. Klinik*, 10, 1087.

Hallion, L., and Morel, L. 1912. L'innervation vaso-motrice du thymus. *J. d. Phys. et d. Path. gén.*, 14, 1.

Halsted, W. S. 1914. The significance of the thymus gland in Graves' disease. *Bull. Johns Hopkins Hosp.*, 25, 223.

Hammar, J. A. 1905*a*. Ist die Thymusdrüse beim Frosch ein lebenswicktiges Organ? Enige experimentelle Untersuchungen. *Arch. f. d. ges. Physiol.*, **110**, 337.

——— 1905*b*. Zur Histogenese und Involution der Thymusdrüse. *Anat. Anz.*, **27**, 23, 41.

——— 1906. Ueber Gewicht, Involution und Persistenz der Thymus im Postfötalleben des Menschen. *Arch. f. Anat. u. Phys., Anat. Abt.*, 91.

——— 1907. Ueber die Natur der kleinen Thymuszellen. *Arch. f. Anat. u. Ent.*, 83.

——— 1908. Zur Kenntniss der Teleostierthymus. *Arch. f. mikr. Anat.*, **73**, 1.

——— 1910. Fünfzig Jahre Thymusforschung; Kritische Uebersicht der normalen Morphologie. *Ergebn. d. Anat. u. Entw.*, **19**, 1.

——— 1911. Zur gröberen Morphologie und Morphogenie der Menschenthymus. *Anat. Hefte*, **43**, 203.

——— 1914. Methode die Menge der Rinde und des Marks der Thymus, sowie die Anzahl und die Grösse der Hassall'schen Körper zahlenmässig festzustellen (unter besonderer Berücksichtigung der Verhältnisse beim Menschen). *Zeit. f. Ang. Anat. u. Konst.-lehre*, **1**, 311.

Hammett, F. S. 1923. Studies of the thyroid apparatus. XIV. *Am. J. Anat.*, **32**, 53.

Hart, C. 1914*a*. Thymusstudien. IV. Die Hassall'schen Körperchen. *Virchow's Archiv*, **217**, 239.

——— 1914*b*. Die Bedeutung der Thymus für Entstehung auf Verlauf des Morbus Basedowii. *Arch. f. klin. Chir.*, **104**, 347.

——— 1923. *Die Lehre vom Status thymico-lymphaticus. Ein Beitrag zur Konstitutionspathologie.* München: Verlag von J. F. Bergmann. 172 pp.

Hassall, A. H. 1846. *The microscopic anatomy of the human body in health and disease.* London.

Hedinger, E. 1905–6. Ueber familiäres Vorkommen plötslicher Todesfälle bedingt durch Status lymphaticus. *Deut. Arch. klin. Med.*, **86**, 248.

——— 1907. Ueber die Kombination von Morbus Addisonii mit Status lymphaticus. *Frank. Zeit. f. Path.*, **1**, 527.

Henderson, J. 1904. On the relationship of the thymus to the sexual organs. I. The influence of castration on the thymus. *J. Physiol.*, **31**, 222.

His, W. 1861. Zur Anatomie der menschlichen Thymusdrüse. *Zeit. f. Wissensch. Zool.*, **11**, 164.

——— 1885. *Anatomie menschlichen Embryonen.* Leipzig.

Hoskins, E. R. 1916. The growth of the body and organs of the albino rat as affected by feeding various ductless glands (thyroid, thymus, hypophysis and pineal). *J. Exp. Zool.*, **21**, 295; also *Anat. Rec.*, **10**, 199.

Hoskins, R. G. 1910. Congenital thyroidism; an experimental study of the thyroid in relation to other organs of internal secretion. *Am. J. Physiol.*, **26**, 426.

Jaffe, H. L. 1924*a*. The influence of the suprarenal gland on the thymus. I. Regeneration of the thymus following double suprarenalectomy in the rat. *J. Exper. Med.*, **40**, 325.

——— 1924*b*. The influence of the suprarenal gland on the thymus. II. Direct evidence of regeneration of the involuted thymus following double suprarenalectomy in the rat. *Ibid.*, **40**, 619.

Jaffe, H. L., and Marine, D. 1924. Effect of suprarenalectomy in rats on agglutinin formation. *J. Infec. Dis.*, **35**, 334.

Jeandelize, P., Lucien, M., and Parisot, J. 1909. Modifications du poids du thymus après la thyroïdectomie chez le lapin. *Compt. rend. Soc. d. biol.*, **66**, 942.

Jonson, A. 1909. Studien über die Thymusinvolution. Die akzidentelle Involution bei Hunger. *Arch. f. mikr. Anat.*, **73**, 390.

Kahn, R. H. 1916. Zur Frage der Wirkung von Schilddrüse und Thymus auf Froschlarven. *Arch. f. d. ges. Physiol.*, **163**, 384.

Klose, H. 1910. Ueber Thymusexstirpation und ihre Folgen. *Arch. f. klin. Chir.*, **92**, 1125.

Klose H., and Vogt, H. 1910. Klinik und Biologie der Thymusdrüse mit besonderer Berucksichtigung ihrer Beziehungen zu Knochen und Nervensystem. *Beitr. z. klin. Chir.*, **69**, 1.

Kölliker, A. 1879. *Entwicklungsgeschichte des Menschen und der höheren Tiere.* Ed. 2, Leipzig.

Kopp, J. 1830. *Denkwürdigkeiten in der ärztlichen Praxis.* Frank. a. M. **1**.

Mann, F. C. 1919. The effect of splenectomy on the thymus. *Endocrinology*, **3**, 299.

Marie, P. 1893. Sur la reviviscence du thymus dans certaines affections presentant des alterations du corps thyroide ou de quelqu'autre glande vasculaire sanguine. *Bull. et mém. Soc. méd. d. Hôp. de Paris*, **10**, 136.

Marine, D. 1915. The frequency of duct-like spaces in the thymus gland with remarks on the formation and fate of Hassall's corpuscles. *Clev. Med. J.*, **14**, 186.

Marine, D., and Manley, O. T. 1917. Transplantation of the thymus in rabbits—relation of the thymus to sexual maturity. *J. Lab. and Clin. Med.*, **3**, 48.

Marine, D., Manley, O. T., and Baumann, E. J. 1924. The influence of thyroidectomy, gonadectomy, suprarenalectomy, and splenectomy on the thymus of rabbits. *J. Exper. Med.*, **40**, 429.

Marmorston-Gottesman, J., and Jaffe, H. L. 1925. Compensatory hypertrophy of the thymus gland in the rat. *J. Exper. Med.*, **42**, 413.

Matsunaga. 1910. Ueber die parenchymatösen Lymphgefässe der Thymus. *Zeit. f. Anat. u. Entw.*, **28**.

Matti, H. 1912. Ueber die Kombination von Morbus Basedowii mit Thymushyperplasia. *Deut. Zeit. f. Chir.*, **116**, 427.

Maximow, A. 1909. Untersuchungen über Blut und Bindegewebe. 2. Ueber die Histogenese der Thymus bei Säugetieren. *Arch. f. mikr. Anat.*, **74**, 525.

——— 1912. Untersuchungen über Blut u. Bindegewebe. 4. Ueber die Histogenese der Thymus bei Amphibien. *Ibid.*, **79**, 560.

Mayer, S. 1888. Zur Lehre von der Schilddrüse und Thymus bei den Amphibien. *Anat. Anz.*, **3**, 97.

Paltauf, A. 1889. Ueber die Beziehungen der Thymus zum plötslichen Tod. *Wien. klin. Woch.*, **2**, 877.

Pappenheimer, A. M. 1910. A contribution to the normal and pathological histology of the thymus gland. *J. Med. Res.*, **22**, 1.

——— 1914*a*. The effects of early extirpation of the thymus in albino rats. *J. Exper. Med.*, **19**, 319.

——— 1914*b*. Further experiments upon the effects of extirpation of the thymus in rats, with special reference to the alleged production of rachitic lesions. *Ibid.*, **20**, 477.

——— 1917. Experimental studies upon lymphocytes. II. The action of immune sera upon lymphocytes and small thymic cells. *Ibid.*, **26**, 163.

Park, E. A. 1917. Extirpation of the thymus in the guinea pig. *J. Exper. Med.*, **25**, 129.

Park, E. A., and McClure, R. D. 1919. The results of thymus extirpation in the dog with a review of the experimental literature on thymus extirpation. *Am. J. Dis. Child.*, 18, 317.

Paton, D. N., and Goodall, A. 1904. Contribution to the physiology of the thymus. *J. Physiol.*, 31, 49.

Pensa, A. 1902. Osservazioni a preposito di una particularità di struttura del timo. *Boll. della Soc. med.-Chir. di Pavia*, 188.

Pepere, A. 1908. Sur un système parathyreoïdien accessoire (thymique) constant chez quelques mammifères. *Arch. ital. de Biol.*, **49**, 336.

Riddle, O. 1924. Studies of the physiology of reproduction in birds. XIX. A hitherto unknown function of the thymus. *Am. J. Physiol.*, **68**, 557.

Romeis, B. 1925. Die Wirkung der Verfütterung frischer Thymus auf Froschlarven. *Arch. f. mikr. Anat.*, **104**, 273.

Schaffer, J. 1891. Ueber das Vorkommen d. cosinophiler Zellen in d. menschlichen Thymus. *Cent. f. d. med. Wiss.*, **29**, 401.

——— 1893. Ueber den feineren Bau der Thymus und deren Beziehungen zur Blutbildung. *Sitz. d. k. Akad. d. Wiss.*, Wien., **102**, 336.

Schambacher, A. 1903. Ueber die Persistenz von Drüsenkanälen in der Thymus und ihre Beziehung zur Entstehung der Hassallschen Körperchen. *Virchow's Archiv*, **172**, 368.

Schridde, H. 1909. In *Path. Anat. von L. Aschoff.* Jena, Bd. **2**, p. 139.

——— 1923. Die Zellen der Thymusrinde. *Cent. f. allg. Path. u. Path. Anat.*, **33**, 284.

Severeanu, G. 1909. Die Lymphgefässe der Thymus. *Arch. f. Anat. u. Physiol., Anat. Abt.*, 93.

Sjolander, A., and Shandberg, A. 1915. Ueber die zur menschlichen Thymusdrüse tretenden Nerven. *Upsula Lakaref. Forb.*, **20**, 262.

Soli, U. 1909*a*. Contribution à la connaissance de la fonction du thymus chez le poulet et chez quelques mammifères. *Arch. ital. biol.*, **52**, 353.

——— 1909*b*. Modifications du développement des os chez les animaux privés de thymus. *Ibid.*, **52**, 217.

Stieda. 1881. *Untersuchungen über die Entwickelung der Glandula thymus, Glandula thyreoidea und Glandula carotica.* Leipzig. 38 pp.

Stöhr, P. 1906. Ueber die Natur der Thymus-Elemente. *Anat. Hefte (Wiesb.)*, **31**, 409.

Svehla, K. 1896. Ueber die Einwirkung des Thymussaftes auf den Blutkreislauf und über die sogenannte Mors thymica der Kinder. *Wien. med. Blätter*, **19**, 723, 740, 757, 775, 791, 806, 821.

Také, N. M., and Marine, D. 1923. The effect of suprarenalectomy in rabbits on hemolysin formation. *J. Infec. Dis.*, **33**, 217.

Tanabe, B. 1923. Notes on the relation between preventive inoculations and status lymphaticus in the Japanese army. *Mil. Surg.*, **52**, 92.

Tarulli, L., and LoMonaco, D. 1897. Ricerche sperimentali sul timo. *Bull. d. r. Acad. med. di Roma*, **23**, 311.

Uhlenhuth, E. 1918. Nature of the retarding influence of the thymus upon amphibian metamorphosis. *J. Gen. Physiol.*, **1**, 305.

Utterström, E. 1910. Contribution à l'étude des effects de l'hyperthyroidisation, specialement en ce qui concerne le thymus. *Arch. de méd. exper. et d'anat. path.*, **22**, 550.

Van Allen, C. M. 1926. Thymectomy in the rabbit. *J. Exper. Med.*, **43**, 119.

Vincent, S. 1904. On the results of extirpation of the thymus glands. *J. Physiol.*, **30**, Proc. p. 16.

Waldeyer, W. 1890. Die Rückbildung der Thymus. *Sitzungsber. d. k. preuss. Akad. d. Wiss.*, **25**, 433.

Wallisch, W. 1903. Zur Bedeutung der Hassall'schen Körperchen. *Arch. f. mikr. Anat.*, **63**, 274.

Watney, A. 1882. The minute anatomy of the thymus. *Phil. Trans. Royal Soc. Lond.*, **173**, pt. 3.

Wiesel, J. 1904. Zur Pathologie des chromaffinen Systemes. *Virchow's Arch. f. path. Anat.*, **176**, 103.

PLATE I

Fig. 249.—Dog's thyroid, osmic acid fixation and Ehrlich-Biondi stain. Showing different stages of the "colloid" or darkly staining cells and "chief" or clear cells. A vacuole is present in one of the colloid cells. (After Langendorff.)

Fig. 250.—Normal thyroid of guinea pig. × 200.

Fig. 251.—Early hypertrophy, thyroid of guinea pig. × 200.

Fig. 252.—Marked hyperplasia. Congenital endemic goiter in an infant. × 100.

249

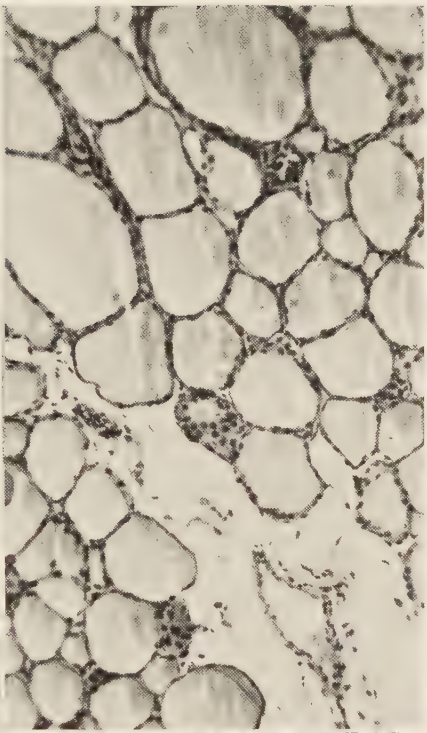

250

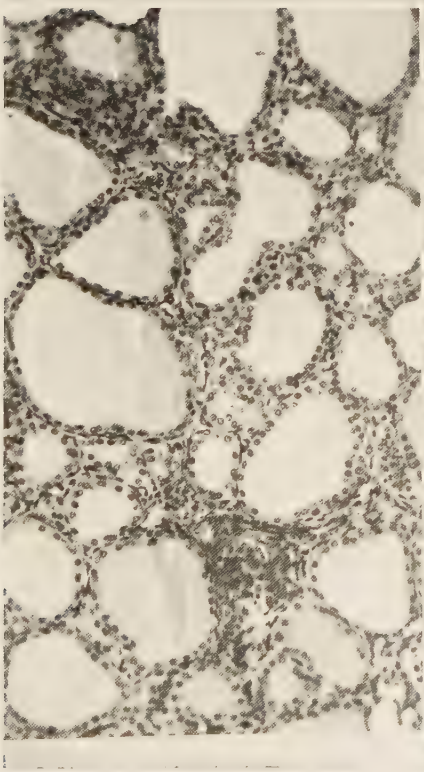

251

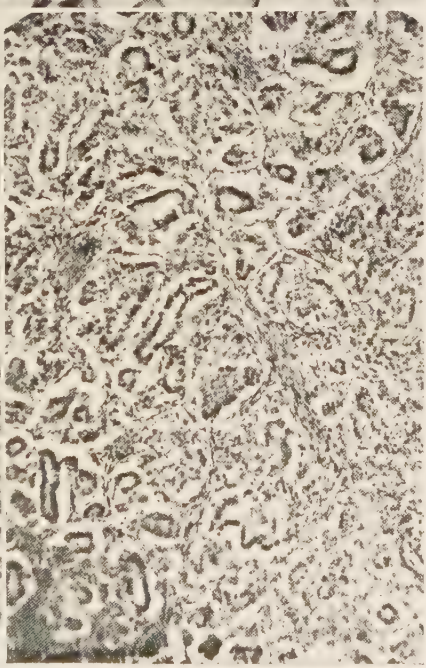

252

PLATE II

FIG. 253.—Marked hyperplasia, human thyroid (from case of exophthalmic goiter). × 400.

FIG. 254.—Marked hyperplasia, simple goiter of fowls (Gallus domesticus). × 400.

FIG. 255.—Colloid goiter, human thyroid (from case of exophthalmic goiter, H.–201, 1908. Crile P. W. S. 3426. Fed iodine for 3 weeks prior to removal).

FIG. 256.—Exhaustion atrophy supervening in marked hyperplasia (case of exophthalmic goiter H.–1233, 1924. Yates, 5505).



253

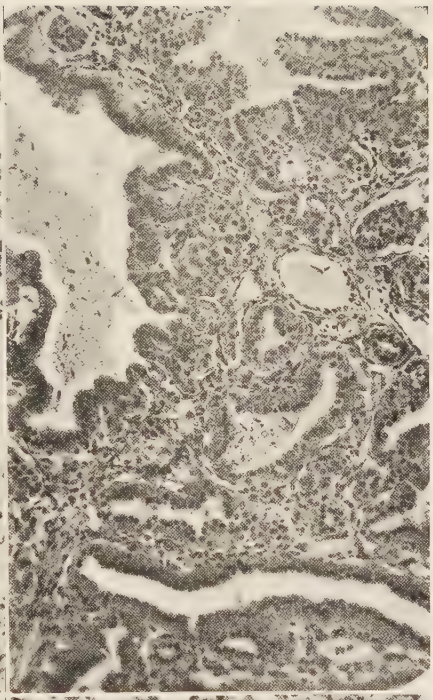

254

255

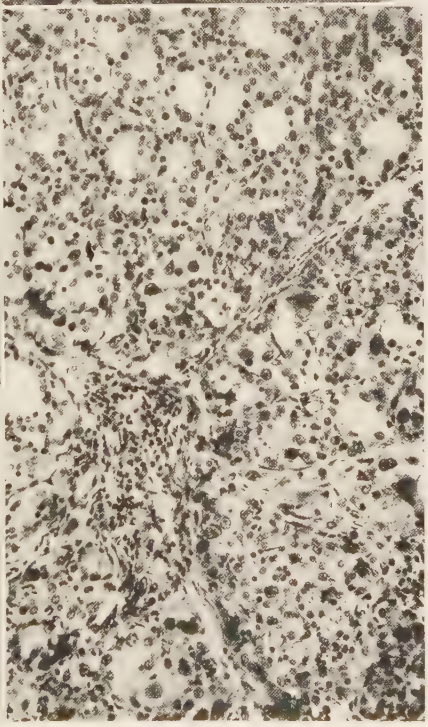

256

PLATE III

FIG. 257.—Exhaustion atrophy supervening in marked hyperplasia (case of endemic cretinism II.–714 Prof. C. Wegelin, 1913). Follicles widely separated, shrunken, marked loss of and degeneration of epithelium.

FIG. 258.—Exhaustion atrophy supervening in marked hyperplasia (A.–129) one of a litter of 4 endemic cretin dogs aged 6 weeks. *First section* removed Nov. 25, 1908. Daily administration of a few mg. iodine since Nov. 20, 1908.

FIG. 259.—Same animal as Fig. 258. *Second section* removed Dec. 17, 1908. Daily administration of a few mg. iodine since Nov. 20, 1908.

FIG. 260.—Same animal as Figs. 258 and 259. *Third section* removed Jan. 18, 1909. Daily administration of a few mg. iodine since Nov. 20, 1908. These three sections (Figs. 258, 259, and 260) illustrate not only the involuting effect of iodine on thyroid hyperplasia but the extraordinary capacity of the thyroid of young animals, even in the state of exhaustion atrophy, to recover when given physiological rest.

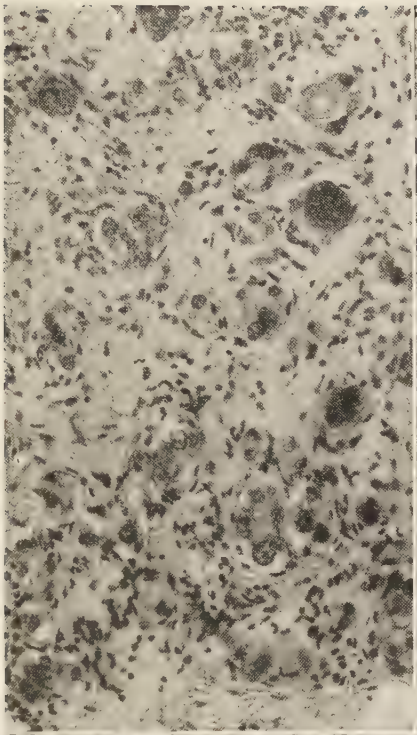

257

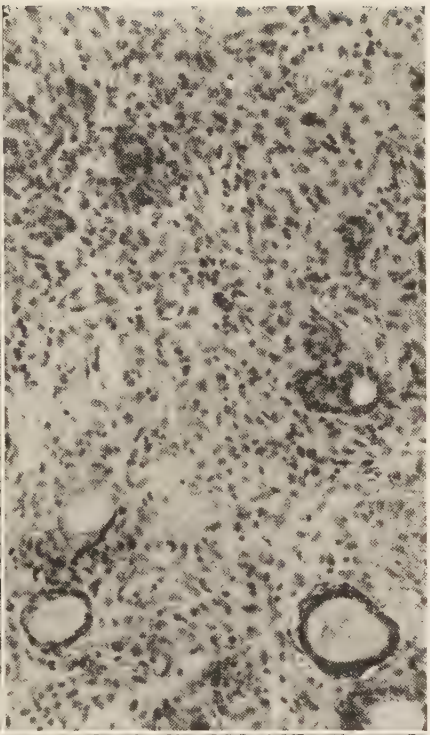

258

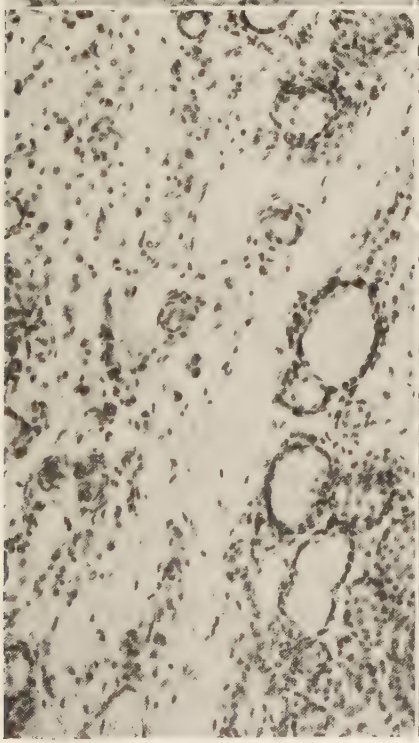

259

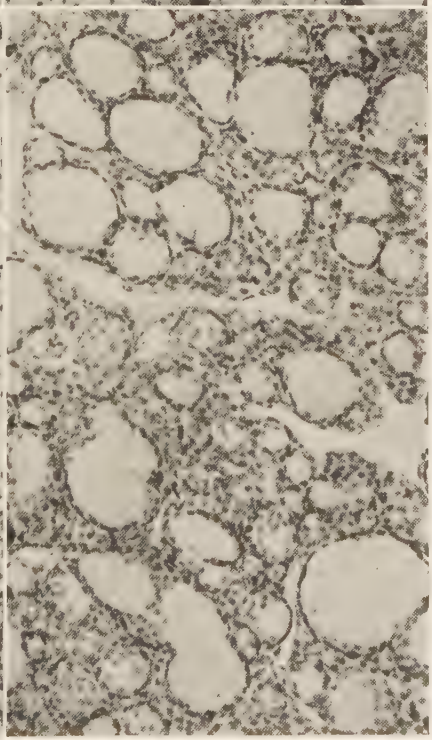

260

PLATE IV

Fig. 261.—Normal human adult parathyroid; lobular type with two groups of oxyphil cells. × 90.

Fig. 262.—Same as Fig. 261. × 250.

Fig. 263.—Normal canine parathyroid; anastomosing strand type; absence of oxyphil cells. × 200.

261

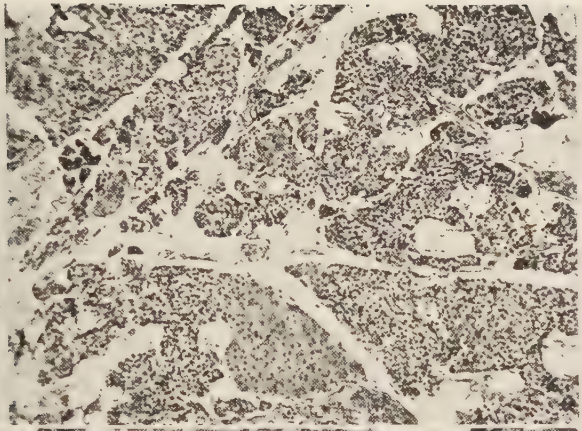

262

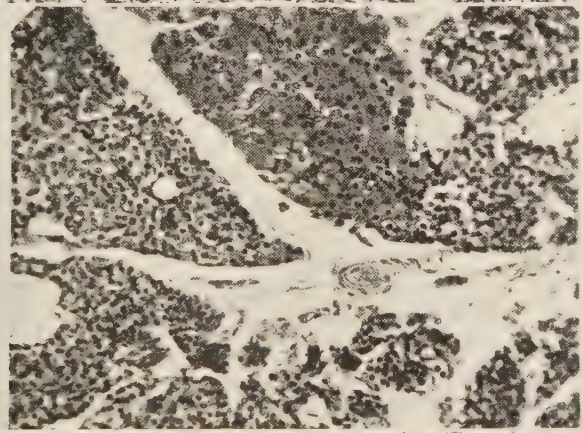

263

PLATE V

Fig. 264.—Regeneration of reticulum 6th day. Thymus transplant, guinea pig (Jaffe.)

Fig. 265.—Regenerating thymus transplant, guinea pig 9th day. Beginning formation of small thymus cells. Reticulum very prominent, numerous large Hassall's corpuscles in various stages of formation from redundant reticulum. Very vascular. (Jaffe.)

Fig. 266.—Regenerating thymus transplant, guinea pig 10th day. Beginning differentiation into cortex and medulla. Medulla contains a large compound Hassall's corpuscle formed from redundant and excessive reticulum. (Jaffe.)

Fig. 267.—Regenerating thymus transplant, guinea pig 5th day. Rapid regeneration of reticulum with one large well formed and many less defined Hassall's corpuscles arising from redundant reticulum. (Jaffe.)

Fig. 268.—Fully developed thymus (cat from Cleveland) showing one large cystic Hassall's corpuscle and one typical concentric Hassall's corpuscle.

Fig. 269.—Dog's thymus (Cleveland) showing a lobule with two cystic spaces and adjacent reticulum.

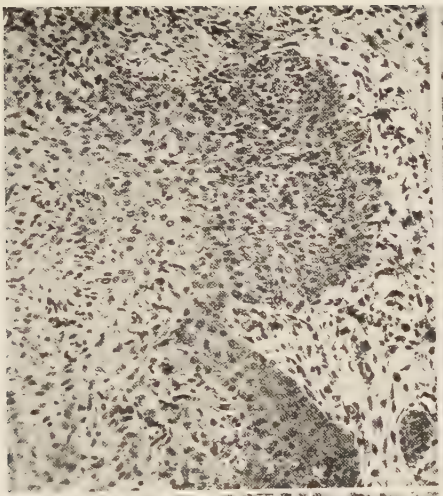

264

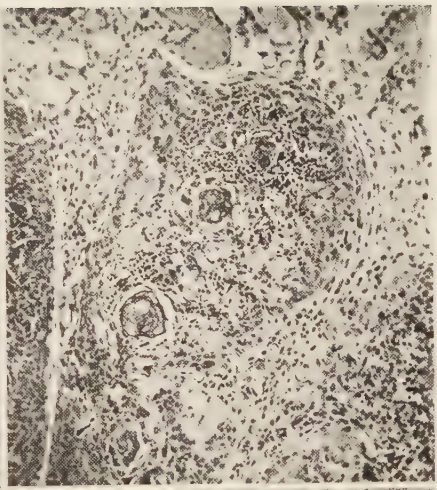

265

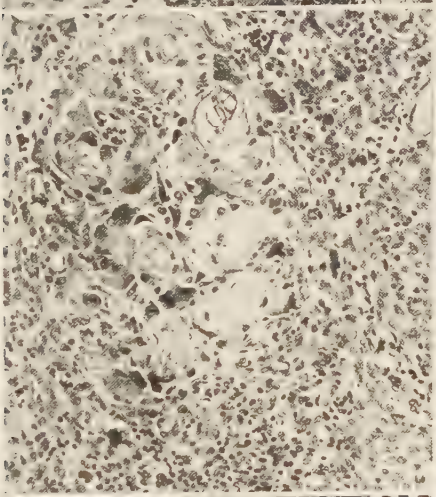

266

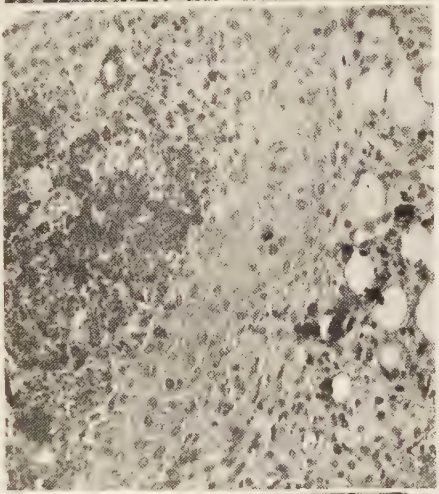

267

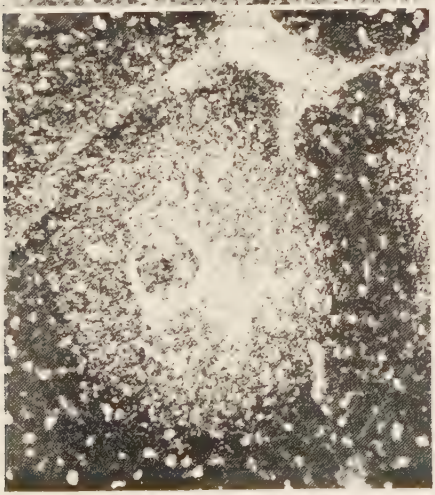

268

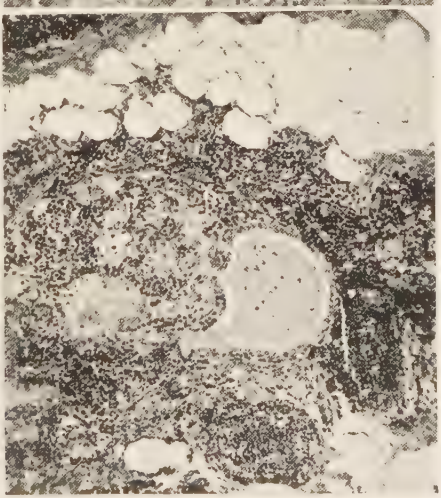

269

PLATE VI

FIG. 270.—Fully developed rabbit thymus. × 75.

FIG. 271.—Early involution rabbit thymus (actually a case of thymic regeneration after suprarenalectomy). × 75.

FIG. 272.—Complete normal (age) involution rabbit, 4 years old. × 75.

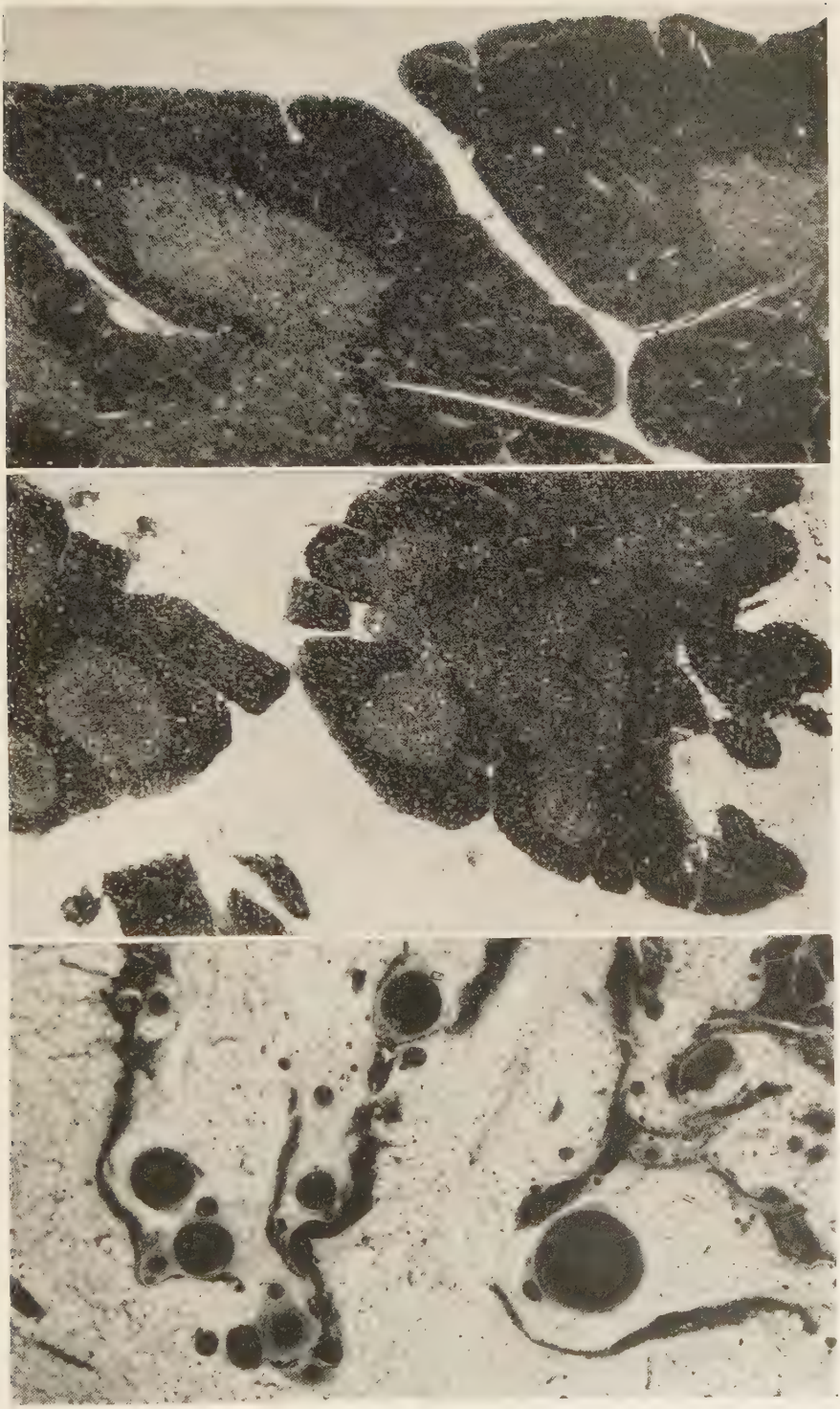

270

271

272

Section XVIII

THE SUPRARENAL BODIES

CONTENTS

Section XVIII

PAGE

I. Medulla 625
1. Functional importance of epinephrin inclusions 631
2. Pigment 640
II. Cortex 640
1. Hypertrophy 648
2. Functional consideration of cortical inclusions 651
III. Bibliography 653

Section XVIII

THE SUPRARENAL BODIES

G. N. STEWART

IN this article it is aimed to consider the "physiological cytology" of the suprarenals, and no systematic description of the microscopic anatomy will be given. That is dealt with in all textbooks of histology and usually in greater detail in monographs on the physiology of the suprarenal bodies, such as the extensive articles by Biedl (1922), Swale Vincent (1925) and Sharpey-Schafer (1924), in their books on endocrine organs. In these generally accessible works the literature, both physiological and anatomical, bearing upon our subject, is extensively cited.

It will be most profitable, it is thought, to devote a minimum of space to cytological features which are common to the cells, cortical or medullary, of the suprarenals and to many other glands, and a maximum of space to the characteristic inclusions. These, at least in the case of the chromaffin granules, are known to be related to the activity of the cells, and in the case of the anisotropic and isotropic lipoid and fatty droplets and granules in the cortical cells constitute very striking objects whether directly related to any important function of the cells or not. It will also be appropriate to say something about the capacity of the medullary and cortical cells, especially the latter, to undergo hyperplasia and hypertrophy. In the present state of our knowledge, however, it must be recognized that it is futile to give a functional significance to all the changes in size which the suprarenals may undergo. Nevertheless, no attempt will be made to exclude allusions to, perhaps speculations on, the relations of the cytological appearances and changes to the probable or possible function of the glands. On the contrary, it is assumed that the chief reason for studying the structure of the cells is to throw light upon their function.

Not much will be said about such cytological features as mitochondria. Too little is known of their physiological meaning, even in cells where they have been more closely studied than in the suprarenal (Cowdry, 1926*a*, *b*). They have been stated to be composed of protein and lipoid in varying proportions (Giroud, 1925). This might be important if clearly proved, lending support to the suggestion of Da Costa (1913) that the mitochondria of the cortical cells are connected with the formation of the lipoids in which these cells are so rich. But it is not clearly proved. According to Da Costa, mitochondria were first described as such in the cortical cells by Bonnamour (1902, 1905), although Plecnik (1902) had previously observed, in the cortical cells of human embryos, granules staining with fuchsin, which were doubtless mitochondria. Mulon (1910*a*, *b*, *c*) made a detailed study of these bodies in the guinea pig, where they are especially evident in the glomerular and in the spongy layers. He denies that mitochondria enter into the elaboration of fat. The mitochondria and the siderophile bodies are considered forerun-

ners of a lipoid substance which finally impregnates the whole cell and which finds its way to the blood vessels by travelling through the cellular interstices. His observations on the adrenals of sheep (whose cortical cells are poor in fat but possess an abundance of mitochondria) lead him to believe that the fat is a sort of reserve substance and that the pigment of the cells is of mitochondrial origin. Da Costa (loc. cit.) extended the study to a large number of mammals.

For the most part the mitochondria of the cortical cells are spherical in shape and of approximately uniform size. Their distribution in the cell varies in different animals and in the different cortical zones. Sometimes they are agglomerated in the neighborhood of the nucleus (typically in the cells of the external and middle cortical layers in the rabbit), more frequently distributed more or less regularly throughout the cytoplasm. It is of interest in connection with the supposed relation of mitochondria to lipoid formation, already mentioned above, that in the herbivora, as the ox, where the cortex is characterized by its poverty in lipoid, mitochondria are very numerous and frequently very large (more than 1μ in diameter). Mitochondria have been found in the suprarenal medullary cells as well as in the cortical cells, e.g., in the rabbit by Mulon (1910c). In a general fashion it can be said that they are more numerous at the periphery of the cell than in the neighborhood of the nucleus (Da Costa, 1913). Some of the granulations colored by iron hematoxylin, described by Hultgren and Andersson (1899), especially those stained more darkly at the periphery of the cells, seem to be mitochondria. Whether they are related to a secretory process, as claimed by Stoerk and v. Haberer (1908), is not worth while discussing since no crucial evidence exists.

It has long been recognized that the mammalian suprarenal consists of two glands, the medulla and the cortex or the adrenal and interrenal glands (Balfour, 1876, 1878*a*, *b;* Swale Vincent, 189-). These are different in origin and function. Their anatomical contiguity does not relate them physiologically any more than the contiguity of the parathyroids and the thyroids renders them similar in function. This represents the view of the great majority of observers, although there are a few writers who still consider that there is a certain degree of cooperation between the two glands. Thus Abelous, Soulié and Toujan (1905, 1906) believe that the active principle of the medulla can be obtained in small quantities from the cortex where it is manufactured from tryptophane. According to Swale Vincent (1925), Schafer and Herring proposed the view that in the cortical cells the material which is to become the chromaffin inclusion of the medulla may pass through initial stages of formation, the process of elaboration being completed in the medulla. Cramer (1918*a*) concludes, from the presence in the cortex (after staining with osmic acid), especially in the layers of cells nearest the medulla, of fine black granules, similar to the adrenalin granules, that "the cortex participates in the functional activity of the medulla and that these two parts of the gland are not two physiologically independent organs." Hartman (1923) supposes that the cortex takes a share in the elaboration of epinephrin. Apart from contamination, due to interpenetration of the cortical tissues by the medulla, or in other ways, other observers have failed to find any evidence of the existence of epinephrin in the cortex (e.g., Sharpey-Schafer, 1924).

No cells possess more characteristic inclusions than the chromaffin granules of the medullary cells. The chemical nature and physiological reactions of the epinephrin which constitutes them or with which they are loaded have been deeply studied. Its fate is known; it passes into the blood and can be detected and estimated, in animals, in the adrenal vein blood. Its discharge is under the control of nerves running mainly in the splanchnics. When the gland is denervated, epinephrin ceases to be liberated or is secreted in such minute quantities that (in dogs, cats and monkeys) none may be detected in the adrenal vein blood even when the test object is delicate enough to demonstrate with certainty the presence of as little as one-thousandth of the normal output (Stewart and Rogoff, 1917*a*, 1919*b*). If the cortical cells liberate a special substance or substances into the blood (or lymph) it does not appear that this process is under the control of the nervous system. For while it has been proved quite clearly that the presence of a certain portion of cortex, possibly sometimes as little as one-eighth or less of the whole (Langlois, 1893; Stewart and Rogoff, 1921; Biedl, 1922) is indispensable to life, the nerves need not remain intact. On the other hand, the medulla can be completely destroyed mechanically, by drilling or curetting (Stewart and Rogoff, 1917*a*, *c*, 1918, 1919*b*, 1922*b*, *c*, *d;* Houssay and Lewis, 1921*b*, 1923), without in any way affecting the health or duration of life of the animal when it has recovered from the surgical effects of the operation as such. Sectioning the nerves has been practised as an extra precaution, in addition to destruction of the medulla, without affecting the result (Stewart and Rogoff, loc. cit.). Wheeler and Vincent (1917) found that animals survive after excision of one adrenal gland and destruction of the medulla of the remaining gland by cauterization. Post-mortem microscopic examination revealed no remaining chromaffin material.

I. MEDULLA

The characteristic cytological feature of the cells of the medulla is the presence in them of granules which are colored brown with chromic acid or its salts and greenish with ferric chloride. They are also blackened by osmic acid, but are not dissolved by the agents in which fat or lipoids are soluble (Cramer, 1918*a*). Because of the chromium reaction the cells have been designated "chromaffin" or "chromophile cells." Cells which stain in a similar way are present in the paraganglia of which the bodies described by Zuckerkandl in the human embryo in the retroperitoneal space in the neighborhood of the abdominal aorta are the best known examples. A large paraganglion is also present, in the dog, dorsal to the abdominal aorta and extending for some distance cephalad from about the bifurcation of that vessel. It can be most easily demonstrated by the method of Kohn (1903), covering the region where it occurs with cotton soaked in potassium

bichromate solution, for six to twelve hours, then washing in running water for a few hours to get rid of the superfluous bichromate. The chromaffin reaction of the cells renders the paraganglion brownish, and it is better seen if the whole preparation is immersed in glycerine. Some chromaffin cells are also found scattered in the sympathetic ganglia.

Together the chromophile tissue of the suprarenal medulla and that in other situations are sometimes spoken of as the chromophile system and the portion outside of the adrenal as the extracapsular or sporadic chromophile tissue. It is assumed by those writers who attribute to the adrenal medulla a specific function that the function of the extracapsular chromophile tissue is the same. But no complete proof has been given, and the matter is of scarcely any importance in view of the dwindling evidence that the adrenal medulla itself plays any significant physiological rôle. It is disappointing that this should be so. For scarcely any histological reaction is more impressive than the massive load of these granules, when brought out by appropriate reagents, in the medullary cells. Nor are there many physiological reactions more striking than the diminution or complete disappearance of the chromophile granules which can be brought about under perfectly definite conditions and their reaccumulation when these conditions are removed. The granules are known to consist of epinephrin, or of a complex whose chief constituent is epinephrin, and the color reactions which they yield in situ are those of epinephrin. If the epinephrin molecules are anchored physically or chemically to other substances, the union is not such as to hinder the color reactions or the easy passage of the epinephrin into the blood of the suprarenal veins in such a form that the serum or the blood at once behaves to sensitive test-objects (as a segment of rabbit's intestine) like an aqueous solution of the active substance. The important and striking physiological reactions of epinephrin artificially extracted from the glands and purified, or synthetically prepared have almost irresistibly suggested that the medulla must possess a function of great physiological significance, and it is only little by little that it has been recognized that these are quite unrelated matters.

The intensity of the chromium reaction, as seen in sections, is roughly proportional to the amount of epinephrin in the gland. If the magnitude of the color reaction in the sections could be estimated as exactly as that in the extracts, it is likely that the relation would be more exact. At the same time it must not be forgotten that as in other histological color reactions a certain caprice, so to say, may not seldom be observed in the distribution of the chromium coloration. Even when the technique of fixation in the fluid is without flaw the cells need not be uniformly colored. Some may miss the reaction altogether. Nor will a medulla which (as indicated by more exact tests on the extract) has a high content of epinephrin necessarily show an intense chromium reaction. Sometimes, according to Ingier and Schmorl

(1911) who worked with human material, the chrome reaction is entirely absent despite the presence of considerable quantities of epinephrin. Whether this may be due to the epinephrin being present in preliminary stages of formation which do not give the chrome reaction cannot be determined at present. At any rate Henle's (1865) chrome reaction should be looked upon only as an orienting test and not as a method of estimating the amount of epinephrin (Biedl, 1922).

The amount of epinephrin in the suprarenals of laboratory animals is on the average about 1 part in 1000 of the moist adrenal weight (1.01 mgms. per gram adrenal, in rabbits—Stewart and Rogoff, 1921; 1.1 mgms. per gram—Fujii, 1924). In the dog the proportion of epinephrin is usually somewhat greater (Stewart and Rogoff, 1916*a*; Fujii, 1925). In man satisfactory material is not so easy to obtain, as some of the epinephrin rapidly disappears at ordinary temperature, after death. But in the fresh gland the proportional weight does not differ much from 1 part in 1000. The relative size of medulla and cortex varies greatly at different ages and in different animals. The relative volume of the medulla is greater in the young mammal and decreases with age. Thus Bager (1917–18) found that in rabbits the medulla constitutes one-fifth of the volume of the adrenal body at birth but only about 2 per cent at twelve months. Elliott and Tuckett (1906) found great differences in the relative volume of the medulla in the guinea pig, rabbit and cat, as much as 14 per cent of the whole adrenal body in a young guinea pig and as little as 1 per cent in an old one. For the cat and rabbit the values were between these extreme limits. Donaldson (1919) found in albino rats a variation from 13 per cent to 6 per cent. The relative volume decreases rapidly from birth to puberty and then remains practically stationary. Among mammals the guinea pig is pre-eminent in the great development of the suprarenal body relatively to the body weight, but this is due mainly to the great development of the cortex. The medulla, according to Elliott and Tuckett (loc. cit.), is slightly less in proportion to body weight than that of the dog, both, however, being high for mammals. In adult rabbits the average weight of the two adrenals is about $\frac{1}{6}$ gm. adrenal to 1 kgm. body weight. In 140 dogs, Stewart and Rogoff (1919*b*, 1923; Rogoff and Stewart, 1926*b*, *c*, 1927) found the ratio $\frac{1}{7}$ gm. adrenal to 1 kgm. body weight. For over 100 cats Stewart and Rogoff (1923) found the ratio $\frac{1}{6.6}$ gm. adrenal per kilogram of body weight. In German soldiers, killed in the war, the average weight of the adrenals, according to Röszle (1919), was 14.1 gms. This would give a ratio to body weight about the same as that in the laboratory animals mentioned.

From the above it follows that the adrenal medulla, although a small portion of the whole gland, may often contain enough of the chromaffin inclusion to amount to $\frac{1}{5}$ mgm. of epinephrin per kilogram of body weight in rabbits (Stewart and Rogoff, 1921). The epinephrin base may constitute

as much as 1 per cent of the moist weight of the medulla, sometimes much more than this, as in adrenals hypertrophied after thyroparathyroidectomy in rabbits (Stewart and Rogoff, loc. cit.). This is of the order of magnitude of the glycogen inclusion in a liver moderately rich in glycogen, and fully justifies the term "massive" which was applied to it above.

The epinephrin is discharged into the blood. The earliest observation was that of Vulpian (1856) who found that the greenish color given in sections of the medulla by ferric chloride was also sometimes obtained in the adrenal vein blood, although the nature of epinephrin was not yet known at that time. More recent work has demonstrated by better methods that the output is continuous, at least under experimental conditions, amounting to an average of 0.0002 mgm. per kilogram of body weight per minute in dogs and cats under ether and a little more (0.00025 mgm. per kilogram per minute) when the animals are under urethane (Stewart and Rogoff, 1923). With sufficiently sensitive methods of testing for epinephrin in the blood of the suprarenal veins a reaction is invariably given by the venous blood leaving the glands (Stewart and Rogoff, 1916*c*, 191–*b*, *d*). It is not known exactly to what extent the liberation of epinephrin into the blood is due to the actual passage of chromophile granules out of the cells, nor indeed in what degree the already stored epinephrin contributes either to the ordinary steady output, or to the greatly increased output (up to twenty times the normal, or even more) occasioned by stimulation of the peripheral end of the splanchnic nerves. For it is difficult to demonstrate a diminution of the epinephrin store even after prolonged excitation of the splanchnic, and a diminution of the depth of the chromium reaction has not been satisfactorily demonstrated at all. In this case it is obvious that stimulation of the secretory nerves must cause speeding up of the formation of epinephrin as well as of its discharge. During excitation of the splanchnics the concentration of epinephrin in the arterial blood rises high enough to provoke distinct, in some cases marked, physiological reactions.

But the ordinary output is too small to permit epinephrin to be detected in the arterial blood on account of the great dilution which it undergoes, probably to something like 1 to 1,000,000,000. The reactions caused are correspondingly insignificant. Despite this fact the discharge of epinephrin from the medulla and the strict regulation of this discharge by the nervous system are phenomena of great interest, for there is no other instance of a specific product of an endocrine gland which can be followed in the blood and estimated there, and the rate of whose liberation can be clearly proved to be under the control of the nervous system. Compare, for instance, the active substance of the thyroid, the parathyroid, the islets of Langerhans (insulin), the "hormones" of the sex glands, or the active substance of the infundibular lobe of the pituitary body; in no case can we detect them in the blood; in no case is it demonstrated that their liberation is controlled

by nerves. It has been said that during stimulation of the splanchnic there appears to be an acceleration of the process of formation of epinephrin in the suprarenal medulla. It is, however, a fact of equal, perhaps greater interest, that it can be and possibly is ordinarily built up without the control of nerves.

This was first shown by Elliott (1912). He divided the nerves coming to one celiac ganglion. The epinephrin store, which is at first diminished, is reaccumulated in a day or two, becoming approximately equal to that of the sister gland which has retained its innervation. This has been confirmed by Stewart and Rogoff (1916*a*) (who, in some cases, find the store in the denervated gland even surpasses, temporarily, that of its fellow), and by subsequent workers. Only Fujii (1924) states that in some of his animals equality of the load was not attained. It must be remembered, in this connection, that edema of the adrenal is easily produced, in rabbits, by operations for denervating the organ and that an edematous gland, unlike a hypertrophied gland which it may resemble superficially, is not only unable to accumulate chromaffin material (or epinephrin) but quickly loses whatever store it possesses. Only when the edema disappears does the medulla again fill up with epinephrin.

When an animal with one gland denervated is subjected to the action of anesthetics such as ether, urethane, chloroform or morphine, a depletion of the epinephrin store in the still innervated gland occurs and goes on increasing for several hours while the denervated gland is "protected" against this depletion and does not lose any part of its epinephrin, so that at the end of a few hours it may have several times as much epinephrin as its fellow and show a correspondingly more intense chrome reaction. Most writers have assumed that whenever the store is diminished the output must have been increased. But while some of the drugs which cause the epinephrin to disappear can be shown to accelerate its liberation into the blood (e.g., morphine in the cat, though little if at all in the dog), others have no such accelerating effect (e.g., ether), and there is another group of substances (e.g., strychnine) which greatly augment the rate of output but do not affect the store (Stewart and Rogoff, 1919*a*, 1922*a*). According to Kodama (1924) chloroform even diminishes the rate of liberation. The most probable explanation of the diminished store, at least in the case of substances which do not increase the rate of output, is that the upbuilding of the epinephrin or its storage as chromaffin granules is interfered with. In the gland whose nerves are intact this must lead to deficiency in the store since the output into the blood goes on unchanged. The deficits actually observed are of the order of magnitude which would be created in several hours if epinephrin left the gland at the ordinary rate while the rate of formation was reduced to half or less of the ordinary rate. In the denervated gland, since no epinephrin is being given off, the store does not diminish.

One of the most interesting methods of causing depletion of the epinephrin store, and of the chromaffin material, is piqûre of the floor of the fourth ventricle, in the region of the so-called sugar puncture of Claude Bernard. The adrenal is unaffected if its nerves are cut (Kahn, 1911). It has therefore been assumed that the epinephrin is liberated in the same way as when the splanchnics are stimulated. As already mentioned, however, there is this difference, that in splanchnic stimulation it is difficult to demonstrate any diminution in the store, while the rate of liberation of epinephrin is increased many times. It would seem, therefore, that piqûre does not act precisely in the same way as electrical stimulation of the splanchnic. Emotional disturbances, although intense and prolonged, as in the case of a dog with one adrenal denervated trying for hours to worry a cat similarly operated upon and protected by a small cage from physical injury, have no effect whatever upon the epinephrin store of the still innervated gland as compared with that of its denervated fellow.

The question may be asked, why does the accumulation of epinephrin stop in the denervated gland when the original amount, or what comes to the same thing, roughly speaking, the amount in the sister gland, is reached? This has a bearing upon other inclusions than the chromaffin granules, e.g., the colloid of the thyroid, which, so far as is known at present is built up and discharged without the intervention of the nervous system. It must be assumed that further formation of epinephrin in the denervated gland practically ceases; since if there is any "spill" into the blood it is so small as to be below the limit which can be detected by sensitive test objects, even by rabbit intestine segments proved to be capable of detecting concentrations of epinephrin corresponding to one-thousandth of the ordinary output.

That the medullary cells in the absence of nervous control should still continue to form epinephrin and to store it as chromophile granules till the ordinary store is replenished is in no wise inconsistent with the view that the secretory nerves constitute a "quick-charging" mechanism for epinephrin formation, and that when the output of epinephrin into the blood is accelerated through the nervous system the mechanism which speeds up its formation is stimulated at the same time. How the limit is determined to which the epinephrin store, or the total mass of the chromophile granules, can increase when a given mass or volume of medullary tissue is "loaded up" remains obscure, but not more obscure than in the case of other inclusions, like the thyroid colloid or even the liver glycogen. It is easy to say, and quite true, that the store constitutes the balance when the quantity given off is deducted from the quantity formed. But that does not explain how in the denervated gland the store comes right up to its initial value or to that of the companion gland and there remains approximately constant. It is not that the cells can only carry a definite maximum amount of the chromophile inclusion determined by their size and the physico-

chemical structure of their cytoplasm, and that they fill themselves up to this limit and then stop making more epinephrin, for there is considerable variability in the load calculated on the mass of the gland in different individuals of the same species living under apparently identical conditions. How much of the variation may be due to differences in the relative mass or volume of medulla and cortex in the different individuals is unknown. It has been ascertained, however, that in hypertrophy of the gland, at least in certain kinds of hypertrophy, the epinephrin store increases in proportion to the size of the whole suprarenal body, so that it constitutes the same percentage of the weight of the hypertrophied gland as of the normal gland. Thus Stewart and Rogoff (1921) found in the adrenals of twenty-five rabbits, from which the thyroids and the whole or the greater portion of the parathyroids had been removed by Dr. Marine, an epinephrin content of almost exactly 1 mgm. per gram of adrenal. The weight of the adrenals per kilogram of body weight was 60 per cent greater than in a series of normal rabbits whose average body weight was 10 per cent greater than that of the thyroparathyroidectomized rabbits. In the hypertrophied glands the epinephrin had accordingly increased precisely in proportion to the increase in the combined weight of medulla and cortex. Whether this was due to hypertrophy of the medulla occurring in exactly the same degree as that of the cortex or to an enhanced store of the chromophile inclusion being created in the medullary cells without any corresponding augmentation of their size or number (perhaps under the stimulus of an increased blood supply) is unknown. Indeed, the possibility of hyperplasia and hypertrophy of the medullary cells is still the subject of discussion.

If it were definitely shown that hypertrophy or hyperplasia of the cortex is associated with a corresponding increase in the load of epinephrin in the gland, in the absence of increase in the volume of the medulla, it might be considered as favorable to the theory previously alluded to, that the cortex takes a share in epinephrin production or is intimately associated with the function of the chromaffin material, as maintained by certain authors. The demonstration, however, is not by any means sufficiently complete to be used for this purpose.

1. *Functional importance of the epinephrin inclusions:*

It has been mentioned already that the proof of liberation of the epinephrin into the blood under the influence of the splanchnic secretory fibers is complete. The granules may even, under certain conditions, be discerned with the microscope in the sinuses and central vein. Of course, the probability that this might occur in the manipulation of the gland or in the sectioning must be considered, as it is easily demonstrated that massage of the adrenal during life causes a greatly increased epinephrin output (Stewart and

Rogoff, 1916*b*). Readers who peruse the literature without critical knowledge might easily conclude that the epinephrin has a great functional importance. Many writers assume this as self-evident or at any rate fully proved (Sharpey-Schafer, 1924). The most convincing evidence that the epinephrin secretion does not play an indispensable rôle is the fact that animals in which the epinephrin output has been suppressed or the medulla destroyed remain indefinitely in good health. This is true of many rabbits and rats even when the whole of both adrenals is taken away. Dogs often survive complete adrenalectomy for a week or more in good health. If, as is sometimes stated, the chief part of the chromophile system is outside of the adrenals, in the dog, for example, we should expect removal of the adrenals to have little, if any, effect upon the animal if the loss of the adrenal medulla is the important thing. Yet in no animal hitherto investigated is the complete removal of the adrenals more uniformly fatal than in the dog (Rogoff and Stewart, 1926*b*, *c*, 1927). It is frequently assumed, from the well-known pharmacological reactions of adrenalin, that the chromaffin inclusion of the adrenal medulla plays a rôle in the maintenance of the normal blood pressure. It has been measured in rabbits and dogs by van Leersum's (carotid loop) method (Rogoff and Dominguez, 1924; see also Rogoff and Stewart, 1927) before and during removal of the first adrenal, then up to and during removal of the second gland and then on till recovery or death. No change in the blood pressure was found which could be attributed to loss of the adrenals. If it be argued that this is due to the extracapsular chromophile tissue, relatively abundant in the dog, it may be answered that rabbits, which are not specially endowed in this way, behave like dogs as regards the blood pressure after adrenalectomy. This is true whether they survive indefinitely or only some weeks. It has been shown (Stewart and Rogoff, 1922*b*) that animals (dogs, rabbits, rats, cats) deprived of the adrenals, or with epinephrin liberation interfered with, are no more susceptible to such influences as fatigue than normal animals. In the case of rats their observations confirm the older ones of Boinet (1895). Statements to the contrary like those of Hartman, Waite and Powell (1922) are due to inadequate check experiments or to the use of animals operated on with inadequate technique or used before recovery from the operation was complete.

Swale Vincent (1925*a*) has made the interesting observation that the chromophile reaction in rats' adrenals is much reduced if the animals are exercised at room temperature (14° or 15°C.), the body temperature falling, whereas at 18° to 20°C. the body temperature neither rises nor falls and the chromophile reaction is unaffected. If they are exercised at higher temperatures their body temperature will rise and the chromophile reaction will not be reduced. It is apparently not the fatigue but the fall of internal temperature which is associated with the change in the intensity of the

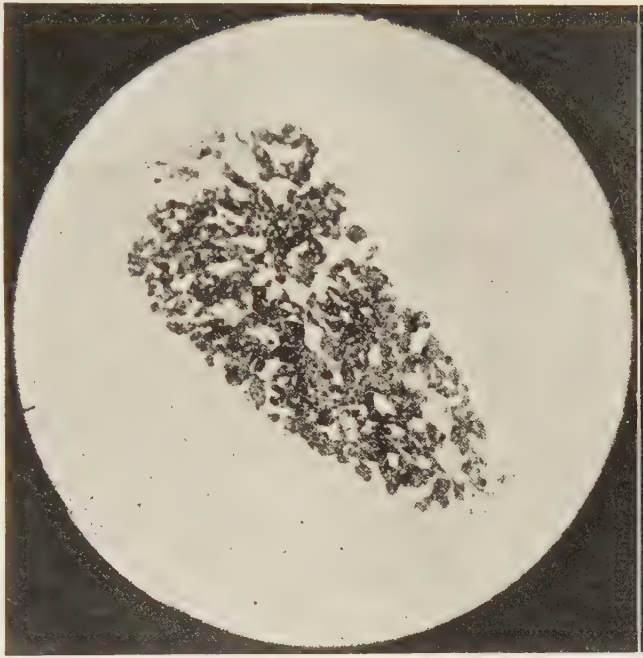

FIG. 273.—Photomicrograph of a section through the adrenal body of a normal rat, fixed in formol-Müller. The medulla only is shown (by its chromophile reaction). × 40. (After Swale Vincent, 1925.)

FIG. 274.—Photomicrograph of a section through the adrenal body of a rat, excised at room temperature, whose body temperature fell from 35.8°c. to 33.8°c. The chromophile reaction is reduced except in patches. × 40. (After Swale Vincent, 1925.)

chromophile reaction. The reduction in the reaction is generally manifested as a complete or almost complete disappearance of the chromophile stain from certain groups of medullary cells and not as a general reduction in the brown or yellow tint (Figs. 273, 274, and 275). There is no evidence whether the diminution in the total mass of the chromophile inclusion is due to increased liberation or to diminished formation. Like changes

FIG. 275.—Photomicrograph of a section through the adrenal body of a rat excised at 18°C. There was no fall of body temperature, and the chromophile reaction is normal. × 40. (After Swale Vincent, 1925.)

produced by certain toxic agents the diminished epinephrin load may be due to a physico-chemical change in the medullary cells which is unfavorable to the formation of colloidal compounds of epinephrin. It has already been mentioned that in edema of the suprarenals, especially in rabbits, a marked diminution or even complete disappearance of the

FIG. 276.—(A) Normal suprarenal of rabbit. Zenker fixation. Junction of medulla and cortex. × 490. (B). Suprarenal of a rabbit which died two hours after injection of 80 mg. T. H. N., hyperpyrexia 44°C. Zenker fixation. Junction of medulla and cortex. This figure gives the picture of an actively secreting gland obtained by ordinary fixatives, and duplicates the appearances usually seen in human postmortem material. × 620. (After Cramer, 1919.)

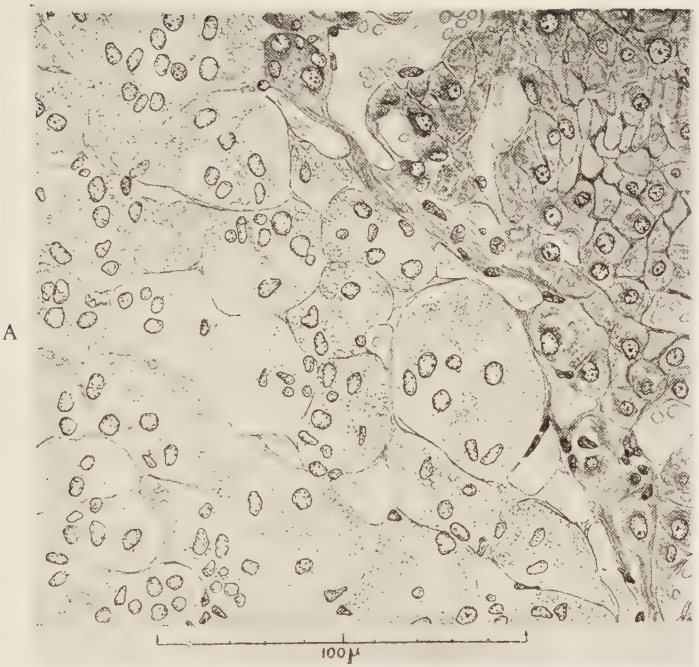

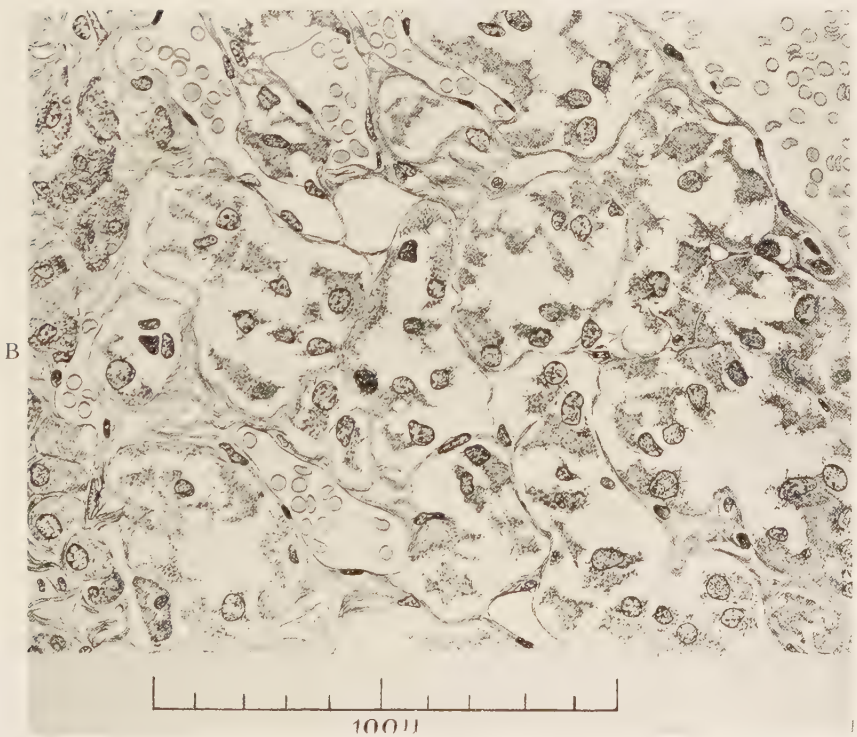

FIG. 276.—(See p. 634 for caption.)

epinephrin store occurs, the water-logged gland being apparently unable to form or to retain the chromophile inclusion.

The apparent relationship between the lowering of the body temperature and diminution of the chromophile reaction, whatever may be its significance, has been accepted by some writers as evidence in favor of the theory that the adrenal medulla, presumably in virtue of its output of epinephrin, plays a part in the regulation of the body temperature. Cramer (1916, 1919, 1926*b*) especially has elaborated this theory. The histological studies made by him in certain diseases such as Graves' disease, in certain bacterial infections such as gas gangrene, streptococcal septicemia and diphtheria, and after the action of certain sympathomimetic drugs as β-tetrahydronaphthylamine, and in other ways, are interesting, but it is impossible at present to attach a definite physiological meaning to them. While it may be true that a drug like β-tetra may cause a diminution in the chromphile inclusion in the medulla (Fig. 276), and that this may be due to increased liberation of epinephrin, several steps remain to be taken before this can be linked up with the disturbed heat regulation responsible for the β-tetra fever. A hyperpyrexia at least as great is produced by morphine in cats. The diminution in the chromophile inclusion is as great, and definite measurements of the epinephrin output have shown that the liberation of epinephrin is increased (Stewart and Rogoff, 1922*a*). Yet it has been proved that in cats whose epinephrin output has been suppressed by a previous operation (removal of one adrenal, curetting of the medulla of the other, accompanied by section of its nerves) the hyperpyrexia is produced all the same, follows the same course and reaches as high a maximum (Stewart and Rogoff, 1922*c*). It is therefore impossible to accept the conclusion that the adrenal medulla, either by itself or in conjunction with the thyroid, constitutes an important heat-regulating mechanism. In dogs after total removal of the adrenals there is no evidence that the heat regulation is disturbed in the least during the period of good health. Often, indeed, the rectal temperature remains normal up till death. It never varies beyond the normal limits during the period of general good health. If in some of the animals it is found to be subnormal, this is only during the last day, or occasionally two days of the survival period, when the fatal symptoms are developing.

The appearances which Cramer (1926*a*) accepts as proving the existence of a self-regulation of the epinephrin formation and liberation by the medulla need not be discussed at length here. He states: "After an injection of adrenalin, the peripheral cells of the medulla—those immediately adjacent to the cortex—lose their adrenalin (see Fig. 274) [Fig. 277]. They thereby lose the typical appearance of medullary cells, and may be mistaken for cells of the cortex. At first sight this gives the impression as if the zona reticularis had hypertrophied enormously at the expense of the medulla,

which appears much smaller than in the normal animal. It is obvious that in the few minutes which have elapsed since the injection of adrenalin no such hypertrophy can possibly have taken place, and closer inspection reveals in this broad zone islets of typical medullary cells still filled with granules of adrenalin (Fig. 277). Figure 278 gives a high-power view of this zone. In some parts these groups of cells are still connected with the medulla and project like peninsulas into this zone. This broad zone therefore belongs to the medulla, and is composed of medullary cells which have lost their content of adrenalin in varying degrees. An adrenalin-free zone of the

FIG. 277.—Adrenal of mouse twenty minutes after injection of 0.015 mg. adrenalin, × 66. Shows appearance of adrenalin from peripheral parts of the medulla—"self-control." The right-hand side of the dotted square still lies inside the medulla. (After Cramer, 1926.)

medulla has thus been interposed between the cells of the zona reticularis of the cortex and the adrenalin-containing cells of the medulla as the result of the injection of adrenalin. The formation of such a zone is interpreted as interfering with the interaction of cortex and medulla, which is essential for the normal functional activity of the gland. It is the morphological manifestation of the check which the gland imposes upon itself in this condition, and by which it protects itself against self-exhaustion. We propose to call this phenomenon 'self control' of the adrenal." Not till evidence of a different kind has been obtained can these microscopic appearances be properly appraised. By themselves they settle little or nothing.

The same is true of the supposed evidence that the cortex is concerned in the formation of the epinephrin inclusion. Cramer states that redistribution of the lipoid inclusions in the cortex is associated with increased formation of epinephrin in the medulla. Lipoid accumulates especially in the zone of cortex near the medulla (zona reticulata). He even goes so far as to say

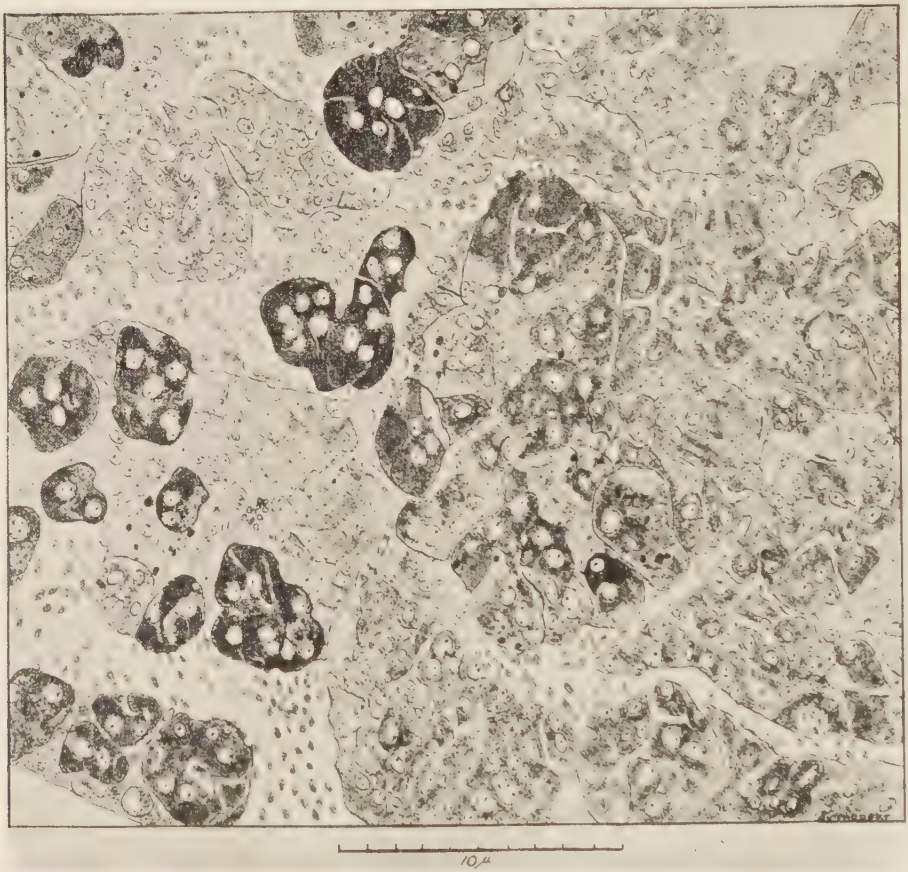

FIG. 278.—High power view of the area enclosed in dotted square shown in Figure 277. × 740. (After Cramer, 1926.)

that when no lipoid is present in the cortex no epinephrin can be formed in the medulla. But this hypothesis is at variance with the fact that epinephrin is formed in the chromophile tissue of those fishes whose interrenal tissue, corresponding to the mammalian cortex, forms a separate organ; also in the extracapsular chromophile tissue of mammals, including such organs as the abdominal chromophile body or paraganglion, and in the scattered chromophile cells in sympathetic ganglia. These remarks are not intended

in any way to belittle the importance of Cramer's histological studies which objectively viewed are admirable. The difficulty, however, of interpreting microscopic changes in terms of functional changes is usually great, exceptionally so in the case of the adrenals, and we are unable to accept his interpretation of the cellular changes. The method employed by him consists of exposing thin slices of adrenal, enclosed in a wet gauze bag, and suspended at 37°c. for one and one-half hours in a closed tube containing some 2 per cent osmic acid solution. The tissue is then transferred to 50 per cent alcohol, passed through the alcohols and imbedded in paraffin. The osmic acid reaction of the medulla was first described by Mulon (1905*b*), (see also T. and A. Ogata, 1917).

In various infections changes are to be found in the adrenals, sometimes in the medulla, sometimes in the cortex, sometimes in both. Perfect unanimity as to the extent and localization of the changes has not been reached. Their interpretation is difficult. It by no means follows that the adrenal has a special relation to an infection because it undergoes changes in its inclusions. It must be shown that in the absence of the adrenals, or of the medulla alone, the susceptibility of the animal, or its immunity reactions are altered. Hardly ever has this been done satisfactorily. Thus Lewis (1921, 1923) states that white rats, deprived of their adrenals, succumb to as little as $\frac{1}{400}$ to $\frac{1}{500}$ the minimum lethal dose of morphine for the normal animals. Scott (1923) has repeated the statement, although his own results show clearly that no such difference exists. Stewart and Rogoff (1922*c*) and Rogoff and De Necker (1925) have shown conclusively that the statement made by Lewis is based upon erroneous interpretation of observations made on animals operated upon by an inadequate technique and often moribund at the time the minimum lethal dose of morphine was being determined. That morphine causes the total amount of the epinephrin inclusion to decrease has no bearing upon the question. For it has not been proved that this change has any functional significance. Most observers who have seen a decrease of the chromic acid coloration, or a diminution in the epinephrin content of the adrenals as determined colorimetrically, or in other ways, have assumed without discussion, not only in the case of morphine but of many other substances, that this is due to increased liberation of epinephrin into the blood. There is another alternative just as likely; namely, that the formation of epinephrin is interfered with by the poison, while the discharge goes on at the ordinary rate. In the dog, for instance, it is doubtful whether morphine accelerates the rate of discharge, although it does so in the cat, but the amount of the inclusion is markedly diminished in both animals. Many writers have described changes in the amount of the epinephrin inclusion produced by bacterial toxins, such as diphtheria or tetanus toxin, and it has been claimed that the resistance to such toxins is markedly diminished when animals are deprived of their adrenals. Rogoff and Ecker

(1926, 1927), however, show that the tolerance of white rats, after adrenalectomy, to tetanus toxin is no less than in unoperated control animals.

2. *Pigment:*

In addition to the chromaffin granules, clumps and granules of blackish pigment with no affinity for chromic acid are not uncommon constituents of cells in the medulla, especially, it is said, in old age. Pigment granules may also be present in the zona reticulata of the cortex. The significance of these pigment inclusions is quite unknown. Interest has been attracted to them, especially among pathologists, because of the classical symptom of bronzing of the skin in Addison's disease, suggesting the existence of a connection between the adrenals and melanin formation. Whatever the explanation of the abnormal deposit of pigment in the skin in some cases of Addison's disease may be, no experimental foundation exists for the view put forward by Adami (1908) that it is due to a transformation of the precursor of epinephrin (e.g., tyrosin) no longer transformed into adrenalin in the medulla. Animals in which total adrenalectomy is fatal (e.g., cats, dogs, monkeys) have been found to live indefinitely, in good health, after suppression of the epinephrin output, or extirpation of the medulla (Stewart and Rogoff, loc. cit.; Houssay and Lewis, loc. cit.). In such animals no pigmentation of the skin or mucous surfaces has been seen. The same is true of dogs which have been kept alive in various ways for as long as two months after total adrenalectomy (Stewart and Rogoff, 1925*a*, *b;* Rogoff and Stewart, 1926*a*, 1927).

II. CORTEX

The most characteristic inclusion of the cortical cells consists of fat-like or so-called lipoid granules or droplets of different size. Many of the droplets are birefringent and stand out in the dark field of the crossed Nicols. The doubly refractive material appears to consist of cholesterin esters (Aschoff, 1910), probably associated with lecithin. The existence of the birefringent lipoid in the adrenal cortex was first pointed out by Orgler (1898) and by Kaiserling and Orgler (1902). Elliott and Tuckett (1906) described the distribution of this lipoid in various animals in health, and its loss in disease. In addition to the anisotropic lipoid the cortical cells contain inclusions of isotropic fatty material. Elliott and Tuckett consider that there is practically no difference in the distribution of the fat-like and lipoid substances throughout the thickness of the cortex. According to them the old distinction of the three zones of cells in the cortex, glomerulosa, fasciculata and reticulata, which was made by Arnold (1866) from anatomical studies in reference to the disposition of the cells and blood vessels in the ox and in man, cannot be applied universally to any mammal, and should be dropped.

That fundamentally the cortical cells are all alike is held by Bonnamour (1905), Mulon (1905*a*), and Bogomolez (1905). However, that is not the opinion of some recent workers (N. Goormaghtigh, 1922*a;* A. C. Da Costa, 1913), who even differentiate in the fasciculata a deep layer and a much thicker superficial layer (layer of the spongiocytes or spongy layer). These distinctions are based on the nature and size of the inclusions and the way in which they vary under different conditions, and appear to indicate a real morphological difference. Everyone admits in reality some differences in the different zones of the cortex, e.g., the tendency of pigment inclusions to be found in the layer next the medulla (juxtamedullary zone or deepest part of the reticulata).

Elliott and Tuckett (loc. cit.) state that pigment in the cortex is present almost exclusively in the guinea pig. The pigment granules are deprived of their color by mercuric chloride and are insoluble in ordinary reagents. Left in water for two or three days the granules swell and color all the cell. Rabl (1891) describes the occasional occurrence of pigment in the outermost cortical strands, in the pigeon. According to Elliott and Tuckett (1906), Fuhrmann (1905) maintains that the cortical granules of the guinea pig are identical with those of the medulla. Da Costa (1913) states that pigment granules do not exist in all animal species but are almost constant in the reticularis in man and are found abundantly in the guinea pig. He quotes Ciulla (1909) who finds that pigment granules are absent at birth and increase with age and in pregnancy. According to Da Costa the presence of the granules is probably a phenomenon of cellular pathology, and he thinks, as does Mulon, that in some cases the degenerated cells desquamate into the capillaries. The composition of these granules is uncertain. Mulon (1903) has described the presence of fat, lipochrome and iron. This has been denied by Diamare (1905), Bonnamour (1905), Moschini (quoted by Da Costa, 1913), and Ciulla (loc. cit.). Some pigmented granules stain intensely black with iron hematoxylin, while others (few) resist this coloration.The large majority of these granules stain black in osmic acid after passage through alcohol. Xylol does not alter the stain.

Landau (1915) states it is generally known that the pigment of the reticularis, in man, is absent in the first twenty years of life. The pigment that is present in the inner layers of the cortex in infants is entirely different and comes from hemorrhage of the degeneration period. Landau believes that it is an "Abnützungsprodukt" of cellular activity and that it has nothing to do with the function of the adrenal cortex. The degeneration reaches a maximum toward the end of the first month of life. Considerable variations exist in regard to this. During this period hemorrhage and fusion occur in the inner layer. The physiological degeneration spoken of by Landau is not present in other mammals investigated. Da Costa (1913) cites Gottschau (1882, 1883), Soulié (1903*a*, *b*), Mulon (1905*a*) and others who

believe the glomerulosa to represent a germinal layer from which evolution of the cortex would be centripetal. He also mentions a statement by Dsershinsay that the cells of the reticularis are the oldest of the cortex and that pigment there is a sign of old age. Tuczek (1914) believes that lipo-

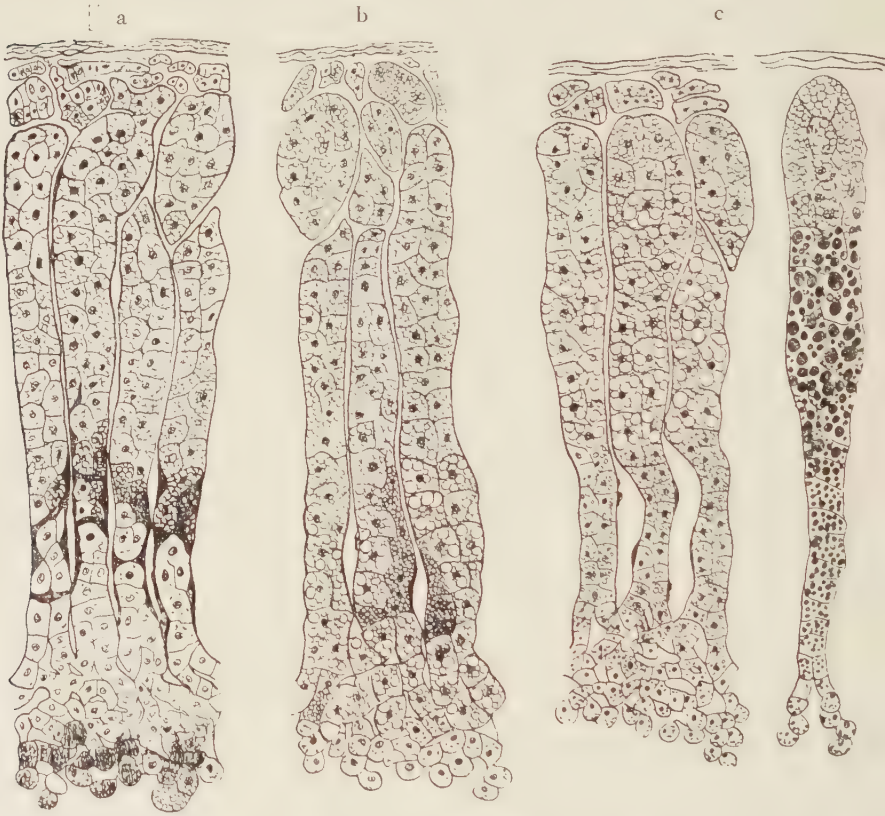

FIG. 279.—a, Normal human adrenal (schematic). b, Adrenal from case of intraperitoneal hemorrhage (schematic), showing considerable enlargement of the spongiosa which occupies all the thickness of the cortex with the exception of a narrow juxtamedullary layer. c, Adrenal from a case of penetrating wound of the abdomen, with hemorrhage and infection, showing a thinning of the inner half of the spongy cords, interpreted as passage of lipoid into the circulation. The fat has become "indélébile" in almost the whole thickness. (After Goormaghtigh, 1922.)

fuscin is a product of old age and that the cortical pigment is an "Alterspigment." Hueck (1912) suggests the use of the term lipofuscin (used by Borst) to designate the cortical pigment instead of lipochrome which has been employed as a botanical term to identify substances which turn blue when treated with concentrated sulphuric acid.

According to Goormaghtigh (1922*a*), who worked with fresh material obtained during the war, the structure of the human adrenal cortex is described as follows (Fig. 279a): proceeding outwards from the medulla is the narrow juxtamedullary layer which constitutes about one-eighth of the total thickness of the cortex. This consists of monocellular cords, irregular and anastomosing between the blood capillaries and presumably the lymphatics, forming a well-developed network. The characteristic inclusion in these cells is stained by osmic acid (osmophile), and in man, though not in all animals, pigmented. The mitochondria there assume the shape of small balls—plastes of Mulon (1912)—packed close to one another. Some of them resist all methods of coloration. The large majority reduce osmic acid and are colored intensely black by iron hematoxylin. These plastes, which Guieysse (1901) and Ciaccio (1903*a*) compare (without physiological basis) to zymogen granules, are not found in the other zones of the cortex. In man many of them become charged with a brownish-yellow pigment, and assume an irregular shape. These pigmented osmophile granules arrange themselves, in anastomosing cords, in the shape of a crescent or ring, leaving free from the inclusions a relatively large portion of the cytoplasm. As a result of their close packing together a large part of the exoplasm remains free from granules and appears sometimes clear, sometimes dark with non-osmic fixatives. The black osmic stain is not altered by xylol and very little by turpentine. Goormaghtigh, and others, consider the changes in the inclusions of this layer as an expression of secretory activity, but as previously mentioned, Da Costa believes it to be a pathological process. It appears preferable, therefore, in the present state of our knowledge, to leave this an open question.

Superficial to the juxtamedullary zone is a somewhat thicker zone. The deep part of this zone consists of reticulated cords of cells corresponding to the superficial part of the zona reticulata, while the superficial part consists of cells arranged in approximately parallel columns corresponding to the deep layer of the zona fasciculata. A well-defined type of cell predominates and gives a special character to this cortical zone. It is a polyhedral turgescent cell, whose pale protoplasm appears finely granular with all fixing agents. Beside the nucleus, containing a number of nucleoli, is the attraction sphere, consisting of two central bodies surrounded by a clear layer. Granules, of mitochondrial nature, variable volume, with angular contour, are scattered through the cytoplasm. They are colored blue by iron hematoxylin while other, punctiform granules, less numerous, reduce osmic acid. There are no lipoid droplets in these cells, and this is, according to Goormaghtigh, the characteristic feature of their morphology.

The superficial parts of this zone are characterized by the presence of a new type of cell, the siderophile cell of Ciaccio (Fig. 280). These cells were studied by Ciaccio (1903*a*) who found them in the guinea pig (abundant),

in the rabbit (finely granular) and in man (coarsely granular) in the deeper layer of the fasciculata. According to Colson (1910) the siderophile elements were described by Guieysse (1901) who found them in the guinea pig. From histological studies made on guinea pigs, treated with toxin-antitoxin mixtures, Goormaghtigh (1922*b*) concludes that the siderophile body is not a permanent element of the adrenal. It represents a stage of the secretory cycle. From its staining qualities it appears closely related to lecithin. He believes that it passes into the blood. These siderophile cells, of elongated form, often remain attached to each other and form strands in the surface

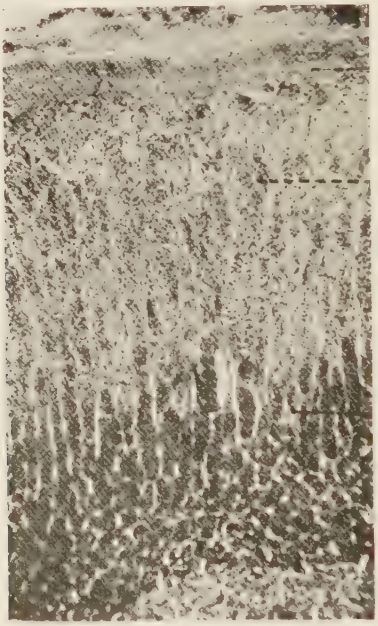

FIG. 280.—Section of normal human adrenal from a case of perforating wound of the lung. Zenker fixation, iron hematoxylin. Pale zone, spongiosa; deep (dark) zone, fasciculata and reticulata. (After N. Goormaghtigh, 1919.)

of a cord of the pale cells. In these elongated cells, compressed by the pale, turgescent cells, the mitochondria seem compressed against each other. Whether they liquefy, as Mulon (1910*b*) has supposed or not, the protoplasm becomes intensely siderophile (Ciaccio, 1910; Mulon, 1910*a*, Colson, 1910, Da Costa, 1913) and osmophile (Mulon, 1910*a*). According to Goormaghtigh the secretory activity in this zone manifests itself by the appearance of very regular small inclusions (enclaves) disseminated among the mitochondria. The black color imparted to them is permanent even for years in preparations mounted in xylol-balsam. This stability is characteristic of the inclusions in the siderophile cell (Da Costa, 1913; Goormaghtigh, 1922*a*).

In the neighboring cells of the next most superficial zone, the so-called spongy zone, and in those which form part of the strings of elongated cells running into the deep layer of the spongy zone these inclusions become more and more numerous as we pass outwards. The mitochondria diminish in number; the siderophilia of the inclusions disappears and the inclusions lose their power to retain the osmic stain. According to Colson (1910) and to Goormaghtigh (1922*a*), it is permissible to conclude from a study of the changes in the inclusions of these cells that the mitochondria play a rôle in the formation of the inclusions and that these are the result of the secretory properties of the protoplasm. If this is so, they point out, the siderophile cells take an important part in the genesis of the lipoid in the suprarenal. At present this can only be termed an interesting speculation.

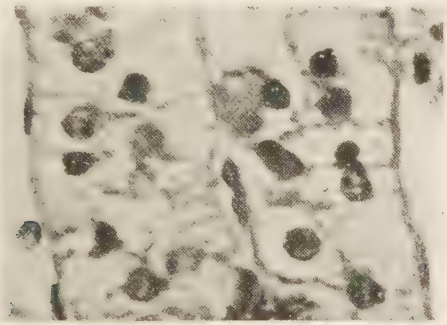

FIG. 281.—Section of normal human adrenal, showing spongy layer. Immersion lens. (After Goormaghtigh, 1919.)

The third zone in the cortex (in the adult human being) proceeding outwards from the medulla is the spongy zone. It occupies about two-thirds of the total thickness of the cortex. The thin juxtamedullary zone, as already stated, takes up no more than one-eighth of the thickness of the cortex and the zone external to it, which has just been described, only a little more. The spongy zone, in preparations which have not been treated with osmic acid, contrasts by its transparency with the darker deep zones. It is formed of characteristic cells, the spongiocytes (Fig. 281). In contrast to the cells of the zone just dealt with, the siderophile material is reduced in amount and its place taken by numerous lipoid droplets of approximately equal size. Thus the cytoplasm, reduced to a fine colorless trellis-work, poor in mitochondria, takes on the aspect of a sponge. The lipoid differs from that in the siderophile cells of the previous zone. The black color imparted to it by osmic acid is not permanent but disappears in Canada balsam. It is a "labile" lipoid (Bernard and Bigart, 1902*a*, *b*, *c*) and is markedly birefringent. In addition, however, some small punctiform granules like those in the previous zone are seen. The cells of the spongy zone are grouped in the

long parallel cords associated with the zona fasciculata, and become thicker as the surface of the organ is approached. Da Costa (1913), referring to the great solubility of fat droplets treated by osmic acid, quotes Plecnik (1902) who found that the suprarenal fat does not stain black by osmic acid unless it is previously treated by passing through alcohol. This observation was confirmed by Mulon. According to Colson (1910) the intensity of the dark coloration by osmic acid and the rapidity with which this black stained fat disappears in solvents such as xylol or turpentine depends in a large measure upon the duration of the reaction. In the bat he was unable to find any labile fat by fixing for eight days with Fleming's or three days with Hermann's fluid. However, fixing for a few hours or a day he was able to demonstrate a sort of "graisse labile" in different portions of the cortex. The very thin superficial layer, immediately under the connective tissue capsule (zona glomerulosa), consists of slender cords made up of clear and darker cells with some spongiocytes containing small vacuoles.

The lipoid inclusions constituting the most striking cytological feature of the cortex, it is natural that much work should have been devoted to the study of their microchemical, particularly their staining reactions. The characteristic anisotropic lipoid material has especially attracted attention. By comparing the appearances of the different zones under varying physiological and pathological conditions, theories connecting the changes in the inclusions with supposed secretory phases of the cortex have been developed by a number of writers. As already stated, we prefer at present to abstain from any functional interpretation of the appearances, all the more since considerable differences occur in the descriptions of different observers and in different animals. This of itself would not be inconsistent with the view that different phases in a process of elaboration and secretion of lipoids into the blood are related to the changes in the cortical cells, and indeed would agree very well with it. But while the lipoid inclusions constitute extremely interesting objects under the microscope, the absence of any real proof that they are passed into the blood, and the great probability that the cortical function is not essentially under the control of the nervous system, since it goes on when all nerves to the adrenals are cut as completely as possible, render it far more difficult to study their formation and fate than in the case of the epinephrin inclusions in the medulla.Yet the latter, as has been seen, highly characteristic as they are in the microchemical reactions, exactly controlled as to their discharge by the nervous system, are yet of little, if any, physiological importance. It may be the same with the cortical lipoids. If the cortex manufactures and discharges a substance of great importance, perhaps necessary for life, it may not be a lipoid at all but a protein, or a complex with a protein element.

However this may be, it is obviously important to study the physical and chemical properties of the various inclusions, especially their behavior

in polarized light and their reactions to stains. It is noteworthy that the birefringent substance is mainly confined to the spongiocytes and therefore to the so-called zona fasciculata. Elliott and Tuckett (1906) are of the opinion that, although of importance in most animals, neither the fat nor the doubly refractive substance are to be regarded as fundamentally essential to the activity of the cortex of vertebrates, for neither appears in the normal cortex of the sheep. They state that "of the secretory products of the cortex the fat must be clearly distinguished from the doubly refractive substance"; and that "as the store of the latter in any area grows, that of the fat, which might be regarded as a sign of its formation, sinks." Under certain conditions the birefringent material appears as crystals. The double refraction disappears at 40°C. (in the rabbit), according to Krylow (1914). The birefringent material seems to consist of cholesterin and esters of cholesterin with some lecithin. According to Bernard, Bigart and Labbé (1903) lecithin constitutes 50 per cent of the entire "fat" extracted from the adrenals. A detailed discussion on staining methods and technique is given by Kawamura (1911). With Nile blue the granules become violet to rose-colored without losing the property of double refraction. Neutral red does not affect them. Sudan III gives an orange color. Scarlet red colors them a pale orange, and osmic acid a brown color (bistre). In osmic stained specimens they remain black after being passed through alcohol but are dissolved out by xylol or oil of turpentine. Some writers (Goormaghtigh, 1922*a;* Bernard and Bigart, 1902*a, b, c*) attribute much importance to the differences in solubility in such media between the birefringent substance and the isotropic fatty inclusions of the cortical cells (neutral fats, fatty acids) which after osmic acid fixation are not dissolved by xylol, oil of turpentine, etc. The anisotropic material is spoken of as "labile," the isotropic as "indelible" (non-labile). This distinction is very well if it is employed strictly to mark a histological and physical difference. Nor is there much to quarrel with if the suggestion is made that substances of different properties may constitute different stages in a functional process. But it is not permissible in framing a schema of a supposed secretory activity to place the substance in the functional sequence as if the terms labile and non-labile derived from totally different considerations had any functional significance. A perusal of the literature shows that the danger is not imaginary. The question of specificity of the different histochemical reactions employed in the study of the so-called lipoids has been investigated by Kaufmann and Lehmann (1926). From their extensive experimental studies it is quite evident that functional interpretations made on the basis of histological evidences alone (staining reactions, etc.) may easily be very misleading. These authors, and others (Leathes, 1910) point out that the term "lipoids" has no chemical significance and its use should be dropped. Excellent reviews on the chemistry of this class of substances have been published by

Leathes (loc. cit.) Mac Lean (1918), and more recently by Levene (1921) where extensive bibliographies may be found.

1. *Hypertrophy:*

The significance of adrenal hypertrophy, which is described by a number of observers as occurring under various conditions, is obscure. Many cases of alleged hypertrophied adrenals cannot be explained upon the assumption, often considered axiomatic, that hypertrophy is due to a call for increased functional activity. Even the so-called compensatory hypertrophy and hyperplasia of one adrenal when the other is removed (Stilling, 1889) is puzzling enough, for one adrenal cortex is far more than is sufficient to maintain health and life indefinitely. In the dog which apparently very seldom has accessory adrenals and therefore might be expected on this theory to show a greater tendency to compensatory hypertrophy of the remaining adrenal than the rabbit, in which accessories are common, there is, in fact, relatively little tendency to it. Swale Vincent (1925) states that "there can be no doubt whatever that such a compensatory hypertrophy may be regularly and easily observed in the dog." This, however, is not entirely in accord with our experience in a large series of dogs. Simmonds (1898, 1902) found that in young rabbits, after extirpation of one adrenal, the other may hypertrophy as much as 28 times and in guinea pigs 160 to 180 times its original size. It must be remembered, however, that the growth of the adrenal associated with the growth of a young animal must account for a considerable portion of this hypertrophy.

It is generally stated that only the cortex partakes in hypertrophy. According to Elliott and Tuckett (1906) compensatory hypertrophy is not easily produced in the guinea pig. When one gland was extirpated piecemeal, the medulla left behind grew and the cortex apparently not. In the rabbit, growth of both cortex and medulla occurred. Swale Vincent believes that after a large part of the adrenals have been extirpated in dogs there is notable compensatory hypertrophy of the abdominal chromophile body. This, however, can have no great functional significance since such hypertrophy of the chromophile tissue, if it exists, does not suffice to sustain life when the remaining cortex is removed.

It is sometimes stated that "hypertrophied" adrenals have a much diminished content of epinephrin. In many cases, edema of the gland may have been interpreted as hypertrophy. Such a condition of course produces a marked and rapid increase in weight of the adrenal and is associated with a great loss or even total disappearance of the chromaffin inclusion (Stewart and Rogoff, 1916*a*).

As regards the effects upon the adrenals of removal of the thyroids alone or with the parathyroids there is very little agreement. According to Rogowitch (1888) there is no change in the adrenal of rabbits after "complete"

thyroidectomy. In two thyroidectomized goats Pick and Pineles (1908) observed hypertrophy of the adrenals and Biedl (1901) observed a slight hypertrophy of the adrenal cortex in thyroidectomized dogs. According to Gley (1914) there is a great hypertrophy of the adrenals of rabbits after thyroparathyroidectomy if the animal survives a long time. Tatum (1913) describes hyperplasia of the adrenal medulla, with an increase of fatty material in the cortex as a result of complete removal of the thyroid in young rabbits. Carlson (1916) says that "after complete thyroidectomy (young rabbits) we invariably get a hypertrophy of the suprarenals to two or three times their normal size." By feeding animals with thyroid substance R. G. Hoskins (1910), Herring (1917*a*, *b*), E. R. Hoskins (1916) and Hewitt (1920) report hypertrophy of the adrenals in various animals (guinea pigs, rats, rabbits, cats). According to Herring (loc. cit.) there is also an increase in the chromaffin inclusion and especially in the weight of epinephrin in proportion to the body weight. Kuriyama (1918) does not support this view and maintains that the variations found by Herring both in the adrenal weight and epinephrin content fall within the normal range. In 25 thyroparathyroidectomized rabbits the average weight of the adrenals in proportion to the body weight was found by Stewart and Rogoff (1921) to be considerably greater than in the normal rabbits. The average weight of epinephrin per unit weight of adrenal was the same in these animals as in the normal series. The store of chromaffin material had therefore increased on the average in the same proportion as the gland weight. The average weight of epinephrin per kilogram of body weight was markedly greater than in the normal series.

Landau (1915) states that hypertrophy of the cortex is found in idiots, with infantile genitalia, and that in old age there is atrophy of the glomerulosa. He quotes Sternberg who found experimentally, in guinea pigs and rabbits, that hypertrophy of the cortex is mainly hyperplasia of the glomerulosa.

Precocious development of the reproductive organs is sometimes associated with tumors or hypertrophies of the adrenal body (Wooley, 1902). In pregnancy Guieysse (1899), Watrin (1914*a*, *b*, *c*, 1919) and others observed hypertrophy of the adrenals and they consider it a normal physiological event.

Elliott and Armour (1911) conclude that "the large size of the *human* suprarenal gland during foetal life is due to a peculiar hypertrophy of the cortex, which commences very early and continues until birth. The inner hypertrophied mass is richly supplied with blood vessels, but it does not store in its cells the characteristic doubly refracting fatty substance which is a chief secretion product of the cortex. Immediately after birth the inner mass of hypertrophied cells degenerates, undergoing fatty change; and at the end of the first year all traces of it have disappeared. Hemorrhages occur

readily in this degeneration zone, which, in consequence, has been wrongly depicted in some text-books as medulla damaged by hemorrhage. Enveloping the mass is a rim of smaller cells that early in foetal life assume the appearance of the cells of the adult cortex and store up fatty substance. These develop steadily and, alone, form the adult cortex. In a case of 'hemicephaly,' a child born without cerebral hemispheres, the characteristic small size of the suprarenals was due to the absence of the 'foetal' cortex: the rim corresponding to the adult cortex was almost normal, so too was the system of chromaffine cells. The suprarenal of the brainless child develops, therefore, in the same manner as does that of the animals."

The close functional as well as histogenetic and cytological relations between the suprarenal cortex and certain ovarian tissues, which certainly have no such relations to the suprarenal medulla, have been placed in a clear light by the recent investigations of Rogoff and Stewart (1927), proving that the conditions of pregnancy and of rut exert an influence in prolonging life in adrenalectomized dogs. It is probable that the corpus luteum or independently of it the ovary, either the follicular or the interstitial tissue, may be a factor in the protective influence of pregnancy in adrenalectomized animals. Histologically the corpora lutea have been shown to resemble adrenal cortex. Mulon (1906) concludes, from studies on the corpus luteum, that the evolution of the luteal cells occurs in a manner identical with the cortical cells of the adrenal—fatty deposits, formation of osmophile bodies (following resorption of fat), pigmentation—and that the cells of both are essentially the same. From the histochemical and morphological points of view, he believes that, in the guinea pig, the corpus luteum of pregnancy becomes a "temporary cortical adrenal." It is stated by Goormaghtigh and Elaut (1925) that the maximum physiological activity of the corpus luteum, in the bitch, is attained between the tenth and the fifteenth day after coition. The criterion of increased function was increased intensity of change in the cellular protoplasm, resulting in its transformation into the siderophile bodies of Guieysse. If the corpus luteum is capable of contributing something to make up for the loss of the adrenals in the pregnant animal, such changes occurring during the period of the tenth to fifteenth day would fit in well with the time at which, in the adrenalectomized dogs studied by Rogoff and Stewart, a neutralizing or protective influence would certainly be needed, and in the case of the dogs whose time of mating was known, must have been exercised. That it is not the adrenals of the embryos, or not these solely, which constitute the protective mechanism against adrenal insufficiency in pregnant dogs is supported by the facts that the protective influence is still exerted when the uterus has been emptied by a normal delivery, and that the fetal adrenals do not appear to be enlarged as might be expected if they were making up, by increased activity, for the loss of adrenal function in the mother. As

further evidence of close functional interrelationship between maternal tissues and the adrenal cortex, Rogoff and Stewart (loc. cit.) find that the changes associated with proestrum and oestrus when the possibility of pregnancy has been excluded exert an influence in neutralizing, for a time, the effects of adrenal insufficiency.

2. Functional consideration of the cortical inclusions:

It is an important question in how far the prominent cytological features of the cortical cells are related to their function. A similar question has already been discussed in the case of the medulla. Here, however, it is far simpler because it can easily be shown that the characteristic inclusion, the chromophile granules, are the very substance, or closely related to it, which is discharged into the blood. The only disappointing thing, if any fact should be termed disappointing, is the insignificance if not absolute nullity of the function which can be attributed to the adrenal epinephrin. A thing without which the body gets along apparently without detriment for an indefinite period cannot be considered as anything but insignificant. On the other hand, the function of the cortex is of great importance, being indeed indispensable to life. But we do not know for certain in what if any of the inclusions its function resides, nor whether these or any of them constitute a stage in an essential secretion which is regularly or irregularly discharged.

Goormaghtigh (1922*a*) concludes that there are two distinct glandular functions of the adrenal cortex: (*a*) a cholesterinogenic function; (*b*) the production of siderophile and pigmented plastes. The first resides in the outer seven-eighths of the cortex and as a consequence of its regulation of the cholesterinemia plays an active part in the defense of the organism against infection. The second (inner one-eighth) has under its control at least some of the manifestations which are in close relation to sexual function, and in particular to the secondary sexual characters.

Hyperfunction of the adrenal cortex during pregnancy, as been supposed by some to be indicated, is interpreted by cytological studies made by Guieysse (1901). His opinion is that the ergatoplasm of the reticularis is represented by filaments stained by "rouge magenta" and the secretion of this zone by the pigment and siderophile granules. The number of these cellular formations increases greatly during pregnancy (and after injection of pilocarpine). The ergatoplasm of the fasciculata would be represented by the siderophile bodies, its secretion being invisible. The spongiosa, he believes, secretes a liquid substance whose rôle is to dissolve the products elaborated by the other cortical zones. This view is supported by Ciaccio (1903*a*) and by Bardier and Bonne (1903). The cytological changes in the adrenal cortex observed during pregnancy, fasting, following castration, and in compensatory hypertrophy are interpreted as indicating

hyperfunction by Ciaccio (1903*b*), who has modified his views from time to time. He believes that hyperfunction is characterized by the presence of lipoid granules (stained by his own method), by diminution of fat, increase in the number of siderophile cells and of pigment.

Contrary to the view of Jacopini (1906), it is held by Ciulla (1909), that pigment is a product of secretion and that the cells which contain it are poor in siderophile bodies (and vice versa). This investigator finds, as an indication of cortical hyperfunction, an increase of lecithin up to 70 per cent of the total amount of adrenal fat, during pregnancy. But Mulon (1907) states that hyperfunction is characterized by increase of pigment and not fat. Bernard and Bigart (1902*a*, *b*, *c*) believe that hyperfunction is indicated by the presence in the cortex of a large number of siderophile bodies, pigment and spongiocytes, which secrete lecithin. The fasciculata represents an indifferent stage of activity. Outside this zone is a gradual formation of spongiocytes; inside, the pigment cells would represent the last stage of cellular evolution. There is no criterion for the study of hypersecretion or hyposecretion of the cortical cells. Hypertrophy has been observed, by a number of investigators, during pregnancy and following the removal of one gland (in some animals). Excepting these two conditions, the other hypertrophies described are questionable (Da Costa, 1913). The characteristic cytological feature found is the increase in adipoid material, pigment and siderophile bodies.

From cytological evidences of secretory activity, Tamura (1926) suggests that the suprarenals are exhausted during pregnancy. The zona reticularis degenerates as pregnancy advances, though there is some early hypertrophy of the glomerulosa and fasciculata regions, which show mitotic figures, while a "zona gestationis" appears. Towards full term there is evidence of medullary hypertrophy. Neither unilateral nor complete gonadectomy affects the structure of the suprarenal glands. But Elliott and Tuckett (1906) state that the change in the cells is so slight that the majority of observers agree that the medulla shows no alteration in pregnancy (or infection). Hultgren and Andersson (1899), on the other hand, observed none in the cortex, but some change in the cytoplasmic granules of the medulla. Gestation accelerates the growth of the gland, so that for a time the female outstrips the male. In such increase the cortex is concerned, but there is undoubtedly growth of the medulla also (Elliott and Tuckett, loc. cit.).

An excellent review of functional considerations can be found in the summary of Goormaghtigh's thesis (1922*a*), also in the articles by Da Costa (1913) and by Colson (1910). However, it has already been emphasized, and is evident from the foregoing, that in the present state of our knowledge it is risky to attribute definite functions to the inclusions of the cortical cells. Premature attempts to read into the histological picture corresponding

functional interpretations necessarily react in bringing even apparently genuine morphological distinctions under suspicion.

I must express my great obligations to friends, especially to Dr. J. M. Rogoff who completed and revised the text and perfected the bibliography when I was obliged to relinquish the task through illness.

III. BIBLIOGRAPHY

Abelous, J. E., Soulié, A., and Toujan, G. 1905. Dosage colorimétrique par l'iode de l'adrénaline. *Compt. rend. Soc. d. biol.*, **57**, 301.

——— 1906. Sur un procédé de controle des dosages chimique et physiologique de l'adrénaline. *Ibid.*, **58**, 174.

Adami, J. G. 1908. *The principles of pathology*. Philadelphia.

Arnold, J. 1866. Ein Beitrag zu der feineren Structur und dem Chemismus der Nebennieren. *Virchow's Archiv*, **35**, 64.

Aschoff, L. 1910. Zur Morphologie der Lipoiden Substanzen. *Ziegler's Beiträge z. path. Anat.*, **47**, 1.

Balfour, F. M. 1876. The development of elasmobranch fishes. *J. Anat. and Physiol.*, **10**, 672.

——— 1878*a*. *Monograph on the development of the elasmobranch fishes*. London.

——— 1878*b*. The development of elasmobranch fishes. *J. Anat. and Physiol.*, **12**, 177.

Bardier and Bonne. 1903. Sur les modifications produites dans la structure des surrénales par la tétanisation musculaire. *J. de l'Anat.*, **39**, 296.

Bager, B. 1917–18. Bidrag rill binjurarnas aldersanatomie hos Kaninen. *Upsala Läkareforenings Förhandlingar*, Band **23**, H. 1–2, 48.

Bernard, L., and Bigart. 1902*a*. Quelques détails de la structure des glandes surrénales normales du cobaye. *Bu'l. et mém. Soc. Anat. de Paris*, **87**, 837.

——— 1902*b*. Note sur la graisse dans les capsules surrénales normales de l'homme. *Ibid.*, **87**, 929.

——— 1902*c*. Étude anatamo-pathologique des capsules surrénales dans quelques intoxications expérimentales. *J. de Physiol. et de Path. gén.*, **14**, 1014.

——— 1905. Les processus sécrétoires dans la substance corticale de la glande surrénale. *Compt. rend. Soc. d. biol.*, **57**, 504.

Bernard, L., Bigart, and Labbé, H. 1903. Sur la sécrétion de lécithine dans les capsules surrénales. *Compt. rend. Soc. d. biol.*, **55**, 120.

Biedl, A. 1901. Zur Schilddrüsenfrage. *Wien. klin. Wchnschr.*, **14**, 1278.

——— 1922. *Innere Sekretion*. Berlin.

Bogomolez, A. 1905. Zur Frage über die Veränderungen der Nebennieren bei experimentelle Diphtherie. *Ziegler's Beiträge*, **38**, 510.

Boinet, E. 1895. Nouvelles recherches sur la résistance à la fatigue de rats décapsulés depuis longtemps. *Compt. rend. Soc. d. biol.*, **47**, 325.

Bonnamour, S. 1902. Recherches histologiques sur la sécrétion des capsules surrénales. *C. R. de l'Assoc. des Anat.*, 4e session, Montpellier.

——— 1905. *Etude histologique des phénomènes de sécrétion de la capsule surrénale chez les mammifères*. Thèse de Lyon.

Brenton, R. L., and Case, M. A. 1925. The beginning of adrenal function in the embryo chick. *Am. J. Physiol.*, **73**, 670.

Cameron, A. T. 1925. Normal variations of percentage weights of body organs of the albino rat with changing body weight. *Am. J. Physiol.*, **74**, 151.

Carlson, A. J. 1916. (Discussion.) *J.A.M.A.*, **67**, 1484.

Ciaccio, C. 1903*a*. Sui caratteri citologici e microchimici delle cellule cromaffini. *Anat. Anz.*, **24**, 244.

——— 1903*b*. Sopra una nuova specie di cellula nelle capsule surrenali degli Anuri. *Ibid.*, **23**, 95.

——— 1903*c*. Ricerche sui processi di secrezione cellulare nelle capsule surrenali dei vertebrati. *Ibid.*, **23**, 401.

——— 1910. Contributo alla conoscenza dei lipoidi cellulari. *Ibid.*, **35**, 17.

Ciulla, M. 1909. *Gli organi a secrezione interna nella gravidanza e nel puerperio. Ricerche istologiche e istochimiche.* Thèse de Palermo.

Clevers, Mlle. J., and Goormaghtigh, M. 1922*a*. *Le rôle du cortex surrénal et de la glande thyroide au cours de la vaccination antivariolique.* Mémoire de l'Acad. Roy. Méd. de Belg.

——— 1922*b*. Le cortex surrénal au cours de la vaccination antidiptérique et de la toxémie diptérique. *Bull. de l'Acad. roy. de Méd. de Belg.*, **2**, 425.

Colson, R. 1910. Histogenèse et structure de la capsule surrénale adulte. *Arch. de Biol.*, **25**, 535.

Cowdry, E. V. 1926*a*. 1. Surface film theory of the function of mitochondria. *Am. Naturalist*, **60**, 157.

——— 1926*b*. The reactions of mitochondria to cellular injury. *Arch. Path. Lab. Med.*, **1**, 237.

Cramer, W. 1916. On the thyroid-adrenal apparatus and its function in the heat regulation of the body. *J. Physiol.*, **50** (Proc.), xxxviii.

——— 1918*a*. Further observations on the thyroid-adrenal apparatus. A histochemical method for the demonstration of adrenalin granules in the suprarenal gland. *Ibid.*, **52** (Proc.), viii–x.

——— 1918*b*. Histochemical observations on the functional activity of the suprarenal medulla in different pathological conditions. *Ibid.*, **52** (Proc.), xiii–xv.

——— 1919. *Observations on the functional activity of the suprarenal gland in health and in disease.* Sixth Scientific Report Imp. Can. Res. Fund.

——— 1926*a*. Self-control and inhibition in the adrenal gland. *Brit. J. Exp. Path.*, **7**, 88.

——— 1926*b*. Fever, infections and the thyroid-adrenal apparatus. *Ibid.*, **7**, 95.

Da Costa, A. C. 1913. Recherche sur l'histo-physiologie des glandes surrénales. *Arch. de Biol.*, **28**, 111.

Diamare, V. 1905. Ancora sulle immagini di secrezione e sulle inclusioni cellulari nelle capsule soprarenali. *Anat. Anz.*, **26**, 193.

Donaldson, J. C. 1919. The relative volumes of the cortex and medulla of the adrenal gland in the albino rat. *Am. J. Anat.*, **25**, 291.

——— 1924. The influence of pregnancy and lactation on the weight of adrenal glands in the albino rat. *Am. J. Physiol.*, **68**, 517.

Elliott, T. R. 1912. The control of the suprarenal glands by the splanchnic nerves. *J. Physiol.*, **44**, 374.

——— 1914. Pathological changes in the adrenal glands. *Quart. J. Med.*, **8**, 47.

Elliott, T. R., and Armour, R. G. 1911. The development of the cortex in the human suprarenal gland and its condition in hemicephaly. *J. Path. Bact.*, **15**, 482.

Elliott, T. R., and Tuckett, I. 1906. Cortex and medulla in the suprarenal glands. *J. Physiol.*, **34**, 332.

Fuhrmann, F. 1904. Der feinere Bau der Nebenniere des Meerschweinchens. *Anat. Anz.*, **24**, 606; 1905. *Ztschr. f. wiss. Zool.*, **78**, 522.

Fujii, I. 1924. Do the blood sugar level, the glycogen content of liver and of muscle and the epinephrine content of suprarenals undergo a seasonal variation? *Tohoku J. Exper. Med.*, **5**, 405.

Fujii, I. 1925. On the influence of ether anaesthesia on the epinephrine content of the suprarenals of the dog. *Ibid.*, **5**, 566.

Girndt, O. 1925*a*. Cholin als Hormon der Darmbewegung. VIII. Mitteilung. Stammt das Darmcholin aus den Nebennieren? *Pflüger's Archiv.*, **207**, 464.

——— 1925*b*. Cholin als Hormon der Darmbewegung. IX. Mitteilung. Die Unfähigkeit der isolierten Darmwand Cholin neu zu bilden. *Ibid.*, **207**, 469.

Giroud, A. 1925. Réactions des substances albuminoïdes sur les chondriosomes. *Compt. rend. Soc. d. biol.*, **93**, 158.

Gley, E. 1914. Valeur physiologique de le glande surrénale des animaux éthyroïdés. *Arch. int. de physiol.*, **14**, 175.

Goormaghtigh, N. 1919. Contribution à l'étude du fonctionnement de la capsule surrénale humaine à l'état normal et dans les états infectieux en particulier dans les gangrénes gazeuses. *Arch. d. Méd. exp. et. d'Anatomie Path.*, **28**, 277.

——— 1922*a*. *Le cortex surrénal humain dans les plaies de l'abdomen et aux periodes intéressantes de la vie sexuelle.* Thèse, Université de Gand.

——— 1922*b*. La signification du corps sidérophile du cortex surrénal du cobaye d'après des données expérimentales. *Compt. rend. de l'association des Anatomistes*, xviie réunion, Gand.

Goormaghtigh, N., and Elaut, L. 1925. Le plan de structure de la surrénale au point de vue physiologique. *Compt. rend. Soc. d. biol.*, **92**, 733.

Gottschau, M. 1882. Über Nebennieren der Säugethieren, speciell über die des Menschen. *Sitzungsb. der Physik.-Med. Gesell.*, Würzburg, No. 4, 56.

——— 1883. Struktur und embryonale Entwickelung der Nebennieren bei Säugethieren. *Arch. f. Anat. u. Entwickl.*, Leipzig. 412.

Guieysse, A. 1899. La capsule surrénale chez la femelle du cobaye en gestation. *Compt. rend. Soc. d. biol.*, **51**, 898.

——— 1901. La capsule surrénale du cobaye histologie et functionnement. *J. de l'anat. et de la physiol.*, **37**, 312, 434.

Hartman, F. A. 1923. Production of adrenaline by the adrenal cortex. *Science*, **58**, 74.

Hartman, F. A., McCordock, H. A., and Loder, M. M. 1923. Conditions determining adrenal secretion. *Am. J. Physiol.*, **64**, 1.

Hartman, F. A., Waite, R. H., and Powell, E. F. 1922. The relation of the adrenals to fatigue. *Am. J. Physiol.*, **60**, 255.

Henle, J. 1865. Über das Gewebe der Nebenniere und der Hypophyse. *Ztschr. f. rat. Med.*, **24**, 142.

Herring, P. T. 1917*a*. The effect of thyroid feeding on the weight of the suprarenals and their adrenaline content. *Quart. J. Exper. Physiol.*, **11**, 47.

——— 1917*b*. The action of thyroid upon the growth of the body and organs of the white rat. *Ibid.*, **11**, 231.

Hewitt, J. A. 1920. The effect of administration of small amounts of thyroid gland on the size and weight of certain organs in the male white rat. *Quart. J. Exper. Physiol.*, **12**, 347.

Hirayama, S. 1925. On the epinephrine content of the suprarenals in the unilaterally splanchnectomized rabbit. *Tohoku J. Exper. Med.*, **5**, 573.

Hoskins, E. R. 1916. The growth of the body and various organs of the albino rat affected by feeding various ductless glands (thyroid, thymus, hypophysis and pineal). *J. Exper. Zool.*, **21**, 295.

Hoskins, R. G. 1910. Congenital thyroidism; an experimental study of the thyroid in relation to other organs of internal secretion. *Am. J. Physiol.*, **26**, 426.

Houssay, B. A., and Lewis, J. T. 1921*a*. Technique de l'extirpation de la partie médullaire des surrénales. *Compt. rend. Soc. d. biol.*, **85**, 1209.

Houssay, B. A., and Lewis, J. T. 1921*b*. Importance comparative des parties medullaire et corticale des surrénales. *Ibid.*, **85**, 1210.

——— 1923. The relative importance to life of cortex and medulla of the adrenal glands. *Am. J. Physiol.*, **64**, 512.

Hueck, W. 1912. Pigmentstudien. *Ziegler's Beitr.*, **54**, 68.

Hultgren, E. O., and Andersson, O. A. 1899. Studien über die Physiologie und Anatomie der Nebennieren. *Skandinav. Arch. f. Physiol.*, **9**, 73.

Ingier, A., and Schmorl, G. 1911. Über den Adrenalingehalt der Nebennieren. *Deutch. Arch. klin. Med.*, **104**, 125.

Jacopini, G. 1906. La secrezioni siderofile delle capsule surrenali. *La Clinica Moderna*, **7**, 251.

Kahn, R. H. 1911. Zuckerstich und Nebennieren. *Pflüger's Arch.*, **140**, 209.

——— 1926. Über die zentrale Reizung der Nebennieren und der Paraganglien während der Insulinvergiftung. *Ibid.*, **212**, 54.

Kaiserling, C., and Orgler, A. 1902. Über das Auftreten von Myelin in Zellen und seine Beziehung zur Fettmetamorphose. *Virchow's Archiv*, **167**, 296.

Kaufmann, C., and Lehmann, E. 1926. Sind die in der histologischen Technik gebräuchlichen Fettdifferenzierungsmethoden spezifisch? *Virchow's Archiv*, **261**, 623.

Kawamura, R. 1911. *Die Cholesterin-esterverfettung*. Jena.

Kennedy, W. P. 1925. Corpus luteum extracts and ovulation in the rabbit. *Quart. J. Exper. Physiol.*, **15**, 103.

Kichikawa, W. 1925. Untersuchungen über die Beziehungen der Nebennieren zu der Entwickelung der sekundaren Geschlechtsmerkmale. *Biochem. Zeit.*, **163**, 176.

Kodama, S. 1924. Einfluss der Chloroformnarkose auf die Epinephrinabgabe der Nebennieren. *Tohoku J. Exper. Med.*, **5**, 149.

Kohn, A. 1903. Die Paraganglien. *Arch. mikr. Anat.*, **62**, 263.

——— 1914. Synkainogenese. *Arch. f. Entwickelungsmechanik*, **39**, 112.

Krylow, D. D. 1914. Experimentelle Studien über Nebennierenrinde. *Ziegler's Beitr.*, **58**, 434.

Kuriyama, S. 1918. The influence of thyroid feeding upon carbohydrate metabolism. II. The epinephrine content of the adrenals of thyroid-fed rats. *J. Biol. Chem.*, **33**, 207.

Landau, M. 1915. *Die Nebennierenrinde*. Jena.

Langlois, P. 1893. Destruction des capsules surrénales chez les chiens. *Arch. de Physiol. norm. et path.*, **5**, 488.

Leathes, J. B. 1910. *The fats*. New York.

Levene, P. A. 1921. Structure and significance of phosphatides. *Physiol. Rev.*, **1**, 327.

Lewis, J. T. 1921. Sensibilité des rats acapsulé envers les toxiques. *Compt. rend. Soc. d. biol.*, **85**, 685.

——— 1923. Sensibility to intoxication in albino rats after double adrenalectomy. *Am. J. Physiol.*, **64**, 506.

McCord, C. P. 1915. *The occurrence of pituitrine and epinephrine in fetal pituitary and suprarenal glands*. Res. Lab. Parke, Davis & Co.

MacLean, H. 1918. *Lecithin and allied substances—the lipins*. New York.

Mikami, S. 1925. The blood sugar level and epinephrine content of the suprarenals of the rabbit in diphtheritic intoxication. *Tohoku J. Exper. Med.*, **6**, 299.

Mott, F. W., and Halliburton, W. D. 1907. The suprarenal glands in nervous and other diseases. *Arch. Neurol.*, **3**, 123.

Mulon, P. 1903. Sur le pigment des capsules surrénales du Cobaye. *Bibliogr. Anat.*; **14**.

——— 1904. Specificité de la reaction chromaffine: glands adrénalogènes. *Compt. rend. Soc. d. biol.*, **56**, 113.

Mulon, P. 1905*a*. Évolution de la corticale surrénale du Cobaye avec l'âge de l'animal. *Ibid.*, **57**, 337.

——— 1905*b*. Sur la réaction osmique de la médullaire des surrénales. *Ibid.*, **57**, 757.

——— 1906. Parallèle entre le corps jaune et la cortico-surrénale chez le Cobaye. *Ibid.*, **58**, 292.

——— 1907. Importance fonctionelle du pigment dans la surrénale. *Ibid.;* **62**, 905.

——— 1910*a*. La méthode des mitochondries (de Benda) appliquée à la corticale surrénale du Cobaye. *Ibid.*, **68**, 103.

——— 1910*b*. Sur les mitochondries de la surrénale (substance corticale, couche graisseuse, cobaye). *Ibid.*, **68**, 872.

——— 1910*c*. Les mitochondries surrénales (substance médullaire). *Ibid.*, **68**, 917.

——— 1912. Mode de formation du pigment figuré dans la corticale surrénale. *Ibid.*, **72**, 176.

——— 1913. Structure des capsules surrénales accesoires chez le lapin. *Ibid.*, **75**, 313.

Ogata, T., and A. 1917. Henle's reaction of the chromaffin cells in the adrenals, and the microscopic test for adrenaline. *J. Exper. Med.*, **25**, 807.

Orgler, A. 1898. *Inaugural dissertation.* Berlin.

Pearlman, I., and Vincent, S. 1919. The function of the chromaphil tissues, *Endoc.*, **3**, 121.

Pick, E. P., and Pineles, F. 1908. Über die Beziehungen der Schilddrüse zur physiologischen Wirkung des Adrenalins. *Biochem. Zeit.*, **12**, 473.

Plecnik, J. 1902. Zur Histologie der Nebenniere des Menschen. *Arch. f. mikr. Anat.*, **60**, 414.

Quinquad, A. 1915. *Relations entre la piqûre diabétique et la sécrétion d'adrenaline.* Travail du Lab. de Biol. Gén. du Collège de France.

Rabl, H. 1891. Die Entwicklung und Structur der Nebennieren bei den Vögeln. *Arch. mikr. Anat.*, **38**, 492.

Riddle, O. 1922. An undescribed relation of the suprarenals to ovulation. *Proc. Soc. Exper. Biol. Med.*, **19**, 280.

——— 1923. Studies on the physiology of reproduction in birds. XIV. Suprarenal hypertrophy coincident with ovulation. *Am. J. Physiol.*, **66**, 322.

Riddle, O., Honeywell, H. E., and Fisher, W. S. 1924. Suprarenal enlargement under heavy dosage with insulin. *Am. J. Physiol.*, **68**, 461.

Riddle, O., and Tange, M. 1926. Some limitations of the action of the so-called follicular hormone in birds. *Proc. Soc. Exper. Biol. Med.*, **23**, 648.

Robertson, T. B. 1926. The function of the lipoid in mitochondria. *Aust. J. Exper. Biol. Med. Sci.*, **3**, 97.

Röszle, R. 1919. Bedeutung und Ergebnisse der Kriegs-pathologie. *Jahreskurse f. ärztliche Fortbildung*, **10**, 23. (Abs., *Endoc.*, **3**, 514.)

Rogoff, J. M., and De Necker, J. 1925. The influence of the adrenals on the toxicity of morphine. *J. Pharm. Exper. Therap.*, **26**, 243.

Rogoff, J. M., and Dominguez, R. 1924. Effect of double adrenalectomy on the systolic blood-pressure of the non-anesthetized rabbit. *J. Meta. Res.*, **6**, 141.

Rogoff, J. M., and Ecker, E. E. 1926. Suprarenalectomy and susceptibility in white rats to tetanus toxin. *Arch. Path.*, **1**, 309.

——— 1927. The susceptibility of albino rats to tetanus toxin following adrenalectomy. *Am. J. Physiol.*, **80**, 200.

Rogoff, J. M., and Stewart, G. N. 1926*a*. Further studies on adrenal insufficiency in dogs. Duration of survival of control animals not subjected to any treatment. *Science*, **64**, 141.

——— 1926*b*. Studies on adrenal insufficiency in dogs. I. Control animals not subjected to any treatment. *Am. J. Physiol.*, **78**, 683.

Rogoff, J. M., and Stewart, G. N. 1926c. Studies on adrenal insufficiency in dogs. II. Blood studies in control animals not subjected to treatment. *Ibid.*, **78**, 711.

——— 1927. Studies on adrenal insufficiency in dogs. III. The influence of pregnancy upon the survival period in adrenalectomized dogs. *Ibid.*, **79**, 508.

Rogowitch, M. N. 1888. Sur les effects de l'ablation du corps thyroïde chez les animaux. *Arch. d. physiol. norm. et path.*, 4e series, **2**, 419.

Scott, W. J. M. 1923. The influence of the adrenal glands on resistance. I. The susceptibility of adrenalectomized rats to morphine. *J. Exper. Med.*, **38**, 543.

Sharpey-Schafer, E. 1924. *The endocrine organs.* London.

Simmonds, M. 1898. Über compensatorische Hypertrophie der Nebenniere. *Virchow's Archiv*, **153**, 138.

——— 1902. Weitere Beobachtungen über compensatorische Hypertrophie der Nebenniere. *Cent. f. allg. Path. u. path. Anat.*, **13**, 81.

Soulié, A. H. 1903a. *Recherches sur le développement des capsules surrénales chez les vertébrés supérieurs.* Thèse de Paris.

——— 1903b. Recherches sur le développement des capsules surrénales chez les vertébrés supérieurs. *J. de l'anat. et de la physiol.*, **39**, 197, 390, 492, 634.

Stewart, G. N. 1921. Adrenal insufficiency. *Endoc.*, **5**, 283.

——— 1924. Adrenalectomy and the relation of the adrenal bodies to metabolism. *Physiol. Rev.*, **4**, 163.

Stewart, G. N., and Rogoff, J. M. 1916a. The influence of certain factors, especially emotional disturbances, on the epinephrine content of the adrenals. *J. Exper. Med.*, **24**, 709.

——— 1916b. The liberation of epinephrine from the adrenal glands by stimulation of the splanchnic nerves and by massage. *J. Pharm. Exper. Therap.*, **8**, 205.

——— 1916c. The spontaneous liberation of epinephrine from the adrenals. *Ibid.*, **8**, 479.

——— 1917a. Quantitative experiments on the liberation of epinephrine from the adrenals after section of their nerves, with special reference to the question whether epinephrine is indispensable for the organism. *Ibid.*, **10**, 1.

——— 1917b. The influence of asphyxia upon the rate of liberation of epinephrine from the adrenals. *Ibid.*, **10**, 49.

——— 1917c. The alleged relation of the epinephrine secretion of the adrenals to certain experimental hyperglycemias. *Am. J. Physiol.*, **44**, 543.

——— 1917d. Effect of stimulation of sensory nerves upon the rate of liberation of epinephrine from the adrenals. *J. Exper. Med.*, **26**, 637.

——— 1918. The relation of the adrenals to piqûre hyperglycemia and to the glycogen content of the liver. *Am. J. Physiol.*, **46**, 90.

——— 1919a. The action of drugs upon the output of epinephrine from the adrenals. I. Strychnine. *J. Pharm. Exper. Therap.*, **13**, 95.

——— 1919b. Further observations showing that epinephrine from the adrenals is not indispensable. *Am. J. Physiol.*, **48**, 397.

——— 1921. Post-operative depletion of the epinephrine store of the adrenals. *Ibid.*, **56**, 220.

——— 1922a. The action of drugs upon the output of epinephrine from the adrenals. VIII. Morphine. *J. Pharm. Exper. Therap.*, **19**, 59.

——— 1922b. The influence of muscular exercise on normal cats compared with cats deprived of the greater part of the adrenals, with special reference to body temperature, pulse and respiratory frequency. *Ibid.*, **19**, 87.

——— 1922c. The influence of morphine on normal cats and on cats deprived of the greater part of the adrenals, with special reference to body temperature, pulse and respiratory frequency and blood sugar content. *Ibid.*, **19**, 97.

Stewart, G, N., and Rogoff, J. M. 1922*d*. Morphine hyperglycemia and the adrenals. *Am. J. Physiol.*, **62**, 93.

——— 1923. The average epinephrine output in cats and dogs. *Ibid.*, **66**, 235.

——— 1925*a*. Studies in adrenal insufficiency. *Proc. Soc. Exper. Biol. Med.*, **22**, 394.

——— 1925*b*. Studies in adrenal insufficiency. *Ibid.*, **23**, 190.

Stilling, H. 1889. Über die compensatorische Hypertrophie der Nebennieren. *Virchow's Archiv*, **118**, 569.

Stoerk, O., and von Haberer, H. 1908. Beiträge zur Morphologie des Nebennierenmarkes. *Arch. f. mikr. Anat.*, **72**, 481.

Tamura, Y. 1926. Structural changes in the suprarenal gland of the mouse during pregnancy. *Brit. J. Exp. Biol.*, **4**, 81 (*Physiol. Abst.*, **11**, 492).

Tatum, A. L. 1913. Morphological studies in experimental cretinism. *J. Exper. Med.*, **17**, 636.

Tokumitsu, Y. 1920*a*. Über eine neue Funktion der Nebennierenrinde. *Mitteilungen aus dem path. Institut der Kaiserlichen Univ. zu Sendai*, **1** (2), 161.

——— 1920*b*. Studies on cortical substance of the suprarenal capsule. *Ibid.*, **1** (2), 211.

——— 1923*a*. Studies on the cortical substance of the suprarenal capsule. *Mitteilungen der Medicinischen Akademie zu Keijo.*

———1923*b*. On the function of suprarenal cortex and its mutual relations with other endocrinal glands. *Japan Med. World*, **3**, 212.

Tuczek, K. 1914. Über die Beziehungen der Nebennierenspigmentation zur Hautfarbe. Mit besonderer Berücksichtigung der pigmentierten Nebennierentumoren. *Ziegler's Beitr.*, **58**, 250.

Vincent, Swale. 1897. The comparative physiology of the suprarenal capsules. *Proc. Roy. Soc.*, **61**, 64.

——— 1917. The experimental and clinical evidence as to the influence exerted by the adrenal bodies upon the genital system. *Surg., Gyn. and Obs.*, Sept., 294.

——— 1925. *Internal secretion and the ductless glands.* New York.

——— 1925*a*. The effects of fatigue and temperature on the adrenal bodies of the rat. *Quart. J. Exper. Physiol.*, **15**, 319.

Vincent, Swale, and Wright, S. 1924. The splanchnic nerve and the chromaphil tissue of the adrenal body. *Quart. J. Exper. Physiol.*, **14**, 285.

Vulpian, A. 1856. Note sur quelques réactions propre à la substance des capsules surrénales, *Compt. rend. Acad. Sc.*, **43**, 663.

Wallin, I. E. 1925*a*. On the nature of mitochondria. VIII. Further experiments in the cultivation of mitochondria. *Am. J. Anat.*, **35**, 403.

——— 1925*b*. On the nature of mitochondria. IX. Demonstration of the bacterial nature of mitochondria. *Ibid.*, **36**, 131.

Watrin, J. 1914*a*. L'hypertrophie des capsules surrénales, au cours de la gestation, est-elle sous la dépendance du corps jaune? *Compt. rend. Soc. d. biol.* **77**, 142.

— — 1914*b*. Le corps jaune "sensibilise" les capsules surrénales á l'action des facteurs qui déterminent leur hypertrophie gravidique. *Ibid.*, **77**, 207.

—— 1914*c*. L'oeuf fécondé conditionne, avant sa fixation, l'hypertrophie des capsules surrénales chez la lapine. *Ibid.*, **77**, 321.

——— 1919. L'hypertrophie des capsules surrénales chez la lapine gestante ne doit pas être attribuée á la présence du foetus. *Ibid.*, **82**, 1405.

Wheeler, T. D., and Vincent, Swale. 1917. The question as to the relative importance to life of cortex and medulla of the adrenal bodies. *Trans. Roy. Soc. Canada*, Series. III, **11**, 125.

Wooley, P. G. 1902. A primary carcinomatoid tumor (mesothelioma) of the adrenals, with sarcomatous metastasis. *Trans. of Ass'n. Am. Phys.*, **17**, 627.

Section XIX
RENAL TUBULES

CONTENTS

SECTION XIX

PAGE

I. PRONEPHROS 664
II. MESONEPHROS 665
III. METANEPHROS 670
1. Reptilian metanephric tubules 676
2. Avian metanephric tubules 679
3. Mammalian metanephric tubule 680
IV. CYTOLOGICAL STRUCTURE OF DIFFERENT PARTS OF MAMMALIAN RENAL TUBULE 687
V. BIBLIOGRAPHY 700

Section XIX

RENAL TUBULES

G. CARL HUBER

EMBRYOLOGICALLY considered, the urinary organs of higher vertebrates, including man, consist in phylogeny and otogeny of three successive sets of excretory organs, known respectively as pronephros, mesonephros and metanephros. In the higher vertebrates the pronephros and mesonephros form transient embryonic structures, recapitulating phylogenic organ systems which form permanent excretory organs in the lower vertebrates; the pronephros in the lowest vertebrates and in the larval stages in amphibians, the mesonephros in fishes and in amphibians, while

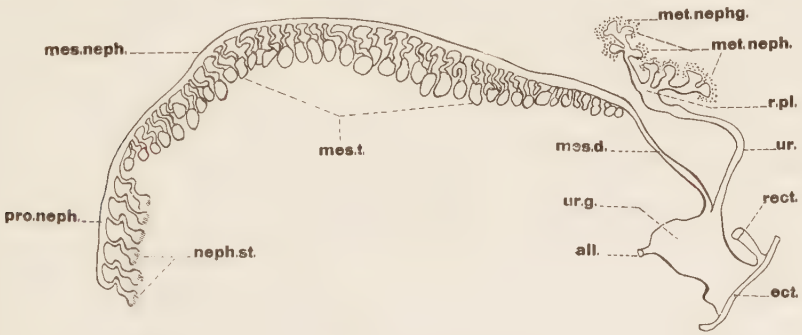

FIG. 282.—Semidiagrammatic figure giving the phylogenetic development of the renal system of mammalia, based on successive stages of human development. all., allantois; ect., ectoderm; mes. d., mesonephric duct; mes. neph.; mesonephros; mes. t., mesonephric tubules; met. neph., metanephros; met. nephg., metanephrogenic tissue (stippled). neph. st., nephrostome; pro. neph., pronephros; rect., rectum. r.pl., renal pelvis; ur., ureter; ur.g., urogenital sinus.

the metanephros forms the final and permanent excretory organ in amniotes —reptiles, birds and mammals. The successive renal organs with their duct systems are of mesodermal origin, being differentiated from the intermediate cell masses or nephrotomes, lying, in the main, lateral to the somites and mesial to the celomic spaces. It is of interest to note that in the development of the renal system of higher vertebrates, one deals not with successive stages in the development of a single organ, but with developmental and regressive stages in a series of organs, each of which presents excretory tubules and a duct system.

The anlage and early developmental stages of the renal complex of a mammal is presented in diagrammatic form in Figure 282. This diagram is based in essentials on reconstructions made from human embryos varying

in ages. The reconstructions on which the diagram is based are from successive stages of development; the data included could not be substantiated in the same embryo at the same time.

I. PRONEPHROS

In the majority of mammalia the pronephros is a vestigial structure with but brief and very incomplete development. In the human embryo the pronephros extends approximately from the seventh to the twelfth or fourteenth segments. In each successive segment there is differentiated from the dorsal surface of the intermediate cell mass a short cord of cells which by proliferation of the cells extends toward the ectoderm, but before it reaches the ectoderm turns caudalward, coming thus into close relation

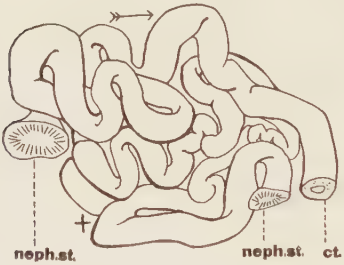

FIG. 283.

FIG. 284.

FIG. 283.—Reconstruction of the pronephric tubules of a larva of Bufo having a total length of 10 mm. neph. st., nephrostomes; ct., common collecting tubule; + region of the Y-shaped junction of the two tubules. × 80.

FIG. 284.—Pronephric tubule of larval frog with vital staining in trypanblau. The cells show a "brush border;" black globules, stain inclusions; fine circles, pigment granules. (Redrawn from v. Möllendorff, Festschrift für M. Fürbringer, 1919.)

with similar segmental elements which differentiate in successive segments in cranio-caudal direction and in further development fuse to form a continuous structure. There are thus formed transverse elements, the anlagen of pronephric tubules, which differentiate in cranio-caudal sequence, and a longitudinal cord, the anlage of the pronephric duct. As the tubules differentiate, they open mesially into the celomic space by means of funnel-shaped openings known as nephrostomes and laterally into the pronephric duct. The pronephric tubules may become invaginated by a glomerular tuft, forming an internal glomerulus. A further glomerulus may form in the wall of the celom in close relation to the nephrostome, the external glomerulus. Both internal and external glomeruli are supplied through branches from the dorsal aorta. The pronephros has its anlage in the human embryo of nine to ten segments and is relatively well developed in one of eighteen to

twenty segments. The pronephric tubules degenerate nearly as soon as they are formed, and this in cranio-caudal direction, to the extent that by the time the human embryo has reached a crown-breech length of approximately 5 mm. the pronephros has completely disappeared. In certain of the lower vertebrates the pronephros has a longer developmental history ond in certain fishes and in larval amphibians it differentiates to become a functional excretory organ. As a type of a functional pronephric tubule there is here figured a reconstruction of a pronephric tubule made from a series of frontal sections of a larval toad of 10 mm. total length. The pronephric tubule shown in Figure 283 presents two nephrostomes (ns). The tubules leading from the nephrostomes come together in a Y-shaped junction, found on the reverse side of the model as placed in the drawing and in the region indicated by the cross. The common tube thus formed has a length of 2.5 mm. and presents three main loops with a secondary loop, the major loops extending in the main in cranio-caudal direction. The epithelial cells lining the coiled portion of the pronephric tubule are of columnar form and present a superficial brush border, while the protoplasm of the basal parts of the cells shows a striation apparently due to relatively coarse cytorecticular bars arranged in the direction of the long axis of the cells. In experiments with vital staining with trypan blue, the coloring matter excreted into the lumen of the tubules, presumably through the glomeruli, appears in globular form in the protoplasm of the cells lining the coiled portion of the pronephric tubules, and the evidence seems convincing that water and contained substances in solution are secreted or excreted through the glomeruli and are reabsorbed into the blood stream through the epithelial cells lining the coiled portions of the pronephric tubules (Fig. 284).

II. MESONEPHROS

The parent tissue from which the mesonephros develops is essentially the same as that giving rise to the pronephros. The pronephric duct, formed by fusion of the lateral ends of the successive pronephric tubules, grows caudally beyond the limits of the pronephric region to reach the cloaca; this in the human embryo when it has reached a crown-breech length of 4.5 mm. This free terminal portion of the pronephric duct grows caudally under the ectoderm in close relation and with slight dorsolateral position to an unsegmented cord of nephrogenic mesoderm derived from the successive intermediate cell masses. In a human embryo of 4.25 mm. crown-breech length and twenty-eight segments this nephrogenic cord extends to the twenty-eighth segment. When the human embryo attains a length of 5.3 mm. crown-breech length the nephrogenic cord appears interrupted in the twenty-sixth and twenty-seventh segments, so that the nephrogenic

tissue becomes divided into two parts, a much longer cephalad portion known as the mesonephrogenic tissue, and a short caudal portion known as the metanephrogenic tissue. From the mesonephrogenic tissue are differentiated, in cranio-sacral direction, nodules of nephrogenic tissue which are in the main of spheroidal form and are to be regarded as the anlagen of the mesonephric tubules. These respective nodules by rearrangement, by proliferation and by differentiation of cells develop to form mesonephric vesicles. The vesicles by regional growth assume ovoid form and from the lateral portion of each ovoid a bud of cells grows toward the adjacent mesonephric duct, with which it joins, and the lumen of the vesicle becomes continuous with the lumen of the mesonephric duct. The wall of the vesicle becomes invaginated by a glomerular capillary tuft, and there is thus developed a mesonephric corpuscle with glomerulus and glomerular capsule joined to the mesonephric duct by means of a tubular segment which in growth in length assumes the shape of a letter S, and with further regional growth acquires secondary loops, so as to form a coil complex of varying degrees of complexity. The coiled tubular segment nearest the mesonephric corpuscle (Malpighian corpuscle) differentiates a secretory or excretory epithelium, while the remainder of the respective tubule retains a cuboidal epithelium and forms an initial collecting duct. The development of the mesonephric tubules is dysmetameric, in segments from the sixth cervical to the third lumbar and to the number of thirty to thirty-five mesonephric tubules per side in human embryos varying in length from approximately 5 to 10 mm. crown-breech length. In mammals, birds and reptiles the mesonephros forms a transitory excretory organ of early embryonic life, then ceases to function as such an organ, with degeneration and transformation of mesenophric tubules and duct. The details of such degeneration and the relative extent to which the mesonephros participates as an excretory organ in forms in which it degenerates are topics not relevant to this chapter. In such vertebrates in which the mesonephros persists so as to constitute the final organ of excretion, fishes and amphibians, it is in the main the caudal portion of the mesonephric anlage which becomes especially differentiated, with the formation of new mesonephric tubules, developed from the unused and proliferating mesonephrogenic tissue, this differentiation proceeding until the mesonephros has attained its full size.

As a type of well-developed excretory tubule of a permanent mesonephros the tubule shown in Figure 285A is presented. This figure is drawn from a reconstruction made from a series of sections of frog's mesonephros (kidney), *Rana catesbiana*. The tubule begins in a renal corpuscle, rc., and ends in a transverse collecting duct, tr. col., and has a total length of very nearly 7 mm. The renal tubule of the frog's kidney traverses the entire dorsoventral thickness of the kidney. The renal corpuscles are in the

main relatively large and of slightly flattened oval form. Structurally the renal corpuscle of the frog's mesonephric tubules consists of a glomerulus and an invaginated glomerular capsule consisting of a parietal and a visceral layer. The parietal layer of the glomerular capsule, by means of a short neck, is joined to the renal tubule with which it is continuous. The

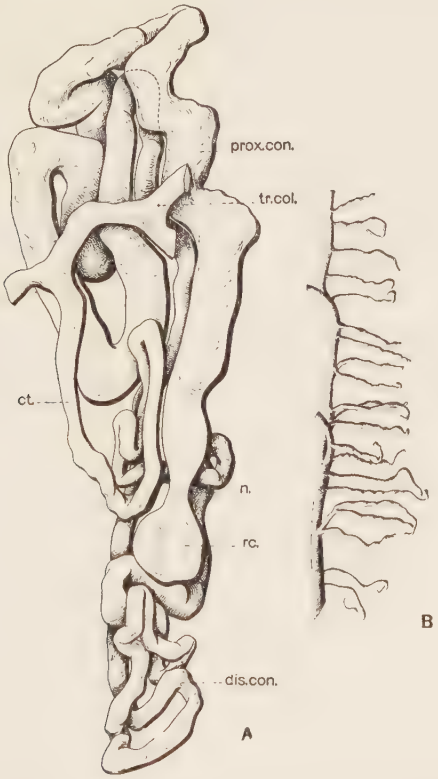

FIG. 285.—A. Reconstruction of a mesonephric tubule of a female frog, Rana catesbiana. × 80. ct., initial collecting tubule; dis. con., distal convoluted segment; n., neck; prox. con., proximal convoluted segment; rc., renal corpuscle; tr. col., transverse collecting duct. B. Corrosion preparation of transverse collecting duct with terminals of the entering renal tubules, from the mesonephros of Rana catesbiana.

tubular segment which follows the neck is here designated the proximal convoluted portion, and in the tubule figured has a length of very nearly 4 mm. and an average diameter of 75μ, it extends toward the dorsal surface of the kidney, forming bold loops and returns again toward the ventral surface to near the level of the renal corpuscle. This proximal convoluted segment is followed by a short segment (0.2 mm. length) of small diameter and in the figure practically hidden by the overlying tubular complex.

This tubular segment is in turn followed by one having a length of approximately 2.5 mm. and an average diameter of 30μ, is very much coiled and in the figure forms the coil complex seen in its lower third. In cross section of the frog's kidney these coil complexes form an irregular band extending from about the level of the layer of renal corpuscles to the ventral surface of the kidney. This coil complex is here designated the distal convoluted tubular segment, dis. con., and is succeeded by a final tubular segment which leads to the transverse collecting duct, cn. The main duct of the frog's kidney, the ductus deferens or ureter (mesonephric duct), courses along the dorsolateral margin of the kidney to its cephalic end. Into this duct empty at fairly regular intervals, and approximately at right angles, numerous transversely coursing collecting ducts which pass to near the lateral margin of the kidney (Fig. 285B. These transverse collecting ducts receive, at fairly regular intervals, the initial collecting tubules, the ends of the renal tubules. In Figure 285A the mesonephric tubule figured is so placed that the dorsal surface of the kidney corresponds to the upper border of the figure. The figure here given, made from a reconstruction, is in essentials very similar to that given by Nussbaum of a frog's renal tubule isolated after maceration in hydrochloric acid. In the illustration as given in Gaupp's edition of Ecker's and Wiedersheim's "Anatomie des Frosches," (1901), the several segments of the tubule are numbered and the descriptive text designates the same by Roman numerals I to V; comparisons are readily made; the segments indicated are essentially as given here.

The glomerulus of the mesonephric corpuscle consists of a vas afferens, a terminal aortic branch and a vas efferens, with intervening rete mirabile consisting of anastomosing capillaries with walls formed of endothelial cells capable of delimitation with silver nitrate solutions. The visceral layer of the glomerular capsule (Bowman's capsule) follows intimately the lobules and the major capillary loops of the glomerulus and consists of a delicate and apparently structureless membrana propria on which rests a flattened epithelium which has been interpreted either as a nucleated syncytial protoplasmic layer or as an epithelial layer consisting of flattened cells with demonstrable cell boundaries, the evidence at hand not being sufficiently conclusive to enable determination at the present time. The parietal layer of the glomerular capsule consists of a very definite structureless or faintly striated membrana propria on which rest relatively large, flattened pavement cells of polygonal form with granular nuclei of flattened ovoid form. The intracapsular space is relatively large. The neck of the tubule is lined by short columnar epithelium with clear protoplasm, each cell possessing several long motile cilia, with cilia directed away from the renal corpuscle. The proximal convoluted segment or tubulus contortus, which constitutes the major segment of the mesonephric tubule, is lined by relatively low columnar epithelial cells, delimited by quite distinct cell boundaries, with

prominent nuclei of spherical or ovoid form and with a relatively distinct basal striation in the protoplasm, apparently due to the presence of fine granules in the cytoreticular threads. The cells further present a very characteristic finely striated superficial border known as a "brush border," the width and distinctness of which appear to vary with phases of physiological activity, with which this border appears to be definitely related. Secretory globules or granules, often presenting light pigmentation, are also found in these cells, more often in their basal portions. In the distal convoluted portion of the mesonephric tubule, the lining cells are of short columnar or cuboidal form, with basal, striated protoplasm, but the characteristic "brush border" of the cells of the proximal convoluted portion is here lacking. The mesonephric tubule is throughout definitely bounded by a membrana propria, quite acid-resistant (hydrochloric acid), enabling maceration and subsequent teasing. The several grades of collecting ducts are lined by epithelial cells of cuboidal or short columnar form, clear cytoplasm and with distinct cell delimitation.

In attempting to analyze and determine the process of renal tubule secretion, the so-called vital stains have been extensively used. The fact that the renal epithelium of the proximal convoluted tubules can be vitally stained by use of certain of these dyes has been interpreted as indicative of the secretory function of this epithelium. The question of renal secretion as correlated with form and structure of the renal tubule will be given brief consideration after the structure of the metanephros has been discussed. The subject is broached at this time, since very fundamental experimental observations on renal secretions are related to the mesonephros of the frog and, to a less extent, to the mesonephros of other vertebrate forms with permanent mesonephros. A. N. Richards, in collaboration with co-workers, has devised a technique for the collection of glomerular urine from a single mesonephric renal capsule, by means of a delicate capillary pipette, which enables comparison of glomerular urine with simultaneously collected bladder urine. The method was extended for the purpose of introducing certain stains and other substances into the intracapsular space of the mesonephric corpuscle, by means of a delicate capillary pipette and without injuring the glomerulus and later by histological methods identifying the same stain in the renal epithelium of the proximal convoluted tubule. By experiment and by comparison it has been determined that certain stains introduced into the glomerular capsule are later found distributed in the renal epithelium of the proximal convoluted tubule segment, much the same as when the same stains are introduced into the circulation and excreted through the kidney. Extended series of experiments taken in relation with other corroborative evidence permit the interpretation that the presence of stain in the renal epithelium is not proof of the secretion of such a stain by this epithelium, since stain intro-

duced into the renal corpuscle appears to be resorbed from the lumen of the tubule; the resultant histological pictures being essentially the same as when the stain is introduced into the circulation and excreted in great dilution through the renal corpuscles. The presumption seems warranted that the vital dyes used in these experimental observations were excreted through the glomeruli and in part resorbed by the renal epithelium of the proximal convoluted segment as the excreted fluid passed through the mesonephric renal tubule.

III. METANEPHROS

The metanephros or the permanent or final kidney of the amniotes—reptiles, birds and mammals—like the mesonephros, has a double origin, the duct system developing from a primary bud derived from the mesonephric duct, the glandular tubular portion from the metanephrogenic tissue. In a human embryo of approximately 5 mm. crown-breech length, there develops from the dorsomesial portion of each mesonephric duct, just before this terminates in the cloaca, a bud which, on growth dorsalward, soon comes into close relation with that portion of the nephrogenic tissue which lies caudal to the twenty-sixth and twenty-seventh segments, segments in which the nephrogenic tissue shows interruption. The metanephric bud growing from its origin on the mesonephric duct in a craniodorsal direction assumes a flask shape with an ampullar end, the anlage of the primary renal pelvis, which becomes capped by metanephrogenic tissue, while the narrower stalk forms the primary ureter. It is not the purpose here to trace in full the developmental history of the metanephros. However it is thought helpful to trace hastily the main phases of the development of the metanephric renal tubules and collecting ducts, since certain topographical relations of different parts of the renal tubules are clearly brought to view through a study of the development of the renal tubules and more intricate relations are simplified if known through development.

By elongation of the primary ureter the primary renal pelvis attains a position at the level of the second lumbar segment in a human embryo of 10 to 12 mm. crown-breech length. By cranial and caudal growth of the primary renal pelvis the cranial and caudal poles are established. By regional growth in the primary renal pelvis, primary evaginations are formed, varying somewhat in number in different forms, but usually numbering not more than four, six or eight. These primary buds form the anlagen of the primary collecting tubules, and differentiate in succession rather than simultaneously, and as they develop they become capped by metanephrogenic tissue. The peripheral end of each primary collecting tubule forms an ampullar enlargement, flattened toward the periphery. By further evagination successive generations of collecting tubules are formed, to the

number of two, three or four for each collecting tubule of a former generation. Thus by the time that the human embryo has reached a crown-breech length of about 20 mm., from four to five generations of collecting tubules have been formed or are in anlage (Fig. 286). The rate of formation of collecting tubules is not the same for all parts of the developing duct system. The process of evagination from the ampullar end of the collecting tubules continues in the human embryo to about the end of the fifth month, by which time twelve to thirteen generations

Fig. 286.

Fig. 287.

Fig. 286.—Reconstruction of a portion of the ureter, the renal pelvis and the primary collecting tubules, through three successive divisions, in a human embryo of 20 mm. head breech length. × 50.

Fig. 287.—From a sagittal series of a human embryo of 18 mm. crown breech length. × 233. Development of the renal tubules. a, primary collecting tubule with ampullar enlargements; b, b′, inner zone of the metanephrogenic tissue; c, outer zone of metanephronic tissue; d, mesodermal anlage of the renal capsule; e, renal vesicle.

of collecting tubules have been formed. As in the beginning, so with the successive generations of collecting tubules, the ampullar ends of each generation of collecting tubules become capped with metanephrogenic tissue, this proliferating to meet the needs for the anlagen of successive generations of renal tubules.

The anlage for the first metanephric tubules to develop in the human embryo is noted when this has attained a crown-breech length of 18 to 20 mm. In Figure 287 is shown a portion of a section from a series of longitudinal sections passing through the metanephros of a human embryo, 18 mm. crown-breech length, presenting essentially the same collecting tubular development as that shown in the reconstruction shown in Figure 286. In Figure 287 is shown one of the collecting tubules of the third generation, with ampullar enlargements and lateral extensions, the anlage of the fourth

generation of collecting tubules. The ends of the lateral extensions are capped with metanephrogenic tissue with an inner, more deeply staining zone formed of epithelioid cells, constituting the inner zone of the metanephrogenic tissue. On the right of the figure it is evident that a portion of the inner zone of the metanephrogenic tissue is separating in the form of a nodule from the remainder of the inner zone. On the left side of the figure,

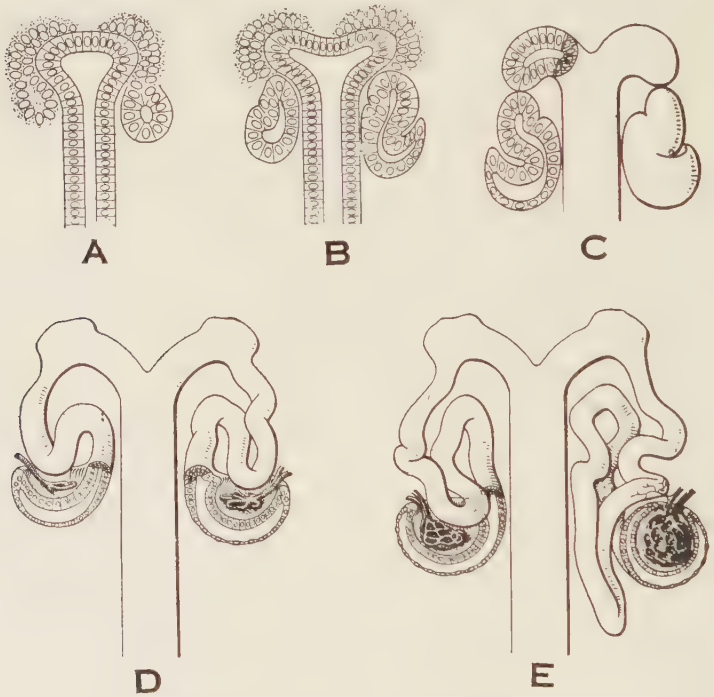

FIG. 288.—Semi-diagrammatic figures of the anlage and differentiation of the renal vesicles and early developmental stages of the renal tubules of mammals. A and B, anlage and differentiation of the renal vesicles as seen in sagittal sections; C, section and outer form of S-shaped tubular anlage before junction with collecting tubule; D and E, successive stages in the development of the renal tubule and the glomerular capsule, beginning with a well formed S-shaped tubular anlage.

by further differentiation and rearrangement of cells, a vesicle with small lumen has been developed, completely separated from the metanephrogenic tissue. Such vesicles are the anlagen of renal tubules and are known as metanephric or renal vesicles ("vesicules rénales," Emery, 1883). Such renal vesicles are at this stage of differentiation completely detached from the developing collecting tubules. The renal vesicles differentiate in successive generations paripassu with the successive generations of collecting ducts. The morphogenesis of the renal tubules from the renal vesicles is

here shown in a series of semi-diagrammatic figures based on reconstructions (Fig. 288 A,B, C, D, E) and a series of figures illustrative of a series of models of successive stages in the development of the human renal tubule, made by wax-plate reconstruction methods. It is hoped that these series of figures may obviate the necessity of extensive description.

In the following discussion of the differentiation of the renal tubules from the renal vesicle the part of the vesicle directed toward the collecting tubule and its ampullar enlargement is designated its mesial wall; the part of the vesicle directed away from the collecting tubule, its lateral wall. A renal vesicle soon after its formation increases in size by means of active cell proliferation and elongates somewhat, thus coming into close relation with the collecting tubule and especially its ampullar enlargement. The upper portion of its outer wall thickens, partly by means of cell proliferation, partly by mere elongation of existing cells. This is not the thinner wall of the vesicle, as is stated by Felix (1912). In the area of thickening there differentiates a cleft, which deepens as it enlarges and, in part, splits the outer wall of the vesicle into two layers, while the lumen of the vesicle becomes hook-shaped (B of Fig. 288). As the renal vesicle enlarges and as a result of regional growth, a slight depression appears on the upper portion of the inner wall of the vesicle, this depression emphasizing the curvature of the vesicle (C of Fig. 288). By deepening of the clefts on the outer and inner wall of the vesicle, this is changed in shape so as to assume the form of a letter S, and while this S-shaped tubular anlage is differentiating by regional growth in respective regions of the vesicle, it acquires union with the ampullar end of the adjacent collecting tubule, and the lumen of the collecting tubule becomes continuous with that of the S-shaped tubular anlage.

The S-shaped tubular anlage of the renal tubule is fundamental, whether considered in its ontogenetic or its phylogenetic development. To characterize this stage more fully, one may speak of an upper S-curve, a middle S-segment and a lower S-curve. The complex as a whole presents an inner and an outer side, or face, with reference to its relative position in regard to the collecting duct with which it is attached. The greater portion of the lower S-curve is from the beginning not of tubular form, but presents the form of a double-walled shallow bowl, or the form of an oyster shell, with the concavity directed toward the periphery of the developing kidney. The cells forming the concave wall are of columnar shape; those forming the convex wall are, almost from the beginning, of flattened polyhedral form. In the reconstruction shown in Figure 288 it will be seen that what in favorably directed sections appears as the lower S-curve is in reality a shallow bowl. The concavity of this bowl is early filled by a vascularized mesenchyme which forms the anlage of the glomerulus of a renal corpuscle, while the double-walled lower S-curve of the S-shaped tubular anlage is destined to form the visceral and parietal layers of the glomerular (Bowman's) capsule

of a renal corpuscle (Malpighian corpuscle). The saucer form or shell-like form of the renal corpuscle in further development assumes a spherical

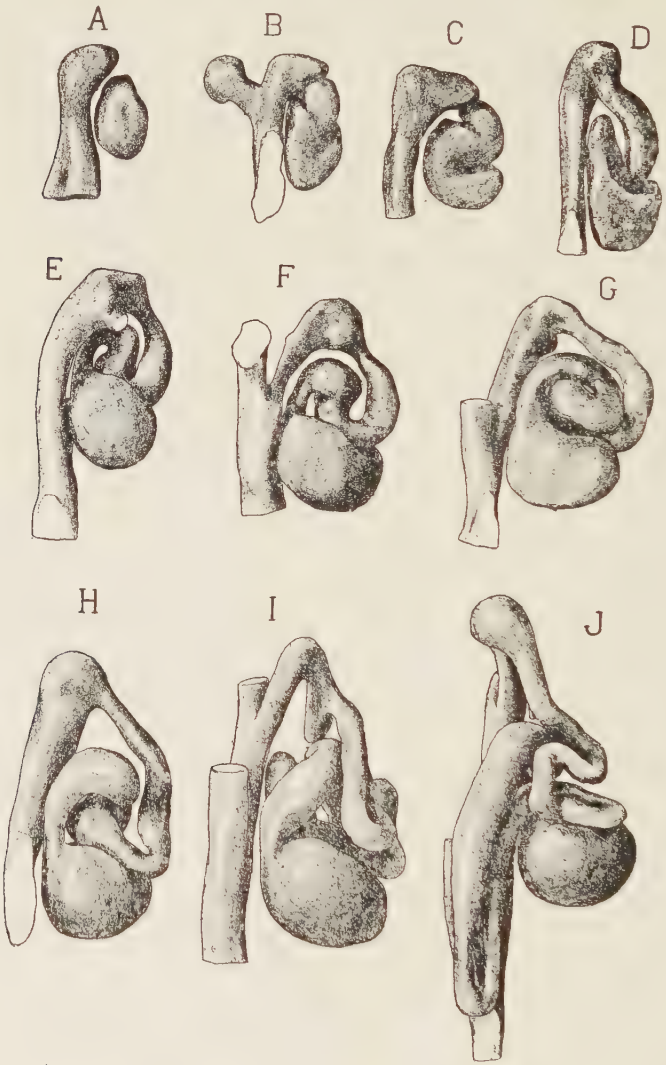

FIG. 289.—A series of models, A to J, showing successive stages in the anlage and development of renal tubules with a portion of the collecting tubule to which each is attached. Reconstructed from a series of sections of the kidney of a human fetus of the seventh month. × 160.

form, partly by growth in depth of the concavity and partly by the growth of a ledge or shelf which develops in the region where the capsular portion of the lower S-curve joins the tubular portion. This crescent-shaped shelf

gradually narrows the opening into the concavity, the narrowed opening ultimately serving as the vascular pole of the renal corpuscle. The S-shaped tubular anlage, thus early fixed at the proximal and distal ends by attachment to the collecting tubule on the one hand and the fixation at the developing vascular pole on the other hand, of necessity, in growth in length, acquires further curvatures which affect almost simultaneously different parts of the S-shaped tubular anlage, in the upper S-curve, in the region of junction of lower S-curve with the middle S-segment and in the middle S-segment. The secondary curvature, which is acquired relatively early, approximately in the middle of the upper S-curve, forms the anlage of the distal convoluted coil complex. The secondary curvature, acquired in the region of the junction of the lower S-curve and the middle S-segment, forms the anlage for the proximal convoluted segment. The remaining portions of the middle S-segment with the distal portions of the upper S-curve by elongation form the anlage of a long loop, the medullary (Henle's) loop, which on further growth and on differentiation of the renal corpuscle grows over the mesial side of the renal corpuscle, always with essentially the same topographical relations of the loop to the renal corpuscle and other tubular segments but with slight difference in rotation on longitudinal axis with reference to the collecting tubule.

This general statement with reference to anlage and relations of different parts of the metanephric renal tubule, somewhat comprehensive in scope, seems warranted and is evidenced by numerous reconstructions of different stages in the development of the renal tubule, not only for human but for a series of mammalian forms, and is documented in the figures of reconstructions presented in Figure 289. Having in mind the above reference to differences in slight rotation on the longitudinal axis of the entire complex of a renal tubule, it may be stated that the semi-diagrammatic figures D and E of Figure 288 give four successive stages in the development of a metanephric renal tubule, which present relatively clearly the interrelations of the different parts of a renal tubule and its relation as a whole to the collecting duct. It is evident that from the fleginning the greater part of the coiled tubular complex of a renal tubule comes to lie between the renal corpuscle and the collecting tubule, with the proximal portion of the tubule in mesial position with reference to the distal portion of the tubule. From the viewpoint of development it is incorrect to name the proximal descending limb of the medullary loop as the lateral limb, and the distal, ascending limb as the mesial limb, as is done by Peter and concurred in by Felix. Further details as to the development of the renal tubule, collecting ducts and the kidney as a whole will be given consideration in the discussion of the form and structure of the metanephric renal tubule when such consideration is thought helpful in elucidating adult structure.

The metanephric tubules of reptiles and birds may receive brief consideration before entering upon a discussion of the mammalian renal tubule.

1. *Reptilian metanephric tubules:*

The metanephric tubules of reptiles may be looked upon as comparable to the S-shaped developmental stage of the mammalian renal tubule. In the fully developed renal tubule of mammalia one may recognize an upper and a lower S-curve and a middle

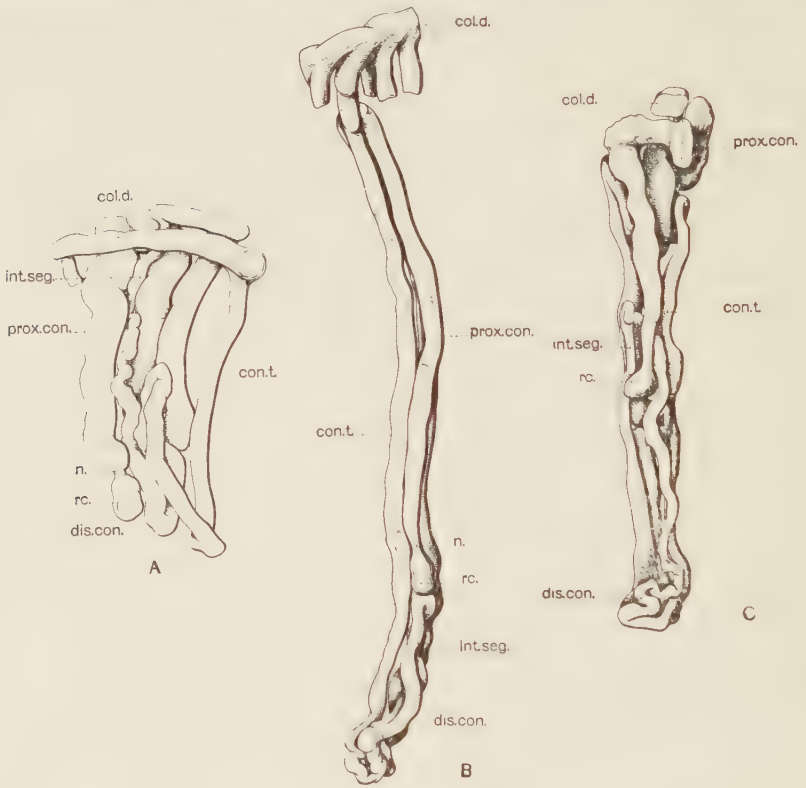

FIG. 290.—Reptilian metanephric renal tubules. A, reconstructed from the kidney of a turtle, Chrysemys marginata; B, reconstructed from the kidney of Alligator mississippiensis; C, reconstructed from the kidney of a snake, Eutaenia sirtalis. × 80. col. d., collecting duct; con. t., initial collecting tubule; dis. con., distal convoluted segment; int. seg., intermediate segment; n., neck; prox. con., proximal convoluted segment; rc., renal corpuscle.

S-segment. The essentials of the form of renal tubules of reptilia are here presented in several reconstructions of renal tubules from the developed metanephros of turtle, alligator and snake, illustrations of which are shown in Figure 290. Zarnik, who has given a good account of the reptilian kidney with consideration of the pertinent literature, based his observations in the main on teased preparations, while the figures of reptilian tubules

here given are based on reconstructions. The form and the structure of the reptilian renal tubules studied are in essentials quite similar in the several forms investigated, so that a consideration of the renal tubule of the turtle, *Chrysemys marginata*, will suffice to portray the essential details. In the turtle each metanephric renal tubule (Fig. 290, A) begins in a relatively small renal corpuscle of average diameter of about 55μ, consisting of glomerulus and glomerular capsule, with visceral and parietal layer, the latter continuous with the respective renal tubule by means of a short and narrow neck. The visceral layer of the glomerular capsule presents a distinct epithelial layer, at times formed by flattened polygonal cells, at times by low cubic cells, forming an epithelium which is suggestive of developmental stages of the mammalian renal corpuscle. The epithelium of the visceral layer becomes continuous with that of the parietal layer at the vascular pole of the renal corpuscle. The epithelium of the parietal layer, resting on a distinct, homogeneous membrana propria, is of the pavement or squamous type. The glomerulus is formed of relatively wide capillary loops. The relatively short neck of the reptilian renal tubule is lined by cuboidal or short columnar epithelial cells, possessing long cilia. The short neck is followed by what is here designated the proximal convoluted segment, the length of which, in the tubule figured, measures 1.5 mm., the whole tubule having a length of 3.3 mm. The proximal convoluted segment has an average diameter of 65μ and presents several bold folds arranged so as to simulate a letter N; the several parts of the N-shaped tubule presenting secondary curvatures. The epithelium lining the proximal convoluted segment is of short columnar form, with prominent spherical nuclei, with a protoplasm having basal striations and a distinct superficial brush border which varies in detail of structure and width coincidentally with different phases of functional activity.

The proximal convoluted tubular segment is succeeded by a short tubular portion having an average diameter of 20μ and a length of about 0.3 mm., and here designated the intermediate segment and in the several reptilian forms studied is lined by a simple columnar ciliated epithelium. The intermediate segment may be regarded as representative of a portion of the medullary loop of mammalian renal tubule. The intermediate portion of the reptilian renal tubule is followed by a tubular segment, here designated the distal convoluted segment, which has a more or less distinct coil complex in the region of the level of the renal corpuscle, and in the tubule figured, has a length of nearly 1 mm., an average diameter of 40μ and is lined by a low columnar epithelium presenting basal striations but not the superficial brush border. The distal convoluted segment is followed by a tubular portion, here designated the initial collecting tubule, which varies somewhat in length for different tubules, but has an average length of about 0.5 mm. and is lined by an epithelium having low columnar form, with distinct cell delimitation and relatively clear protoplasm. The general duct system of the reptilian kidney is relatively simple, the ducts leading through several divisions to a ventrally placed ureter. The ducts throughout are lined by columnar epithelium having distinct cell boundaries, prominent ovoid or spherical nuclei and a clear protoplasm. The renal tubules of *Alligator mississippiensis* and the snake, *Eutaenia sirtalis*, shown from reconstructions in B and C of Figure 290, in the main features resemble closely in form and structure the renal tubule of *Chrysemys marginata*, above described. Slight differences in form are evident, but the different tubular segments enumerated may be determined readily in each and the close resemblance in detail of structure of the several segments noted. The alligator tubule figured measures 4.5 mm. and the snake tubule measures 4.0 mm. These measurements may be taken as giving approximately the length of renal tubules in the forms considered. There is to be noted more difference in the detail in arrangement of the duct systems in the forms studied. In the alligator there is found a dorsal and a ventral ureter, so that the kidney substance may be said to be arranged in a dorsal and a ventral

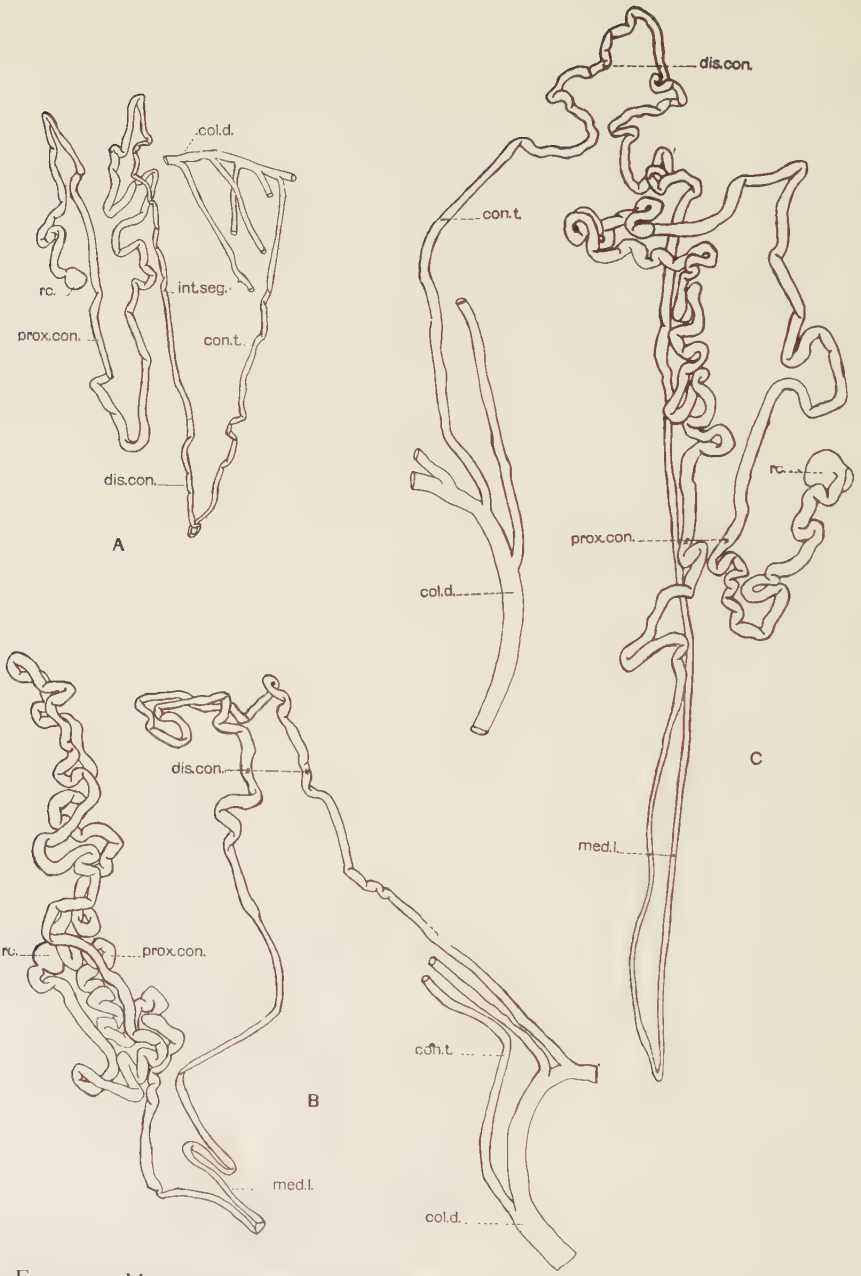

FIG. 291. Metanephric renal tubule of birds, Gallus domestica, completely isolated by teasing, showing renal tubules of a reptilian type, A; tubules which present a transition between a reptilian and a mammalian type, B; and mammalian type or avian renal tubule, C. × 40. col. d. collecting duct; con. t., initial collecting tubule; dis, con., distal convoluted segment; int. seg., intermediate segment; med. l., medullary loop; prox. con., proximal convoluted segment; rc., renal corpuscle.

half. In the ophidian forms studied the ureter was found to occupy a ventral and a ventromesial position. These differences in the relative position of the ureters cause a difference in the form and arrangement of the primary and secondary collecting ducts. In all of the reptilian forms studied the terminal collecting ducts hold essentially the same relations to the renal tubules to which they are united by means of the initial collecting tubules.

2. *Avian metanephric tubules:*

The description here given of the form and the relations of the avian metanephric tubule is based on the study of the renal tubules in *Gallus domestica* and by methods of maceration and teasing. The kidney of the bird is an elongated lobulated organ with the ureter on the ventral and the mesoventral side. The ventral and mesoventral portion of each lobe presents a short renal pyramid, nearly wholly surrounded by cortex. The renal tubules forming the periphery of a lobe present a form which is very similar to that described for the renal tubule of the reptilian metanephros. The tubules found in the more central portion of a lobe have a form and arrangement of parts which resemble the mammalian renal tubule. There are transition types from one form of tubule to the other, in an intermediate zone. The avian renal tubule figured in A of Figure 291 was taken from the periphery of a lobe and presents a form which is very similar to that described for the reptilian metanephric tubule. Avian renal tubules similar to this one begin with a relatively small renal corpuscle joined to the tubule by a short narrow neck. The total length of this tubule is 6.5 mm. of which the proximal convoluted segment measures 3.8 mm., arranged in the form of a letter N, each part of the N-form presenting a number of secondary curves. A relatively short intermediate segment follows and this is succeeded by the distal convoluted segment arranged in a number of compact loops, found separated in the figure. A short initial collecting tubule leads to the terminal collecting duct.

In B of Figure 291 is presented the drawing of a tubule from the transition zone. This tubule has a total length of 13 mm., with a proximal convoluted segment measuring 7.5 mm. This is followed by a short small tubular segment arranged in the form of a loop, which from its position may be known as the medullary loop, and is succeeded by the distal convoluted segment with distinct secondary loops. In C of Figure 291 is illustrated an avian renal tubule which in form and arrangement of parts resembles very closely a mammalian renal tubule. It was teased from the central portion of a lobe of the kidney of an adult rooster, and was very successfully mounted in the position shown in this figure. The tubule measured 15.5 mm. from renal corpuscle to terminal collecting duct. Tubules measuring approximately 18 mm. were successfully isolated from the kidney of this same bird. In tubule C, Figure 291, the renal corpuscle is of nearly spherical form and measures about 100μ in diameter. A relatively short neck unites the renal corpuscle to the proximal convoluted segment, which segment has a length of 8.5 mm. and is arranged in the form of bold loops with numerous secondary loops. The proximal convoluted segment is followed by a relatively straight tubular segment of small diameter and bent in the form of a loop which extends for a short distance into the medulla, having a total length of 4 mm. and designated the medullary loop. This loop segment is followed by the distal convoluted segment, presenting two primary and numerous secondary loops. The relations of the several parts of this tubule were in the main essentially the same, as ascertained before complete teasing was attained, and as found for homologous parts in the mammalian renal tubule to be discussed in the following pages. A study of the figures of the different types of avian renal tubules as here presented indicates that within the same lobule of the bird's kidney there is found a transition from the simpler type of metanephric tubule as found in reptilia to the more complex type with the medullary loop as found in mammalia.

3. *Mammalian metanephric tubule:*

Two methods are available for determining the form of the mammalian renal tubule, namely, (a) the method of wax-plate reconstruction, the more satisfactory method within the limits of its applicability, since it permits reproduction of the several parts of the renal tubule in their normal relation and in permanent form; and (b) the method of maceration and teasing, permitting isolation of long tubular segments or complete tubules in continuity but of necessity destroying details of topographical relation of the several parts.

The length of the mammalian renal tubule in an approximately fully developed kidney of all but the smallest mammals is such, that with the magnification which it is necessary to use, the models attain such size that manipulation is quite impossible and the tracing of tubular segments, especially the long medullary loop, a matter of great difficulty and uncertainty. The reconstruction of a portion of the renal tubule, even though it involves the coil complexes and their relation to the renal corpuscle, is a procedure quite possible and has led to definite extension of our knowledge as regards both form and structure of the mammalian renal tubule. The reconstruction of a renal tubule of a newly born cat and rabbit at a magnification of 400 diameters results in models having an over-all length of nearly five feet. For the study of developmental stages of mammalian renal tubule the method of wax-plate reconstruction is quite adequate. The method of maceration and teasing is the older of the two methods referred to and has been widely used. It has the great advantage of placing at the disposal of the observer great numbers of tubular segments and perchance complete tubules, enabling comparisons and the determination of the relations of numbers of tubules, not readily gained, unless extensive reconstructions are made. However, the method is not without distinct limitations and it is only with great care and patient effort that successful teasing of mammalian renal tubules is attained. By modification of maceration methods to meet special needs it has become possible to isolate completely renal tubules in an adult mammal, making it possible to trace in sequence in a single tubule the several structurally divergent tubular segments, and note their size, relative length and topographical relations.

As macerating media, hydrochloric and nitric acid have been extensively used in combination or separately. Peter employed very concentrated solutions of hydrochloric acid for the purpose of kidney tissue maceration and was able to isolate, study and sketch relatively long segments of renal tubules of several mammals and of man. Zarnik, with slight modification of the method used by Peter, studied the renal tubule of *Echidna* and was able to isolate entire renal tubules in this form, tubules which present structural peculiarities characteristic of late fetal stages in higher mammalian forms. The desirability of extending the method of maceration in its application to the elucidation of kidney structure, more particularly of extending the method so as to obtain more uniform maceration throughout the relatively large pieces of kidney substance which it is found necessary to use, and to obtain more equal maceration of the cortex and medulla as to time, was met by Huber by injecting a concentrated solution of hydrochloric acid into the renal vessels under relatively high pressures in fresh tissue, after partial irrigation of the vessels. The method has been used with success in isolating complete renal tubules, from renal corpuscles to collecting ducts, in rabbit, cat, dog, guinea pig and rat, with not quite complete success in man. There has not been opportunity, for want of adequately fresh material, to extend the observation so as to isolate complete adult

human renal tubules. The method of maceration by means of injecting 75 per cent hydrochloric acid into the blood vessels, as well as surrounding the block of tissue with this macerating fluid, was found to give much more uniform results and to enable isolation and teasing of mammalian renal tubules to an extent not possible by other methods.

After requisite maceration and thorough washing in distilled water it was found possible to stain tissue blocks in Mayer's hemalum, which appears to neutralize the acid remaining in the tissue while staining the same. The tissue pieces become pliable and the stain is developed by placing them for some time in very dilute ammonium hydrate solution before final teasing is undertaken. The teasing is carried on under stereoscopic binocular, in water and with very fine needles. Relatively long tubular segments are easily separated and small portions of tissue are readily sufficiently separated to admit of determining tubular parts and noting their general topographical relations. Under favorable conditions complete renal tubules of adult mammals can be isolated. They are best studied in water with the binocular so as to be able to study the tubular complex from all sides, to draw apart coil complexes and allow the same to resume pre-existing relations. It is hazardous to postulate relative to the different parts of a renal tubule and their relation to each other, unless the respective tubule has been completely teased to the extent that it becomes possible to unravel all of the coil complexes and still maintain an unbroken tubule. It has been found exceedingly difficult to mount in anything like permanent form completely isolated mammalian renal tubules.

In an introduction to a more detailed consideration of the form and structure of the mammalian renal tubule, the interrelation of its parts and their more definite topographical position in the kidney substance, it is deemed helpful to discuss briefly a type form of the mammalian renal tubule and give general consideration to the several structurally different tubular segments which in definite sequence make up a renal tubule; to note in general the relations which they have one to another, and to present a simplified nomenclature which will be used in subsequent pages and is suggested for general use. The general statements to be made relative to the mammalian renal tubules are here based on the renal tubule shown in Figure 292, giving a camera lucida drawing of a completely isolated and successfully mounted renal tubule from the kidney of an adult rabbit, and presenting a tubule of average length and structure. The several tubular segments, indicated by means of reference legends, can be followed with ease. Attention is called to the fact that the figures here given which portray the several types of metanephric tubule have all been drawn to scale, the reptilian metanephric tubules at magnification of eighty diameters, the avian metanephric tubule at forty diameters and the mammalian renal tubule shown in Figure 293 at a magnification of twenty diameters. Therefore, quite direct comparison can be made as to length and complexity of form of the metanephric tubule as noted in the phylogenic scale.

The metanephric mammalian renal tubule begins (following in designation and nomenclature the course of the urine flow) in a renal corpuscle (corpusculum renis, Malpighian corpuscle) of approximately spherical form and of varying size, its size being somewhat commensurate with the length

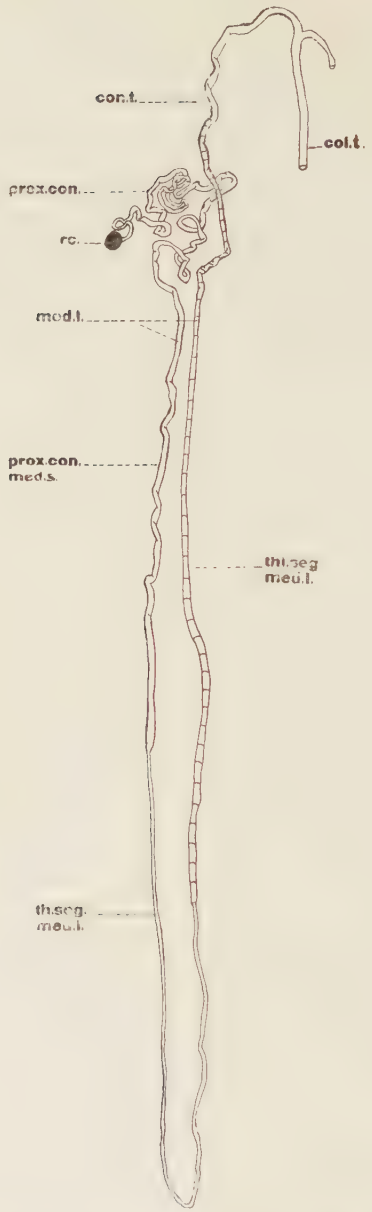

FIG. 292.—Metanephric renal tubule of adult rabbit, completely isolated by teasing; camera lucida drawing. × 20. col. t., cortical collecting tubule; con. t., initial collecting tubule; med. l., medullary loop; prox. con., proximal convoluted segment; prox. con. med. s., proximal convoluted, medullary segment; rc., renal corpuscle; th. seg. l., thin segment of medullary loop; thi. seg. med. l., thick segment of medullary loop.

of the renal tubule. The diameter of the mammalian renal corpuscle varies between 100μ and nearly 200μ. It presents a vascular and a urinary pole which are seldom even approximately opposite. It consists of a glomerulus (glomerulus renis) and a glomerular capsule (capsula glomeruli, Bowman's capsule) presenting a visceral and a parietal layer.

The glomerulus, a rete mirabile, has an arterial vas afferens and an arterial vas efferens. The parietal layer of the glomerular capsule, constricts into a funnel shape at the urinary pole and becomes continuous with a relatively short and narrow tubular segment, known as the neck of the renal tubule, hidden behind the renal corpuscle in the Figure 293. The neck is followed by a very characteristic tubular segment, forming a distinct coil complex, consisting of a series of loops, placed in relatively close juxtaposition and generally in close proximity to the renal corpuscle of the respective renal tubule. This coiled tubular segment finally extends toward the medulla, and without changing its diameter or its structure assumes a more definite course, at times nearly straight, again slightly coiled, wavy or serpentine and generally extends for a distance into the medulla. I have designated this tubular segment of the mammalian renal tubule as the proximal convoluted portion with medullary segment. It has been variously named, Hauptstück, pars contorta 1, tubulus contortus, portio convoluta, Konvolut, tube contourne, and the medullary segment as the spiral or wavy portion or segment, Endstück, end segments, or segment of Schachowa. It constitutes that portion of the renal tubule which has the greatest diameter and is lined by an epithelium which is here more specifically designated as the renal epithelium, characterized by epithelial cells having protoplasm with basal striations and a specific superficial brush border. This tubular segment has been designated "proximal convoluted portion" by reason of its proximity to the renal corpuscle and "with medullary segment" by reason of the fact that an integral portion of this tubular segment extends toward and into the medulla. Further justification for designating a segment of the mammalian renal tubule as the "proximal convoluted tubule with medullary segment" is found in the fact that in the reptilian metanephric tubule and in the simple avian metanephric tubule in which no medullary loops appear there is found a continuous tubular segment of relatively large diameter, which follows immediately on the renal corpuscle and neck, is lined by the characteristic renal epithelium with superficial brush border and was designated proximal convoluted segment. In the mesonephric tubule of amphibia that part of the renal tubule which joins the renal corpuscle is of relatively large diameter and is lined by an epithelium which in structure is similar to that lining the proximal convoluted segment of the metanephric tubule, thus it also forms a homologous segment of the renal tubule and was designated proximal convoluted segment. In discussing the pronephric tubule there was charac-

terized a tubular segment, the same in relative position with reference to the glomerulus or the nephrostome lined with an epithelium with superficial brush border, which thus may be regarded as homologous with the proximal convoluted segment of the mesonephric and metanephric tubules of higher vertebrate forms.

The renal tubule shown in Figure 295 has a total length of nearly 24 mm. measured from renal corpuscle to terminal collecting duct. The proximal convoluted segment measured from the region of the glomerular corpuscle to the region of the cross placed by the side of the descending limb of the relatively long loop, thus to the end of the medullary segment of the proximal convoluted portion, has a length of 9.4 mm. The relatively straight tubular segment arranged in the form of a simple long loop, which follows the proximal convoluted segment, is a distinctive differentiation of the renal tubule which makes its appearance in the avian kidney in the renal tubules which occupy the central portions of the renal lobes. In general terms it represents a mammalian differentiation of the renal tubule foreshadowed in certain avian renal tubules. The loop varies greatly in length in different renal tubules. It is longest in renal tubules that fall to the earlier generations of mammalian metanephric renal tubule developed, and becomes progressively shorter with successive generations of renal tubule formation and is shortest in those last developed. This tubular segment consists of a relatively long tubule, bent upon itself to form a simple loop with nearly parallel sides. It should be named without giving primary consideration to its epithelial lining, since this varies, in structure and in detail, with distinct regional distribution of the several types of epithelium found in this loop. This loop segment of the mammalian renal tubule, in practically all instances, extends into the medulla for a distance; therefore, considering position alone, it is here designated as a medullary loop. In description the loop is divided into a proximal descending arm, a loop and a distal ascending arm. This tubular segment was first recognized structurally by Henle (1862) but wrongly interpreted. The work of Henle was reviewed by v. Kölliker in the fourth edition of his well-known textbook (1863) and named the loop of Henle. This structure was much more accurately and definitely characterized by Schweigger-Seidel (1865).

In the tubule shown in Figure 293 this loop, measured from a little below the level of the renal corpuscle to its return to the same level, has a total length of approximately 16 mm. A portion of this loop, in both the descending and the ascending limb, lies within the level of the cortex. The loop may extend through nearly the whole width of the medulla. The proximal portion of the proximal descending limb of the medullary loop is formed by the medullary segment of the proximal convoluted portion, which extends for a distance into the medulla without loss of diameter or change of structure. The tubule forming this portion of the medullary loop

has a diameter which varies from 50μ to 60μ. Quite suddenly the tubule narrows to a tubular segment having a diameter of 15μ to 20μ and lined by a thin flattened epithelium. This thin segment of the medullary loop, a distinctively mammalian differentiation, varies greatly in length in the different tubules within the same kidney. It may, as in the tubule figured, involve the distal portion of the descending proximal limb, the loop itself and the proximal portion of the ascending distal limb, thus the lower portion of the medullary loop as placed in the figure; or it may be confined to the proximal limb of the loop, terminating before the loop is reached, with

FIG. 293.—Three stages in the development of the mammalian renal corpuscle, from rabbit embryo near term, given to show the development of the visceral and the parietal layer of the glomerular capsule. × 20. A, from renal tubule in S-shaped stage, lower S-curve, visceral layer glomerular capsule of columnar cells, parietal layer of pavement cells; B, intermediate stage, visceral layer glomerular capsule of cuboidal cells, parietal layer of pavement cells; C, structurally developed mammalian renal corpuscle, visceral and parietal layer of glomerular capsule lined by pavement cells.

gradations, in length of this segment of medullary loop, between the two extremes specifically designated. This thin tubular segment of the medullary loop is followed by one in which the diameter varies from 30μ to 40μ, the thick segment of the distal ascending portion of the medullary loop. This thicker segment is lined by a low columnar epithelium with cells having protoplasm with basal striation. There is not present a superficial brush border. This thicker tubular segment extends to the end of the distal ascending limb of the medullary loop. It is thus evident that in the mammalian renal tubule, each medullary loop sufficiently long to extend into the medulla consists of a thick proximal portion, an intervening thin segment which varies greatly in length, and a distal segment which in diameter is not as great as the proximal medullary segment, but is always

distinctly thicker than the intervening thin segment, each distinctive portion having a special epithelial lining.

The distal ascending limb of the medullary loop is followed by a tubular segment which was first clearly characterized by Schweigger-Seidel (1865) as having a larger diameter than the ascending limb of the medullary loop, as being somewhat irregular in contour and having an irregular course. It was named by him the Schaltstück. This tubular segment is quite easily recognized in teased preparations, constituting a tubular portion in which the renal tubule, distal to the medullary loop, presents an irregular contour and an irregular zigzag course, the configuration simulating a letter U, the letter N or the letter Z, each of the parts presenting secondary folds. The end of the distal arm of the medullary loop remains, from the time in development when it can be recognized as a loop, in close relation to the renal corpuscle of the respective renal tubule, either passing over it at a variable distance from the urinary pole or in close relation to it. The coil complex following the ascending distal limb of the medullary loop is here designated as the distal convoluted segment and is found usually in close relation to the renal corpuscle of the respective tubule and, in the main, lateral to the proximal convoluted segment of the same tubule, when considered in relation to this and to the collecting duct. The distal convoluted segment forms a much shorter component of the renal tubule than does the proximal convoluted segment and is lined by a structurally simpler epithelium. The distal convoluted segment is easily recognized in the simple avian and reptilian metanephric renal tubule, in which it forms a relatively long tubular segment, which is found more intricately folded than in this segment in the renal tubules of higher mammals. A distal convoluted segment was recognized in the mesonephric renal tubule of the frog and described as such. The tubular segment, here known as the distal convoluted segment, has long been known in literature under various designations: Schaltstück, interstitial segment, intercalated segment, tubulus contortus II, and pars convoluta II. It deserves recognition and designation as a definite tubular segment.

The distal convoluted segment is followed by a tubular segment which unites the renal tubule to the terminal collecting duct. It is here designated the initial collecting tubule, a term which has been used in the description of the simpler avian and reptilian metanephric tubules and the tubules of the mesonephros. This segment unites the renal tubule to the collecting duct and in its course is found the region of the juncture of the developing S-shaped stage of the renal tubule and the ampullar enlargement of the collecting duct, although the exact place of junction cannot be determined after this has been effected. The length of the initial collecting tubule varies quite markedly in different tubules, depending somewhat on the position of the renal corpuscle of the respective tubule with reference to the

periphery of the renal cortex. In the course of the initial collecting tubule the structure of the epithelium changes from that of a secretory or excretory epithelium of the renal tubule to that of the collecting duct.

As here enumerated and briefly considered in the general discussion of the mammalian renal tubule, this consists of the following more or less clearly defined tubular segments, in recapitulation mentioned in serial order, giving to each segment the designation suggested: (1) renal corpuscle, with glomerulus and glomerular capsule, this with a visceral and a parietal layer; (2) neck segment; (3) proximal convoluted portion with medullary segment; (4) medullary loop, with descending proximal limb, loop and ascending distal limb; (5) distal convoluted segment, and (6) initial collecting tubule. These tubular portions (exclusive of the glomerulus) are developed from the renal vesicles differentiated from the metanephrogenic tissue. This nomenclature is applicable to the different parts of the simpler avian and reptilian metanephric tubules and the mesonephric tubules, except for division 4, medullary loop, which as such is not found in these simpler forms, its place being taken by a short tubular segment of small diameter and distinctive epithelium, which has been designated the intermediate segment. Braus (1924) has coined the term "nephron" to give conception to the tubular unit made of successive diversified parts as discussed in the preceding pages.

IV. CYTOLOGICAL STRUCTURE OF THE DIFFERENT PARTS OF THE MAMMALIAN RENAL TUBULE

The glomerular capsule of the renal corpuscle, as has been stated, consists of a visceral and a parietal layer or lamella. The visceral layer surrounds the glomerulus very intimately, following the irregularities of its lobes and is often evaginated by major capillary loops. In fully developed renal corpuscles of mammalia, and especially of man, it is often difficult to make out clearly a continuous epithelial layer. Considered histogenetically, the visceral layer of the glomerular capsule is thought to possess a definite epithelial lining consisting of very much flattened epithelial cells with somewhat serrated borders not easily defined in sections. It is often difficult to distinguish clearly their nuclei from the nuclei of the endothelial cells of the superficial glomerular capillaries. The epithelial layer has been regarded as consisting of a thin, nucleated syncytial layer of protoplasm or as disappearing entirely as a continuous epithelial layer in the fully developed renal corpuscles of mammalia. In developing renal corpuscles (Fig. 293) the visceral layer of the glomerular capsule presents in early developmental stages an epithelium of short columnar or cuboidal form with nuclei quite closely juxtaposed, and only when the renal corpuscle has nearly completed its cytomorphosis do the cells of this layer assume

pavement form. In the metanephric renal corpuscles of reptilia, the epithelium of the visceral lamina is usually quite clearly determined as a definite layer of cells with nuclei quite clearly spaced. At the vascular pole of the renal corpuscle the visceral lamella becomes continuous with the cells lining the outer lamella of the glomerular capsule. The epithelial cells of this layer are of polygonal form and are quite readily defined and gradually become thicker as the urinary pole of the renal corpuscle is reached, where they assume short columnar form and become continuous with the epithelial lining of the neck segment of the renal tubule. Braus has estimated that there is transuded through the visceral lamella of each renal corpuscle in man in the course of twenty-four hours 0.03 c.c. of provisional urine consisting of water, with inorganic salts in great dilution and, it would seem, containing also organic substances.

The neck segment of the mammalian renal tubules constitutes a relatively short tubular segment often consisting of a mere slight constriction of the tubule where this joins the renal corpuscle. In mammalia this short tubular segment is lined by an epithelium varying in form from cuboidal to short columnar, in structure simulating the epithelium of the urinary pole of the parietal lamella of the glomerular capsule. The cells appear indistinctly bounded; they possess a granular protoplasm and relatively prominent nuclei. The neck segment of the metanephric tubules of reptilia present a columnar ciliated epithelium, the long cilia projecting into the lumen away from the renal corpuscle. Phylogenetically considered the short segment intervening between the renal corpuscle and the proximal convoluted segment deserves especial designation, even though it forms an inconspicuous tubular segment in the renal tubules of mammalia.

With the beginning of the proximal convoluted segment the renal tubule attains a larger diameter quite suddenly and maintains this larger diameter through the convoluted portion with the medullary segment. The epithelium of this segment, which in previous pages has been designated "renal epithelium," is not easily determined structurally, in that it shows post-mortem change quickly, varies greatly in structural appearance as presented on use of different fixatives, and appears to present quite distinctive structures dependent on phases of physiological activity. The account here given is influenced by that given by Disse. In well-fixed preparations of kidney cortex, the section of the proximal convoluted segments appear in two main varieties, in the one the epithelium appears relatively low with consequent relatively wide lumen; in the other type the epithelium appears relatively high with consequent narrower lumen, with transition types. In the tubular type with wide lumen, the epithelium appears distinctly bounded toward the lumen, although the cell boundaries are quite indistinct. The cells possess relatively large nuclei of spheroidal shape. The basal portion of cells presents a protoplasm with

cytoreticular threads and meshes of rectangular shape, with delicate granules in the more vertically placed cytoreticular threads, which give the basal portion of the cell a striated or rodded appearance first noted by Heidenhain and then found by Rothstein to be due to the arrangement of granules in cytoreticular threads. The supranuclear portion of the cells presents a differentiation which has been designated as brush border. This appears to vary in width and distinctness and often presents a delicate vertical striation, not primarily due to the presence of granules, and suggestive of the striated cuticular border of the surface epithelial cells of the small intestine. A centrosome situated in the protoplasm beneath the brush border has been described by Zimmerman and by Disse. In the tubules with narrower lumen the inner or free border of the lining cells domes into the lumen and the brush border is at times quite indistinct, being replaced by a clear vesicular cap which projects into the lumen of the tubule.

Mitochondria have been found distributed in the protoplasm of the cells of the proximal convoluted segment in the metanephric tubules of reptiles, birds and mammals and well figured by Cowdry (1918), in the kidney cells of a white mouse. They have also been described in the proximal segment of the mesonephric renal tubule of amphibians and the renal cells of pronephric tubules. The direct relation of the mitochondria to renal secretion has not been fully established, since granular constituents other than mitochondria, which resemble these in some respects and differ from them in other respects, have been determined and, according to Cowdry, complicate the question. Oliver (1915, 1916), who has studied the variations of the mitochondrial elements of the normal kidney in different functional states, finds that the batonnets present very uniform character in the renal tubules that have secreted little for some time, forming long sinuous rods which reach from the basal membrane for varying distances toward the lumen. In tubules in the stage of diuresis the batonnets become distinctly granular with free granules in the more apical portion of the cells. Basing interpretation on experimental observation, Oliver suggests that "the secretion of the urea is by means of the mitochondrial batonnets which act as condensers."

Extended experimental observations, dealing with the elimination of dyes through the kidneys, extending now over a long period of years, participated in and very ably reviewed with extensive citation of literature by v. Möllendorff (1915), have thrown much light not only on the function but also on the structure of the renal epithelium. The use of stains in the study of renal secretion was introduced by Chrzonszczewsky (1864). The well-known studies of Heidenhain (1874) on the excretion of sodium sulphindigotate came somewhat later. In these experiments the presence of stain in the epithelial cells of the proximal convoluted segment was accepted as indicative of excretion of the stain by this tubular segment.

Numerous contributions dealing with the excretion of stains by the cells of the renal tubules are found in the literature. But it is not thought necessary to make extensive citations here, since, as noted, this has relatively recently been done in a comprehensive review and contribution by v. Möllendorff, on the elimination of various dyes through the kidney. However, it is desirable to indicate that the evidence is becoming quite clear that the mere presence of stain globules or granules in the protoplasm of the renal cells is not proof positive of the excretory function of such cells. Evidence of resorption of substances which through selective transudation pass through the visceral layer of the glomerular capsule in relatively great dilution, to be resorbed through the renal epithelium in transit through the renal tubule, is accumulating. It has been noted that the colored globules or granules indicative of resorption of stain are found first in that part of the renal cell directed toward the lumen of the tubule, beneath its brush border and only later in the deeper portions of the cells. Figure 294, gves a diagrammatic representation of resorption of colored granules after vital staining with trypan blue.

The observations of v. Möllendorff seem to warrant the conclusion that the deposition of dyes within the cells of the proximal convoluted segment is independent of mitochondrial granules or the batonnets. The observations of Aschoff and his co-workers bring morphological and physiological proof of the excretion of vital dyes through the glomeruli and resorption of the dye through the renal epithelium of the proximal convoluted segment with a condensation of the resorbed dye in granular particles. The close relation of the function of the glomeruli and the accumulation of dye in the renal cells is indicated in the relatively recent experiments of v. Möllendorff (1920*a*, *b*), who found on examining larval amphibia reared in dilute solution of trypan blue that stain granules were found only in those tubules of the developing mesonephros in which the respective renal corpuscles presented a visceral layer of the glomerular capsule having an epithelial lining composed of pavement cells. The very fundamental observations of A. N. Richards and his co-workers, cited in connection with the discussion of the mesonephric tubules of amphibia, are very helpful in forming deductions with reference to the presence of colored globules or granules in the renal epithelium during elimination of stains. The term secretion is, strictly speaking, not correctly used with reference to the renal tubule. So far as can be determined, substances to be transuded into the renal capsule pre-exist in the blood plasma within the glomerular capillaries, and are not transformed in passage through the endothelium and the epithelial layer of the visceral lamella of the glomerular capsule. Although a selective transudation is admitted, it is one not dependent wholly on the blood stream. In the mammalian renal tubule (notably in the cat), the epithelium of the proximal convoluted portion which con-

tinues into the medullary segment, contains lipoid globules. The suggestion seems permissible that in such forms lipoid substances found within the lumen of the renal tubule are resorbed by the renal epithelium, the

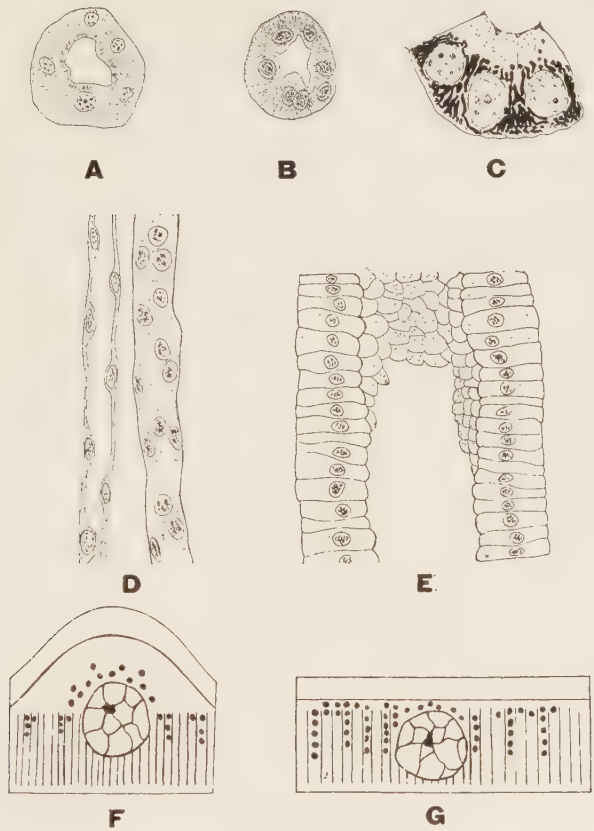

FIG. 294.—Sections of mammalian renal tubules; A, B, D and E. A, cross section of proximal convoluted segment of a renal tubule of a rabbit showing "brush border" and basal striation; B, slightly oblique section of distal convoluted segment of renal tubule of rabbit, showing basal striations; C, kidney cells of white mouse showing mitochondria, × 1500. (Cowdry, 1918.) D, thin segment of medullary loop, renal tubule of rabbit, to left section through lumen, to right surface view of epithelium; E, papillary duct from kidney of rabbit, section and surface view of epithelium; F and G, drawn from a figure of v. Möllendorff (1915), to illustrate resorption of trypanblau in vital staining; F, portion of tubule with protoplasmic cap, "brush border" as light band.

brush border perhaps playing the same rôle as does the striated cuticular border in the intestinal epithelium.

The proximal convoluted portion with medullary segment forms a tubular segment which varies only in an immaterial way in the renal tubules of any one form, irrespective of the total length of the renal tubules of the

respective form. Renal tubules completely isolated from the kidneys of adult rabbits vary in length on actual measurement from approximately 20 mm. to approximately 30 mm. In these same tubules the length of the proximal convoluted portion with the medullary segment was approximately 10 mm. The same general relations maintain in other mammalian forms studied, with slight differences in relative length of the convolute and the total tubule length. The generalization can be extended to include other simpler metanephric tubules of birds and reptiles, with the reservation that in the avian metanephric tubules in which the total length was found to vary between 6.5 mm. and approximately 18 mm., the tubule length of the short tubules is less than the length of the proximal convoluted segment in the longest tubules, namely, approximately 8 mm. In the amphibian mesonephric tubules the proximal convoluted segment forms approximately one-half of the total length of the tubule.

The thin segment of the medullary loop forms that segment of the mammalian renal tubule which has the smallest diameter and is the most variable in length. It is lined by a clear epithelium with pavement cells of polygonal form, with relatively large nuclei. The cells appear distinctly thinner at their borders than in the central portion containing the nuclei, and since the nuclei often appear as if alternately placed on opposing sides of the thin tubes, the lumen is given a slightly wavy course, best seen in well-directed longitudinal sections. Distinct protoplasmic granules, mitochondrial granules and colored granules after vital staining have not been found in the protoplasm of these cells. This tubular segment varies greatly in length in the renal tubules in the same form and there have been noted distinct and constant differences in the relative length of the thin segment of the medullary loop in different mammalian forms. In completely teased renal tubules of adult rabbits, the thin segment of the medullary loop was found to vary in length from approximately 1 mm. to about 15 mm. In the dog and in the cat the thin segments of the medullary loop are, in all tubules, relatively long. In man there are found certain cortical renal tubules in which no thin segment exists, others with relatively short thin segments, still others with relatively long loops and long thin segments, with intermediate forms. The mammalian renal tubule taken collectively presents medullary loops in which there is found no thin, segment—few in man, more numerous in the pig—tubules in which the thin segment of the descending proximal limb of the medullary loop ends before the loop is reached or in the loop, and tubules in which this segment begins in the proximal descending limb, forms the loop and extends a certain distance along the distal ascending limb. In all, irrespective of the relative length of the thin segment, its epithelium is of the same structure.

The thick segment of the medullary loop develops suddenly, following the thin segment, and begins either in the descending proximal limb, in the

loop itself, or in the ascending distal limb of the medullary loop. The epithelium lining the thick segment of the medullary loop and the distal convoluted segment is essentially of the same structure, although the cells are not of the same thickness throughout, thus giving a different diameter to different tubular portions. The similarity in structure of the epithelium in the tubular segments is such that a division into several parts with different types of epithelium seems uncalled for here. The height of the epithelium in the thick segment of the medullary loop and the distal convoluted segment, varies somewhat, as described, for the proximal convoluted segment. In such tubules in which the epithelium is low the lumen is more distinct and regular; in tubules in which the epithelium is high the lumen is constricted and irregular. The cells lining these segments present a clear supranuclear zone devoid of a brush border and a granular basal zone with prominent nuclei of round or oval form in an intermediate position. The granules in the basal zone are arranged vertically, giving the cells a basal striation or rodded appearance; this, though, not quite as distinct as in the cells lining the proximal convoluted segment. According to Oliver, the cells lining the thick segment of the medullary loop and the distal convoluted segment have mitochondria; the batonnets exist as "homogeneous cylindrical formations, and show much less affinity for iron hematoxylin than those of the proximal convoluted tubules." During diuresis they show no change but resemble the appearance seen in resting tubules. According to v. Möllendorff, vital staining is not obtained in the cells of the medullary loop nor the cells of the distal convoluted tubular segment.

The initial collecting tubule, the final segment of the renal tubule proper, develops gradually, following the distal convoluted segment, and is lined by a low columnar or cuboidal epithelium with quite distinct cell boundaries. The cells have relatively prominent nuclei of spheroidal form and a protoplasm which is without distinct granulation. There is found a variable degree of union between initial collecting tubules, without material change in size of resultant tubule or change in epithelial structure.

The primary collecting ducts of the cortex of the kidney, according to Peter, form two main types of union. One of these he has designated arcade formation, where union takes place in the periphery of the cortex, the collecting tubule thus formed passing toward the medulla without receiving further branches. In the other type a limited number of collecting tubules join in the periphery of the cortex; the ducts thus formed, in passing through the cortex, receive further branches at about the level of the convolutes of the respective tubules terminating in them. The ducts of the human kidney unite after the latter type. Traut has added interesting details as to the mode of branching or of uniting of the larger collecting ducts. In the human kidney, beginning with the eighth order of division, which falls to a

level just below the transition from the inner to the outer zone of the medulla, the collecting tubule of the eighth order divides dichotomously in two successive divisions, so that four ducts of the tenth order are formed, which pass without further division cortexward, each to divide further and receive initial collecting tubules in the course throughout the cortex. In the majority of the mammalia more carefully studied, there is found a zone of rapid division of ducts in the deeper portion of the medulla, a wide band of medulla through which the ducts pass without further division, division to be resumed in the periphery of the medulla or only after the ducts pass into the cortex. The ducts throughout are lined by a very regular columnar epithelium, presenting very nearly hexagonal form on surface view. Delicate intercellular cement bars are found near the border of the cells. The cell border toward the lumen is definite, giving the lumen a regular outline. The nuclei are of spherical or ovoid form. The cells of the collecting ducts have a protoplasm which does not present specific granulation, and these cells are without basal striation. They are not stained by vital stains, either diffusely or by storage of colored granules. The thickness of the epithelium increases with the diameter of the collecting ducts, being tallest in the large papillary ducts. By way of recapitulation and summary it may be stated that the following types of epithelium are found, in the order enumerated, in the renal tubules of mammalia: (a) squamous epithelium of the visceral layer of the glomerular capsule; (b) squamous epithelial layer of the parietal layer of the glomerular capsule; (c) cuboidal to short columnar epithelium of the neck segment of the renal tubule; (d) renal epithelium of the proximal convoluted portion and medullary segment with basal striations and brush border; (e) squamous epithelium of the thin segment of the medullary loop; (f) cuboidal to short columnar epithelium of the thick segment of the medullary loop with distal convoluted segment with basal striation but without brush border, and (g) cuboidal to columnar epithelium in the initial collecting tubules and collecting ducts without basal striations in the protoplasm. (Fig. 294.)

By reason of the fact that each mammalian renal tubule presents in the main a type form and is composed serially of tubular segments having a lining consisting of different types of epithelium with consequent differences of tubular diameter and transparency, the kidney substance composed of these tubules, especially in the medulla, irrespective of whether the kidney is unipapillary or multipapillary, becomes divisible into certain zones to which Peter has called especial attention. The medulla is divisible into an inner and an outer zone (zone interna and zone externa), while the outer zone is further divisible into an inner and an outer stripe. These, as given by Peter (1909), are dependent upon the structural changes of the tubules at respective levels. The boundary between the two stripes lies in the region of transition of the medullary segment of the proximal

convoluted portion and the thin segment of the medullary loop and the boundary between the inner and the outer zone in the region where, in the long medullary loop, the thin segment changes to the thick segment of the distal ascending limb of the loop. The line of demarcation is clear in fresh gross preparations, distinct in properly directed sections and easily determined both in unstained and stained macerated and partly teased preparations.

Space does not admit of extensive discussion of the gross anatomy of the mammalian kidney, which is essentially the same, irrespective of whether the kidney is unipapillary or multipapillary or of a type representing a transition from one to other. However, the subject deserves notice to the extent of permitting consideration of the relative position of the renal tubule in the kidney substance. A division of the mammalian kidney into cortex and medulla (substantia corticales and substantia medullaris) is universally recognized. In the cortex there are designated pars radiata (medullary rays) and pars convoluta, surrounding each ray and composed of the convolutes of the renal tubules. The zones of the medulla have been indicated on the preceding pages as consisting of an outer zone, further divisible into an outer and inner stripe, and of an inner zone. Numerous attempts have been made to divide the renal substance of the several renal lobes of a multipapillary kidney or the simple lobe of a unipapillary kidney into smaller, definite structural units, which, multiplied many times, would constitute a renal lobe. Typical structural units are also vascular units. Such a unit may possess an artery which occupies an axial position and is intralobular, while the veins collect toward the periphery and are thus interlobular, as in the splenic lobule (Mall) or in many glands that develop by repeated division of the primary duct anlage, the duct being accompanied through successive divisions by the artery, the main lymph vessels and the nerve. Or the structural unit may possess a central, intralobular vein which drains the lobule, as in the hepatic lobule, while the hepatic arterial branches and the portal branches are in an interlobular position. In the kidney substance neither arterial nor venous units of such type have been clearly determined. In such units as have been characterized, both arterial and venous branches are placed at the periphery and do not develop with the duct system.

Huschke, in 1844, in his "Lehre von den Eingeweiden," describes "Nierenläppschen." They have since been known as lobuli renales or lobuli corticales. In such units a medullary ray forms the axial portion and is surrounded by a layer of the pars convoluta. Pyramidal masses of kidney substance are readily separated in successfully macerated portions of a mammalian kidney, and Traut deserves credit for analyzing such pyramidal masses, involving both cortex and medulla, which he has designated as structural units and, by inference, as lobuli and has given us their general structure. He has characterized such structural units more clearly than has been done before, and it is here suggested that they be designated pseudo-lobuli and not lobuli, since the arterial and venous blood supply are peripherally placed. As pertains to the human kidney, Traut's structural units, the renal pseudo-lobuli, are of pyramidal form and extend from the periphery of the cortex to the inner zone of the medulla. The apex of each renal pseudo-lobule is formed by a single collecting duct of the eighth generation, recognizing the papillary ducts of the adult kidney as of the fourth or fifth generation. The collecting duct of the eighth generation, forming the apex of the pseudo-lobuli, divides dichotomously in two successive divisions, forming thus four ducts of the tenth generation around which and between which are found medullary loops which extend into the medulla to varying depths, thus giving this portion of the renal pseudo-lobule a slender pyramidal form. Relatively few medullary loops extend into the medulla deeper than the level of the

eighth generation of collecting ducts. The cortical portion of each pseudo-lobule, continuous with that of the medullary portion, has the form of a truncated pyramid with the collecting ducts and the straight portions of the renal tubules axially placed and surrounded on all sides by convolutes of renal tubules. Along the borders and the sides and peripheral to the zone of convolutes are found renal corpuscles, placed irregularly at

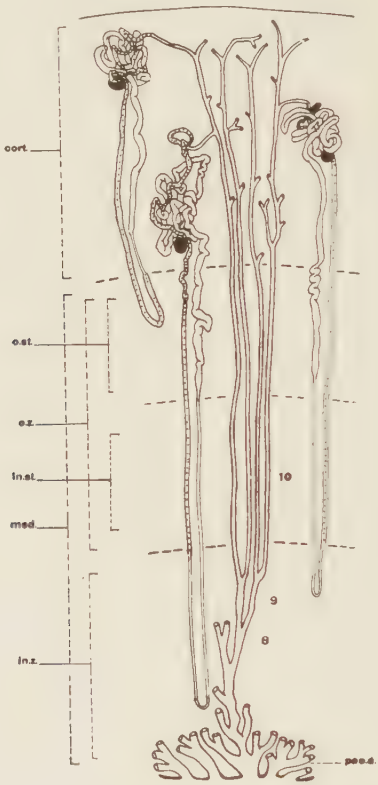

FIG. 295.—Diagram of mammalian renal tubules with collecting duct system indicating topographic relations of the different tubular segments and their relations to the medullary zones as given by Peter. Diagram based on reconstructions and teased preparations and refers in the main to human renal tubules. cort., cortex; in. st., inner stripe; in. z., inner zone; med., medulla; o. st., outer stripe; o. z., outer zone; pap. d., papillary ducts terminating in renal calyx; figures, 8, 9 and 10, refer to the respective successive divisions of the collecting tubule including such divisions as are absorbed into the developing renal pelvis. Collecting ducts of the 8th generation form the apices of renal pseudolobules.

successive levels; between the renal corpuscles, convolutes come to the surface. In a pseudo-lobule, the relations of the different parts of the contained renal tubules as given by Traut (with use of his own words, and with a request for indulgence for change in terminology), is as follows: ". . . as has been stated above, the renal corpuscles of a pseudolobule all lie on the periphery of the unit, where they are in close relation to the

blood supply, while the collecting ducts occupy the center of the structural unit. The space between the corpuscles and the medullary rays is occupied by convoluted tubules so that always, as has been noted by Huber, the proximal and distal convolutions lie between the renal corpuscle and the collecting ducts. This view is at variance with the findings of Peter, who in this diagram often shows the renal corpuscle occupying a position between the convolution and the collecting duct." Traut further states that from dissections he feels certain that the distal convoluted segment of the renal tubule lies in closest apposition to the renal corpuscle, while the proximal convoluted portion lies, for the most part, superimposed upon the distal convoluted segment, the ascending limb of the medullary loop passing very close to its own renal corpuscle, the descending proximal limb lying nearest the collecting duct; with the reservation, noted while discussing the development of the medullary loop, that the whole complex of the renal tubule may rotate on a longitudinal axis, so that the proximal limb of the medullary loop may be said to be tangential as regards the collecting duct. Traut's discussion brings out that in a renal pseudo-lobule the medullary loops "are closely and concentrically grouped into a fasciculus about the collecting duct with which they are confluent, being so bound by light connective tissue stroma, but more securely probably by the extensive capillary bed which surrounds them like a veil." It is difficult to give expression of the ultimate relations of collecting tubules, tubule convolutes and medullary loop in a simple diagram without erring in the direction of making such a diagram very simple and merely a diagram, or so complex as to make it difficult to follow within the limits of a text figure. In Figure 295 is presented a diagram of mammalian renal tubules and ducts based on teased preparations and reconstructions made by the author, by Peter and by Traut.

The ultimate distribution of the blood vessels within the kidney and the relations of the renal tubules to the terminal capillaries deserve brief mention, since they very materially influence conceptions of the function of the renal tubules. The renal artery as it enters the renal sinus divides to form anterior and posterior branches which on further division enter the renal lobes, coursing in the periphery of the medulla as arcuate branches. From the arcuate branches at irregular though close intervals there are given off branches which pass into the cortex. These, following v. Ebner (1899), have long been known as interlobular arteries (arteriae interlobulares). The interlobular arteries are very generally figured as passing into the cortex without much branching and as giving off, at fairly regular intervals, afferent glomerular branches. The name radiate arterial branches is here suggested as more appropriate than interlobular branches. In celluloid injection and corrosion preparations, in which relatively large portions of the renal vascular tree can be successfully injected and macerated from the kidney substance and studied under stereoscopic binocular before and after definite mounting, division of radiate branches is much more common than would appear from current figures, and afferent glomerular vessels are seen to leave the parent stem in clusters of two, three, four and even more, giving a picture of distinct branching of radiate vessels. The term radiate branches furthermore obviates considering the structural units here designated as pseudo-lobules, as vascular units, which they are not, under a strict interpretation of the term.

The point of special interest with reference to the blood supply of the renal tubule, first clearly demonstrated by the author in studies made with celluloid injection and corrosion preparations, relates to the fact that practically all of the arterial blood reaching the capillaries surrounding the different parts of the tubule, both in the cortex and in the medulla, is blood that has passed first through the glomerulus before it reaches the renal tubules. The exceptions to this are negligible and need not be considered in a general statement. In a glomerulus the vas afferens breaks up into a capillary net, clearly shown in the reconstruction figured by Johnston and distinctly evident in well-injected celluloid corrosion preparations. The capillaries collect to form the vas efferens, usually stated to be of smaller caliber than the vas afferens, although it seems reasonable to assume that differences in the diameter of the lumen casts in injected preparations are not proof positive of differences in the diameter of the vas afferens and vas efferens in living tissue, since on arterial injection the vas afferens is subjected to greater pressure than is the vas efferens. The vasa efferentia of the glomeruli of several lower tiers of renal corpuscles divide into long slender arterioles and capillaries which pass into the medulla, surrounding the medullary loops and collecting ducts, known as the arteriolae rectae. The vasa efferentia of the other renal corpuscles divide into long close-meshed capillary nets which surround the convoluted cortical portions of the renal tubules. That the circulation of the kidney was primarily a glomerular circulation was taught by Huschke (1828) and Bowman (1842). Others of the earlier writers, notably Ludwig (1854) and Virchow (1857), were of the opinion that arterial blood passed directly to the renal tubules without passing through the glomeruli, and the latter stressed the presence of arteriolae rectae verae.

Nearly all of the current text figures still give recognition to the views of Virchow, although the author in 1907, in celluloid preparations, was able to determine and demonstrate quite clearly that arteriole rectae verae arising directly from arcuate or radiate arterial branches were negligible in number, their presence being accounted for by degeneration of renal tubules with established glomerular circulation. These observations were confirmed by Morrison (1926) who states that "the medulla of the kidney receives its blood supply solely from efferent branches of the lower glomeruli"; by MacCallum (1926), who concludes that "the arteriolae rectae arise in the dog, cat, rabbit, guinea pig, rat and opossum exclusively from the vasa efferentia of glomeruli"; and finally Traut (1923), who says: "In all my dissections of the human kidney the existence or non existence of 'arteriolae rectae veriae' has been constantly in mind and a careful search has offered only six instances in which they could be demonstrated, as against the usual and what is, I am convinced, the normal vascular arrangement, where the capillary beds surrounding the tubular elements are

supplied by the efferent glomerular artery." In the cortex certain few arterioles, branches of radiate arterial vessels, terminate in connective tissue, in the outer cortical zone and in the renal capsule, in terminal capillary

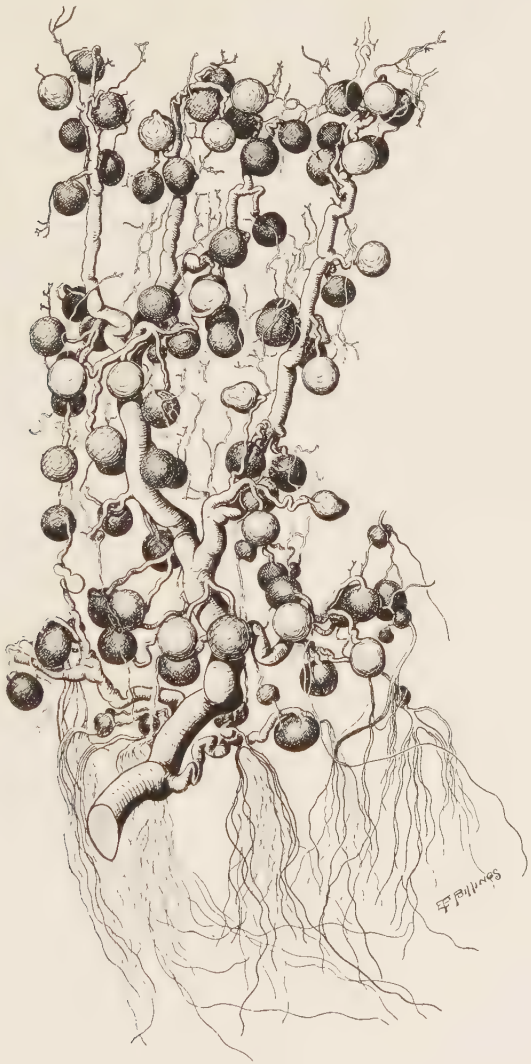

FIG. 296.—Celluloid corrosion preparation of the terminal arterial branches of the renal artery of a dog, showing arcuate and radiate arterial branches, arteriolae rectae and portions of the cortical capillary net.

nets; but, as correctly stated by Morison, "nonglomerular sources of nutrient supply are, however, so infrequent as to be negligible from a physiological point of view." The course of the venous renal ssveels, from

radicals to exit, varies non-essentially in gross pattern in different mammalian forms, but this offers no point of special interest from the viewpoint of function; therefore, it need not occupy space here. In Figure 296 there is presented a very careful drawing of a corrosion preparation of the terminal arterial branches from the kidney of a dog, bringing to view many of the points presented in the above discussion. Braus records an estimate which states that of 500 to 600 liters of blood that pass through the renal vessels of man in the course of twenty-four hours, there pass into the renal tubules through the visceral lamellae of the glomerular capsules of the renal corpuscles, by selective transudations, approximately 60 liters of fluid, which in transit through the renal tubules are resorbed, leaving, as the quantity of final urine, about 1.5 liters per diem. The conclusion seems warranted that the blood surrounding the renal tubules in capillary nets, both in the cortex and in the medulla, blood which has first passed through the glomeruli, is of a composition as to water and salt content which would favor the resorption.

The best account of the innervation of the renal tubule is that given by v. Smirnow (1901) who made extensive studies using both chrome silver and methylene blue methods. He describes delicate fibrils terminating on both convoluted and straight portions of the renal tubules and on the outer lamella of the glomerular capsule. Terminal endings between renal cells are noted and figured. Hirt has relatively recently written on the gross relations of the thoracico-lumbar and cranio-sacral sympathetic innervation of the kidney in a number of laboratory mammals. The contribution is illustrated by instructive figures.

V. BIBLIOGRAPHY

Aschoff, L. 1924. *Renal secretion and renal diseases.* Harvey Lectures. Phila.: J. B. Lippincott Co.

Augier, A. 1921. Appareil urinaire. Les reins et leurs canaux excréteurs. In *Traité d'anatomie humaine,* **5,** 37.

Bowman, W. 1842. On the structure and use of the Malpighian bodies of the kidney, with observations on the circulation through the gland. *Phil. Trans. Roy. Soc.,* **1,** 57.

Braus, H. 1924. Anatomie des Menschen. In *Harn- und Geschlechtsapparat,* **2,** 327. Berl.: Springer.

Chrzonszczewsky. 1864. Zur Anatomie der Niere. *Virchow's Archiv,* **31,** 153.

Cowdry, E. V. 1918. The mitochondrial constituents of protoplasm. *Contributions to Embryology, Carnegie Institution,* **8,** 39.

Disse, J. 1902. Harn- und Geschlechtsorgane. In v. Bardeleben, *Handbuch der Anatomie des Menschen,* **7,** 1.

v. Ebner, V. 1899. Von den Harnorganen. In Koelliker's *Handbuch der Gewebelehre des Menschen,* **3,** 342. Leipz.: Engelmann.

Ecker, A., and Weidersheim, R. 1901. *Anatomie des Frosches.* (Gaupp's edition.) Dritte Abt., 238. Braunschweig: Vieweg und Sohn.

Emery, C. 1883. Recherches embryologique sur le rein des mammifères. *Arch ital. de Biol.,* **4,** 80.

Felix, W. 1906. Die Entwickelung des Harnapparates. *In Handbuch der vergleichenden und experimentellen Entwickelungslehre der Wirbeltiere;* **3,** 81. Jena: Fischer.

——— 1912. The development of the urogenital organs. In Keibel and Mall, *Manual of Human Embryology,* **2,** 752.

Hayman, J. M., Jr., and Richards, A. N. 1926. Deposition of dyes, iron and urea in the cells of a renal tubule after their injection into its lumen: glomerular elimination of the same substances. *Am. J. Phys.,* **79,** 149.

Heidenhain, R. 1874. Mikroskopische Beitrage zur Anatomie und Physiologie der Niere. *Arch. f. mikr. Anat.,* **10,** 1.

Henle, J. 1862. Zur Anatomie der Nieren. *Abhandl. d. k. Gesellsch. d. Wissensch. Göttingen,* **10.**

Hinman, F., Morison, D. M., Lee-Brown, R. K. 1923. Method of demonstrating the circulation in general, as applied to a study of the renal circulation in particular. *J. Am. Med. Ass.,* **81,** 177.

Hirt, A. 1926. Ueber den Faserverlauf der Nierennerven. *Ztschr. f. d. Ges. Anat.,* **78,** 260.

Huber, G. Carl. 1905. On the development and shape of uriniferous tubules of certain of the higher mammals. *Am. J. Anat.,* **4** (Supplement), 1.

——— 1907. The arteriolae rectae of the mammalian kidney. *Ibid.,* **6,** 391.

——— 1910. *The morphology and structure of the mammalian renal tubule.* Harvey Lectures. Phila.: J. B. Lippincott Co.

——— 1911. A method for isolating the renal tubule of mammalia. *Anat. Record,* **5,** 187.

——— 1917. On the morphology of renal tubules of vertebrates. *Ibid.,* **13,** 305.

Huschke, Prof. 1828. Ueber die Textur der Nieren. *Isis von Oken,* **21,** 560.

——— 1844. Lehre von den Eingeweiden. In Sömmering's *Handbuch.*

Johnston, W. B. 1899. A reconstruction of a glomerulus in the human kidney. *Anat Anz.,* **16,** 260.

Lorenz, H. 1889. Ueber den Bürstenbesatz und dessen Bedeutung an normalen und pathologischen Nieren. *Ztschr. f. klin. Med.,* **15,** 400.

Ludwig, C. 1872. Ins Stricker, *Handbuch der Lehre von den Geweben des Menschen und der Thiere* (In translation as "A Manual of Histology." N. Y., 1872, See Chap. 26 (The Kidney), 460.)

Ludwig, C., and Zawarykin, Th. 1863. Zur Anatomie der Niere. *Sitzungsb. d. Kais. Akad. d. Wissensch. Wien.* Sonderabdruck, 1–34.

MacCallum, D. B. 1926. The arterial blood supply of the mammalian kidney. *Am. J. Anat.,* **38,** 153.

v. Möllendorff, W. 1915. Die dispersität der Farbstoffe, ihre beziehungen zu Ausscheidung und Speicherung in der Niere. *Anat. Hefte,* **53,** 81.

——— 1919. Funktionelle Entwicklung der Urniere von Rana fusca. *Greisfw. Med. Ver. in Deutsche Med. Wochenschr.,* No. 12.

——— 1920*a*. Ueber Funktions-beginn und Funktionsbestimmung in den Harnorganen von Kaulquappen. *Festschrift f. M. Fürbringer Sitz. Ber. Heidelbg. Akad. Math. Naturw. Cl.,* Abt. B.

——— 1920*b*. Vitale Färbungen an Tierischen Zellen. *Ergeb. d. Physiol.,* **18,** 141.

Morison, D. M. 1926. A study of the renal circulation, with special reference to its finer distribution. *Am. J. Anat.,* **37,** 53.

Nussbaum, M. 1878. Fortgesetzte Untersuchungen über die Sekretion der Niere. *Pflüger's Archiv,* **17,** 580.

——— 1886. Ueber den Bau und die Thätigkeit der Nierenorgane. *Arch. f. mikr. Anat.,* **27,** 442.

Oliver, Jean. 1915. The histogenesis of chronic uranium nephritis with especial reference to epithelial regeneration. *J. Exper. Med.*, **21**, 425.

——— 1916. A further study of the regenerated epithelium in chronic uranium nephritis. An anatomical investigation of its function. *Ibid.*, **22**, 301.

Peter, K. 1907. Ueber die Nierenkanälchen des Menschen und einiger Saugetiere. *Verhandl. d. Anat. Gessels.*, 114.

——— 1908. Ueber den feineren Bau der menschlichen Niere. *Ibid.*, 159.

——— 1909. *Untersuchungen über Bau und Entwickelung der Niere.* Jena: Fischer, 446 pp.

Policard, A. 1912. Les divers segments du tube urinaire du rein des mammifères. *Comp. rend. Assoc. d. anat.*

Richards, A. N., and Schmidt, C. F. 1922. The glomerular circulation in the frog's kidney. *Am. J. Phys.*, **59**, 489.

Rothstein. 1891. Zur Kenntnis des Nierenepithels. In *Biologica Föreningens Förhandlinger*, 3 (cited from Disse).

Sauer, H. 1895. Neue Untersuchungen über das Nierenepithel und sein Verhalten bei der Harnabsonderung. *Arch. f. mikr. Anat.*, **46**, 109.

Schachowa, S. 1876. *Untersuchungen über die Nieren.* Dissertation. Bern.

Schweigger-Seidel, F. 1865. *Die Nieren des Menschen und der Säugethiere in ihrem feinen Baue.* Halle. 1–89.

Shikinami, J. 1926. Details of the Wolffian body in human embryos of the first eight weeks. *Contributions to Embryology, Carnegie Institution*, **18**, 49.

v. Smirnow, A. E. 1901. Ueber die Nervenendigungen in den Nieren der Saugetiere. *Anat. Anz.*, **19**, 347.

Traut, H. F. 1923. The structural unit of the human kidney. *Contributions to Embryology, Carnegie Institution*, **15**, 103.

Virchow, R. 1857. Einige Bemerkungen über die Circulationsverhältnisse in den Nieren. *Arch. f. Path. Anat.*, **12**, 310.

Watt, J. C. 1915. Description of two young twin human embryos with 17–19 paired segments. *Contributions to Embryology, Carnegie Institution*, **2**, 5.

Wearn, J. T., and Richards, A. N. 1924. Observations on the composition of glomerular urine, with particular reference to the problem of resorption in the renal tubules. *Am. J. Phys.*, **71**, 209.

Zarnik, B. 1910. Vergleichende Studien über den Bau der Niere von Echidna und der Reptilienniere. *Jenaischen Ztschr. f. Naturwiss.*, **46**, 113.

LANE MEDICAL LIBRARY
300 PASTEUR DRIVE
PALO ALTO, CALIFORNIA 94304
Ignorance of Library's rules does not exempt violators from penalties.

SEP - 9 1971

50M-10-63-5632

LANE MEDICAL LIBRARY
300 PASTEUR DRIVE
PALO ALTO, CALIF. 94304

D581
C88
v.1
1928

Cowdry, E. V. 67819
Special cytology.

NAME	DATE DUE
Sue Kilk (Lier)	MAR 28 1952
VA HOSPITAL, STA 1787 OAKLAND, CALIFORNIA	NOV 11 1955
	Cm
D Berman	MAR 7 1958
Lc. 4.1 - Lc. 5.6 - Lc. 6.3 - Lc. 7.1	
Lc. 8.5 - Lc. 9.16 - Lc. 10	
Yes Dr. Sharon	1
Jh. 10/20	
I M. Sharon by B	
Ken	
J H Cohen (B	
R F Tallma	
K. HOLLO	
Ames	

D581
C88
1928
v.1